

Intracranial Mesenchymal Chondrosarcoma: Introducing Two Cases

İntrakranyal Mezenkimal Kondrosarkoma: İki Olgu sunumu

ALPER KAYA, OSMAN TÜRKMENOĞLU, YÜKSEL ŞAHİN, YUNUS AYDIN, CANAN TANIK

Sisli Etfal Hospital, Department of Neurosurgery, (AK, OT, YŞ, YA), İstanbul

Sisli Etfal Hospital, Department of Pathology, (CT), İstanbul

Geliş Tarihi: 13.3.1998 ⇔ Kabul Tarihi: 6.8.1999

Abstract: Intracranial mesenchymal chondrosarcomas, and especially those that originate from the dura mater, are very rare. This paper describes two cases of primary intracranial mesenchymal chondrosarcoma that originated from the right frontal dura mater and the left tentorium. The patients were both females, aged 25 and 30 years of age. The patient with the tentorial tumor had undergone surgery for the same lesion 1 year earlier, at which time the mass had been histopathologically misdiagnosed as meningioma. We discuss the histopathological features, computed tomography findings, and treatment of these tumors, and review the relevant literature.

Key Words: intracranial mesenchymal chondrosarcoma, meningeal tumor, tentorial tumor

Özet: İntrakranyal mezenkimal kondrosarkomlar, özellikle dura materden kaynaklanmış olanlar, çok enderdirler. Bu makalede, sağ frontal dura mater ve sol tentoriumdan kaynaklanmış iki primer intrakranyal mezenkimal kondrosarkoma anlatılmaktadır. Hastaların her ikisinde boyandı, yaşları 25 ve 30'du. Tentoryal tümürlü hasta, bir yıl önce aynı lezyon nedeniyle opere edilip histopatolojik olarak menenjioma yanlış tanısı konmuştur. Bu tümörlerin tedavilerini, histopatolojik özelliklerini, bilgisayarlı tomografi bulgularını tartışıp, ilgili literatürü gözden geçireceğiz.

Anahtar Sözcükler: İntrakranyal mezenkimal kondrosarkoma, meningeal tümör, tentoryal tümör

INTRODUCTION

Intracranial mesenchymal chondrosarcoma, an unusual but well-defined tumor, was first described by Lichtenstein and Bernstein in 1959. This form of neoplasia generally develops in bone, especially in the pelvis, ribs, femur, humerus, vertebrae, and mandible, and is less commonly found in somatic soft tissue (17,19,25). The central nervous system is the most commonly reported extraosseous site of origin (10,13,19,26). These tumors are often located in the head and neck and, before histopathological examination, are often misdiagnosed as a different

tumor of the cranial cavity, such as meningioma or hemangiopericytoma (10,13,19,26). However, mesenchymal chondrosarcomas differ from other benign and malignant tumors in that they consist of cellular mixtures of small spindle-shaped anaplastic cells, and are frequently located around small vessels in chondroid tissue at various stages of development. The tumors have a characteristic bimorphic pattern, and are made up of islands of hyaline cartilage within a population of small, undifferentiated, mesenchymal cells. Although the histopathological appearance of this tumor is quite distinct, their rarity, their frequent occurrence in the meninges, and their highly vascular

structure can lead to the erroneous diagnosis of angioblastic meningioma or hemangiopericytoma.

The two cases described here were both initially thought to be meningioma, but postoperative histopathological examination led to the diagnosis of mesenchymal chondrosarcoma. In our patients, the interesting similar features were the lack of a tumor focus outside the cranial cavity, computed tomography (CT) appearance of high, homogeneous contrast enhancement with calcification and sharp contours, a well-developed, firm, pinkish-white mass which was easily removed from the brain tissue at surgery, and no invasion of brain parenchyma or vascular structures.

CASE 1

Background:

A 30-year-old female presented with the complaints of vomiting, disequilibrium, and left-sided hearing loss. This was the patient's second admission to the clinic as she had undergone surgery 1 year earlier for a left tentorial mass that had been histopathologically diagnosed as meningioma. Her neurological examination revealed loss of hearing due to pressure on the left auditory nerve, as well as ataxia and bilateral papilledema. CT showed a supratentorial lobulated mass extending from the cerebellopontine angle at the posterior fossa to the thalamus in the supratentorial region (Figure 1a). The mass was also obstructing the transverse sinus and the cerebellopontine cistern. In precontrast sections,

the mass was slightly hyperdense and its posterior section contained calcified areas. After contrast injection, the mass was homogeneously hyperdense. We also detected compression of the third ventricle and a shift of the supratentorial structures approximately 5 mm to the right. It was interesting to note that the tumor had regained its original size within a year of having been excised from the dura mater.

Surgery:

The previous incision scar, which extended from the temporal region to the occipitoretromastoid region above the ear, was used to lift the skin flap. Because the tumor had infiltrated the mastoid bone, the previous craniectomy defect was enlarged until intact bone was reached. The dura graft used for the first operation was removed completely. After total removal of the tumor, the dura was closed using a new autograft. Total removal of the tumor was confirmed by CT in the early postoperative stage (Figure 1b).

Postoperative History:

The patient's auditory nerve paresis continued, but there was noticeable recovery with regard to her ataxia. The histopathological diagnosis was mesenchymal chondrosarcoma. Total-body bone scintigraphy and CT scanning of the thorax and abdomen revealed no other tumor focus. Also, repeat cranial CT done at regular intervals four times during the year after her second operation showed no tumor recurrence. The patient also underwent radiotherapy.

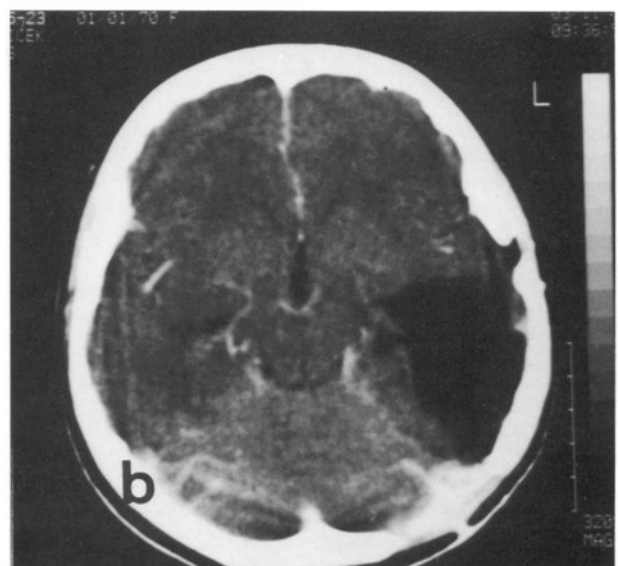
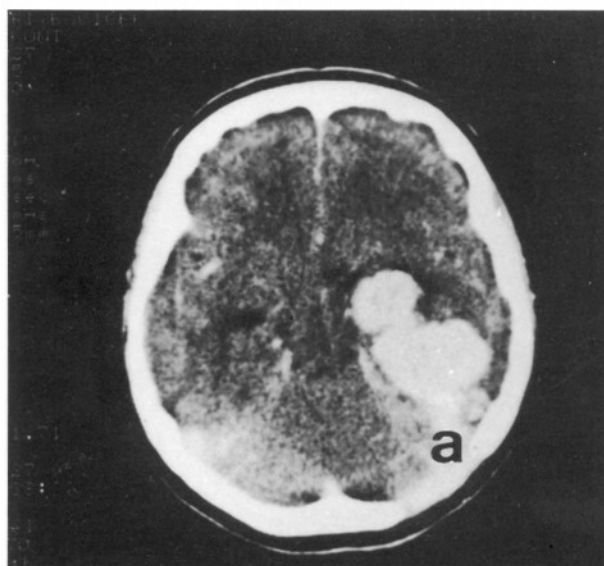


Figure 1: a) Preoperative CT scan of Case 1 showing a left tentorial, lobulated, hyperdense mass after contrast injection, b) after total excision of the tumor.

CASE 2

Background:

A 25-year-old female presented with the complaints of headache, vomiting, and reduced sight. Her only abnormalities on neurological examination were bilateral papiledema and reduced long-distance sight. Cranial CT showed a 4.5 cm diameter mass in the frontal midline (Figure 2a) that was slightly hyperdense on precontrast sections and became hyperdense after contrast injection.

Surgery:

A bicoronal approach was used for the operation. When the bone flap was lifted, we could see that the tumor had invaded the dura and the adjacent bone. The tumor tissue was well vascularized, pinkish-white in color, and quite firm. After removing the mass from the cortex, we severed its connections with the falx cerebri. There was no invasion of the brain parenchyma or the pericallosal arteries. The dura was closed using an autograft, and all damaged bone was removed. A postoperative cranial CT confirmed total removal of the tumor (Figure 2b).

Postoperative History:

In the long term, the patient's complaints diminished significantly. The histopathological diagnosis was mesenchymal chondrosarcoma. This patient was followed in the same manner as Case 1. There was no other tumor focus, but cranial CT at 18 months postsurgery showed evidence of recurrence.

The patient refused treatment with either chemo- or radiotherapy.

Histopathology:

Macroscopically, the tumors in both cases were firm, pinkish-white, and coarsely nodular. The tumor surface exhibited a large vascular network. The cut surface showed areas of mixed bony and cartilaginous material.

The histological features of the two tumors were identical. Microscopically, there was a highly cellular area composed of spindle-shaped polygonal and oval cells with scant cytoplasm. Most nuclei were small, hyperchromatic, and polymorphous, and mitotic figures were rare. The tumor cells were clustered around the numerous vessels, resembling a hemangiopericytoma. In some areas, the cells were arranged as irregular diffuse sheets. Silver-impregnated reticulin fibers allowed the observation of individual tumor cells and distinguished them from the vascular channels. Islands of well-differentiated hyaline cartilage contained central areas of calcification. Osteoid and mature osseous differentiation suggesting metaplastic change was observed in some regions. The undifferentiated cells were round to spindle-shaped, and contained inconspicuous nuclei and sparse cytoplasm. The second histological pattern which is seen in both of the cases, was composed of islands of hyaline cartilage at various stages of maturity interspersed in the cellular matrix (Figures 3a, 3b, 4a, 4b).

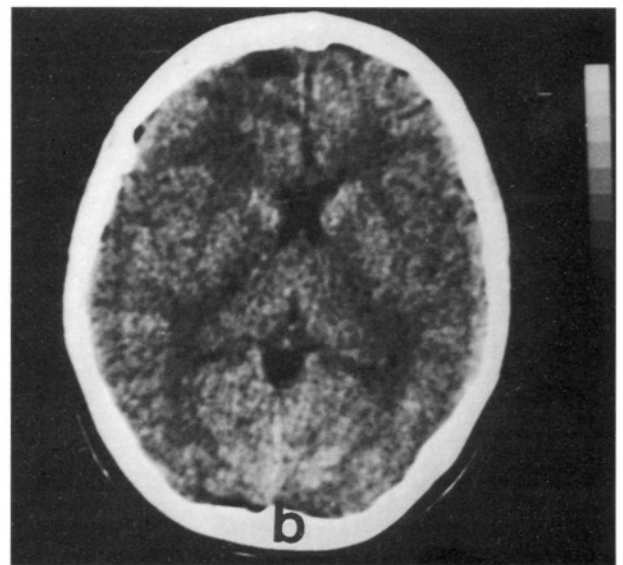
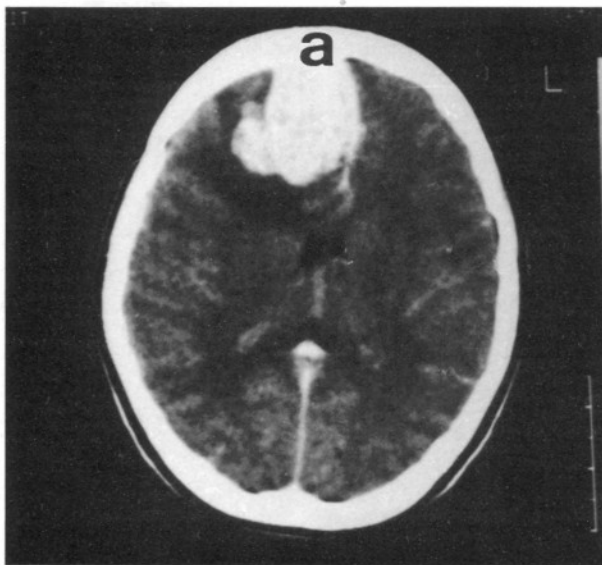


Figure 2: a) Preoperative CT scan of Case 2 showing a right-sided, frontal, hyperdense mass after contrast injection, b) after total excision of the tumor.

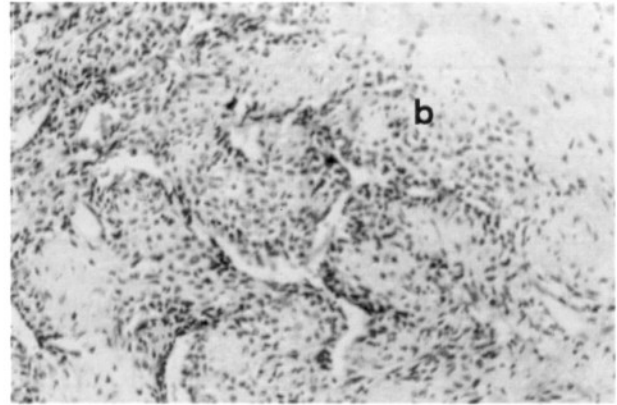
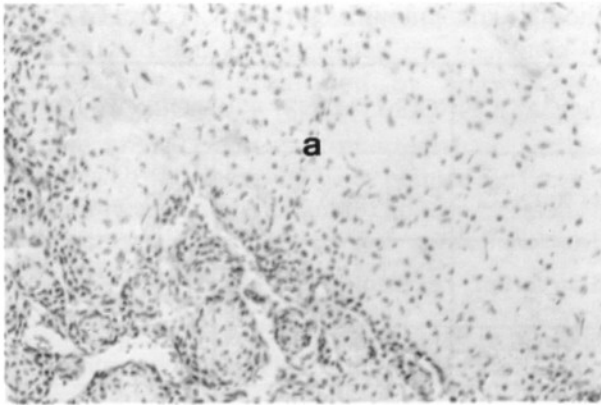


Figure 3: a) Clusters of mesangial cells among chondroid areas (Case 1) H&E X 100, b) mesangial areas including hemangioperistameteous fissures and chondroid areas (Case 2) H&E X 100.

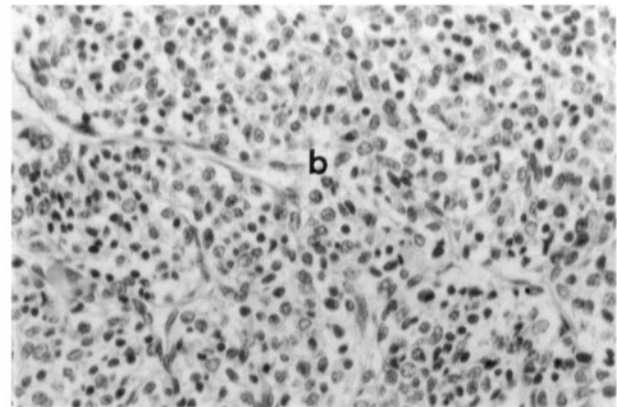
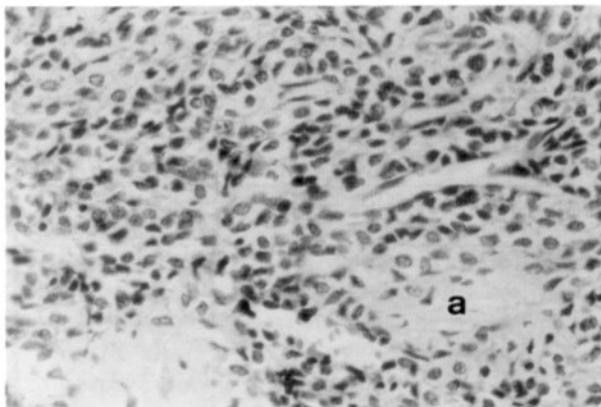


Figure 4: Small round cells with hyperchromatic nuclei and scant cytoplasm, and hemangioperistameteous fissures a) Case 1, b) Case 2 H&E X 200.

DISCUSSION

Chondrosarcomas are malignant cartilaginous neoplasms that originate from bone, cartilage, and mesenchymal soft tissue. They are currently classified as skeletal or mesenchymal types. Both types of chondrosarcoma, each with a distinct morphological appearance, can arise from bone and extrasosseous mesenchymal tissue. Pure skeletal type extrasosseous intracranial chondrosarcomas are rare, and seem have a better prognosis (1).

The first observation of primary intracranial mesenchymal chondrosarcoma, a mass located in the parietal dura, was noted by Dahlin and Henderson in 1964 (6). Table 1 lists all the primary intracranial mesenchymal chondrosarcoma cases noted in the literature since that first discovery. All of these originated in the brain or dura mater. The extradural mesenchymal chondrosarcoma cases originated from the cranium or from adjacent soft tissues, and the

intracranial mesenchymal tumors, which contain cartilage with unusual microscopic features, were excluded from the list. (1,2,8,15,18,27-29).

The clinical symptoms associated with intracranial mesenchymal chondrosarcoma are quite nonspecific, including pain and focal neurological deficits. Subarachnoid and intracranial hemorrhage was observed in only one of eight cases reported by Scheithauer et al., and in the case reported by Chemm (4,26). Craniography can detect findings associated with increased intracranial pressure, regions of calcification, and osteolytic and destructive changes (5,10,13). Although calcification of the lesion and local destruction in the frontal bone were observed in Case 1 during the operation, craniography showed no pathological findings in this patient. In contrast, craniograms for Case 2 showed a previous craniectomy defect and local destruction in the left petrous bone.

Tablo I: Reported Cases of Intracranial Mesenchymal Chondrosarcoma with Dural or Cerebral Origin*

AUTHORS	PATIENT 'S AGE	PATIENT 'S SEX	TUMOR LOCATION	TREATMENT	FOLLOW-UP
Dahlin&Henderson 1962 (6)	44	F	Rt parietal dura mater	Excision: X 10	D:9yr R:X 9
Raskind&Grant 1966 (22)	48	F	Rt frontal cerebrum	Excision	D:3d
Wu&Lappi 1970 (31)	18	F	Rt frontoparietal dura mater	Excision : X 3 Rad	D: 16 mo R: X 3
Guccion et al. 1973 (9)	32	M	Lt parietal dura mater	Excision: X 2 Rad	?
Scheithauer&Rubinstein 1978 (26)	7 17 40	M F M	Rt middle fossa dura mater Anterior fossa dura mater Convexity dura mater	Excision Rad Excision Rad Excision	D: 7yr R : X 1 D: 2yr D: 5d
Zucker&Horoupian 1978 (32)	19	M	Suboccipital tentorial dura mater	Excision	?
Rollo et al. 1979 (23)	11	M	Lt tentorial dura mater	Excision : X 2	A : 9yr R : X 1
Heros& Martinez 1980 (12)	22 33 26 23	F M F F	Frontoparietal dura mater Lt sphenoid wing dura mater Lt cerebellum Rt parietal dura mater	Excision Excision: X 2 Excision Excision	D : 3 d A: 3yr R: X 1 A : 2,5 yr A: 4,5 yr
Kobayashi et al. 1980 (14)	11	F	Lt parietal dura mater	Excision: X 3 Rad : X 2	D: 18yr R: X 2
Kubota et al. 1982 (16)	22	F	Bilateral frontal dura mater	Excision	D: 6yr 10 mo
Chhem et al. 1992 (4)	11	F	Lt parietal cerebrum	Excision Rad: X 1	D: 18 mo R: X 1
Cho et al. 1992 (5)	13	F	Superior sagittal sinus	Excision : X 2 Rad: X 1	A: 38 mo R: X 1
Nozaki et al. 1999 (21)	15	M	Lt sigmoid sinus dura mater ? or Lt jugular foramen?	Excision Rad : X 1	A : 35 mo
Kaya et al. Present case	25 30	F F	Rt frontal dura mater Lt tentorium	Excision Excision: X2 Rad: X 1	A: 27 mo R: X 1 A: 2yr, R: X 1

Abbreviations : A, alive; D, dead; Lt, left; R, recurrence; Rad, radiotherapy; Rt, right; X, times (frequency).

Because of the close association of mesenchymal chondrosarcoma with the dura, the CT findings in these cases can lead to the misdiagnosis of meningioma. It is interesting to note that only a few of the cases reported in the literature were examined by CT. Precontrast sections showed isodense or slightly hyperdense lobulated calcified masses with

surrounding hypodense areas. Postcontrast sections showed high and homogeneous contrast uptake. Although some of these findings are not specific and can be confused with those of meningioma, the observation of a lobulated calcified mass with a hypodense area around it is relatively rare in meningioma.

Since mesenchymal chondrosarcomas are more vascularized than meningiomas, they can be more successfully differentiated by angiography (5,10,12,16,20). Before the use of CT became more routine, in 1980 Heros et al. reported a case that was examined by angiography. They pointed out that the appearance of mesenchymal chondrosarcoma in angiography can easily be confused with arteriovenous malformation (12).

Preoperative embolization may be very useful for highly vascularized large tumors that are difficult to excise due to excessive bleeding, as in our Case 1. On pathological examination, both of our patients' tumors were macroscopically described as lobulated firm masses that bled excessively and were easily dissected from normal brain tissue. None of the cases described in literature mentioned any difficulty dissecting the tumor from normal brain tissue. Significant bone and dura invasion, and a marked tendency to bleed were common features of the reported cases. (5,12,16,26).

Microscopically, mesenchymal chondrosarcomas are biphasic tumors composed of a mixture of hyaline cartilage islands in an undifferentiated stroma composed of small cells resembling primitive mesenchymal cells. These stroma cells are polygonal or spindle-shaped, and have a hyperchromatic pleomorphic nucleus and scant cytoplasm. Mitotic figures are common. The histogenesis of these cells is still under debate, and they are generally thought to be primitive mesangial or precartilaginous cells. The cells of the hyaline cartilage islands are generally well differentiated. It has been suggested that sarcomas of the brain and meninges originate from pluripotential mesenchymal cells, or from their derivatives (24). These cells are present in the arachnoid extensions that enclose the cerebral blood vessels. Fibroblasts, arachnoid and pial cells are, therefore, the potential sources of intracranial sarcomas (1,26).

Tumors of cartilage cells represent 0.6% of all intracranial tumors (3). Of these, chondroma and chondrosarcoma are the most common. Mesenchymal chondrosarcomas constitute 1.2% of all intracranial sarcomas (24,25). The cartilage cells of nonmesangial chondrosarcomas exhibit more pleomorphism, and there is a sharp distinction between cartilage and stroma, which distinguishes them from mesenchymal chondrosarcomas. The latter should also be distinguished from meningiomas, which can include cartilage, although differentiation into cartilage is very rare in all types

of meningioma. Nevertheless, when mesenchymal chondrosarcoma includes a few mesenchymal cells, as in Case 1, it can be confused with an angioblastic type of meningioma and hemangiopericytoma (15,26).

Epithelial membrane antigen is often present in meningiomas, and this test was negative in our two cases. Nonangioblastic meningiomas that have a cartilage component can easily be identified because of their low vascular content. A cartilage component is rare in angioblastic meningioma and, if present, is very limited compared to that of mesenchymal chondrosarcoma. Similarly, hemangiopericytomas involving cartilage islands can also be mistaken for mesenchymal chondrosarcomas. However, the presence of cartilaginous islands generally prevents the confusion with hemangiopericytoma, as the literature contains only one case of hemangiopericytoma containing cartilaginous islands (7). Dahlin and Scheithauer reported that the cartilaginous content of the tumor decreases in the case of recurring mesangial chondrosarcoma (6,26). In our study, no recurrence has been observed to date in Case 2, and in Case 1 the cartilaginous content was higher in the samples taken the previous year.

Radical excision is widely accepted as the treatment of choice for mesenchymal chondrosarcoma. However, the tendency for the tumor to recur locally is quite high (26). It has been suggested that recurrence does not necessarily dictate shorter life span, as it does in cases of extracranial mesenchymal chondrosarcoma (20). On rare occasions, extracranial metastasis can also be observed (30). In order to prevent local recurrence, adjuvant radiotherapy can also be used, especially when total excision is not possible (10,11). After being diagnosed with mesenchymal chondrosarcoma, the patient in Case 1 underwent radiotherapy. The other patient declined any form of therapy. Although the effect of chemotherapy on these tumors is still under debate, some authors recommend chemotherapy in both the pre- and postoperative periods (10,13).

Correspondence: Alper Kaya

İş : Şişli Etfal Hastanesi
Nöroşirürji Kliniği Şişli/İstanbul 80270
Ev Tel: 212 296 25 22
İş Tel : 212 234 33 38

REFERENCES

1. Alvira MM, McLaurin RL: Asymptomatic subdural chondrosarcoma. *J Neurosurg* 48:825-828, 1978
2. Ball J, Cook TA, Lynch PG, Timperley WR: Mixed mesenchymal differentiation in meningiomas. *J Pathol* 116:253-258, 1975
3. Berkmen YM, Blatt ES: Cranial and intracranial cartilaginous tumors. *Clin Radiol* 19: 327-333, 1968
4. Chemm RK, Bui BT, Calderon-Villar H, Fontaine S: Case Report : Primary mesenchymal chondrosarcoma of the brain. *Clinical Radiology* 45 : 422-423, 1992
5. Cho BK, Chi JG, Wang KC, Chang KH, Choi KS : Intracranial mesenchymal chondrosarcoma. A case report and literature review. *Child's Nerv Syst* 9 : 295-299, 1993
6. Dahlin DC, Henderson ED: Mesenchymal chondrosarcoma. Further observations on a new entity. *Cancer* 15: 410-417, 1962
7. Ensinger FM, Weiss SW: Mesenchymal chondrosarcoma in soft tissue tumors. Third edition, Mosby 95 USA, St. Louis p1004-1008, 1995
8. Fisher FR, Davis JS, Lemmen IJ: Meningeal hemangiopericytoma. *Arch Neurol Psychiatry* 79: 40-45, 1958
9. Guccion JG, Font RL, Enzinger FM, Zimmerman LE: Extracranial mesenchymal chondrosarcoma. *Arch Pathol Lab Med* 95: 336-340, 1973
10. Harsh GR, Wilson CB: Central nervous system mesenchymal chondrosarcoma. *J Neurosurg* 61 : 375-381, 1984
11. Harwood AR, Krajchich JI, Fornasier VL: Mesenchymal chondrosarcoma. A report of 17 cases. *Clin Orthop* 158: 144-148, 1981
12. Heros CR, Martinez AJ, Ahn HS: Intracranial mesenchymal chondrosarcoma. *Surg Neurol* 14: 311-317, 1980
13. Huvos AG, Rosen G, Dabska M, Marcove RC : Mesenchymal chondrosarcoma. A clinicopathological analysis of 35 patients with emphasis on treatment. *Cancer* 51: 1230-1237, 1983
14. Kobayashi T, Yoshida J, Kageyama N, Makita Y, Aoyama I, Yamashita J: Mesenchymal chondrosarcoma arising from dura mater. *No Shinkei Geka* 8: 881-887, 1980
15. Kruse F Jr: Hemangiopericytoma of meninges (angioblastic meningioma of Cushing and Eisenhardt). Clinicopathologic aspects and follow-up studies in 8 cases. *Neurology* 11: 771-777, 1961
16. Kubota T, Hayashi M, Yamamoto S: Primary intracranial mesenchymal chondrosarcoma. A case report with review of the literature. *Neurosurgery* 10: 105-110, 1982
17. Lichtenstein L, Bernstein D: Unusual benign and malignant chondroid tumors of bone. *Cancer* 12: 1142-1157, 1959
18. Lynch PG, Uriburu E: An intracranial cartilage-containing meningeal tumor: Case report. *J Neurosurg* 39:261-264, 1973
19. Nakashima Y, Unni KK, Shives TC, Swee RG, Dahlin DC: Mesenchymal chondrosarcoma of bone and soft tissues. A review of 111 cases. *Cancer* 57 : 2444-2453, 1986
20. Nokes SR, Dauito R, Murtagh FR, Love LC, Arrington JA: Intracranial mesenchymal chondrosarcoma. *AJNR* 8: 1137-1138, 1987
21. Nozaki K, Nagata I, Takahashi JA, Hashimoto N: Intracranial mesenchymal chondrosarcoma associated with a left transverse sigmoid dural A-V fistula. *Acta Neurochir* 141:327-328, 1999
22. Raskind R, Grant S: Primary mesenchymal chondrosarcoma of the cerebrum: Report of a case. *J Neurosurg* 24: 676-678, 1966
23. Rollo JL, Green WR, Kahn LB: Primary meningeal mesenchymal chondrosarcoma. *Arch Pathol Lab Med* 103: 239-243, 1979
24. Rubinstein LJ: Sarcomas of the nervous system. Pathology of the nervous system, vol.2, J Minckler, Ed. Newyork, McGraw Hill, 1971, 2144-2164.
25. Salvador AH, Beabout JW, Dahlin DC: Mesenchymal chondrosarcoma. Observations on 30 new cases. *Cancer* 28: 605-615, 1971
26. Scheithauer BW, Rubinstein LJ: Meningeal mesenchymal chondrosarcoma. Report of 8 cases with review of the literature. *Cancer* 42 : 2744-2752, 1978
27. Schut L, Canady AI, Sutton LN, Bruce DA: Meningeal tumors in children. *Concepts Pediatr Neurosurg* 4:335-337, 1983
28. Seth HN, Singh M: Intracranial mesenchymal chondrosarcoma. *Acta Neuropathol* 24:86-89, 1973
29. Sugiyama K; Hirano A; Liens JF; Goodrich JT; Uozumi T; Kurisu K; Harada K Mesenchymal chondrosarcoma in anterior skull base: case report. *Noshuyo Byori*, 13(1):57-60 1996 Apr
30. Waga S, Matsushima M, Ando K, Morii S: Intracranial chondrosarcoma with extracranial metastasis. *J Neurosurg* 36: 790-794, 1972
31. Wu WQ, Lappi A: Primary non-skelatal intracartilagenous neoplasms: Report of a chondroma and a mesenchymal chondrosarcoma. *J Neurol Neurosurg Psychiatry* 33: 469-475, 1970
32. Zucker DK, Horoupian DS: Dural mesenchymal chondrosarcoma. *J Neurosurg* 48:829-833, 1978