

Functional Recovery of the Injured Optic Chiasma after Omental Transplantation

Hasarlı Optik Kiazmanın Omestal Transplantasyon Sonrası Fonksiyonel Düzelmeleri

HERNANDO RAFAEL, PEDRO MOROMIZATO, MAXIMINO ESPINOZA, VERÓNICA TALAVERA,

Department of Neurosurgery (HR), Universidad Nacional Autónoma de México (UNAM). Mexico city. México.
Department of General Surgery (PM) and Anesthesiology (ME), Instituto Mexicano del Seguro Social (IMSS). Mexico city.
México Department of Ophthalmology (VT), Organización Peruana de Lucha contra la Ceguera (OPELUCE). Lima, Perú.

Abstract: The authors describe a woman with visual loss and epilepsy that were caused by removal of a meningioma on the right sphenoidal ridge in an operation 5 years prior to presentation. The patient started to improve neurologically after omental transplantation to the injured optic chiasma and right temporal lobe. The epileptic seizures virtually disappeared after this surgery, and vision gradually improved over 3 months. These results indicate that placing omentum directly on injured nervous tissue can lead to neurological improvement.

Key Words: Epilepsy, omentum, omental transplantation, optic chiasma, visual loss

Özet: Yazarlar bu makalede 5 yıl önce sağ sfenoid kanat meningioması nedeniyle ameliyat edilen, görme kaybı ve epilepsi nedeniyle başvuran bir kadın hastayı sunmuşlardır. Hasta, hasarlı optik kiazma ve sağ temporal loba yapılan omental transplantasyon sonrası nörolojik olarak düzelmeye başlamıştır. Epileptik nöbetler cerrahiden hemen sonra kaybolmuş ve görme de 3 ay içinde tedricen düzelmiştir. Bu sonuçlar, hasarlı sinir dokusuna doğrudan yerleştirilen omentumun nörolojik düzelme sağladığını desteklemiştir.

Anahtar Kelimeler: Epilepsi, görme kaybı, omentum, omental transplantasyon, optik kiazma

INTRODUCTION

Many different lesions can cause chiasmal compression (16,24), including pituitary adenoma, suprasellar meningioma, basal leptomeningitis, craniopharyngioma, aneurysm, intrasellar cysticercosis, chordoma, and metastases. In addition, the chiasma and optic nerves can be damaged by ischemia (5,23) and trauma (12). However, aside from rehabilitation, to date there is no specific treatment

aimed at improving the function of the chiasma and optic nerves after chronic injury. We report the unusual case of a young woman with visual loss and epilepsy caused by ischemia of the optic chiasma. The injury occurred during removal of a meningioma in the right sphenoidal ridge. Five years after this surgery, the patient underwent omental transplantation to the affected region, and our results suggest that the omentum improved the function of the residual nervous tissue in the visual pathway.

CASE REPORT

A 30-year-old right-handed woman from Lima, Peru was admitted for surgery. In February 1990, she presented with headache and complex partial seizures evolving to tonic-clonic generalized seizures. Despite these problems, the patient's motor and visual functions were normal. On May 22, 1990 the woman underwent surgery via a pterional approach to remove a meningioma in the medial portion of the right sphenoidal ridge. She was extubated the morning after the operation, and manifested binocular blindness at that time. Two months postsurgery, the patient began to experience two or three partial seizures per month and one tonic-clonic generalized seizure every 3 months. On admission, the patient was taking daily doses of 600 mg carbamazepine and 200 mg diphenylhydantoin.

Examination:

On physical examination, the patient's appearance was appropriate for her age and she was lucid. The ocular fundi revealed optic atrophy of the papillae, loss of retinal nerve fibers, and macular pigment epitheliopathy. She exhibited blindness and absence of a pupillary light response in her right eye. In the left eye, her visual acuity and visual field (Fig. 1A) were reduced to distinguishing shades at a distance of 30 cm, she was unable to identify colors, and she lacked the ability for central fixing. The remainder of the neurological examination was normal. Magnetic resonance imaging (MRI) scans demonstrated an infarct and a cystic formation in the

right temporal pole (Fig. 2A). The visual evoked response (VER) revealed absence of waves in the right eye, and P100 waves with poor amplitude and latency of 152.3 ms in the left eye. An electroretinogram (ERG) showed absence of waves in the right eye, and "a" waves with low amplitude and latency of 37.6 ms, as well as absence of "b" waves.

Surgery:

Omental transplantation was performed on February 15, 1995 without complication. We opted to expose the chiasmatic region through the same right pterional approach that had been used previously. The surgical findings were as follows: 1) multiple adhesions between the dura mater and right temporal lobe; 2) infarct and cyst in the temporal pole; 3) hypotrophy of the chiasma and both optic nerves (left optic nerve reduced to 80% and right optic nerve to 50%); 4) marked pallor of the chiasma; 5) chiasma in normal position; 6) right ophthalmic artery of normal caliber; and 7) marked decrease in blood vessels on the dorsal surface of the chiasma.

The neurosurgical procedures for the omental transplantation were carried out according to the technique we described in earlier reports (19,20). Briefly, an end to-end anastomosis by invagination between occipital vessels and the gastroepiploic vessels were performed. Afterwards, a small segment of omentum was passed between the right optic nerve and the ophthalmic artery, and placed above the prechiasmatic space and chiasma. Another omental

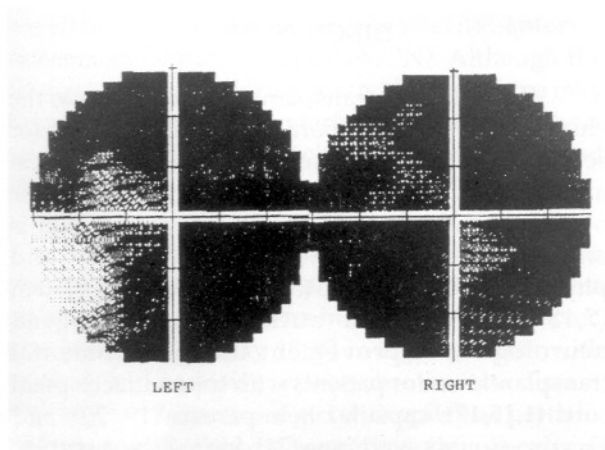


Figure 1a: Preoperative Humphrey automated perimetry (November 2, 1994) showing loss of fixing and a small area of paracentral vision between 5 and 10 degrees in the left eye. Poor isles of vision in the right eye.

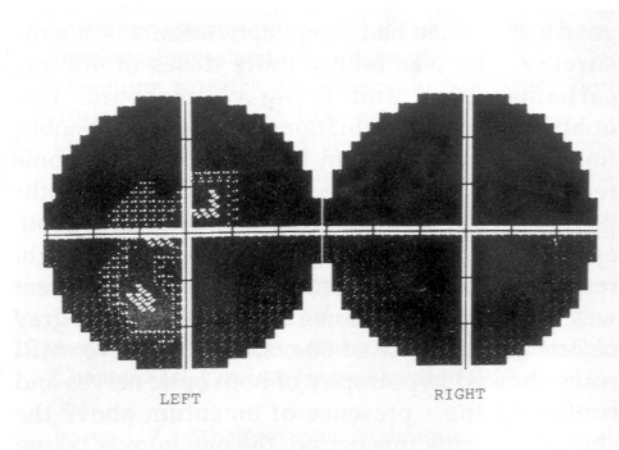


Figure 1b: Humphrey automated perimetry 12 months postoperatively, showing vision subnormal, low threshold, and best fixing in the left eye. The vision is subnormal and low threshold in the right eye.

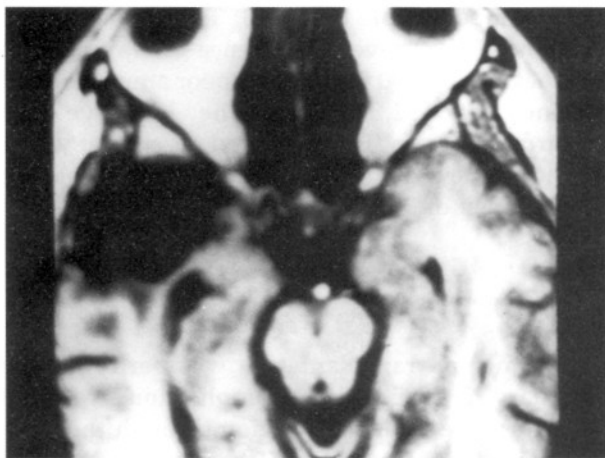


Figure 2a: MRI scans done before surgery showing an infarct and a cyst in the right temporal pole.

segment was placed into the cyst cavity and spread over the lateral surface of the damaged temporal lobe. Finally, the surgical wound was closed in standard fashion.

Postoperative Course:

Two days after surgery, the patient had photophobia, headache, and left facial paresis. She was able to walk with assistance, and day 2 postoperative computed tomography (CT) scans confirmed the presence of omentum above ("covering" or "over") the chiasma, temporal fossa, and right orbital lobe (Fig. 2B), as well as revascularization of the underlying brain tissue.

Three months later, the patient's condition was good and she had had no epileptic seizures since the surgery. She was taking daily doses of 400 mg carbamazepine and 2 mg clonazepam. Her ophthalmologic examination revealed photophobia, finger-counting to 50 cm in the left eye, and some reactivity to light in the right pupil. At 8 months postsurgery, there was visual improvement in both eyes, and her direct and consensual pupillary light responses were intact. Using her left eye, the patient was able to identify some white, black, and gray objects at a distance of 60 cm. Postoperative MRI scans showed hypotrophy of both optic nerves and confirmed the presence of omentum above the chiasma. During this period, the patient was taking only a nightly dose of 3 mg clonazepam. The last automated perimetry (January 23, 1996) showed fixation and increase of some threshold in the left eye (Fig. 1B). Furthermore, VEP testing showed P100 waves with poor amplitude and latency of 192.7 ms

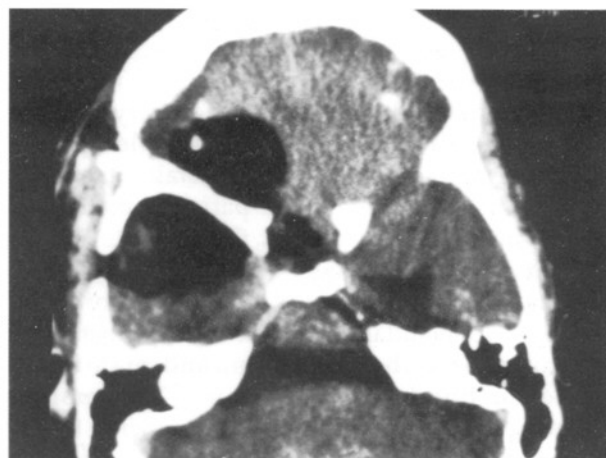


Figure 2b: Postoperative CT scans without contrast done 2 weeks after surgery, showing the presence of omentum in the chiasmatic region and right orbital gyri. At the right temporal fossa the image is mixed, illustrating the infarct, cyst, and omentum.

in the right eye, and distorted, low amplitude P100 waves with a latency of 125.6 ms in the left.

At present, 26 months after omental transplantation, the patient's findings are as follows: pupillary light response intact and can distinguish shades at a distance of 20 cm with the right eye; able to write numbers and recognize the shape and size of objects at a distance of 100 cm with the left eye. As well, she occasionally recognizes the color blue. The patient's condition is good, she is having no epileptic seizures, and is taking 3 mg clonazepam nightly.

DISCUSSION

We decided to transplant omental tissue to the chiasma and right temporal lobe of our patient for several reasons. First, based on the patient's clinical and neuroophthalmological findings. Second, the optic nerve is a fasciculus of white matter that is embryologically, morphologically, and physiologically similar to the central nervous system (7,18). Third, other authors have achieved neurological improvement using the omental transplantation for patients with traumatized spinal cord (1,15,17), capsular hemiparesis (19, 20), and Dejerine-Roussy syndrome (21) due to lacunar stroke. We chose the omentum because it is the best tissue for developing vascular connections with the cerebral and cerebellar cortex, and with the spinal cord and cauda equina (1,15,20). Additionally, omental tissue releases neurotransmitters and neurotrophic factors

that are transported to the underlying nervous tissue through the penetrating omental neovessels (4).

We believe that the patient's visual improvement was primarily due, initially to the revascularization of residual vital axons in the ischemic regions and ischemic penumbra in the chiasma and optic nerves, and in the right temporal loop of visual radiation. Based on the fact that experimental (3,6,10) and clinical (15,17,20) findings have proven there is a direct relationship between revascularization and recovery of demyelinated and/or degenerated axons, we also attribute her improvement to functional recovery of other axons in different stages of demyelination and degeneration. In addition, the visual improvement suggests functional recovery of some optic fibers from the retina up to the level of the lateral geniculate nuclei, as well as the presence of geniculocalcarine axons in the right Flechsig-Meyer loop (7,18). Evidence of this is the direct light response in the patient's right pupil, as well as the improvement in visual acuity and visual field in her left eye.

These preliminary results demonstrate that there are axons in the injured optic pathway that can recover if circulation is regained. They also confirm previous experience (1,17,25) that large numbers of axons can be remyelinated or regenerated under selected conditions (3,6,10). Therefore, contrary to the opinions of other authors (2,8,11), we believe that the revascularization of the injured chiasma should be attempted even years after the damage has occurred. We also believe that omental transplantation may be beneficial in patients with nonarteritic anterior ischemic optic neuropathy (NAION). Although the etiology of NAION is unknown, this technique may help revascularize the anterior optic nerve in these cases since ischemic optic neuropathy is involved (23).

Moreover, our patient's case confirms that the placement of omental tissue on the epileptic focus aborts seizures. It does so in the manner observed previously (since May 1988) in eight patients with epilepsy and occlusive type cerebrovascular disease (20), and in a 10-year-old girl with epilepsy partialis continua (13). We believe that this excellent improvement in seizure status is due to revascularization of the epileptogenic foci in the temporal lobe, which are characterized by loss of neurons, astrocytic gliosis, loss of GABAergic axon terminals, and severe hypoxia/ischemia (9,14,22).

Similar histopathologic changes have been noted in lacunar stroke of cerebrovascular disease (20). Therefore, increasing the flow of blood, oxygen, and neurotrophic factors to the damaged hippocampal formation, and improving the function of neurons in chronic ischemia reduce the excessive excitability of the dendrites and favor neuronal regeneration. In conclusion, our patient's recovery from binocular blindness and seizures shows that placing omental tissue directly on epileptogenic foci and injured optic chiasma tissue produces significant neurological improvement.

Correspondence: Hernando Rafael
Belgica 411-Bis,
Colonia Portales,
03300 Mexico City,
MEXICO
Telephone: (525) 532-91-01
Fax: (525) 539-50-83

REFERENCES

1. Abraham J, Paterson A, Bothra M, Mofti AB, Taylor GW: Omento-myelo-synangiosis in the management of chronic traumatic paraplegia. Case report. *Paraplegia* 25: 44 - 49, 1987
2. Anderson DR: Ascending and descending optic atrophy produced experimentally in squirrel monkey. *Am J Ophthalmol* 76: 693 - 711, 1973
3. Aubert I, Ridet JL, Gage FH: Regeneration in the adult mammalian CNS: Guided by development. *Curr Opin Neurobiol* 5: 625 - 635, 1995
4. Berger MS, Weinstein PR, Goldsmith HS, Hattner R, Longa EZ, Perira B: Omental transposition to bypass the blood-brain barrier for delivery of chemotherapeutic agents to malignant brain tumors: preclinical investigation. Goldsmith HS (ed). In, *The omentum: research and clinical applications*. New York: Springer-Verlag 1990, pp 117-129
5. Dawson BH: The blood vessels of the human optic chiasma and their relation to those of the hypophysis and hypothalamus. *Brain* 81: 207-217, 1958
6. De la Torre JC, Goldsmith HS: Increased blood flow enhances axon regeneration after spinal transection. *Neurosci Lett* 94: 269-273, 1988
7. Duke-Elder S: *Textbook of ophthalmology*. Vol IV: The neurology of visual motor and optical anomalies. Chapter XLII. London: Henry Kimpton 1949, pp 3473-3617
8. Frisen L: Ophthalmoscopic evaluation of the retinal nerve fiber layer in neuro-ophthalmologic disease. Smith JL (ed). In, *Neuro-ophthalmology focus 1980*. New York: Masson Publ, USA Inc 1979, pp 53-67
9. Grunthal E: Ammon's horn. Minckler J (ed). In, *Pathology of the nerve system*. Vol 1. New York: McGraw-Hill Book Co 1968, pp 707-711.

10. Hopkins J, Bunge RO: Regeneration of axons from adult human retina in vitro. *Exp Neurol* 112: 243-251, 1991
11. Lundstrom M, Frisen L: Evolution of descending optic atrophy. *Acta Ophthalmol* 53: 738-746, 1975
12. Mahapatra AK, Tandon DA: Prospective study of 360 patients with optic nerve injury. Presented at the Xth International Congress of Neurological surgery. Acapulco, Mexico. October 17-22, 1993: 323
13. May Ch, Vogel IS: Epilepsia partialis continua successfully treated by transplantation of omentum. Case report. Presented at the First International Congress of Omentum in CNS. Xuzhou, China. May 7-11, 1995: 34
14. Miller LA, Muñoz DG, Finmore M: Hippocampal sclerosis and human memory. *Arch Neurol* 50: 391-394, 1993
15. Nagashima Ch, Masumori Y, Hori E, Kubota S, Kawanuma S, Shimada Y, Iwasaki T, Heshiki A, Mizuno H: Omentum transplantation to the cervical cord with microangioanastomosis. *No Shinkei Geka (Japan)* 19 (4): 309-318, 1991
16. Rafael H, Gómez-Llata S: Intracellar cysticercosis. Case report. *J Neurosurg* 63: 975-976, 1985
17. Rafael H, Malpica A, Espinoza M, Moromizato P: Omental transplantation in the management of chronic traumatic paraplegia. Case report. *Acta Neurochir (Wien)* 114: 145-146, 1992.
18. Rafael H: Nervios craneanos. Segunda edición. Capítulo 2. México, DF: Editorial Prado 1995, pp 13-47
19. Rafael H: Omental transplantation to the insular cortex. Presented at the First International Congress of Omentum in CNS. Xuzhou, China. May 7-11, 1995: 28-30
20. Rafael H: El epiplón: Trasplante al sistema nervioso. Capítulo 8. México, DF: Editorial Prado 1996, pp 79-91
21. Rafael H, Elera H, Ortiz A, Moromizato P, Espinoza M: Trasplante de epiplón y dolor central reversible. *An Fac Med UNMSM (Perú)*: In press
22. RibakChE, Harris AB, Vaughn JE, Robert SE: Inhibitory GABAergic nerve terminals decrease at sites of focal epilepsy. *Sciences* 205: 211-214, 1979
23. The ischemic optic neuropathy decompression trial research group. Optic nerve decompression surgery for nonarteritic anterior ischemic optic neuropathy (NAION) is not effective and may be harmful. *JAMA* 273 (8): 625-632, 1995
24. Walsh MLS: Surgical management of chiasmal compression. *Proc Roy Soc Med* 70: 317-319, 1977
25. Waxman SG: Demyelination in spinal cord injury. *J Neurol Sci* 91: 1-14, 1989