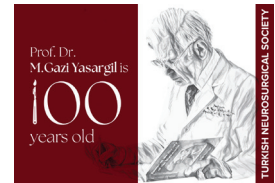




Received: 17.02.2024

Accepted: 02.09.2024

Published Online: 30.04.2025



The Impact of Atlantoaxial Intra-Articular Fusion on Cervical Spine Curvature and Sagittal Balance

Ji WU^{1*}, Yang LI^{1,2*}, Xiaolin LI^{1*}, Fei CHEN¹, Zhenji XU¹, Yiyang DING¹, Bin NI^{1**}, Xuhua LU^{1**}, Qunfeng GUO^{1**}¹Naval Medical University, Shanghai Changzheng Hospital, Department of Orthopedics, Shanghai, People's Republic of China²University of Shanghai for Science and Technology, School of Health Science and Engineering, People's Republic of China

*Ji Wu, Yang Li and Xiaolin Li contributed equally to this work.

**Bin Ni, Xuhua Lu and Qunfeng Guo contributed equally to this work.

Corresponding author: Qunfeng GUO ✉ guoqunfeng83@163.com

ABSTRACT




AIM: To investigate whether atlantoaxial intra-articular fusion (AIF) can maintain sagittal balance stability in the cervical spine during follow-up.**MATERIAL and METHODS:** The data of 39 patients with anterior atlantoaxial dislocation who underwent AIF and 21 patients who underwent structural bone grafting (SBG) fusion were retrospectively reviewed. Radiographic variables, including T1 slope (T1S), C1–C2 angle, C2–C7 angle, C2–C7 sagittal vertical axis (SVA), and lateral atlantoaxial joint space height (LAAJSH), were measured preoperatively, postoperatively, and at the last follow-up. Analyzing the differences in cervical spine curvature and sagittal balance during the preoperative, postoperative, and follow-up periods, as well as identifying the influencing factors.**RESULTS:** In the AIF Group, compared to the preoperative measurements, there was a statistically significant increase in both the C1–C2 angle ($p < 0.001$) and LAAJSH ($p < 0.001$) at the final follow-up, while a significant decrease was observed in the C2–C7 angle ($p < 0.001$). At the final follow-up, there was a decrease in LAAJSH compared to immediately post-surgery ($p < 0.001$), but there were no significant changes in the C1–C2 angle ($p = 0.366$), C2–C7 angle ($p = 0.502$), T1S ($p = 0.082$) and C2–C7 SVA ($p = 0.209$).**CONCLUSION:** Posterior AIF technique can effectively reconstruct the alignment of the atlantoaxial complex and avoid secondary imbalance and loss of lordosis of the subaxial cervical spine.**KEYWORDS:** Atlantoaxial intra-articular fusion, Atlantoaxial dislocation, Cervical sagittal balance, Cervical spine curvature




INTRODUCTION




In recent decades, posterior C1–C2 segmental fixation and fusion have been widely utilized in the treatment of atlantoaxial dislocation (6). It can achieve open reduction and achieve high fusion rate combined with posterior C1–C2 structural bone grafting (SBG) fusion (2,7,11). However, some patients experience loss of lordosis in the subaxial cervical spine and cervical imbalance following atlantoaxial posterior fusion surgery. Currently, it is believed that fixing the atlantoaxial joint excessively in a lordotic position is a

significant factor leading to the loss of cervical lordosis and imbalance in the cervical spine (14,21,24,25).

Previous cases of subaxial cervical lordosis loss have mainly been treated with posterior compression bone grafting or surface bone grafting. Both techniques, especially posterior compression bone grafting, tend to excessively fix the atlantoaxial joint in a lordotic position (14,21,24,25). In recent years, the atlantoaxial intra-articular fusion (AIF) technique has gradually been introduced into clinical practice. This technique effectively restores the height of the lateral atlantoaxial joint

Ji WU  : 0000-0002-8483-7208
Yang LI  : 0009-0003-9905-1712
Xiaolin LI  : 0009-0009-6545-260X

Fei CHEN  : 0009-0007-0478-7241
Zhenji XU  : 0009-0005-0680-5680
Yiyang DING  : 0009-0007-7819-7156

Bin NI  : 0000-0003-0522-5869
Xuhua LU  : 0000-0002-8400-8960
Qunfeng GUO  : 0000-0003-2510-6197



This work is licensed by "Creative Commons Attribution-NonCommercial-4.0 International (CC)".

space, theoretically allowing for the restoration of tension in the atlantoaxial ligamentous complex. This can result in fixing the atlantoaxial joint in a more anatomically normal position, thereby avoiding fixation in an excessively lordotic position (3,5,6).

However, there is a lack of relevant research on whether the AIF technique leads to the loss of subaxial cervical lordosis or sagittal imbalance. Therefore, this study aimed to evaluate whether AIF can maintain sagittal balance stability in the cervical spine during follow-up by retrospectively comparing the outcomes of cases undergoing AIF and SBG.

■ MATERIAL and METHODS

Study Design

This study retrospectively reviewed the data of 39 patients with anterior atlantoaxial dislocation who underwent AIF between June 2018 and June 2019 and a control group of 21 patients treated with SBG. Ethics committee approval was obtained from Naval Medical University/Second Military Medical University (20.02.2017; No: 81772380). Informed consent was obtained from all patients.

General Information and Criteria for Patient Inclusion and Exclusion

This study included patients diagnosed with reducible atlantoaxial dislocation, who subsequently underwent posterior atlantoaxial segmental fixation and AIF or SBG. In order to eliminate the potential influence of the direction of atlantoaxial dislocation, patients with anterior atlantoaxial dislocation were specifically selected for this study. Patients with the following conditions were excluded from this study: 1) Irreducible atlantoaxial dislocation; 2) Congenital occipitocervical malformation; 3) Atlantoaxial dislocation caused by tumors or inflammatory diseases; 4) Severe osteoporosis; 5) The patients who were followed up for less than 12 months.

Surgery Methods

Under general anesthesia, the patient was placed in a prone position on a plaster table, with cranial traction applied to maintain stability. A midline posterior incision was made to expose the spinous process and lamina of the axis, as well as the posterior arch of the atlas. Bilateral C1 lateral mass-C2 pedicle screws were then inserted. For the AIF Group, the C2 nerve root and the surrounding venous plexus were gently displaced towards C1 along the C2 isthmus for protection. Use an anatomical dissector to disrupt the posterior capsule of the joint by inserting it into the joint. Then, expanders of different sizes were sequentially used to further release the joint space. Connect C1 and C2 screws on both sides with a longitudinal rod to achieve atlantoaxial reduction. After removing the articular cartilage using a small endplate scraper or spatula, the joint gap height was retested using a spreader. Based on the size of the joint gap, choose a cage with height of 5mm. The cage which contains autogenous bone from the C1 posterior arch and C2 lamina was inserted into the joint. After placing cages on both sides, cranial traction was removed,

and the screws were finally secured. For the SBG Group, the autologous iliac bone block which was slightly larger than the distance between the posterior arch of the atlas and the posterior arch of the axis was inserted and secured between the posterior arch of the atlas and the vertebral lamina of the axis after longitudinally compressing the screw-rod system (3).

Clinical Outcome Assessment

Visual analog scale score for neck pain (VASSNP) and Japanese Orthopedic Association (JOA) scores were evaluated before operation and at follow-up interval.

Assessment of Radiographic Variables

A Cervical X-ray, computed tomography (CT) scan and three-dimensional reconstruction were performed preoperatively, immediately postoperatively, and at regular postoperative follow-up visits (3,6, and 12 months and yearly thereafter). Standard lateral cervical radiographs were taken with the patient in a standing position with both knees locked and looking straight ahead. The criterion for atlantoaxial facet bone fusion was established based on the CT scans: trabeculae bridging the neighboring articular surfaces of the facets within the facet joint space. The lateral atlantoaxial joint space height (LAAJSH) was measured using the CT coronal reconstructions (13). The T1 slope (T1S), C1–C2 angle, C2–C7 angle, and C2–C7 sagittal vertical axis (SVA) were measured on a lateral radiograph in the neutral position (Figure 1). The T1S was defined as the angle formed by a horizontal line and the superior endplate of T1. The C1–C2 angle was defined as the angle between the inferior aspects of the atlas and the axis. The C2–C7 angle was defined as the angle between the inferior aspect of the axis and C7. The C2–C7 SVA was defined as the distance between a plumb line from the center of C2 and the posterior superior corner of C7. These measurements were taken preoperatively, immediately postoperative, and at the final follow-up visit. The differences between the final follow-up and preoperative measurements were calculated and recorded as follows: changes in the C1–C2 angle ($\Delta^1\text{C1–C2 angle}$), changes in the C2–C7 angle ($\Delta^1\text{C2–C7 angle}$), changes in the C2–C7 SVA ($\Delta^1\text{C2–C7 SVA}$), and changes in the LAAJSH ($\Delta^1\text{LAAJSH}$). The differences between the final follow-up and immediate postoperative measurements were calculated and recorded as follows: $\Delta^2\text{C1–C2 angle}$, $\Delta^2\text{C2–C7 angle}$, $\Delta^2\text{C2–C7 SVA}$ and $\Delta^2\text{LAAJSH}$.

Three experienced orthopedists who were not involved in the surgeries took these measurements three times, and their means were recorded. The clinical outcomes and imaging data of the two cohorts were compared.

Statistical Analyses

Data are expressed as the mean \pm standard deviation. Statistical analysis was performed using independent samples t-test, paired t-test, and Pearson's correlation coefficient (*r*). A $p < 0.05$ was considered statistically significant. The analyses were conducted using SPSS Version 26.0 (SPSS Inc., Chicago, Illinois, USA).

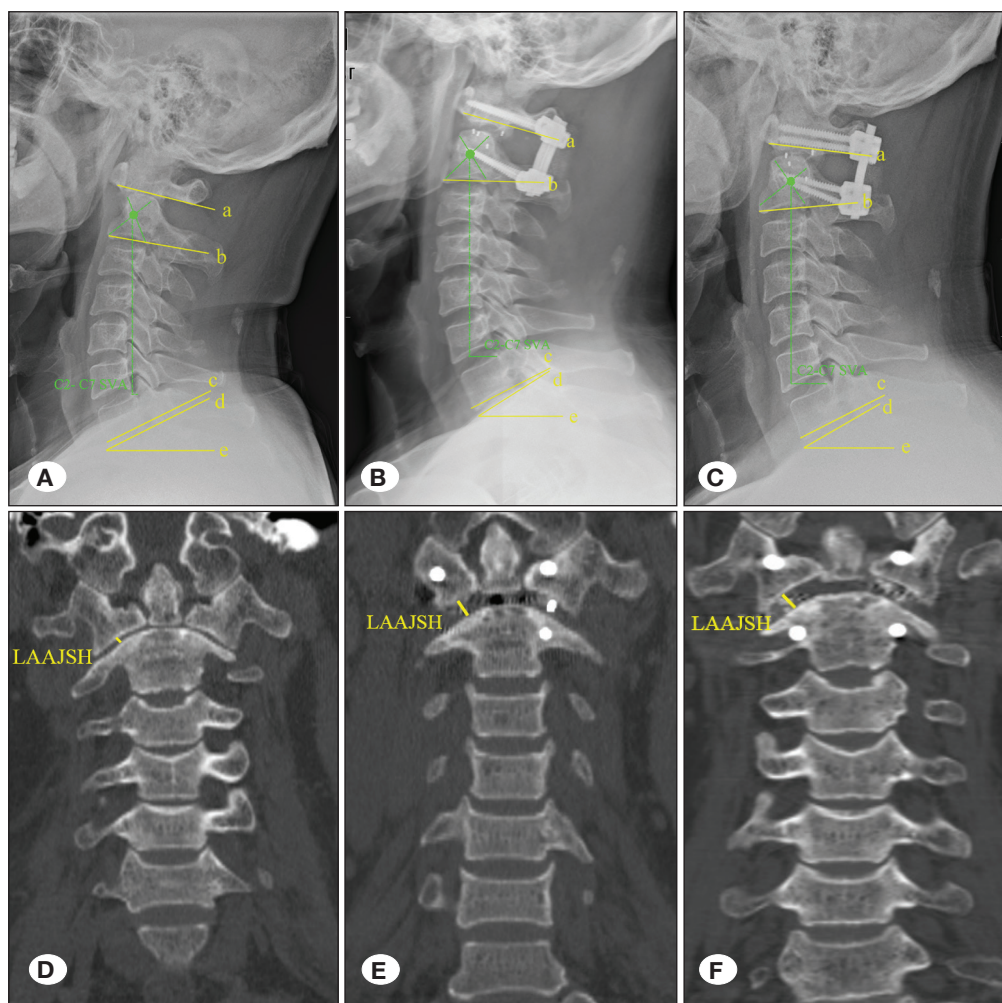


Figure 1: The C1–C2 angle is formed by the inferior aspects of the atlas and axis (lines a and b), and the C2–C7 angle by the inferior aspects of the axis and C7 (lines b and c). The T1S is the angle between the superior end plate of T1 (line d) and a horizontal line (line e); C2–C7 SVA was defined as the distance between a plumb line from the center of C2 and the posterior superior corner of C7; LAAJSH was measured on CT coronal reconstructions. In a patient with an old odontoid process fracture, lateral X-rays of the cervical spine were taken preoperatively (A), immediately postoperatively (B), and at the last follow-up (C). The postoperative images demonstrate an increase in the C1–C2 angle and a decrease in the C2–C7 angle compared to preoperative measurements. However, there was no statistically significant difference in cervical curvature observed at the last follow-up compared to the immediate postoperative measurements. In the same patient with an old odontoid process fracture, coronal reconstructions from CT scans were obtained preoperatively (D), immediately postoperatively (E), and at the last follow-up (F). Both immediately postoperatively and at the last follow-up, the LAAJSH exhibited a significant increase compared to preoperative values.

RESULTS

General Information

The general information of the patients is summarized in Table I. All patients underwent surgery successfully without any injuries to the vertebral artery or nerves and completed follow-up assessments postoperatively. The average VASSNP score decreased in both groups, while the JOA score showed improvement ($p < 0.05$).

Preoperative and Postoperative Differences in Radiographic Variables

In the AIF Group, compared to the preoperative measurements,

there was a statistically significant increase in both the C1–C2 angle ($p < 0.001$) and LAAJSH ($p < 0.001$) at the final follow-up, while a significant decrease was observed in the C2–C7 angle ($p < 0.001$). The T1S ($p = 0.560$) and C2–C7 SVA ($p = 0.900$) did not change significantly from preoperative to the final follow-up. At the final follow-up, there was a decrease in LAAJSH compared to immediately post-surgery ($p < 0.001$), but there were no significant changes in the C1–C2 angle ($p = 0.366$), C2–C7 angle ($p = 0.502$), T1S ($p = 0.082$) and C2–C7 SVA ($p = 0.209$) (Table II).

In the SBG Group, a statistically significant increase in the C1–C2 angle ($p < 0.001$) and a significant decrease in the C2–C7 angle were observed at both immediate post-surgery

and final follow-up assessments compared to preoperative measurements ($p<0.05$). The T1S, C2–C7 SVA, and LAAJSH showed no statistically significant differences across the three measurement time points ($p>0.05$) (Table II).

Table I: Patient' General Information.

Variable	AIF Group	SBG Group
Age at operation (years)	45.6 \pm 22.8	45.3 \pm 19.2
Sex (numbers of patients)		
Male	12	6
Female	27	15
Etiology (number of patients)	39	21
Odontoid fracture	7	5
Os odontoideum	22	13
Ligamentous lesion	10	3
Surgery time (min)	114.2 \pm 7.9	115.0 \pm 10.5
Blood loss (ml)	206.4 \pm 25.2	211.2 \pm 28.7
Bone fusion time (mo)	4.8 \pm 1.2	5.0 \pm 1.4
Average follow-up time (mo)	45.6 \pm 4.4	41.9 \pm 11.1
JOA score*		
Preoperative	7.0 \pm 1.3	7.3 \pm 2.1
Final follow-up	14.8 \pm 2.1	14.2 \pm 2.3
VASSNP*		
Preoperative	4.5 \pm 1.6	4.0 \pm 1.5
Final follow-up	1.7 \pm 0.7	1.6 \pm 1.0
Δ^1 C1–C2 angle (°)	13.5 \pm 9.3	11.3 \pm 9.2
Δ^1 C2–C7 angle (°)	-7.5 \pm 9.9	-6.4 \pm 10.8
Δ^1 C2–C7 SVA (cm)	-0.3 \pm 3.0	1.5 \pm 4.2
Δ^1 LAAJSH (mm) ^a	3.0 \pm 0.7	0.1 \pm 0.7
Δ^2 C1–C2 angle (°)	-0.3 \pm 1.8	-0.1 \pm 3.2
Δ^2 C2–C7 angle (°)	-0.4 \pm 4.1	-1.7 \pm 5.9
Δ^2 C2–C7 SVA (cm)	-0.2 \pm 0.9	0.7 \pm 3.7
Δ^2 LAAJSH (mm)	-0.4 \pm 0.4	-0.2 \pm 0.6

Data expressed as mean \pm standard deviation unless otherwise indicated. JOA score, Japanese Orthopedic Association score; VASSNP, visual analog scale score for neck pain; Pre. indicates preoperative; Δ^1 , the differences between the final follow-up and preoperative measurements; Δ^2 , the differences between the final follow-up and immediately postoperative measurements.

* $p<0.05$, paired t-test, values at final follow-up compared to preoperative values in two groups.

^a $p<0.05$, independent samples t-test, values at final follow-up compared to preoperative values in two groups.

The C1–C2 angle, C2–C7 angle, T1S, and C2–C7 SVA measurements exhibited no statistically significant differences between the two groups at the three time points ($p>0.05$). Preoperatively, there was no significant disparity in LAAJSH between the two groups ($p>0.05$); however, postoperatively and at the final follow-up assessment, the AIF group consistently demonstrated a significantly greater LAAJSH compared to the SBG group ($p<0.001$).

There were no statistically significant differences observed between the two groups in terms of changes from preoperative to final follow-up and from immediate postoperative to final follow-up regarding the C1–C2 angle, C2–C7 angle, and C2–C7 SVA ($p>0.05$). The Δ^1 LAAJSH of the AIF group was significantly greater than that of the SBG group ($p<0.001$), while there was no significant difference in the Δ^2 LAAJSH ($p=0.173$).

Relationships Between Radiographic Variables in the AIF Group

The C2–C7 angle was positively correlated with T1S both postoperatively ($r = 0.847$, $p<0.001$) and at the final follow-up ($r = 0.876$, $p<0.001$). The C2–C7 SVA was positively correlated with C1–C2 angle ($r = 0.515$, $p=0.001$), T1S ($r = 0.426$, $p=0.007$), and LAAJSH ($r = 0.552$, $p<0.001$) at the final follow-up. The Δ^1 C1–C2 angle displayed a negative correlation with Δ^1 C2–C7 angle ($r = -0.726$, $p<0.001$).

DISCUSSION

Our study performed AIF surgery on 39 patients with anterior atlantoaxial dislocation. We also selected a control group comprising 21 patients who underwent SBG treatment. Through the measurement and comparison of radiographic and clinical outcomes obtained preoperatively, immediately postoperatively, and at the final follow-up, we observed that AIF can significantly improve patients' clinical symptoms, maintain the postoperative stability of the atlantoaxial joint, and preserve cervical sagittal balance and curvature.

The fusion angle of the C1–C2 is a crucial factor that influences changes in the curvature of the lower cervical spine (14,21,24,25). Numerous studies have documented the occurrence of cervical lordosis loss, straight alignment of the cervical spine, cervical kyphosis deformity or even swan neck deformity after posterior atlantoaxial fusion surgery (14,21,24,25). Changes in the C1–C2 angle typically result in compensatory adjustments in the subaxial cervical curvature, allowing for the maintenance of horizontal gaze. Fixing the atlantoaxial joint in an excessively anterior lordotic position significantly contributes to the loss of cervical lordosis (14,21,24,25). Toyama suggested an optimal C1–C2 fixation angle of approximately 20° to maintain postoperative cervical lordosis (20). In our study, the C1–C2 angle increased postoperatively while the C2–C7 angle decreased. In the AIF Group, the Δ^1 C1–C2 angle was significantly negatively correlated with the Δ^1 C2–C7 angle. However, the C2–C7 angle remained constant during follow-up, with no significant difference observed between immediately postoperative and the final follow-up. The good C2–C7 curve may be

Table II: Differences in Radiographic Variables Before and After Operation in AIF Group (n=39) and SBG Group (n=21)

Variables	Pre.	Post.	Fin.	Pre. vs Post. p-value	Pre. vs Fin. p-value	Post. vs Fin. p-value
C1–C2 angle(°)						
AIF ^{ab}	5.2 ± 10.0	18.9 ± 5.5	18.7 ± 6.1	<0.001	<0.001	0.366
SBG ^{ab}	6.8 ± 10.0	18.2 ± 4.3	18.1 ± 5.3	<0.001	<0.001	0.892
C2–C7 angle(°)						
AIF ^{ab}	18.9 ± 15.7	11.9 ± 10.9	11.4 ± 10.3	<0.001	<0.001	0.502
SBG ^{ab}	20.0 ± 11.6	15.2 ± 7.7	13.5 ± 7.3	0.030	0.013	0.198
T1S(°)						
AIF	24.3 ± 10.3	25.0 ± 6.6	23.8 ± 6.5	0.560	0.573	0.082
SBG	23.2 ± 7.7	25.1 ± 7.2	25.0 ± 5.2	0.184	0.181	0.950
LAAJSH(mm)						
AIF ^{abc}	2.0 ± 0.5	5.4 ± 0.7*	5.1 ± 0.5*	<0.001	<0.001	<0.001
SBG	2.1 ± 0.5	2.4 ± 0.6	2.2 ± 0.4	0.053	0.522	0.141
C2–C7 SVA(cm)						
AIF	1.9 ± 2.9	1.8 ± 1.1	1.6 ± 1.2	0.900	0.606	0.209
SBG	1.4 ± 1.4	2.1 ± 1.0	2.9 ± 3.9	0.093	0.131	0.390

Data expressed as mean ± standard deviation unless otherwise indicated. **Pre:** Indicates preoperative values, **Post:** indicates immediately postoperative values, **Fin:** indicates values at final follow-up

^ap<0.05, paired t-test, immediately postoperative values compared to preoperative values.

^bp<0.05, paired t-test, values at final follow-up compared to preoperative values.

^cp<0.05, paired t-test, values at final follow-up compared to immediately postoperative values.

^{*}p<0.05, independent samples t-test, AIF Group compared to SBG Group.

attributed to good reconstruction of the sagittal alignment of the atlantoaxial complex with the AIF technique. At the final follow-up, the LAAJSH in the AIF Group was significantly enlarged to 5.1 ± 0.5 mm from a preoperative value of 2.0 ± 0.5 mm, slightly larger than the mean of 3.0 ± 0.5 mm in the general population (13). The good reconstruction of the LAAJSH can restore the tension of the atlantoaxial complex, thereby avoiding fixing C1–C2 in an excessively lordotic position (5). Consequently, immediately after operation, the C1–C2 angle was improved to $18.9^\circ \pm 5.5^\circ$ from a preoperative value of $5.2^\circ \pm 10.0^\circ$, being closed to the recommended angle of 20° (20). The C2–C7 angle decreased to $11.9^\circ \pm 10.9^\circ$ from a preoperative value of $18.9^\circ \pm 15.7^\circ$, closely resembling the $13.9^\circ \pm 14.2^\circ$ reported by Yokoyama et al. (23) in asymptomatic individuals. The C2–C7 angle was well maintained during follow-up, with no significant difference observed between immediately postoperative and the final follow-up. Additionally, in comparison to the SBG group, we observed no significant differences in other radiographic parameters, with the exception of LAAJSH. Although the SBG group exhibited a more pronounced decrease in the C2–C7 angle from immediately postoperative to the final follow-up, there was no significant difference between two measurement time points. The good outcome may be attributed to the

iliac bone grafts utilized intraoperatively being slightly larger than the distance between the posterior arch of the atlas and the posterior arch of the axis, thereby effectively preventing excessive lordotic position of C1–C2 resulting from longitudinal compression of C1 and C2.

The C2–C7 SVA is a pivotal parameter for evaluating cervical sagittal balance and plays a significant prognostic role in postoperative outcomes (1,9,15,18,22). Imbalance in the sagittal plane can lead to increased muscular effort and energy expenditure and result in pain, fatigue, and disability (18,22). In asymptomatic individuals, Zhong et al. reported a C2–C7 SVA of 16.8 ± 11.2 mm (26), whereas Tang et al. and Scheer et al. found that the C2–C7 SVA in healthy populations was approximately 20 mm (16,18). At both immediate postoperative and final follow-up assessments, the C2–C7 SVA closely approximated the asymptomatic population. Previous studies have demonstrated that the C2–C7 angle and T1S are crucial parameters significantly influencing the C2–C7 SVA (8,12,17,27). However, some studies have demonstrated that the C2–C7 angle is not correlated with the C2–C7 SVA (1,10,19). In the AIF Group, the C2–C7 SVA was significantly positively correlated with the T1S, C1–C2 angle but not with the C2–C7 angle at the final follow-up. Additionally, whether

immediately after surgery or at the final follow-up, this study demonstrates a strong positive correlation between the C2–C7 angle and T1S. Therefore, good reconstruction of the LAAJSH and C1–C2 angle significantly impacts the postoperative preservation of C2–C7 SVA because the T1S is a constant (4). In our study, the LAAJSH and C1–C2 angle were well reconstructed using the AIF technique, ensuring the good outcomes evaluated by VASSNP and JOA.

There were limitations in our study. Firstly, it was retrospective with a small sample size. Secondly, only patients with anterior atlantoaxial dislocation were included in our study. The direction of the atlantoaxial complex may impact the alignment and balance of the subaxial cervical spine. Therefore, it is imperative to conduct larger-scale prospective studies encompassing various directions of atlantoaxial dislocation in order to derive more definitive conclusions.

CONCLUSION

Posterior AIF technique can effectively reconstruct the alignment of the atlantoaxial complex and avoid secondary imbalance and loss of lordosis of the subaxial cervical spine during follow-up.

Declarations

Funding: This study was supported by Naval Medical University Research Foundation (No: 2021MS14) and National Natural Science Foundation of China (No: 81772380).

Availability of data and materials: The datasets generated and/or analyzed during the current study are available from the corresponding author by reasonable request.

Disclosure: The authors declare no competing interests.

AUTHORSHIP CONTRIBUTION

Study conception and design: QG, XL

Data collection: FC, ZX, YD

Analysis and interpretation of results: XL, JW

Draft manuscript preparation: YL, JW

Critical revision of the article: JW, BN

Other (study supervision, fundings, materials, etc.): BN, QG

All authors (JW, YL, XL, FC, ZX, YD, BN, XL, QG) reviewed the results and approved the final version of the manuscript.

REFERENCES

- Cheng J, Liu P, Sun D, Ma Z, Liu JP, Wang ZL, Mou JH: Correlation of cervical and thoracic inlet sagittal parameters by MRI and radiography in patients with cervical spondylosis. *Medicine (Baltimore)* 98:e14393, 2019. <https://doi.org/10.1097/MD.00000000000014393>
- Coyne TJ, Fehlings MG, Wallace MC, Bernstein M, Tator CH: C1–C2 posterior cervical fusion: Long-term evaluation of results and efficacy. *Neurosurgery* 37:688–692, 1995. <https://doi.org/10.1227/00006123-199510000-00012>
- Guo Q, Chen F, Zhang M, Wang H, Guo X, Lu X, Ni B: Posterior reduction and intra-articular cage fusion with a C2 nerve root preservation technique for treating posterior atlantoaxial dislocation secondary to os odontoideum. *Oper Neurosurg (Hagerstown)* 25:365–371, 2023. <https://doi.org/10.1227/ons.0000000000000828>
- Guo Q, Deng Y, Wang J, Wang L, Lu X, Guo X, Ni B: Influence of the T1-slope on sagittal alignment of the subaxial cervical spine after posterior atlantoaxial fusion in os odontoideum. *Clin Neurol Neurosurg* 149:39–43, 2016. <https://doi.org/10.1016/j.clineuro.2016.07.025>
- Guo Q, Wu Y, Zhang M, Chen F, Wang H, Wu J, Lu X, Ni B: Sagittal reconstruction of the atlantoaxial lateral mass complex with an intra-articular cage fusion technique for degenerative atlantoaxial instability. *World Neurosurg* 175:e129–e133, 2023. <https://doi.org/10.1016/j.wneu.2023.03.039>
- Guo Q, Zhu J, Yang J, Chen F, Wu L, Zhou X, Ni B: Comparison of atlantoaxial intra-articular fusion and posterior structural bone grafting techniques for treating atlantoaxial dislocation. *Oper Neurosurg (Hagerstown)* 24:e10–e15, 2023. <https://doi.org/10.1227/ons.0000000000000455>
- Harms J, Melcher RP: Posterior C1–C2 fusion with polyaxial screw and rod fixation. *Spine (Phila Pa 1976)* 26:2467–2471, 2001. <https://doi.org/10.1097/00007632-200111150-00014>
- Hyun SJ, Han S, Kim KJ, Jahng TA, Kim HJ: Assessment of T1 slope minus cervical lordosis and C2–7 sagittal vertical axis criteria of a cervical spine deformity classification system using long-term follow-up data after multilevel posterior cervical fusion surgery. *Oper Neurosurg (Hagerstown)* 16:20–26, 2019. <https://doi.org/10.1093/ons/opy055>
- Hyun SJ, Kim KJ, Jahng TA, Kim HJ: Relationship between T1 slope and cervical alignment following multilevel posterior cervical fusion surgery: Impact of T1 slope minus cervical lordosis. *Spine (Phila Pa 1976)* 41:E396–402, 2016. <https://doi.org/10.1097/BRS.0000000000001264>
- Iyer S, Nemani VM, Nguyen J, Elysee J, Burapachaisri A, Ames CP, Kim HJ: Impact of cervical sagittal alignment parameters on neck disability. *Spine (Phila Pa 1976)* 41:371–377, 2016. <https://doi.org/10.1097/BRS.0000000000001221>
- Jeon SW, Jeong JH, Choi GH, Moon SM, Hwang HS, Choi SK: Clinical outcome of posterior fixation of the C1 lateral mass and C2 pedicle by polyaxial screw and rod. *Clin Neurol Neurosurg* 114:539–544, 2012. <https://doi.org/10.1016/j.clineuro.2011.11.001>
- Lee SH, Kim KT, Seo EM, Suk KS, Kwack YH, Son ES: The influence of thoracic inlet alignment on the craniocervical sagittal balance in asymptomatic adults. *J Spinal Disord Tech* 25:E41–E47, 2012. <https://doi.org/10.1097/BSD.0b013e3182396301>
- Li S, Ni B, Xie N, Wang M, Guo X, Zhang F, Wang J, Zhao W: Biomechanical evaluation of an atlantoaxial lateral mass fusion cage with C1–C2 pedicle fixation. *Spine (Phila Pa 1976)* 35:E624–632, 2010. <https://doi.org/10.1097/BRS.0b013e3181cf412b>
- Mukai Y, Hosono N, Sakaura H, Fujii R, Iwasaki M, Fuchiya T, Fujiwara K, Fuji T, Yoshikawa H: Sagittal alignment of the subaxial cervical spine after C1–C2 transarticular screw fixation in rheumatoid arthritis. *J Spinal Disord Tech* 20:436–441, 2007. <https://doi.org/10.1097/bsd.0b013e318030ca3b>

15. Qiao J, Zhu F, Liu Z, Xu L, Zhu Z, Qian B, Sun X, Jiang Q, Qiu Y: Measurement of thoracic inlet alignment on MRI: Reliability and the influence of body position. *Clin Spine Surg* 30:E377-380, 2016. <https://doi.org/10.1097/BSD.0000000000000306>
16. Scheer JK, Tang JA, Smith JS, Acosta FL, Jr, Protopsaltis TS, Blondel B, Bess S, Shaffrey CI, Deviren V, Lafage V, Schwab F, Ames, CP: Cervical spine alignment, sagittal deformity, and clinical implications: A review. *J Neurosurg Spine* 19:141-159, 2013. <https://doi.org/10.3171/2013.4.SPINE12838>
17. Shao ZX, Yan YZ, Pan XX, Chen SQ, Fang X, Chen XB, Wu AM, Wang XY: Factors associated with cervical spine alignment in an asymptomatic population: A preliminary analysis. *World Neurosurg* 122:e48-e58, 2019. <https://doi.org/10.1016/j.wneu.2018.09.036>
18. Tang JA, Scheer JK, Smith JS, Deviren V, Bess S, Hart RA, Lafage V, Shaffrey CI, Schwab F, Ames CP: The impact of standing regional cervical sagittal alignment on outcomes in posterior cervical fusion surgery. *Neurosurgery* 76:S14-S21, 2015. <https://doi.org/10.1227/01.neu.0000462074.66077.2b>
19. Tang YC, Zhao WK, Yu M, Liu XG: Normative values of cervical sagittal alignment according to the whole spine balance: Based on 126 asymptomatic Chinese young adults. *Beijing Da Xue Xue Bao Yi Xue Ban* 54:712-718, 2022. <https://doi.org/10.19723/j.issn.1671-167X.2022.04.021>
20. Toyama Y: The optimum position of fusion in atlanto-axial arthrodesis. *Cerv Spine Res Soc* 59:134-135, 1992
21. Toyama Y, Matsumoto M, Chiba K, Asazuma T, Suzuki N, Fujimura Y, Hirabayashi K: Realignment of postoperative cervical kyphosis in children by vertebral remodeling. *Spine (Phila Pa 1976)* 19:2565-2570, 1994. <https://doi.org/10.1097/00007632-199411001-00012>
22. Yang K, Li XY, Wang Y, Kong C, Lu SB: Relationship between TIA minus C0-7 angle and C2-7 SVA: Analysis of 113 symptomatic patients. *BMC Musculoskelet Disord* 23:338, 2022. <https://doi.org/10.1186/s12891-022-05301-0>
23. Yokoyama K, Kawanishi M, Yamada M, Tanaka H, Ito Y, Kawabata S, Kuroiwa T: Age-related variations in global spinal alignment and sagittal balance in asymptomatic Japanese adults. *Neurol Res* 39:414-418, 2017. <https://doi.org/10.1080/01616412.2017.1296654>
24. Yoshida G, Kamiya M, Yoshihara H, Kanemura T, Kato F, Yukawa Y, Ito K, Matsuyama Y, Sakai Y: Subaxial sagittal alignment and adjacent-segment degeneration after atlantoaxial fixation performed using C-1 lateral mass and C-2 pedicle screws or transarticular screws. *J Neurosurg Spine* 13:443-450, 2010. <https://doi.org/10.3171/2010.4.SPINE09662>
25. Yoshimoto H, Ito M, Abumi K, Kotani Y, Shono Y, Takada T, Minami A: A retrospective radiographic analysis of subaxial sagittal alignment after posterior C1-C2 fusion. *Spine (Phila Pa 1976)* 29:175-181, 2004. <https://doi.org/10.1097/01.BRS.0000107225.97653.CA>
26. Zhong J, Pan Z, Chen Y, Yao H, Cheng Z, Liu Q, Zeng Z, Li Z, Duan P, Chen J: Postoperative cervical sagittal Realignment improves patient-reported outcomes in chronic atlantoaxial anterior dislocation. *Oper Neurosurg (Hagerstown)* 15:643-650, 2018. <https://doi.org/10.1093/ons/opy035>
27. Zhu YC, An ZC, Zhang YJ, Wei H, Dong LQ: Predictive formula of cervical lordosis in asymptomatic young population. *J Orthop Surg Res* 3:15, 2020. <https://doi.org/10.1186/s13018-019-1526-x>