



Is There a Risk of Stroke During Anterior Cervical Discectomy? A Randomized Controlled Trial

Nevin Esra GUMUS¹, Tuba KUVVET YOLDAS², Vaner KOKSAL³, Ahmet KARKUCAK⁴, Birol BAYRAKTAR³

¹Samsun Training and Research Hospital, Anesthesia Clinic, Samsun, Türkiye

²Health Sciences University, Tepecik Training and Research Hospital, Anesthesia Clinic, Izmir, Türkiye

³Samsun University, Samsun Training and Research Hospital, Department of Neurosurgery, Samsun, Türkiye

⁴Samsun Great Anatolian Hospital, Neurosurgery Clinic, Samsun, Türkiye

Corresponding author: Vaner KOKSAL ✉ vaner.koksal@samsun.edu.tr

ABSTRACT

AIM: To examine the effects of different retractor techniques for anterior cervical discectomy on cerebral oxygen saturation.

MATERIAL and METHODS: In this study, a prospective comparative design was employed to examine the effects of different retractor techniques on a cohort of 48 adult patients with ASA I-II classification who underwent anterior cervical discectomy under general anesthesia. The study was conducted under assessor-blinded conditions, and the patients were divided equally into two groups: the self-retaining retractor group and the hand-held retractor group. In addition to standard anaesthesia monitoring, the utilization of cerebral oximetry monitoring was implemented for all patients. A total of 7 measurements were obtained at various stages, including preoperative, during anaesthesia induction, surgical positioning, surgical retraction, release of retractors, after correction of extension position, and prior to extubation. The main objective of this study was to evaluate the impact of neck position and surgical retraction on brain perfusion, as measured by regional cerebral oximetry.

RESULTS: Sociodemographic data, duration of operation, hemodynamic parameters, bilateral regional cerebral oxygen saturation (rScO₂), and Mini Mental State Examination (MMSE) scores did not differ significantly between the two groups. In both groups, the bilateral rScO₂ decreased significantly with positioning and the left rScO₂ decreased significantly following the installation of retractors. Only the left rScO₂ increased significantly upon the release of both retractors. Following the correction of the neck position, bilateral rScO₂ increased significantly in both groups (p<0.001).




CONCLUSION: The rScO₂ of the left carotid artery was shown to significantly decrease due to the indirect impact of the retractors. After extending the head and neck, bilateral rScO₂ values decreased significantly in both groups. However, despite this decline, there was no significant decrease in brain perfusion that would result in ischemia. The absence of a statistically significant distinction between the groups implies that it is unlikely to have an impact on brain perfusion.

KEYWORDS: Carotid artery, Cerebral blood oxygenation, Anterior cervical spine surgery, Near-infrared spectroscopy, Ischemic stroke

INTRODUCTION

Anterior cervical discectomy (ACD) is a common surgical procedure used to treat radicular and myelopathic cervical intervertebral discopathy, which causes nerve root and spinal cord compression in neurosurgery. The patient

is positioned in the supine position during ACD, prior to admission of general anaesthesia. The patient's neck is gently extended to the extent that it can tolerate, and mild distal traction is administered by placing a support beneath the shoulder. Numerous studies have documented that the extension of the neck has the capacity to modify blood circulation in

Nevin Esra GUMUS  : 0000-0002-1363-3099
Tuba KUVVET YOLDAS  : 0000-0001-5567-6313
Vaner KOKSAL  : 0000-0002-4902-5298

Ahmet KARKUCAK  : 0000-0003-2522-1822
Birol BAYRAKTAR  : 0000-0003-4546-2797

adults, hence potentially resulting in intraoperative cerebral ischemia in situations where collateral flow is insufficient (22).

Near-Infrared Spectroscopy (NIRS) is a method that can be employed to evaluate regional cerebral oxygen saturation. Jobsis were the first to employ NIRS in 1977 to evaluate the risk of developing cerebral ischaemia while providing information on brain tissue oxygenation (13,17). NIRS is a technological approach that allows the non-invasive assessment and monitoring of cerebral blood flow. NIRS quantifies the relative concentrations of oxy-haemoglobin and deoxy-haemoglobin in tissues by analysing the transmission and absorption of near-infrared light (3). It offers a means of quantifying regional oxygen saturation (rSO₂) (3), enabling the non-invasive and continuous evaluation of cerebral oxygenation (2). A reduction in bilateral or unilateral cerebral oxygen saturation of >20% from baseline is considered an indicator of cerebral ischaemia (8). NIRS monitoring was used to examine the impact of body position changes (head lift in shoulder surgeries, prone, supine, and 90° neck flexion) on cerebral oxygenation in certain surgical procedures, such as thyroidectomy, shoulder surgery, and carotid endarterectomies (1,6,10,16). To the best of our knowledge, no study has been undertaken that explicitly evaluates any alteration of cerebral oxygenation through the use of NIRS monitoring in patients undergoing ACD operations.

Postoperative cognitive dysfunction refers to a subtle condition affecting various cognitive functions, potentially impacting specific domains of thought processes like executive functions, verbal and visual memory, language abilities, visuospatial abstraction, as well as attention and concentration (11,25). Mini Mental State Examination (MMSE) is one of the commonly used cognitive screening tool that is useful in quantitatively estimating the severity of cognitive impairment and in serially documenting changes in cognitive function (9).

The primary aim of this study was to examine the impact of the surgical retraction technique and neck position on cerebral perfusion employed during ACD. The secondary objective of the study was to investigate the impact of neck posture and surgical retraction on cognitive skills following surgery.

■ MATERIAL and METHODS

Study Design

Conducted between July 2020 and August 2021 in adherence to the principles outlined in the Declaration of Helsinki, this was a randomized, controlled, prospective study with blinded assessors. The research was granted approval by the local ethics committee under the reference number SBÜSEAH-KAEK-2020/6/3. The study was also registered with clinicaltrials.gov, with the identifier NCT05717010. Each patient provided written informed consent to partake in the study and to allow their data to be utilized for research purposes.

Patients

ASA physical status class I-II patients aged 18–70 years with a preoperative MMSE score between 27 and 30 who were

scheduled to undergo ACD surgery under general anaesthesia were recruited for the study. The study excluded individuals with hypertension, severe lung disease, anaemia, cardiac disease, ischemic cerebrovascular disease, renal disease, hepatic disease, pregnancy, uncontrolled diabetes mellitus, carotid or vertebral artery obstruction, or a body mass index > 30. Prior to administering anaesthesia, the patient's standard peripheral oxygen saturation, non-invasive blood pressure, and ECG were monitored. A cerebral oximeter (INVOS, Somanetics Corporation, Troy, MI, USA) was used to monitor cerebral oxygen saturation. The oximeter pads were affixed to the patient's forehead and specifically positioned over the right and left frontal regions, 1 cm laterally from the midline and distal from the temporalis muscle, as well as 1 cm superior to the eyebrow. Following a period of 10 minutes in the supine position, various hemodynamic parameters including heart rate (HR), mean arterial pressure (MAP), as well as peripheral and cerebral regional oxygen saturation (SpO₂, rScO₂) were recorded. General anaesthesia was administered using a standardised protocol that includes propofol 2-3 mg kg⁻¹, rocuronium 0.6 mg kg⁻¹ and fentanyl 1 µg kg⁻¹ for induction of anaesthesia followed by maintenance with 2% sevoflurane in 50% oxygen with 50% air and 0.05-0.2 mcg/kg/min remifentanyl. Tidal volume was set at 6-8 ml/kg and respiratory rate of 8-12/min to obtain an end tidal carbon dioxide (EtCO₂) of 35-40 mmHg. Patients were positioned in the semi-fowler position with extension of the neck and head at an angle of 30-45°.

Randomisation and Outcomes

The closed envelope technique was employed to implement patient randomization before their enrolment into the study. Each patient was given a randomization ID that was later used during follow-up evaluations. Patients were evenly and randomly allocated into two distinct groups. A self-retaining retractor was used for surgical retraction in one group, while a hand-held retractor was used in the other group. The physician responsible for assessing the patients' postoperative mental status (NEG) remained unaware of the assigned group during the evaluation period, providing a blinded approach.

The primary outcome was the effects of neck position and surgical retraction on brain perfusion. The secondary outcome was the effect of brain perfusion on perioperative and postoperative neurological complications.

Measurements were recorded at the following time frames:

T0: preoperative

T1: after anesthesia induction

T2: after surgical positioning

T3: 5 minutes after surgical retraction

T4: 45 minutes after surgical retraction

T5: after the release of retraction

T6: after correction of extension

T7: after extubation

In order to ensure patients possessed the cognitive capacity to follow the instructions of the test, the MMSE was administered prior to testing and at the 2nd postoperative hour. Patients who obtained an MMSE score of 24 did not undergo any additional testing.

Statistical Analysis

A pilot study involving ten patients per group was conducted. The required number of participants for the study was determined to be 24 for each group when using an alpha of 0.05, standard effect power of 0.69, and power of 0.90, in order to detect a decrease in cerebral oximetry readings of %20. Considering the possibility of dropouts, 50 patients were included in the study.

Data obtained in the study were analysed using SPSS v. 21 software (Statistical Package for the Social Sciences – IBM®). The Chi-square test was used to analyse categorical variables. Conformity of numerical data to normal distribution was analysed with the Kolmogorov Smirnov and Shapiro-Wilk normality tests. Normally distributed numerical data were analysed using the Independent Samples t-test, and non-normally distributed numerical data with the Mann Whitney U-test. Repeated measurements ANOVA analysis was performed to compare the effect of anaesthesia, surgical positioning, and retraction manipulations on cerebral oxygenation during the operation in the hand-held retractor group and the self-retain-

ing retractor group. In both groups, Mauchly’s Test of Sphericity indicated that the assumption of sphericity had been violated and therefore, Greenhouse-Geisser corrections were used. The Bonferroni test was used to make post hoc comparisons. The level of statistical significance was set as $p < 0.05$.

RESULTS

Out of the total sample size of fifty participants, forty-eight individuals were deemed eligible and included in the study. The study’s CONSORT diagram (Figure 1) illustrates the factors leading to exclusion. There were no statistically significant differences observed between the groups with respect to age, gender, ASA physical status, height, weight, and surgical times (Table I).

The study included a total of 48 patients, 24 in the self-retaining retractor group and 24 in the hand-held retractor group. The self-retaining retractor group was comprised of 13 (27.2%) males and 11 females, and the hand-held retractor group was comprised of 14 (29.2%) males and 10 females. No statistically significant difference was found between the groups in respect of sociodemographic data, operating time, and hemodynamic parameters. In both groups, the majority of the operations were performed for a single intervertebral disc (Table I).

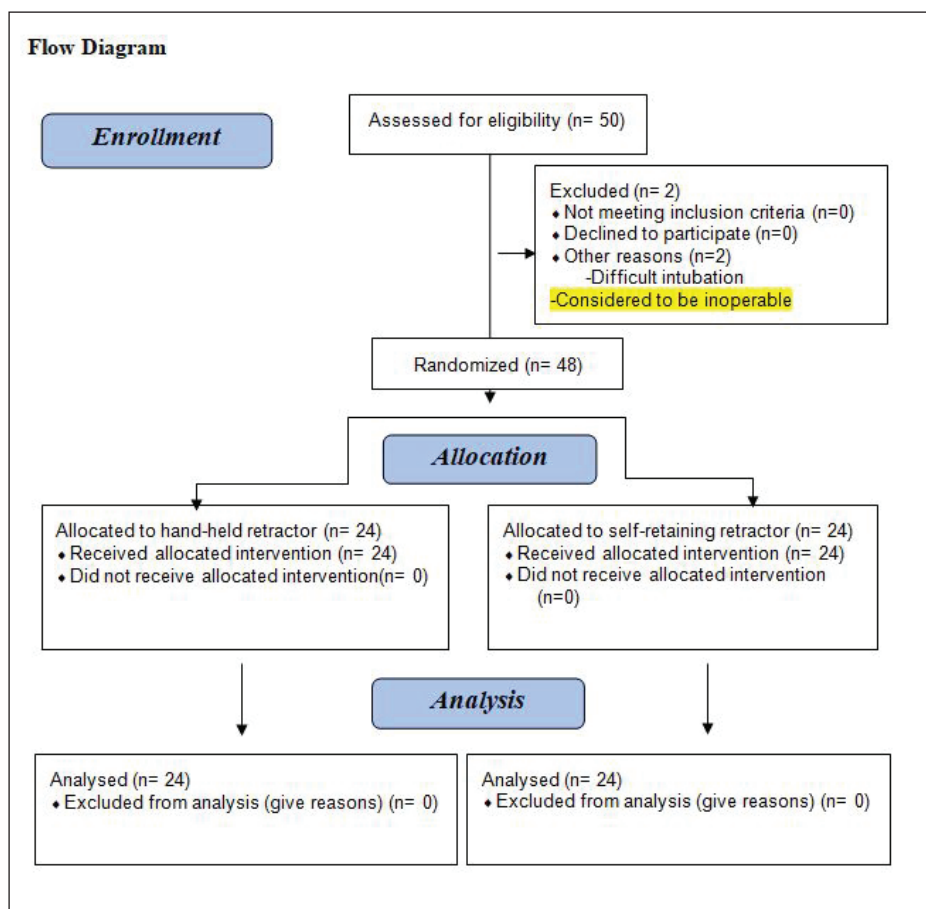


Figure 1: Flow diagram of study.

There was no statistically significant difference between the two groups in terms of HR, MAP, and SpO₂ at all time periods as well as between the MMSE scores preoperatively and at the postoperative second hour. When the right and left

rScO₂ values were compared the recorded time frames, no statistically significant difference was seen between the two groups (Table II).

Table I: Demographic Characteristics, Level, Duration of Surgery and Mean MMSE Scores of the Groups

	Group self-retaining retractor (n=24)	Group hand-held retractor (n=24)	Test statistic	p-value
Age (years)	42.7 ± 8.6	47.0 ± 12.7	-1.388 ¹	0.172
Gender	Female	11 (46%)	0.085 ²	0.771
	Male	13 (54%)		
Surgical level	One level	13 (54%)	0.751 ²	0.386
	Two levels	11 (46%)		
Duration of surgery (mins)	132.1 ± 31.9	127.5 ± 37.1	0.459 ¹	0.648
MMSE	Preoperative	27.75 ± 2.38	0.751 ¹	0.457
	Postoperative second hour	29.04 ± 1.62	0.790 ¹	0.433

¹Independent samples t test; data are presented as mean ± standard deviation (SD). ²Pearson Chi-square test; data are presented as number (percentage). **MMSE:** Mini mental state examination.

Table II: Comparison of Left-Right rScO₂ values of the Groups

		Group self-retaining retractor (n=24)	Group hand-held retractor (n=24)	Test statistic	p-value
		Mean ± SD	Mean ± SD		
Left rScO₂	T0	69.92 ± 9.34	70.13 ± 6.26	-0.091	0.928
	T1	81.67 ± 8.20	81.38 ± 8.52	0.121	0.904
	T2	69.67 ± 7.93	68.83 ± 7.36	0.377	0.708
	T3	67.29 ± 7.82	67.00 ± 7.00	0.136	0.892
	T4	67.21 ± 8.16	66.54 ± 7.14	0.301	0.765
	T5	69.04 ± 7.36	68.29 ± 7.28	0.355	0.724
	T6	71.75 ± 6.31	71.79 ± 7.39	-0.021	0.983
Right rScO₂	T7	79.79 ± 9.67	77.92 ± 7.40	0.754	0.455
	T0	69.13 ± 8.29	70.54 ± 6.86	-0.645	0.522
	T1	79.96 ± 8.20	80.67 ± 7.82	-0.306	0.761
	T2	68.42 ± 8.18	68.50 ± 6.90	-0.038	0.970
	T3	67.88 ± 7.83	68.08 ± 7.33	-0.095	0.925
	T4	67.42 ± 8.19	67.68 ± 7.20	-0.112	0.911
	T5	69.50 ± 8.79	68.38 ± 6.98	0.491	0.626
T6	73.50 ± 9.26	71.96 ± 6.68	0.662	0.512	
	T7	80.13 ± 7.86	77.71 ± 6.83	1.137	0.261

Independent samples t test; data are presented as mean ± standard deviation (SD). **T0:** Preoperatively, **T1:** After anaesthesia induction, **T2:** After surgical positioning, **T3:** 5 minutes after surgical retraction, **T4:** 45 minutes after surgical retraction, **T5:** After the release of retraction, **T6:** After correction of extension, **T7:** After extubation.

When successive rScO₂ values in the hand-held retractor group were evaluated, they were found that the right and left rScO₂ values recorded at T0 increased greatly at T1 and then decreased significantly at T2. At T3 and T4, only the left rScO₂ value decreased significantly, while at T5, only the left rScO₂ value increased significantly. At T6 and T7, the right and left rScO₂ measurements increased significantly (Table III).

There were significant effects of intraoperative manipulations on cerebral oxygenation on both the left (F=38.195, p<0.001, η²=0.624) and right sides (F=37.294, p<0.001, η²=0.619). When the consecutive rScO₂ values were compared in the

self-retaining retractor group, it was determined that the right and left rScO₂ values measured at T0 increased significantly at T1, and then decreased significantly at T2. At T3 a significant decrease was observed only in the left rScO₂ value. At T5, T6 and T7, both the right and left rScO₂ values increased significantly (Figure 2) (Table IV).

DISCUSSION

The purpose of this investigation was to evaluate the effect of head and neck extension and two distinct surgical retraction techniques on cerebral perfusion during an ACD procedure.

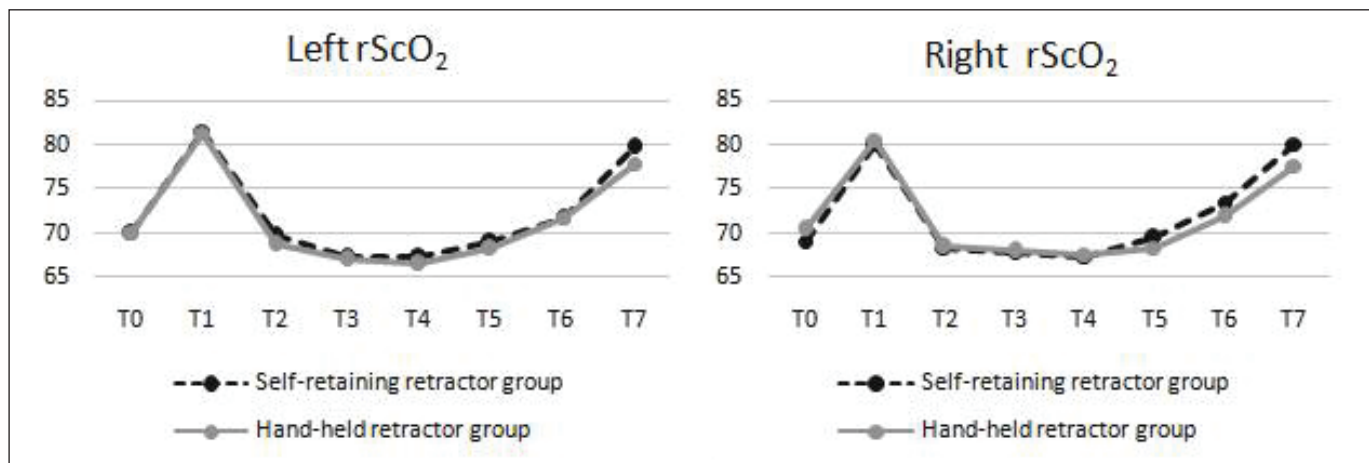


Figure 2: Left and right rScO₂ values.

Table III: Comparisons of the Consecutive rScO₂ Values in the Hand-Held Retractor group

Left rScO ₂	Mean ± SD	F	p-value	Right rScO ₂	Mean ± SD	F	p-value
T0	70.13 ± 6.26	59.584	0.001	T0	70.54 ± 6.86	60.938	0.001
T1	81.38 ± 8.52			T1	80.67 ± 7.82		
T1	81.38 ± 8.52	88.602	0.001	T1	80.67 ± 7.82	83.266	0.001
T2	68.83 ± 7.36			T2	68.50 ± 6.90		
T2	68.83 ± 7.36	7.441	0.012	T2	68.50 ± 6.90	0.171	0.683
T3	67.00 ± 7.00			T3	68.08 ± 7.33		
T3	67.00 ± 7.00	0.763	0.391	T3	68.08 ± 7.33	0.489	0.491
T4	66.54 ± 7.14			T4	67.68 ± 7.20		
T4	66.54 ± 7.14	8.431	0.008	T4	67.68 ± 7.20	3.339	0.081
T5	68.29 ± 7.28			T5	68.88 ± 6.98		
T5	68.29 ± 7.28	26.414	0.001	T5	68.88 ± 6.98	26.464	0.001
T6	71.79 ± 7.39			T6	71.96 ± 6.68		
T6	71.79 ± 7.39	35.301	0.001	T6	71.96 ± 6.68	26.663	0.001
T7	77.92 ± 7.40			T7	77.71 ± 6.83		

Repeated measurements ANOVA; data are presented as mean ± standard deviation (SD). T0: Preoperatively, T1: After anaesthetic induction, T2: After surgical positioning, T3: 5 minutes after surgical retraction, T4: 45 minutes after surgical retraction, T5: After the release of retraction, T6: After correction of extension, T7: After extubation.

Table IV: Comparisons of the Consecutive rScO₂ Values in the Self-Retaining Retractor Group

Left rScO ₂	Mean ± SD	F	p-value	Right rScO ₂	Mean ± SD	F	p-value
T0	69.92 ± 9.34	45.350	0.001	T0	70.54 ± 6.86	88.582	0.001
T1	81.67 ± 8.20			T1	80.67 ± 7.82		
T1	81.67 ± 8.20	110.400	0.001	T1	80.67 ± 7.82	117.848	0.001
T2	69.67 ± 7.93			T2	68.50 ± 6.90		
T2	69.67 ± 7.93	4.756	0.045	T2	68.50 ± 6.90	0.880	0.358
T3	67.29 ± 7.82			T3	68.08 ± 7.33		
T3	67.29 ± 7.82	0.007	0.936	T3	68.08 ± 7.33	0.604	0.445
T4	67.21 ± 8.16			T4	67.68 ± 7.20		
T4	67.21 ± 8.16	5.221	0.032	T4	67.68 ± 7.20	5.680	0.026
T5	69.04 ± 7.36			T5	68.88 ± 6.98		
T5	69.04 ± 7.36	8.708	0.007	T5	68.88 ± 6.98	11.807	0.002
T6	71.75 ± 6.31			T6	71.96 ± 6.68		
T6	71.75 ± 6.31	31.902	0.001	T6	71.96 ± 6.68	18.757	0.001
T7	79.79 ± 9.67			T7	80.13 ± 7.86		

Repeated measurements ANOVA; data are presented as mean ± standard deviation (SD). **T0:** Preoperatively, **T1:** After anaesthetic induction, **T2:** After surgical positioning, **T3:** 5 minutes after surgical retraction, **T4:** 45 minutes after surgical retraction, **T5:** After the release of retraction, **T6:** after correction of extension, **T7:** After extubation.

Saracoglu et al. investigated the influence of the cervical extension position during thyroidectomy on carotid artery blood flow and rScO₂ levels. Doppler data revealed a considerable reduction in carotid blood flow and rScO₂ values between induction and the end of the operation (21). Smarius et al. found a substantial decrease in rScO₂ readings as a result of neck hyperextension in the Rose position used in cleft palate procedures (22). Yaman et al. reported a 35% decrease in carotid blood flow when the position was applied to patients undergoing thyroid surgery (27). Consistent with previous research, a significant decrease in rScO₂ levels was seen in the current investigation when the head and neck was extended following induction.

To obtain adequate surgical exposure during ACD, the right sternocleidomastoid muscle, right jugular vein, right common carotid artery, and right vagus nerve must be retracted anterolaterally, while the oesophagus and trachea must be retracted medially. Improper surgical dissection and intraoperative excessive retraction during anterior cervical spine surgery modifies the flow dynamics of the common carotid artery by significantly reducing vascular cross-sectional area (18). Although these alterations are particularly obvious in young people, cases of stroke during lengthy surgery and in patients with atherosclerotic risks have been reported (4,7,19,20,28). In cases where the procedure is anticipated to be lengthy, such as a multi-level corpectomy, it has been suggested that it may be necessary to periodically release the retractor blades in order to restore adequate blood flow to the brain via the internal carotid artery (4). Within the framework of our study, it is es-

sential to emphasize that the duration of surgical procedures did not surpass the threshold of 160 minutes.

Moreover, sustained pressure on the carotid artery can result in thrombosis or cerebral ischemia. Plaques may become dislodged as a result of manipulation techniques, resulting in intracranial embolism and stroke (18). Consequently, throughout the surgical procedure, the retractor underwent multiple readjustments in order to achieve sufficient surgical exposure. However, it was not completely released in order to temporarily suspend the retraction.

Only the left rScO₂ value decreased significantly ($p < 0.05$) following the installation of a retractor in both groups. Deep neck dissection was performed from the right side of the neck on all patients in both groups, and the right sternocleidomastoid muscle and carotid artery were retracted. The left carotid was not directly subjected to retraction. The utilization of NIRS measurements enabled the evaluation of both bilateral direct and indirect pressure. The decrease in the left rScO₂ value was ascribed to the retraction technique, specifically the action of withdrawing the retractor from the side where the oesophagus and trachea are situated, rather than the side where the carotid artery is positioned, with the intention of improving visibility of the surgical site. When approaching the neck from the right side, it is hypothesized that tissues shifted toward the carotid on the left side in order to better visualize the anterior surface of the vertebra will lead to more indirect pressure. A possible solution to this issue is to release the retractors on a regular basis.

Bilateral or unilateral cerebral oxygen saturation values of <50% or a drop of >20% from the baseline value are regarded as an indicator of cerebral ischaemia (8,10,12,15). In the current study, a change of this magnitude did not occur in the cerebral oxygenation values. Patients with atherosclerotic risks, who were not included in this study, may experience higher declines that could result in cerebral ischaemia. It has been claimed that cerebral oximetry plays a vital role in protecting brain functions despite its limits, and undetected periods of cerebral ischaemia may be seen (17). During anterior cervical discectomy, it is possible to inadvertently induce cerebral ischemic damage of varying magnitudes. Initially, there may be no obvious clinical signs.

However, only a few studies explicitly reporting the occurrence of postoperative stroke in patients who underwent anterior cervical discectomy are available in literature. Furthermore, large retrospective series have reported that complications occur rarely. No study that focused on the actual mechanism of occurrence in ischemic stroke was identified (5,8,19,24,26,29). The occurrence of a fatal stroke in the brain stem may have been influenced by intraoperative surgical manipulation and protracted neck hyperextension leading to arterial blood flow obstruction (23). The necessity for conducting large prospective randomized control trials to effectively establish the safety profile of outpatient ACD has been emphasized, as stated in a meta-analysis (29).

The MMSE was administered preoperatively and two hours after surgery to measure postoperative cognitive status; however, there were no significant differences in the mean scores.

To date, many experimental models of ischemic stroke have been made, but the possibility of ischemia occurring during a surgery that may affect our carotid vessels in humans has not been investigated. It has been reported that vascular anomalies in the main nutrients of the brain are complicated with ischemic stroke, and few case reports have been reported (14,30). It is the only study investigating whether there is a risk of stroke when performing cervical spine surgery with an anterior approach. This study is valuable because no previous study has assessed the effect of surgical positioning and retraction in ACD on the level of cerebral oxygenation using NIRS monitoring.

Limitations

The possibility of overlooking the transitory effects of neck positions on the vertebral artery was a limitation of this research. However, the fact that the research population was relatively young mitigated additional carotid vessel-related risk factors. Another constraint is that surgical procedures did not exceed 160 minutes. Stated differently, the potential risks associated with cerebral ischemia in patients undergoing significantly prolonged surgery times and exhibiting no apparent risk factors remain elusive and unexplored. Furthermore, we compared a precisely calibrated automatic retractor with a hand-held retractor that depends on the operator's hand sensitivity and habits. This comparison inherently introduces a higher

potential for bias due to the contrasting standardisation levels. However, the results of our study revealed no significant differences in any parameter related to the retractor selection, indicating that this limitation may not have significantly impacted the observed outcomes.

CONCLUSION

The occurrence of perioperative stroke associated with the carotid artery following anterior cervical discectomy is exceedingly rare. Cerebral hypoperfusion and ischemic stroke can be induced by prolonged retraction, carotid artery atherosclerosis, and intraoperative hypotension. Following head and neck extension, bilateral rScO₂ values decreased significantly in both groups, however, this did not result in a reduction in brain perfusion sufficient to produce ischemia.

As factors that could enhance the risk of ischemia were omitted from the current investigation, rScO₂ reductions that could lead to deeper ischemia may occur in individuals at risk for cerebrovascular events and during protracted ACD procedures. The preoperative evaluation of risk, meticulous perioperative handling with cautious placement of retractors, and ensuring sufficient cerebral perfusion are essential considerations.

ACKNOWLEDGMENTS

Special thanks to Associate Professor Serkan Tulgar from Samsun University.

Declarations

Funding: There is no funding to report.

Availability of data and materials: The datasets generated and/or analyzed during the current study are available from the corresponding author by reasonable request.

Disclosure: All authors declare that they have no conflict of interest and, whose names are listed immediately below certify that they have no affiliations with or involvement in any organisation or entity with any financial interest (such as honoraria; educational grants; participation in speakers' bureaus; membership, employment, consultancies, stock ownership, or other equity interest; and expert testimony or patent-licensing arrangements), or non-financial interest (such as personal or professional relationships, affiliations, knowledge or beliefs) in the subject matter or materials discussed in this manuscript.

AUTHORSHIP CONTRIBUTION

Study conception and design: VK, NEG

Data collection: NEG, AK, BB

Analysis and interpretation of results: NEG, TKY

Draft manuscript preparation: NEG, VK

Critical revision of the article: VK

Other (study supervision, fundings, materials, etc...): AK, BB

All authors (NEG, TKY, VK, AK, BB) reviewed the results and approved the final version of the manuscript.

■ REFERENCES

- Ancora G, Maranella E, Aceti A: Effect of posture on brain hemodynamics in preterm newborns not mechanically ventilated. *Neonatology* 97:212-217, 2010. <https://doi.org/10.1159/000253149>
- Badenes R, Gouvea Bogossian E, Chisbert V: The role of noninvasive brain oximetry in adult critically ill patients without primary non-anoxic brain injury. *Minerva Anestesiol* 87:1226-1238, 2021. <https://doi.org/10.23736/S0375-9393.21.15333-7>
- Cardim D, Griesdale DE: Near-infrared spectroscopy: Unfulfilled promises. *Br J Anaesth* 121:523-526, 2018. <https://doi.org/10.1016/j.bja.2018.05.058>
- Chozick BS, Watson P, Greenblatt SH: Internal carotid artery thrombosis after cervical corpectomy. *Spine* 19:2230-2232, 1994. <https://doi.org/10.1097/00007632-199410000-00020>
- Chughtai M, Sultan AA, Padilla J: Postoperative stroke after anterior cervical discectomy and fusion in patients with carotid artery stenosis: A statewide database analysis. *Spine* 19:597-601, 2019. <https://doi.org/10.1016/j.spinee.2018.09.011>
- Cura Z, Oc B, Arun O: Effects of sevoflurane and propofol anesthesia on cerebral oxygenation in patients undergoing carotid endarterectomy. *Turk Neurosurg* 32:76-82, 2022. <https://doi.org/10.5137/1019-5149.JTN.33776-21.2>
- Du YQ, Duan WR, Chen Z: Carotid artery-related perioperative stroke following anterior cervical spine surgery: A series of 3 cases and literature review. *J Stroke Cerebrovasc Dis* 28:458-463, 2019. <https://doi.org/10.1016/j.jstrokecerebrovasdis.2018.10.024>
- Edmonds HL, Ganzel BL, Austin HE: Cerebral oximetry for cardiac and vascular surgery. *Semin Cardiothorac Vasc Anesth* 8:147-166, 2004. <https://doi.org/10.1177/108925320400800208>
- Folstein MF, Folstein SE, McHugh PR: "Mini-mental state": A practical method for grading the cognitive state of patients for the clinician. *J Psychiatric Res* 12:189-198, 1975. [https://doi.org/10.1016/0022-3956\(75\)90026-6](https://doi.org/10.1016/0022-3956(75)90026-6)
- Fuchs G, Schwarz G, Kulier A: The influence of positioning on spectroscopic measurements of brain oxygenation. *J Neurosurg Anesthesiol* 12:75-80, 2000. <https://doi.org/10.1097/00008506-200004000-00001>
- Hansen MV: Chronobiology, cognitive function and depressive symptoms in surgical patients. *Dan Med J* 61:B4914, 2014
- Hou X, Ding H, Teng Y: Research on the relationship between brain anoxia at different regional oxygen saturations and brain damage using near-infrared spectroscopy. *Physiol Meas* 28:1251-1265, 2007. <https://doi.org/10.1088/0967-3334/28/10/010>
- Jobsis FF: Noninvasive, infrared monitoring of cerebral and myocardial oxygen sufficiency and circulatory parameters. *Science* 198:1264-1267, 1977. <https://doi.org/10.1126/science.929199>
- Kaya AH, Erdogan H, Tasdemiroglu E: Searching evidences of stroke in animal models: A review of discrepancies a review of discrepancies. *Turk Neurosurg* 27:167-173, 2017. <https://doi.org/10.5137/1019-5149.JTN.15373-15.2>
- Kocaoglu B, Ozgen SU, Toraman F: Foreseeing the danger in the beach chair position: Are standard measurement methods reliable? *Knee Surg Sports Traumatol Arthrosc* 23:2639-2644, 2015. <https://doi.org/10.1007/s00167-014-3090-6>
- Kurihara K, Kikukawa A, Kobayashi A: Cerebral oxygenation monitor during head-up and -down tilt using near-infrared spatially resolved spectroscopy. *Clin Physiol Funct Imaging* 23:177-181, 2003. <https://doi.org/10.1046/j.1475-097X.2003.00488.x>
- Murkin JM, Arango M: Near-infrared spectroscopy as an index of brain and tissue oxygenation. *Br J Anaesth* 103 Suppl 1:i3-13, 2009. <https://doi.org/10.1093/bja/aep299>
- Pollard ME, Little PW: Changes in carotid artery blood flow during anterior cervical spine surgery. *Spine* 27:152-155, 2002. <https://doi.org/10.1097/00007632-200201150-00006>
- Radcliff K, Ong KL, Lovald S: Cervical spine surgery complications and risks in the elderly. *Spine* 42:E347-E354, 2017. <https://doi.org/10.1097/BRS.0000000000001799>
- Radhakrishnan M, Bansal S, Srihari GS: Perioperative stroke following anterior cervical discectomy. *Br J Neurosurg* 24:592-594, 2010. <https://doi.org/10.3109/02688691003711575>
- Saracoglu A, Altun D, Yavru A: Effects of head position on cerebral oxygenation and blood flow velocity during thyroidectomy. *Turk J Anaesthesiol Reanim* 44:241-246, 2016. <https://doi.org/10.5152/TJAR.2016.77598>
- Smarius BJA, Breugem CC, Boasson MP: Effect of hyperextension of the neck (rose position) on cerebral blood oxygenation in patients who underwent cleft palate reconstructive surgery: Prospective cohort study using near-infrared spectroscopy. *Clin Oral Invest* 24: 2909-2918, 2020. <https://doi.org/10.1007/s00784-019-03157-8>
- Tsai YF, Doufas AG, Huang CS: Postoperative coma in a patient with complete basilar syndrome after anterior cervical discectomy. *Can J Anaesth* 53:202-207, 2006. <https://doi.org/10.1007/BF03021828>
- Wang LC, Liou JT, Liu FC: Fatal ischemia stroke in a patient with an asymptomatic carotid artery occlusion after lumbar spine surgery-a case report. *Acta Anaesthesiol Taiwan* 42:179-182, 2004
- Wang W, Wang Y, Wu H, Lei L, Xu S, Shen X, Guo X, Shen R, Xia X, Liu Y, Wang F: Postoperative cognitive dysfunction: Current developments in mechanism and prevention. *Med Sci Monit* 20:1908-1912, 2014. <https://doi.org/10.12659/MSM.892485>
- Wewel JT, Brahimaj BC, Kasliwal MK: Perioperative complications with multilevel anterior and posterior cervical decompression and fusion. *J Neurosurg Spine* 20:1-6, 2019. <https://doi.org/10.3171/2019.6.SPINE198>
- Yaman F, Pehlivanli F, Aydin G: Effects of semi-fowler position on cerebral oxygenation during thyroidectomy. *Osmangazi J Med* 42:645-651, 2020
- Yeh YC, Sun WZ, Lin CP: Prolonged retraction on the normal common carotid artery induced lethal stroke after cervical spine surgery. *Spine* 29:431-434, 2004. <https://doi.org/10.1097/01.brs.0000141177.95850.b1>
- Yerneni K, Burke JF, Chunduru P: Safety of outpatient anterior cervical discectomy and fusion: A systematic review and meta-analysis. *Neurosurgery* 86:30-45, 2020. <https://doi.org/10.1093/neuros/nyy636>
- Yuan F, Lin J, Ding L: Hemifacial spasm and recurrent stroke due to vertebrobasilar dolichoectasia coexisting with saccular aneurysm of the basilar artery: A case report. *Turk Neurosurg* 23:282-284, 2013