



# Evaluation of the Regeneration Effects of Systemically Applied Methylprednisolone and Vitamin B12 on Mental Nerve Crush Injury

Cigdem KARA<sup>1</sup>, Nihat LACIN<sup>1</sup>, Berat Metin ADAK<sup>1</sup>, Alper KARA<sup>1</sup>, Selcuk TUNIK<sup>2</sup>, Ersin UYSAL<sup>3</sup>, Fahri Emrah SOYLU<sup>4</sup>, Ozge SARI TURGUT<sup>4</sup>

<sup>1</sup>Izmir Katip Celebi University, Faculty of Dentistry, Department of Oral and Maxillofacial Surgery, Izmir, Türkiye

<sup>2</sup>Dicle University, Faculty of Medicine, Department of Histology and Embryology, Diyarbakir, Türkiye

<sup>3</sup>Dicle University, Department of Computer Technologies, Diyarbakir, Türkiye

<sup>4</sup>Ege University, Laboratory Animals Application and Research Center, Izmir, Türkiye

**Corresponding author:** Berat Metin ADAK ✉ beradak@hotmail.com

## ABSTRACT

**AIM:** To evaluate the effects of methylprednisolone and vitamin B12 injection on the regeneration of the nerves after a mental nerve crush injury.

**MATERIAL and METHODS:** A total of 40 albino Wistar rats have been randomly divided into four groups: group 1 (n=10): crush-like nerve damage was created by pinching the left mental nerve for 60 s with an aneurysm clip and intraperitoneally administered 1 ml of saline for 14 days; group 2 (n=10): the left mental nerve was pinched for 60 s with an aneurysm clip and intraperitoneally administered 2 mg/kg of methylprednisolone for 14 days; group 3, experimental group (n=10): the left mental nerve was pinched for 60 s with an aneurysm clip and intraperitoneally administered 2 mg/kg of vitamin B12 for 14 days; and group 4, experimental group (n=10): the left mental nerve was pinched for 60 s and intraperitoneally administered 2 mg/kg of methylprednisolone and 2 mg/kg of vitamin B12 for 14 days. All rats were sacrificed on the 28<sup>th</sup> postoperative day, and histopathological evaluation was performed.

**RESULTS:** Nerve damage was higher in the control group than in other groups ( $p<0.05$ ). When Neural Cell Adhesion Molecule (NCAM) expression levels were compared, no major differences were observed between the methylprednisolone and control groups ( $p>0.05$ ). The B12 and B12+methylprednisolone groups reached significantly higher NCAM expression levels compared to the control and methylprednisolone groups. When the myelin basic protein (MBP) expression levels were compared ( $p<0.05$ ), the MBP expression was significantly higher in all experimental groups than in the control group ( $p<0.05$ ).

**CONCLUSION:** Systemic vitamin B12 and methylprednisolone administration effectively supported remyelination in the crushed mental nerve by increasing Schwann cell proliferation and differentiation.




**KEYWORDS:** Vitamin B12, Methylprednisolone, Mental nerve damage, Nerve regeneration, Nerve crush injury, Rat

## INTRODUCTION

Peripheral nervous system injury deteriorates the damaged nerve function and changes the arousal threshold (7,8,16,43). Its symptoms include pain, burning, stinging, loss of sensation, asymmetrical appearance, numbness,

and tingling sensation (1,5,25,36). In oral and maxillofacial surgery, surgical procedures that may cause nerve damage are frequently performed (1,29,31). The majority of damages during procedures are caused by crushing or overstretching the nerve. Total or partial rupture-like injuries with completely

Cigdem KARA  : 0000-0003-4849-0785  
Nihat LACIN  : 0000-0003-3661-2378  
Berat Metin ADAK  : 0000-0002-7385-3130

Alper KARA  : 0000-0001-8762-987X  
Selcuk TUNIK  : 0000-0002-0549-8472  
Ersin UYSAL  : 0000-0001-8349-3506

Fahri Emrah SOYLU  : 0000-0002-8405-5468  
Ozge SARI TURGUT  : 0000-0001-5284-7420

disrupted nerve integrity are rare (18). Damages are generally temporary, and the majority of these heal within 6–8 weeks. In some cases, sensory loss continues for 6 months or longer, resulting in permanent neuropathic disorders (22,37). It can be treated with pharmacological therapies such as steroids, antioxidants, antidepressants, anti-inflammatory drugs, and vitamins or alternative treatments such as acupuncture, cryotherapy, biomodulation, ozone therapy, low-level laser applications, or surgical techniques (17,45). The response of damaged nerve tissues to treatment depends on the degree of nerve damage. Pharmacological treatments aim to restore the functions of the damaged nerve, accelerate nerve tissue regeneration, and eliminate the aesthetic and psychological concerns of the patients (11,13).

Among the pharmacological treatments, steroids are the most preferred agents because of their strong anti-inflammatory properties (10,33,38). Steroids administered at the early stages of injury slow the nerve damage progression and accelerate healing. Steroids reduce perineural edema at the site of injury in cases where the damage does not impair the nerve integrity (17,44). In this method, steroids reduce nerve pressure, slow down axon degeneration, and increase regeneration and prevent the formation of fibrosis (2,21).

Vitamin B has positive effects on the nervous system, immune system, skin health, and metabolism. This pharmaceutical agent has been used after peripheral nerve injuries and has curative and protective positive effects on nerve regeneration (4,26). Moreover, steroids reduce degeneration and increase the regeneration of axons and support the preservation of the myelin sheath structure and nerve fiber regeneration (19).

Therefore, this study aimed to reveal the possible effects of methylprednisolone and vitamin B12 injection on rat models with crush-type mental nerve damage using immunohistochemical methods.

## ■ MATERIAL and METHODS

With the project code 2020-TDU-D-F-0008, the Izmir Katip Celebi University Scientific Research Coordination Unit funded this study, which also received approval from the local animal experimentation ethics committee of Ege University (No: 2020-007; Date: 29.01.2020). A total of 40 Wistar albino rats aged 3 months, with an average weight of 250–300 g, with an equal number of males and females, have been used in this study. With 10 test animals in each group, the subjects were randomly divided into four groups. Animals have been kept on a 12-h day/night cycle and maintained *ad libitum* on the standard laboratory aliment and water. We preferred 2 mg/kg drug doses, guided by a previous study (15).

### Experimental Groups

Group 1 (the control group, n=10): The left mental nerves of rats were exposed and compressed using Yaşargil aneurysm clips (Aesculap, Braun Medikal, Istanbul, Turkey) for 60 s, and the crush-type nerve damage was created. After the nerve damage has been created, the skin tissues and muscles were sutured with simple sutures and 1 ml of saline was injected intraperitoneally for 14 days.

Group 2 (the methylprednisolone group, n=10): The left mental nerves of the rats were exposed and compressed with Yaşargil aneurysm clips for 60 s, and crush-type nerve damage was created. After the nerve damage has been created, the skin and muscle tissues were sutured using simple sutures, and 2 mg/kg methylprednisolone was injected intraperitoneally for 14 days.

Group 3 (the vitamin B12 group, n=10): The left mental nerve of the rats was exposed and compressed with Yaşargil aneurysm clips for 60 s, and crush-type nerve damage was created. After the nerve damage has been created, the skin and muscle tissues were sutured with simple sutures, and 2 mg/kg of vitamin B12 has been injected intraperitoneally for 14 days.

Group 4 (the methylprednisolone and vitamin B12 group, n=10): The left mental nerve of the rats was exposed and compressed with Yaşargil aneurysm clips for 60 s, and the crush-type nerve damage was created. After the nerve damage has been created, the skin tissue and muscles were sutured with simple sutures, and both 2 mg/kg of methylprednisolone and 2 mg/kg of vitamin B12 were injected intraperitoneally for 14 days.

### Surgical Procedures

Preoperatively, each rat was anesthetized with 10 mg/kg of xylazine (Rompun; Bayer, Istanbul, Turkey) and 90 mg/kg of ketamine hydrochloride intramuscularly (Ketalar; Pfizer, Istanbul, Turkey). Following anesthesia, neck hairs were removed, and the subjects were then placed on the fixing board. To prevent infection at the surgical site, a povidone-iodine solution (Poviodex, Kimpa, Turkey) has been applied to the shaved region. After establishing the requisite asepsis and antisepsis conditions, sterile surgical drapes were used to isolate the surgical region before administering local anesthetics using 0.5 ml of a 1:200,000 epinephrine-containing articaine solution (Ultracain-DS hoechst Marion Roussel, Istanbul, Turkey). The incision line was identified. The masseter muscle was accessed by making a 1 cm-long vertical dermal incision at the neck midpoint and descending 1 cm inferior to the lower lip midline. The masseter muscle was dissected, and the mental nerve was exposed. The exposed nerve was pinched for 60 s with a Yaşargil aneurysm clip (Aesculap, Braun Medikal, Istanbul, Turkey), and the crushed nerve damage was created.

After the surgical operations were completed, the skin tissue has been sutured with a 4/0 silk suture material (Dosan, Turkey) and the muscle tissue with absorbable glycolide-based 4/0 suture material (Vicryl, Ethicon, Brussels, Belgium). To prevent local infection, a topical antibiotic called Neo Caf Spray (Intervent, MSD, Italy) was then applied to the wound region.

Following a 28-day recovery period, the subject's mental nerve tissues, including healthy tissues near and far from the damaged area, were removed and put in a solution of zinc formalin for immunohistochemistry testing. Then, while under general anesthesia, the animals were sacrificed using cervical dislocation.

## Postoperative Care

Enrofloxacin (Baytril-K® 2.5 mg/kg IM) and meloxicam (Maxicam® 1 mg/kg IM) were administered intramuscularly to the rats once daily for 5 days postoperatively. To prevent local infection, the topical antibiotic Neo Caf Spray (Intervent, MSD, Italy) was applied to the wound region once daily for 5 days postoperatively. For 28 days, an expert veterinarian periodically assessed the animals' weight, nutrition, and overall health. The animals were supplied food and water ad libitum.

## Histopathological and Immunohistochemical Examination Methods

The nerve tissues were placed into a zinc formalin (Z2902 Sigma-Aldrich, USA) solution, and necessary fixation procedures were completed. The tissues were then embedded in paraffin blocks, and 4–5-m-thick sections were cut from the blocks using a microtome (catalog no. Leica RM2265, Wetzlar, Germany) for immunohistochemical and hematoxylin-eosin staining (H&E).

The nerve damage level was evaluated after H&E staining of nerve tissue sections. Myelin sheath swelling, vacuolization, the presence of myelin ellipsoids, mononuclear cell infiltration, and edema were considered during the evaluation. The nerve damage of the obtained sections was scored by assigning a value between 1 and 4 (1, 0%–25%; 2, 25%–50%; 3, 50%–75%; and 4, 75%–100%) (8,9,26,27,36).

Neural Cell Adhesion Molecule (NCAM) expression levels were evaluated after anti-NCAM staining of nerve tissue sections. The expression intensity was calculated by considering values between 0 and 4 (0, no expression; 1, minimal expression; 2, moderate expression; 3, above-moderate expression; and 4, strong expression) (13).

The myelin basic protein (MBP) expression levels were evaluated after anti-MBP staining of nervous tissue sections. The expression intensity was calculated by considering values between 0 and 4 (0, no expression; 1, minimal expression; 2, moderate expression; 3, above-moderate expression; and 4, strong expression) (14).

## Statistical Analysis

Fisher's exact, Mann–Whitney U, and Kruskal–Wallis tests were used to compare variances between the means of independent groups using non-parametric analysis tests, multiple comparisons, and multiple comparisons, respectively.

The R Foundation for Statistical Computing Free Software, was used for descriptive statistics and test analyses. The results have been considered statistically significant if the p-value is less than 0.05 ( $p < 0.05$ ).

## RESULTS

### H&E Staining Results

Myelin sheath swelling, vacuolization, the presence of myelin ellipsoids, mononuclear cell infiltration, and edema findings were evaluated for histopathological examination. The mean score values of the samples in the control, B12, methylprednisolone, and B12+methylprednisolone groups were 3.80, 1.90, 2.70, and 1.90 respectively (Table I and Figure 1).

### Anti-NCAM Staining Results

NCAM expression levels were evaluated using the anti-NCAM dye. The mean score values of the samples were 1.80, 3.00, 1.70, and 2.50 in the control, B12, methylprednisolone, and B12+methylprednisolone groups, respectively (Table I and Figure 2).

**Table I:** Comparison of Groups with Mann Whitney U Test

Parameters	Groups	n	Mean	Median	Average Rank	Different ( $p < 0.05$ ) from groups	Kruskal-Wallis test values	Significance level (p)
Nerve Damage Scores	(1) Control	10	3.80	4.00	34.00	(2), (3), (4)	23.567	0.000
	(2) Vitamin B12	10	1.90	2.00	13.00	(1), (3)		
	(3) Methyl prednisolone	10	2.70	3.00	22.00	(1), (2), (4)		
	(4) B12 + Methyl prednisolone	10	1.90	2.00	13.00	(1), (3)		
NCAM expression	(1) Control	10	1.80	2.00	14.40	(2), (4)	16.286	0.001
	(2) Vitamin B12	10	3.00	3.00	30.10	(1), (3)		
	(3) Methyl prednisolone	10	1.70	2.00	13.20	(2), (4)		
	(4) B12 + Methyl prednisolone	10	2.50	3.00	24.30	(1), (3)		
MBP expression	(1) Control	10	1.90	2.00	9.70	(2), (3), (4)	14.278	0.003
	(2) Vitamin B12	10	2.80	3.00	20.15	(1)		
	(3) Methyl prednisolone	10	3.30	3.50	25.85	(1)		
	(4) B12 + Methyl prednisolone	10	3.30	3.50	26.30	(1)		

n: Number, **NCAM:** Neural Cell Adhesion Molecule, **MBP:** Myelin Basic Protein.

### Anti-MBP Staining Results

MBP expression levels were evaluated using an anti-MBP stain. The mean score values of the samples were 1.90, 2.80, 3.30, and 3.30 in the control, B12, methylprednisolone, and B12+methylprednisolone groups, respectively (Table I and Figure 3).

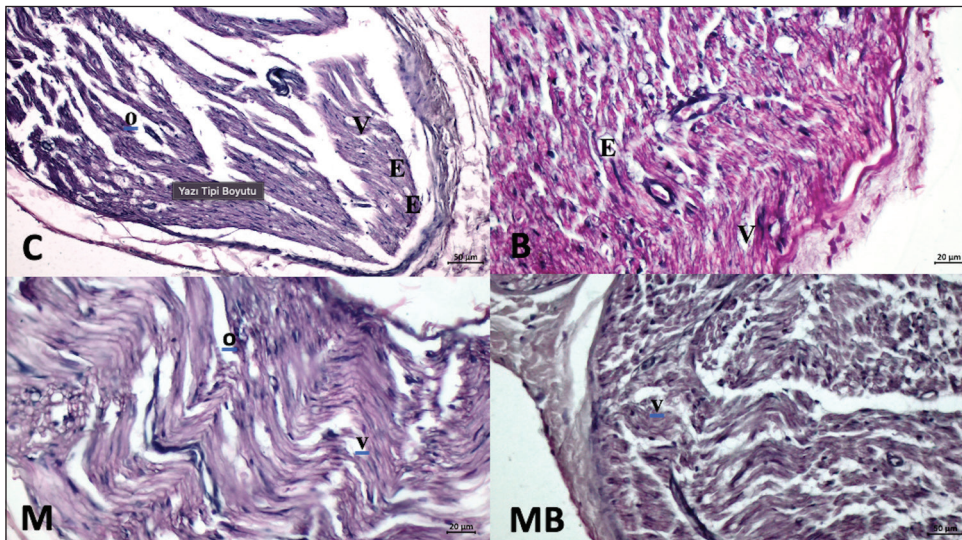
### Statistical Analysis Results

The results of multiple comparisons between independent groups using the Mann–Whitney U test and Kruskal–Wallis values to compare the differences between the means are presented in Table I. Score evaluations in the four groups made up of three histological staining parameters have been statistically significant (Table I). Based on the Mann–Whitney U test, the B12 and B12+methylprednisolone groups were statistically comparable in H&E staining, although all groups were statistically different from that of the control group. Anti-NCAM staining revealed a significant difference between the B12 and

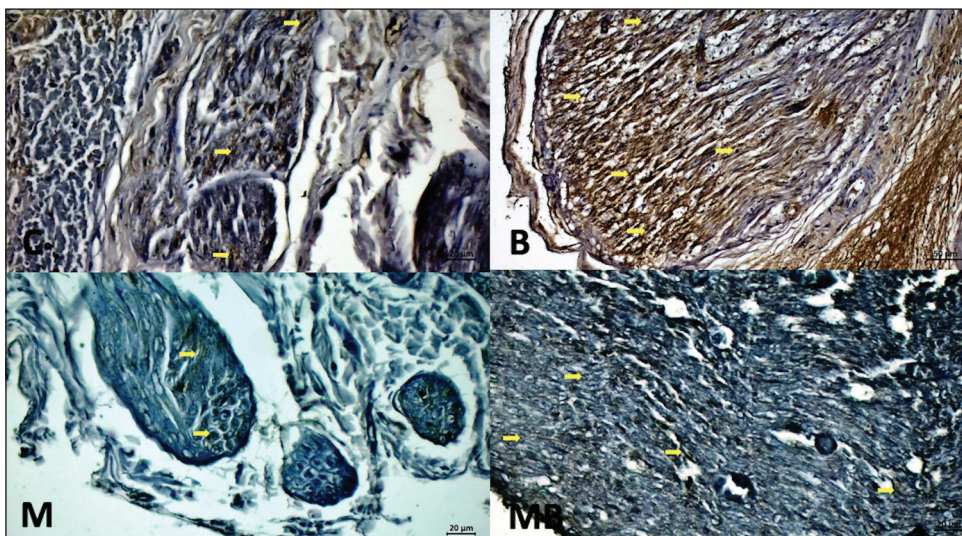
B12+methylprednisolone groups and the control group but not between the control and methylprednisolone groups. In anti-MBP staining, methylprednisolone and B12+methylprednisolone groups were statistically comparable, although all groups considerably differed from the control group.

### DISCUSSION

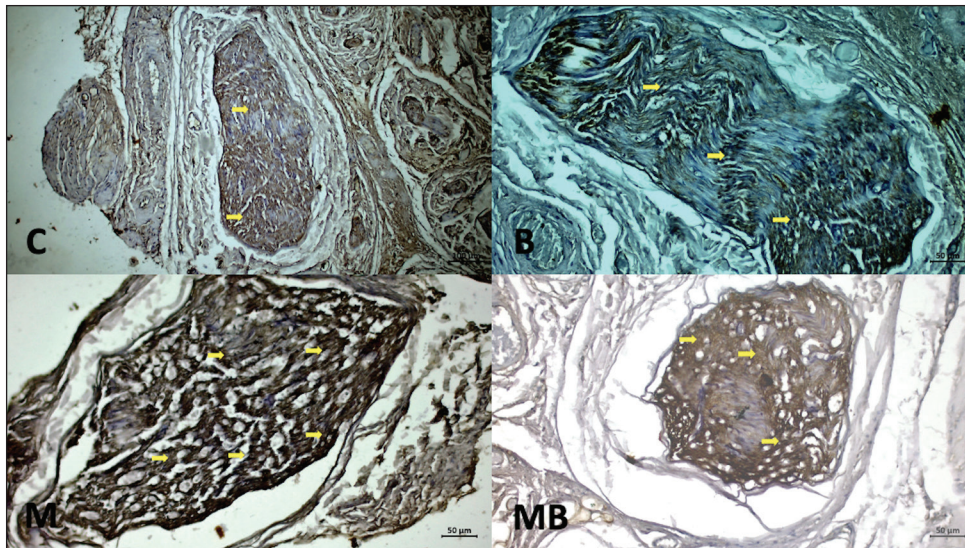
Nerve damage can occur during different procedures involving the oral and maxillofacial regions. A considerable proportion of patients experience this issue even though losing sensation as a result of these procedures is a rare complication. The lingual, mental, and inferior alveolar nerves are the three most commonly injured nerves (23). Nerve disruption also affects the central nervous system and functional brain (12). The peripheral nerve injury treatments aim to accelerate healing, ensure complete or almost complete healing, and prevent the occurrence of complications and other possible sequelae (20). Due to their anti-inflammatory effects, the most commonly



**Figure 1:** Control (C), vitamin B12 (B), methylprednisolone (M), methylprednisolone +vitamin B12 (MB) group sections stained with H&E x400. Edema (O), vacuole (V) and ellipsoid (E) myelin are observed in the nerve fiber.



**Figure 2:** Control (C), vitamin B12 (B), methylprednisolone (M), methylprednisolone +vitamin B12 (MB) group sections stained with anti-NCAM antibody (x400). **Arrows:** show immunoreactivity.



**Figure 3:** Control (C), vitamin B12 (B), methylprednisolone (M), methylprednisolone +vitamin B12 (MB) group sections stained with anti-MBP antibody (x160). **Arrows:** show immunoreactivity.

prescribed pharmaceuticals are corticosteroids in idiopathic, traumatic, and infectious peripheral nerve injuries. Vitamin B12 is essential for many metabolic pathways in the central nervous system. In cases of vitamin B12 deficiency, many structures such as that of the brain, optic nerve, peripheral nerves, and spinal cord may be affected, which may result in different neurological conditions (35,41).

Sekiya et al. investigated the effects of methylprednisolone administration before and after the compression-type injury on the cochlear nerve and reported that the use of methylprednisolone could prevent cochlear nerve damage due to its anti-inflammatory effect (34). Our results support this study. Nerve damage scoring was found to be significantly lower in both groups receiving methylprednisolone than the control group. Nachemson et al. reported that methylprednisolone suppressed scar formation and improved axonal regeneration after transection and suturing of rat peripheral nerves (42). In our study, methylprednisolone positively contributed to regeneration by suppressing axonal degeneration. Bao et al. reported that methylprednisolone reduced lipid peroxidation and inhibited arachidonic acid hydrolysis following a spinal cord injury in early-treated rats (6). In our results, NCAM levels were low, but MBP levels were high in the methylprednisolone group. Low NCAM expression levels in the methylprednisolone group suggest that methylprednisolone suppresses inflammatory processes due to reduced axonal degeneration.

Hobbenaghi et al. reported that vitamin B12 has protective and restorative effects on secondary pathochemical events after a sciatic nerve injury in rats (17). Our study results showed that nerve damage scores were lower in the groups administered with vitamin B12 compared to the methylprednisolone and control groups. Nerve regeneration was higher in the vitamin B12-administered group. Sun et al. found that dexamethasone and vitamin B12 stimulated the production of endogenous neurotrophic factors and thus increased peripheral nerve repair (39). Data obtained from our study showed

that the combined use of vitamin B12 and methylprednisolone has positive effects on nerve regeneration and may have a potential role in nerve regeneration. Al-Khalisy and Ali compared the effects of vitamins B12, B6, and B1 on crush-type injuries in rats and reported that vitamin B12 was more effective in nerve fiber regeneration and remyelination (3). In our study, both NCAM and MBP levels were high in the vitamin B12 group, suggesting that vitamin B12 accelerates regeneration (41).

Pan et al. reported that MBP played a crucial role in increasing functional recovery and promoting nerve regeneration after a sciatic nerve injury in rats (28,40). In our study, the perineurium structure was more preserved in the experimental groups compared to the control group, and these data were consistent with high MBP levels in the experimental groups. Rustemeyer and Dicke reported a close relationship between MBP density and functional recovery following a sciatic nerve injury in rats (32). The high MBP levels in our experimental groups suggest that B12 and methylprednisolone administration increased the proliferation of Schwann cells, accelerated regeneration, upregulated the MBP, and accelerated remyelination at the injury site (43). Roach et al. investigated the role of MBP in the peripheral nervous system in mice with mutations in a part of the MBP gene. They reported that myelin thickness decreased in peripheral nerves without MBP; however, axonal integrity was preserved. In our study, low MBP levels in the control group indicate downregulation of MBP synthesis and myelin damage after a crush injury (30).

Martini and Schachner investigated the identification of L1, NCAM, and myelin-associated glycoprotein by immunoelectron microscopy in the crushed and dissected adult mouse sciatic nerve. The majority of cells tested positive for NCAM. NCAM and L1 were expressed by growth cones and regrowth axons at the points of cell interaction (24). In our study, NCAM expression levels were higher in the experimental groups than that in the control group.

Data obtained at the end of the study suggest that the vitamin B12 and methylprednisolone treatment for mental nerve crush injury in rats reduces nerve damage scoring and contributes to the preservation of the perineurium tissue.

Our study shows that systemic vitamin B12 and methylprednisolone administration effectively supports remyelination of the crushed mental nerve by increasing Schwann cell proliferation and differentiation. The MBP and NCAM expression levels in nerve regeneration after mental nerve injury were first evaluated in our study. The results showed that the MBP expression levels increased during myelin sheath repair and NCAM levels during axonal repair. For the first time, a combination of methylprednisolone and vitamin B12 for the treatment of nerve injuries was administered in our study. Based on our obtained data, the combined use of vitamin B12 and methylprednisolone has positive effects on and may have a potential role in nerve regeneration. In addition, this drug combination, which has not been previously tried in this experimental model, sheds light on further studies. Our study suggests that vitamin B12 and methylprednisolone may have different and beneficial effects on nerve regeneration when administered separately or in combination at different application doses and at different time intervals. The use of different histopathological or immunohistochemical markers for histological evaluation may provide a more comprehensive understanding of the mechanisms of action of vitamin B12 and methylprednisolone on nerve regeneration.

## CONCLUSION

Combined use of vitamin B12 and methylprednisolone, an untested method on a rat mental nerve crush injury model, can be used as a potential new treatment to treat nerve damage, control pain, and accelerate regeneration in mental nerve injury.

### Declarations

**Funding:** Izmir Katip Celebi University Scientific Research Coordination Unit (2020-TDU-D-F-0008).

**Availability of data and materials:** The datasets generated and/or analyzed during the current study are available from the corresponding author by reasonable request.

**Disclosure:** Authors declare no conflict of interest.

### AUTHORSHIP CONTRIBUTION

Study conception and design: CK, NL

Data collection: CK, NL, BMA

Analysis and interpretation of results: ST, EY, FES, OST

Draft manuscript preparation: CK, BMA, AK

Critical revision of the article: CK, NL, BMA

Other (study supervision, fundings, materials, etc.): CK, NL AK

All authors (CK, NL, BMA, AK, ST, EU, FES, OST) reviewed the results and approved the final version of the manuscript.

## REFERENCES

- Adak BM, Lacin N, Simsek F, Uysal E, Soylu FE, Ozkan I: Evaluation of the effects of different hemostatic agent applications on mental nerve. *Eur Arch Oto-Rhino-Laryngol* 279:5355-5362, 2022. <https://doi.org/10.1007/s00405-022-07434-3>
- Al-Bishri A, Dahlin L, Sunzel B, Rosenquist J: Systemic betamethasone accelerates functional recovery after a crush injury to rat sciatic nerve. *J Oral Maxillofac Surg* 63:973-977, 2005. <https://doi.org/10.1016/j.joms.2004.10.010>
- Al-Khalisy MH, Ali SM: Morphometrical and histological evaluation of the effect of vitamins B1, B6 and B12 on rats sciatic nerve after crush injury. *Int Jour of Med Sci and Clin Inv* 4:2715-2726, 2017. <https://doi.org/10.18535/ijmsci/v4i2.15>
- Altun I, Kurutas EB: Vitamin B complex and vitamin B12 levels after peripheral nerve injury. *Neural Regen Res* 11:842-845, 2016. <https://doi.org/10.4103/1673-5374.177150>
- Asplund M, Nilsson M, Jacobsson A, von Holst H: Incidence of traumatic peripheral nerve injuries and amputations in Sweden between 1998 and 2006. *Neuroepidemiology* 32:217-228, 2009. <https://doi.org/10.1159/000197900>
- Bao F, Chen Y, Dekaban GA, Weaver LC: Early anti-inflammatory treatment reduces lipid peroxidation and protein nitration after spinal cord injury in rats. *J Neurochem* 88:1335-1344, 2004. <https://doi.org/10.1046/j.1471-4159.2003.02240.x>
- Beydoun A: Neuropathic pain: From mechanisms to treatment strategies. *J Pain Symptom Manage* 25:S1-S3, 2003. [https://doi.org/10.1016/S0885-3924\(03\)00063-0](https://doi.org/10.1016/S0885-3924(03)00063-0)
- Cameron NE, Cotter MA: Metabolic and vascular factors in the pathogenesis of diabetic neuropathy. *Diabetes* 46 Suppl 2:S31-S37, 1997. <https://doi.org/10.2337/diab.46.2.S31>
- Carriel V, Garzón I, Alaminos M: Histological assessment in peripheral nerve tissue engineering. *Neural Regen Res* 9:1657-1660, 2014. <https://doi.org/10.4103/1673-5374.141798>
- Chong MS, Bajwa ZH: Diagnosis and treatment of neuropathic pain. *J Pain Symptom Manage* 25:S4-S11, 2003. [https://doi.org/10.1016/S0885-3924\(03\)00064-2](https://doi.org/10.1016/S0885-3924(03)00064-2)
- Cornwall R, Radomisl TE: Nerve injury in traumatic dislocation of the hip. *Clin Orthop Relat Res* 377:84-91, 2000. <https://doi.org/10.1097/00003086-200008000-00012>
- Eksi MS, Eksi E, Arslanhan A, Sirinoglu H, Erbil S, Gungor A, Algin O, Konya D: Functional reorganization in the primary somatosensory cortex of rat following hind-paw amputation: A study of functional imaging with 1.5 Tesla MRI. *Turk Neurosurg* 30:17-22, 2020. <https://doi.org/10.5137/1019-5149.JTN.25595-18.2>
- Er N, Canakci FG, Capar G, Alkan A: Peripheral nerve injury and treatment in dentistry. *Atatürk Üniv Diş Hek Fak Derg* 26:147-152, 2016. <https://doi.org/10.17567/dfd.33334>
- Fedchenko N, Reifenrath J: Different approaches for interpretation and reporting of immunohistochemistry analysis results in the bone tissue - a review. *Diagn Pathol* 9:221, 2014. <https://doi.org/10.1186/s13000-014-0221-9>
- Goldberg H, Mibielli MA, Nunes CP, Goldberg SW, Buchman L, Mezitis SGE, Rzetelna H, Oliveira L, Geller M, Wajnsztajn F: A double-blind, randomized, comparative study of the use of a combination of uridine triphosphate trisodium, cytidine monophosphate disodium, and hydroxocobalamin, versus isolated treatment with hydroxocobalamin, in patients presenting with compressive neuralgias. *J Pain Res* 10:397-404, 2017. <https://doi.org/10.2147/JPR.S123045>

16. Grobman LR, Pollak A, Fisch U: Entrapment injury of the facial nerve resulting from longitudinal fracture of the temporal bone. *Otolaryngol Head Neck Surg* 101:404-408, 1989. <https://doi.org/10.1177/019459988910100318>
17. Hobbenaghi R, Javanbakht J, Hosseini E, Mohammadi S, Rajabian M, Moayeri P, Hassan MA: Neuropathological and neuroprotective features of vitamin B12 on the dorsal spinal ganglion of rats after the experimental crush of sciatic nerve: An experimental study. *Diagn Pathol* 11:109, 2016 (Retraction). <https://doi.org/10.1186/s13000-016-0578-z>
18. Kalender AM, Dogan A, Bakan V, Yildiz H, Gokalp MA, Kalender M: Effect of Zofenopril on regeneration of sciatic nerve crush injury in a rat model. *J Brachial Plex Peripher Nerve Inj* 4:6, 2009
19. Kato Y, Tanaka T, Isawa S, Matsuda A, Nakazawa T: Quantitative studies of histological findings on acrylamide-induced neuropathy. Degenerative changes and effect of vitamin B complex. *Vitamins* 51:197-206, 1977
20. Korlu S: Travmatik Periferik Sinir Paralizlerinde Sinir İyileşmesi Üzerine Dekametazon Ve Metilprednizolon İle Mikofenolat Mofetil Tedavilerinin Etkinliğinin Elektrofizyolojik, Histopatolojik, Biyokimyasal, Elektron Mikroskopik Ve İmmünohistokimyasal Olarak İncelenmesi (Uzmanlık Tezi). Mersin: Mersin Üniversitesi Tıp Fakültesi, 2011:94
21. Lamberts SW, Bruining HA, de Jong FH: Corticosteroid therapy in severe illness. *N Engl J Med* 337:1285-1292, 1997. <https://doi.org/10.1056/NEJM199710303371807>
22. Leung YY, Fung PP, Cheung LK: Treatment modalities of neurosensory deficit after lower third molar surgery: A systematic review. *J Oral Maxillofac Surg* 70:768-778, 2012. <https://doi.org/10.1016/j.joms.2011.08.032>
23. Lopes V, Mumenya R, Feinmann C, Harris M: Third molar surgery: An audit of the indications for surgery, post-operative complaints and patient satisfaction. *Br J Oral Maxillofac Surg* 33:33-35, 1995. [https://doi.org/10.1016/0266-4356\(95\)90083-7](https://doi.org/10.1016/0266-4356(95)90083-7)
24. Martini R, Schachner M: Immunoelectron microscopic localization of neural cell adhesion molecules (L1, N-CAM, and myelin-associated glycoprotein) in regenerating adult mouse sciatic nerve. *J Cell Biol* 106:1735-1746, 1988. <https://doi.org/10.1083/jcb.106.5.1735>
25. Menorca RM, Fussell TS, Elfar JC: Nerve physiology: Mechanisms of injury and recovery. *Hand Clin* 29:317-330, 2013. <https://doi.org/10.1016/j.hcl.2013.04.002>
26. Nedeljković P, Zmijanac D, Drašković-Pavlović B, Vasiljevska M, Vučević D, Božić B, Bumbaširević M: Vitamin B complex treatment improves motor nerve regeneration and recovery of muscle function in a rodent model of peripheral nerve injury. *Arch Biol Sci* 69:361-368, 2017. <https://doi.org/10.2298/ABS160320114N>
27. Oliveira AC, Garzón I, Ionescu AM: Evaluation of small intestine grafts decellularization methods for corneal tissue engineering. *PLoS One* 8:e6653816, 2013. <https://doi.org/10.1371/journal.pone.0066538>
28. Pan HC, Yang DY, Ou YC, Ho SP, Cheng FC, Chen CJ: Neuroprotective effect of atorvastatin in an experimental model of nerve crush injury. *Neurosurgery* 67:376-389, 2010. <https://doi.org/10.1227/01.NEU.0000371729.47895.A0>
29. Pogrel MA, Kaban LB: Injuries to the inferior alveolar and lingual nerves. *J Calif Dent Assoc* 21:50-54, 1993
30. Roach A, Takahashi N, Pravtcheva D, Ruddle F, Hood L: Chromosomal mapping of mouse myelin basic protein gene and structure and transcription of the partially deleted gene in shiverer mutant mice. *Cell* 42:149-155, 1985. [https://doi.org/10.1016/S0092-8674\(85\)80110-0](https://doi.org/10.1016/S0092-8674(85)80110-0)
31. Robert RC, Bacchetti P, Pogrel MA: Frequency of trigeminal nerve injuries following third molar removal. *J Oral Maxillofac Surg* 63:732-736, 2005. <https://doi.org/10.1016/j.joms.2005.02.006>
32. Rustemeyer J, Dicke U: Correlation of three sciatic functional indices with histomorphometric findings in a rat sciatic nerve allograft repair model. *Microsurgery* 29:560-567, 2009. <https://doi.org/10.1002/micr.20658>
33. Salinas RA, Alvarez G, Daly F, Ferreira J: Corticosteroids for Bell's palsy (idiopathic facial paralysis). *Cochrane Database Syst Rev* 3:CD001942, 2010. <https://doi.org/10.1002/14651858.CD001942.pub4>
34. Sekiya T, Shimamura N, Suzuki S, Hatayama T: Methylprednisolone ameliorates cochlear nerve degeneration following mechanical injury. *Hear Res* 151:125-132, 2001. [https://doi.org/10.1016/S0378-5955\(00\)00219-7](https://doi.org/10.1016/S0378-5955(00)00219-7)
35. Sen S, Durat G, Atasoy I: Mental and neurological disorders related to vitamin B12 and folic acid deficiencies. *Türk Klinik Biyokimya Derg* 7:31-36, 2009
36. Senses F, Onder ME, Kocyigit ID, Kul O, Aydin G, Inal E, Atil F, Tekin U: Effect of platelet-rich fibrin on peripheral nerve regeneration. *J Craniofac Surg* 27:1759-1764, 2016. <https://doi.org/10.1097/SCS.00000000000003066>
37. Smith MH, Lung KE: Nerve injuries after dental injection: A review of the literature. *J Can Dent Assoc* 72:559-564, 2006
38. Stankiewicz JA: A review of the published data on steroids and idiopathic facial paralysis. *Otolaryngol Head Neck Surg* 97:481-486, 1987. <https://doi.org/10.1177/019459988709700509>
39. Sun H, Yang T, Li Q, Zhu Z, Wang L, Bai G, Li D, Li Q, Wang W: Dexamethasone and vitamin B(12) synergistically promote peripheral nerve regeneration in rats by upregulating the expression of brain-derived neurotrophic factor. *Arch Med Sci* 8:924-930, 2012. <https://doi.org/10.5114/aoms.2012.31623>
40. Tamaddonfard E, Farshid AA, Ahmadian E, Hamidhoseyni A: Crocin enhanced functional recovery after sciatic nerve crush injury in rats. *Iran J Basic Med Sci* 16:83-90, 2013
41. Terzi M, Turker H, Akkurt A, Yazici D, Onar M: Spinal MRI and clinical findings of three subacute combined degeneration cases. *Türkiye Klinikleri J Neur* 4:41-46, 2009
42. Tsai SY, Chiu PY, Yang CP, Lee YH: Synergistic effects of corticosterone and kainic acid on neurite outgrowth in axotomized dorsal root ganglion. *Neuroscience* 114:55-67, 2002. [https://doi.org/10.1016/S0306-4522\(02\)00261-0](https://doi.org/10.1016/S0306-4522(02)00261-0)
43. White S: Assessment of chronic neuropathic pain and the use of pain tools. *Br J Nurs* 13:372-378, 2004. <https://doi.org/10.12968/bjon.2004.13.7.12680>
44. Wicke C, Halliday B, Allen D: Effects of steroids and retinoids on wound healing. *Arch Surg* 135:1265-1270, 2000. <https://doi.org/10.1001/archsurg.135.11.1265>
45. Yamany AA, Sayed HM: Effect of low level laser therapy on neurovascular function of diabetic peripheral neuropathy. *J Adv Res* 3:21-28, 2012. <https://doi.org/10.1016/j.jare.2011.02.009>