



Comparison of Single Lumbar Transforaminal Epidural Steroid Injections for Treatment of Early and Late Recurrent Lumbar Disc Herniation

Utku ADILAY¹, Levent DENİZ², Muhammed Fatih SARI¹, Ahmet OZDEMİR¹, Salim KATAR¹, Bulent GUCLU³

¹Balikesir University, Faculty of Medicine, Department of Neurosurgery, Balikesir, Türkiye

²Marmara Pain Center, Neurosurgery Clinic, Bakirkoy, Istanbul, Türkiye

³Ministry of Health, Dr. Lutfi Kırdar Kartal City Hospital, Neurosurgery Clinic, Kartal, Istanbul, Türkiye

Corresponding author: Utku ADILAY ✉ utkuadilay@hotmail.com

ABSTRACT

AIM: To compare the results of fluoroscopically guided transforaminal epidural steroid injection (TESI) for pain reduction in ipsilateral early recurrent lumbar disc herniation (RLDH) with ipsilateral late RLDH.

MATERIAL and METHODS: A total of 738 patients complaining of radicular pain due to ipsilateral early and late RLDH were assessed. Of these, TESI was administered to 390 subjects for ipsilateral early RLDH and 346 for ipsilateral late RLDH. TESIs were performed based on radicular leg pain; all subjects were followed up and reexamined after 12 weeks of the therapy. Pre- and postprocedural visual analog scale (VAS) scores and all complications were recorded for the study.

RESULTS: For radicular pain, the mean pre-, and postprocedural VAS scores for ipsilateral early RLDH were 85.44 ± 6.85 and 20.16 ± 3.77 respectively. For late RLDH, the mean pre-, and postprocedural VAS scores were 72.82 ± 5.12 and 30.87 ± 4.17 , respectively. A significant statistical difference for pre- and postprocedural VAS scores were observed between ipsilateral early and late recurrent disc herniation TESI groups ($p < 0.05$).

CONCLUSION: TESI was more effective for early RLDH than for late RLDH during the 12-week follow-up period.

KEYWORDS: Intervertebral Disc Herniation, Epidural Steroid Injection, Recurrence, Outcome, Transforaminal

ABBREVIATIONS: RLDH: Recurrent lumbar disc herniation, TESI: Transforaminal epidural steroid injection, VAS: Visual analogue scale

INTRODUCTION

Recurrent lumbar disc herniation (RLDH) is the most frequently reported complication following primary open discectomy (15). The recurrence of a lumbar disc herniation may occur early or late after the initial surgery. In these cases, nerve root compression caused by lumbar disc herniation may elicit inflammatory responses (17, 18). Therefore, corticosteroid is administration to reduce inflammation and

pain. Under fluoroscopic guidance, a transforaminal epidural steroid injection (TESI) can offer robust levels of corticosteroids and other therapeutic reagents to the pathological sites (4). If correctly carried out, TESIs have been shown to be effective in the treatment of lumbar and radicular pain (1,6,21). A few studies have evaluated the efficacy of TESI in reducing radicular discomfort in RLDH patients (5,9,20). However, no study has yet compared the results of fluoroscopically guided TESI for pain reduction between ipsilateral early RLDH and

Utku ADILAY  : 0000-0003-4867-244X
Levent DENİZ  : 0000-0002-8648-1372
Muhammed Fatih SARI  : 0000-0001-7200-8915

Ahmet OZDEMİR  : 0000-0002-3939-8082
Salim KATAR  : 0000-0002-8311-1122
Bulent GUCLU  : 0000-0002-0012-5706

ipsilateral late RLDH. This report aimed to compare the results of fluoroscopically guided TESI for pain reduction between cases of ipsilateral early RLDH and ipsilateral late RLDH.

■ MATERIAL and METHODS

Patients

A total of 738 patients complaining of radicular pain due to ipsilateral early and late RLDH were included in this study. TESIs were carried out based on radicular leg pain, MRI affirmation of relevant ipsilateral RLDH, and a previous failed attempt to find relief through medical treatments and/or physical therapy. All subjects were followed up and reexamined after 12 weeks of therapy. Pre- and postprocedural VAS scores and all complications were recorded for further analyses.

The subject inclusion criteria were ipsilateral recurrent radicular pain following a pain-free period lasting for a minimum of 12 weeks following an initial single-level lumbar microsurgical discectomy, MRI affirmation of ipsilateral RLDH, a previous failed attempt to find relief through medical treatments and/or physical therapy, and a single TESI for RLDH. The subject exclusion criteria were unresolved radicular pain after initial lumbar disc surgery, ipsilateral recurrent radicular pain after a definite pain-free period within 3 months of initial surgery, contralateral RLDH, isthmic, or degenerative spondylolisthesis, midsagittal spinal canal diameter of <8 mm; sagittal vertebral translation of >3 mm, and an angulation on dynamic radiography of >10°; cauda equina syndrome; lumbar disc herniation in more than one level, and metabolic disorders including diabetes mellitus.

Neurologic deficit is not an exclusion criterion. If a patient has recurrent disc herniation and a new neurological deficit due to recurrence, we operated the patient microsurgically and did not perform TESI intervention in this patient. If a patient had a neurologic deficit before the recurrence of disc herniation, we performed TESI intervention to the patient.

All cases of ipsilateral RLDHS were classified into the following two groups: i) the ipsilateral early RLDH group—in which pain due to RLDH occurred in <12 months after the initial operation (Figure 1), and ii) the ipsilateral late RLDH group—in which pain due to RLDH occurred at least 12 months after the initial surgery (Figure 2).

MRI Data Analyses

All lumbar MRI acquisitions were made with 1.5-Tesla images. Radicular pain was associated with MR images collected at the engagement of the nerve root. Preprocedural MRIs were interpreted by an experienced radiologist blinded to the study. The criterion for ipsilateral RLDH was the occurrence of ipsilateral pain due to herniated lumbar disc, at least 3 months after the initial surgery. Not all patients received a postprocedural MRI.

Procedure

The subjects were first positioned in prone and then underwent TESI with aseptic technique. Briefly, a 1% lidocaine solution was administered at the insertion site. A 22-gauge Quincke spinal needle was inserted by using a preganglionic transforaminal method under fluoroscopy. Then, 1 mm of contrast media was administered to verify the epidural spread. Once determined, 3 mm of 0.33% lidocaine/4 mg dexamethasone were administered into the site (Figure 3). As dexamethasone was stored in glass ampules, the solution was prepared using a filter needle. All the patients were followed up for examination at 12 weeks post-procedure. Pre- and postprocedural radicular pain VAS (22) scores, as well as all complications, were recorded.

VAS Score Assessment

Pre- and postprocedural radicular pain mean VAS scores were determined for each patient. The VAS consists of a 10-cm line, with two end points representing 0 (“no pain”) and 10 (“pain as bad as it could possibly be”). However, in this study, to

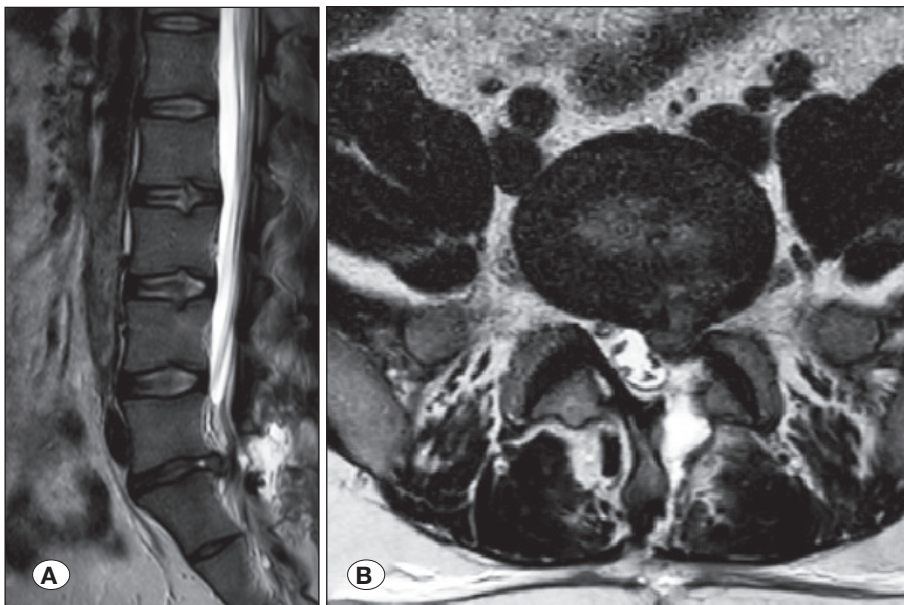


Figure 1: Early recurrent lumbar disc herniation; **A)** sagittal and **B)** axial T2W MRI scans of L5-S1 early recurrent disc herniation.

obtain a fine measurement, a horizontal scale was used to obtain VAS, where 0 = “no pain” and 100 mm = “severe pain”. Three different measures of self-rated radicular leg pain was used to obtain the mean VAS score: pain at present and the minimum and maximum pain levels over the past 3 days. Then, a mean VAS score was determined based on these measurements.

This retrospective study was approved by the Clinical Research Ethics Committee, Balikesir University Faculty of Medicine, Balikesir, Turkey (Decision No. 2023/65, Date: 10/05/2023). The recruitment for the study was only granted after informed consent was obtained from all patients. All patients were given information (both written and oral consultation) about

the treatment of pain due to RLDH with TESI. In addition, all patients were given details about the research design and study. The major presenting symptoms from the patients were leg and lower back pain. Before the procedure, the patients were administered NSAIDs or analgesics.

Statistical Analysis

Statistical analysis was performed using SPSS version 21.0. A paired sample t-test was applied for VAS and the repeated measure ANOVA test was performed to compare the outcomes of fluoroscopically guided TESI of ipsilateral early and late RLDH. $p < 0.05$ was considered to indicate statistical significance.

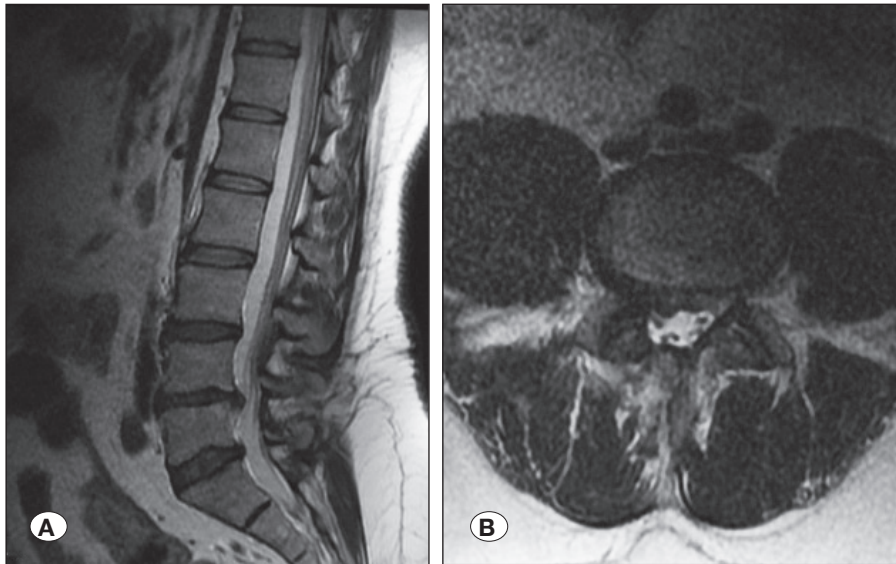


Figure 2: Late recurrent lumbar disc herniation: **A)** sagittal and **B)** axial MRI scans of L4-L5 recurrent disc herniation.

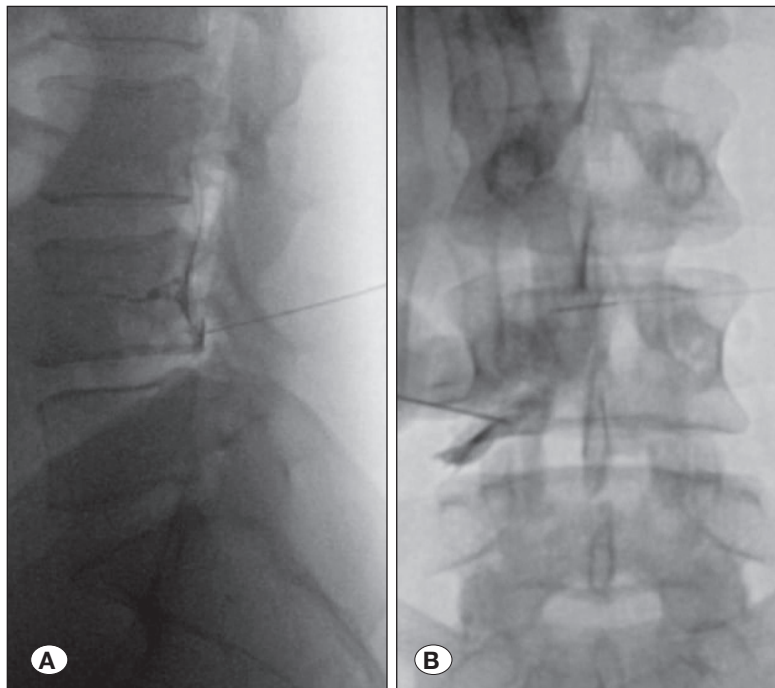


Figure 3: Lumbar transforaminal epidural steroid injection under C-arm guidance. **A)** Lateral view, **B)** anteroposterior view.

RESULTS

In this study of 738 patients (men: 407, women: 331; mean age: 41.5 ± 4.6 years, age range: 22–61 years, 392 subjects were administered TESI for ipsilateral early RLDH and 346 patients were treated for ipsilateral late RLDH. Four patients had ipsilateral RLDH at L2–L3, 11 at L3–L4, 392 at L4–L5, and 331 at L5–S1. All subjects were administered lumbar TESI. The mean duration between TESI and initial lumbar discectomy was 6.02 ± 1.13 (range: 3–12) months for the early RLDH group and 20.19 ± 3.22 (range: 12–49) months for the late RLDH group. The mean duration of ipsilateral recurrent radicular pain before TESI was 15.3 ± 2.7 (range: 1–63) days for the early RLDH group and 47.2 ± 7.8 (range: 1–75) days for the late RLDH group.

In terms of radicular pain, the mean pre-, and postprocedural VAS scores were 85.44 ± 6.85 and 20.16 ± 3.77 , respectively, for early RLDH, and 72.82 ± 5.12 and 30.87 ± 4.17 , respectively, for late RLDH. A significant statistical difference for pre- and postprocedural VAS scores were observed between the ipsilateral early and late RLDH TESI groups ($p < 0.05$) (Table I).

Of the 738 patients, 704 had no neurological deficit and 34 had some weakness in the legs or feet movements before TESI intervention. No major complications due to TESI intervention were recorded. There were 28 minor issues (3.8%) including infection in 5 patients, headache due to intradural injection and cerebrospinal fluid fistula in 9 patients, and temporary motor deficit in 14 patients. Only 17 subjects needed surgical intervention due to unremitting pain or increased neurological deficits.

DISCUSSION

RLDH is the most frequently reported complication following primary open discectomy (15). Oh et al. (16), and Lee et al. considered RLDH to be residual if it occurred within 6 months of the first surgery (12), whereas Leven et al. considered RLDH to be residual if it occurred within 6 weeks of the first surgery (13). Another study found that the time limit was unnecessary, and the emergence of complaints after a painless period was regarded to be recurrent (19). In this study, we considered recurrent pain due to lumbar disc herniation occurring within 3 months of the first surgery as residual; thus, we did not include these cases in the study. We also classified RLDH that returned within 12 months of the initial surgery as early RLDH. If herniation returned after 12 months, it was considered late RLDH. In addition, we excluded contralateral recurrent disc herniation from the study. In the literature, only a few articles have investigated the efficacy of TESI in reducing radicular pain in recurrent disc herniation patients (5,9,20). Our study's primary goal was to compare the effect of fluoroscopically guided TESI on radicular pain caused by ipsilateral early and late RLDH.

A steroid injection into the epidural space can reduce inflammation/pain in the affected nerve root. Steroids may be administered translaminal epidurally; however, the transforaminal method increases analgesic efficacy. The efficacy of this method may be linked to augmented steroid disbursement and/or enhanced contact with the root ventral side and the extruded disc. Different reports have demonstrated TESI efficacy for radicular pain treatment caused by lumbar disc herniation (1,2,3,7,8,10,14). However,

Table I: Demographic Features, the Level of Early and Late RLDH of TESI Patients and the Evaluation of the VAS Scores in Early and Late RLDH Patients Who Underwent Single Lumbar TESI

Gender	Patients (n=738)	Age of Patients
Male	407	41.5 (\pm 4.6 years) (ranged from 22-61)
Female	331	
Lumbar disc herniation level	Patients (n=738)	
L2-L3	4	
L3-L4	11	
L4-L5	392	
L5-S1	331	
Early recurrent lumbar disc herniation TESI patients (n=392)	The evaluation of the VAS scores	p-value
Before TESI	85.44 ± 6.85	0.001*
After TESI	20.16 ± 3.77	
Late recurrent lumbar disc herniation TESI patients (n=346)		
Before TESI	72.82 ± 5.12	
After TESI	30.87 ± 4.17	

TESI: Transforaminal epidural steroid injection, **VAS:** Visual analog scale, Paired sample *t* test, * $p < 0.05$, statistically significant.

TESI may not demonstrate similar levels of pain relief on each individual lumbar disc herniation types. To the best of our knowledge, no reports have compared the outcomes of fluoroscopically guided TESI for radicular pain caused by ipsilateral early and late RLDH. Thus, our study is the first to equate fluoroscopically guided TESI for the treatment of radicular pain in ipsilateral early and late RLDH.

The literature for radicular pain treatment using lumbar epidural spinal injections exhibits varying outcomes. The efficacy ranges from 0 to 100% and lasts nearly 3 months (11). In terms of radicular pain, the mean pre-, and postprocedural VAS scores were 85.44 ± 6.85 and 20.16 ± 3.77 for early RLDH and 72.82 ± 5.12 and 30.87 ± 4.17 for late RLDH, respectively. In a 12-week follow-up study, TESI for early RLDH was found to be more effective than late RLDH, possibly due to greater epidural fibrosis in late RLDH when equated with early RLDH.

Our study revealed that TESI was more effective for early RLDH than for late RLDH in a 12-week follow-up period. No study has yet compared the effect of TESI for early and late RLDH. The hypothesis and the reason for the effect of TESI for early RLDH more than for late RLDH are unclear. Epidural fibrosis is the excessive production of scar tissues near the nerve root. Epidural fibrosis occurs commonly after spinal surgery. Epidural fibrosis is a scar tissue that adheres to the nerve root during the months after surgery. In early times after lumbar disc surgery, there is no or less epidural fibrosis, and, as the time passes, epidural fibrosis increases. In early RLDH, there is little, or no epidural fibrosis, hence TESI may be more effective in reducing pain due to augmented steroid disbursement and/or enhanced contact with the root. However, in late RLDH, there is more epidural fibrosis than in early RLDH, and there is less steroid disbursement and/or enhanced contact with the root. We thus believe that the amount of epidural fibrosis effects the outcome of TESI.

In our research, no major complications were observed, and only 28 (3.8%) minor issues, including infection in 5 patients, headache caused by intradural injection and cerebrospinal fluid fistula in 9 patients, and temporary motor deficit in 14 patients, were noted. These findings indicate that TESI is a very safe procedure. Only 17 patients underwent surgery for unremitting pain or increased neurological deficits. Our research revealed that TESI was very helpful and safe in alleviating radicular pain in patients with RLDH. The strengths of our study include the large sample size and originality, and the limitations include the retrospective nature of the study, selection bias, and a single primary outcome.

CONCLUSION

RLDH can cause severe pain, and the relief of this pain through conservative treatment may not be adequate to reduce the pain levels. Surgery should be the last resort for treatment of patients with recurrent lumbar herniation. TESI is a safe method and an alternative for patients with recurrent lumbar disc herniation to alleviate radicular pain. The present findings support that TESI was more effective for early RLDH than late recurrent lumbar disc herniation in a 12-week follow-up period.

AUTHORSHIP CONTRIBUTION

Study conception and design: UA, LD, SK

Data collection: LD, AÖ

Analysis and interpretation of results: UA, BG, AÖ

Draft manuscript preparation: MFS, UA, SK

Critical revision of the article: BG,UA

All authors (UA, LD, MFS, AO, SK, BG) reviewed the results and approved the final version of the manuscript.

REFERENCES

- Adilay HU, Guclu B, Deniz L, Kahveci R: Comparison of the effect of single lumbar transforaminal epidural steroid injections for the treatment of L4-5 and L5-S1 paramedian disc herniation. *Turk Neurosurg* 29:279-284, 2019. <https://doi.org/10.5137/1019-5149.JTN.24029-18.1>
- Bhatia A, Flamer D, Shah PS, Cohen SP: Transforaminal epidural steroid injections for treating lumbosacral radicular pain from herniated intervertebral discs: A systematic review and meta-analysis. *Anesthesia&Analgesia* 122:857-870, 2016. <https://doi.org/10.1213/ANE.0000000000001155>
- Byun JM, Park HS, Woo JH, Kim J: The effects of a forceful transforaminal epidural steroid injection on radicular pain: A preliminary study. *Korean J Pain* 27:334-338, 2014. <https://doi.org/10.3344/kjp.2014.27.4.334>
- Derby R, Kine G, Saal JA, Reynolds J, Goldthwaite N, White AH, Zucherman J: Response steroid and duration of radicular pain as predictors of surgical outcome. *Spine* 17:176-183, 1992. <https://doi.org/10.1097/00007632-199206001-00020>
- Evrans S: The efficacy of transforaminal epidural steroid injection (TFESI) in single level lumbar disc herniation. *J Turkish Spinal Surg* 30:41-46, 2019
- Ghahreman A, Ferch R, Bogduk N: The efficacy of transforaminal injection of steroids for the treatment of lumbar radicular pain. *Pain Medicine* 11:1149-1168, 2010. <https://doi.org/10.1111/j.1526-4637.2010.00908.x>
- Guclu B, Deniz L, Katar S, Ozdemir A: Optimal timing and outcome of transforaminal epidural steroid injection for the management of radicular pain due to extruded lumbar disc herniation. *Turk Neurosurg* 33:509-513, 2023. <https://doi.org/10.5137/1019-5149.JTN.43361-23.4>
- Guclu B, Deniz L, Yuca Y, Adilay HU, Aytar H, Turkoglu M, Tiryaki M, Ozdek R, Boran BO: Transforaminal epidural steroid injection in the treatment of pain in foraminal and paramedian lumbar disc herniations. *Turk Neurosurg* 30:394-399, 2020. <https://doi.org/10.5137/1019-5149.JTN.27220-19.3>
- Karamouzian S, Ebrahimi-Nejad A, Shahsavarani S, Keikhosravi E, Shahba M, Ebrahimi F: Comparison of two methods of epidural steroid injection in the treatment of recurrent lumbar disc herniation. *Asian Spine J* 8:646-652, 2014. <https://doi.org/10.4184/asj.2014.8.5.646>
- Kawada T: Lumbar transforaminal epidural steroid injection in patients with chronic unilateral radicular pain. *Am J Physical Med Rehabil* 97:e17, 2018. <https://doi.org/10.1097/PHM.0000000000000869>

11. Kennedy DJ, Dreyfuss P, Aprill CN, Bogduk N: Paraplegia follow image-guided transforaminal lumbar spine epidural steroid injection: Two case reports. *Pain Med* 10:1389-1394, 2009. <https://doi.org/10.1111/j.1526-4637.2009.00728.x>
12. Lee JK, Amorosa L, Cho SK, Weidenbaum M, Kim Y: Recurrent lumbar disk herniation. *JAAOS* 18:327-337, 2010. <https://doi.org/10.5435/00124635-201006000-00005>
13. Leven D, Passias PG, Errico TJ, Lafage V, Bianco K, Lee A, Lurie JD, Tosteson TD, Zhao W, Spratt KF, Morgan TS, Gerling MC: Risk factors for reoperation in patients treated surgically for intervertebral disc herniation: A subanalysis of eight-year SPORT data. *J Bone Joint Surg* 97:1316-1325, 2015. <https://doi.org/10.2106/JBJS.N.01287>
14. Manchikanti L: Role of neuraxial steroids in interventional pain management. *Pain Physician* 5:182-199, 2002. <https://doi.org/10.36076/ppj.2002/5/182>
15. Mariscal G, Torres E, Barrios C: Incidence of recurrent lumbar disc herniation: A narrative review. *J Craniovertebr Junction Spine* 13:110-113, 2022. https://doi.org/10.4103/jcvjs.jcvjs_38_22
16. Oh JT, Park KS, Jung SS, Chung SY, Kim SM, Park MS, Kim HK: Surgical results and risk factors for recurrence of lumbar disc herniation. *Korean J Spine* 9:170-175, 2012. <https://doi.org/10.14245/kjs.2012.9.3.170>
17. Olmarker K, Störkson R, Berge OG: Pathogenesis of sciatic pain: A study of spontaneous behavior in rats exposed to experimental disc herniation. *Spine* 27:1312-1317, 2002. <https://doi.org/10.1097/00007632-200206150-00013>
18. Saal JS: The role of inflammation in lumbar pain. *Spine* 20:1821-1827, 1995. <https://doi.org/10.1097/00007632-199508150-00013>
19. Shin BJ: Risk factors for recurrent lumbar disc herniations. *Asian Spine J* 8:211-215, 2014. <https://doi.org/10.4184/asj.2014.8.2.211>
20. Um MK, Lee E, Lee JW, Kang Y, Ahn JM, Kang HS: Fluoroscopic lumbar transforaminal epiduralsteroid injections for recurrent herniated intervertebral disc after discectomy: Effectiveness and outcome predictors. *Plos One* 17:e0271054, 2022. <https://doi.org/10.1371/journal.pone.0271054>
21. Vad VB, Bhat AL, Lutz GE, Cammisa F: Transforaminal epidural steroid injections in lumbosacral radiculopathy: A prospective randomized study. *Spine* 27:11-15, 2002. <https://doi.org/10.1097/00007632-200201010-00005>
22. Wewers ME, Lowe NK: A critical review of visual analogue scales in the measurement of clinical phenomena. *Res Nurs Health* 13:227-236, 1990. <https://doi.org/10.1002/nur.4770130405>