

Mutism After Total Removal Of Medulloblastoma: Case Report

MÜFİT KALELİOĞLU, NEJAT IŞIK, NİHAL IŞIK, MERCAN SARIER

Göztepe Social Security Hospital Neurosurgery. (MK, NI, MS) and Neurology (NI) Clinics İstanbul -Türkiye

Abstract : Mutism without any disorder of consciousness level and or cranial deficit following posterior fossa surgery is not common and there is no definitive aetiological hypothesis. Here we report a case of mutism in a 6-year- old patient after total removal of a posterior fossa medulloblastoma. Mutism was noted

immediately after the operation and resolved after four months. The literature is reviewed and possible mechanisms of cerebellar mutism are discussed.

Key Words : Medulloblastoma, Mutism, Posterior fossa surgery

INTRODUCTION

Speech disorders occur frequently following posterior fossa surgery (2,10). Mutism is the total absence of speech in an awake patient (2,3,10), but mutism without any disorder of consciousness level and or cranial nerve deficit after posterior fossa surgery is not common. Reketa reported six cases of mutism of cerebellar origin in 1985 (13), and recently cerebellar mutism cases have been reported in increasing numbers (1,4,5,9,11,12,13,14). All the reported patients were fully alert and had neither lower cranial nerve deficits nor midbrain compression. Radiological and surgically the majority had large tumours arising from the fourth ventricle.

We present a case of a fourth ventricle medulloblastoma in a six-year-old child who, immediately after surgery developed mutism, lasting four months.

Case:

U.K., a six-year- old boy who presented with a six-month history of headache, vomiting and ataxia was admitted to hospital. He had bilateral

papilloedema and horizontal nystagmus. At cerebellar examination, bilateral clumsiness was noted and ataxia. Cranial CT and MRI showed hydrocephalus and a solid contrast enhancing neoplastic mass of 5x5x4 cm filling the fourth ventricle (Fig. 1).

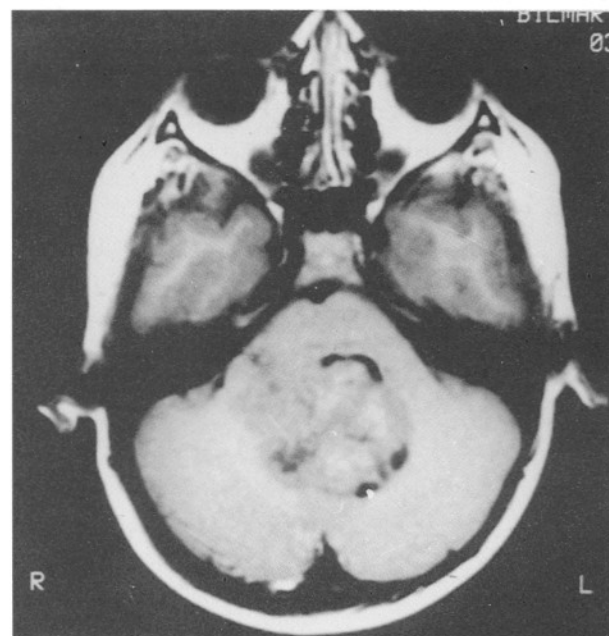


Fig. 1 : MRI showing a large midline tumour

Operation: A posterior fossa exploration was performed in the supine position with suboccipital craniectomy and C1 laminectomy. The fourth ventricle was reached by splitting the inferior vermis and a gray-purple coloured tumoral mass was found and excised totally. There was no abnormality in the aqueductus sylvii or periaqueductal region and CSF circulation was re-established. Histopathological examination of the tumour revealed medulloblastoma.

Clinical evaluation: In the early postoperative state, it was noted that the patient was not speaking and his relations with the environment were diminishing. A cranial CT showed no abnormalities except a slight hydrocephalic brain. Ventricular drainage was performed through the existing burr-hole and anti-oedematous therapy was maintained. The patient was not discharged because of the mutism state and was admitted for radiotherapy but no chemotherapy was used. The mutism lasted for one-and-a-half months when speech began to be reestablished, with single words increasing day by day. In the fourth month speech was reestablished. Cranial CT and MRI performed 18 months later showed no recurrence, there was no hydrocephalus and neurological examination was almost normal (Fig. 2).

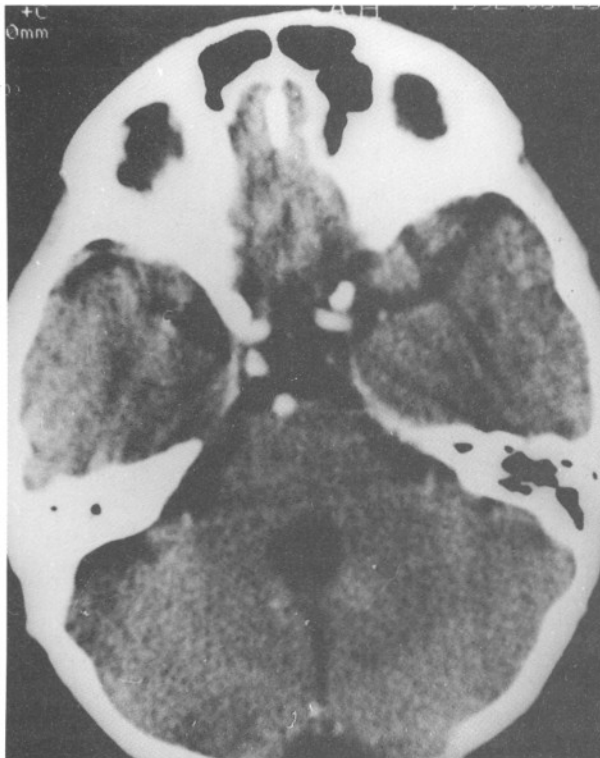


Fig. 2 : after tumour excision, there is no residual tumour. the 4th ventricle is dilated and the aqueductus sylvii seems to be open.

DISCUSSION

Speech disorder without loss of consciousness is defined as mutism (2,3). Benson and other authors reported six organic reasons for speech disorder: 1. Lesion of the broca area, 2. Lesion of the supplementary region of the dominant hemisphere, 3. Lesion of the reticular formation in the mesencephalon (Akinetic mutism), 4. Pseudobullar paralysis, 5. Bilateral thalamotomy performed for Parkinson's disease, 6. Bilateral sharyngeal or vocal cord paralysis (2,5,13). Five of the these are of central nervous system origin as the sixth. In 1985, Rekata added mutism of cerebellar origin as the sixth reason (4). To date, 24 similar cases have been reported in the literature (1,5,9,11,12,14) (Table I). In all cases there

Table I : Summary of 24 reported cases of cerebellar mutism

Authors	Year	Case Number	Histopathology	Mutism Duration
Reketa	1985	6	Medulloblastoma (4) Cystic Astrocytoma (1) Ependymoma (1)	4 days-12 weeks
Yonemasu	1985	4	Medulloblastoma (2) Ependymoma (2)	4-12 weeks
Humphrey	1988	5	Medulloblastoma (3) Ependymoma (1) Fibrillar Astrocytoma (1)	7-12 weeks
Ammiratti	1989	1	Low Gr. Astrocytoma	3-12 weeks
Ferante	1990	3	Pilocytic Astrocytoma	8 days
Nagatani	1991	1	Medulloblastoma	78 days
Dietze	1991	1	AVM Medulloblastoma	0-12 weeks
Salvatti	1991	1	Medulloblastoma	
Özek	1991	1	Pontin Glioma	12 weeks

were no cranial nerve deficits, no end organ lesions and no consciousness problems, as in our case. It was Hirsche who for the first time underlined the existence of mutism in children who underwent cerebellum or fourth ventricle operations (8). Possible reasons for mutism following posterior fossa operations are: 1 - Severe damage to the cerebellar parenchyma, 2 - Cerebrovascular disorder (ischaemic origin such as occlusion of the mesencephalic artery or oedema), 3 - CSF circulation disorder, 4 - Postoperative meningitis (1,5,9,13,15). The majority of cases are large tumours with midline localization. This fact supports the aetiological hypothesis that

mutism occurs as a consequence of oedema and ischaemia due to bilateral ecartion of the cerebellum. The duration of hydrocephalus in some cases may be another explanation. The development of postoperative meningitis among 6 reported cases might explain the occurrence of mutism but in the majority of cases mutism was not observed very early in the postoperative stage (5,9,13). Excessive stretching of deep cerebellar nuclei may also contribute to mutism. Fraoli and Guidetti observed total speech disorders when trying to treat spasticity by stereotaxic lesions of the dentate nucleus of the cerebellum (6,7). In the majority of cases, ischaemia, oedema and adhesions due to excessive ecartation may be the most important causes of mutism. For this reason one should abstain from ecartation that may cause excessive stretching during the operation and avoid postoperative oedema, hydrocephalus and meningitis in order to diminish the risk of mutism.

Correspondence : Dr. Nejat Işık

Tuğlacıbaşı Çıkma Sokak Çamlık Apt.

No: 10/11 Feneryolu (81040) İstanbul-Türkiye

Tel : 0.216.338 07 34

Fax : SSK Göztepe Hastanesi 0.216.350 12 45

REFERENCES

1. Ammiratti M, Mirazi S, Samii M: Transient mutism following removal of a cerebellar medulloblastoma. Childs Nerv Syst 5:12-14, 1989.
2. Benson D.F.: Aphasia, Alexia and Agraphia. New York: Churchill Livingstone. 1979:163-164.
3. Brain WR: Speech disorder, Aphasia, Apraxia and Agnosia, ed 2. London: Butterworths: 1965:1-121.
4. Dietze DD, Mickle JP: Cerebellar mutism after posterior fossa surgery. Pediatric Neurosurgery 16(1):25-31, 1991.
5. Ferrante L, Mastronardi L, Acoui M, Fortuna A: Mutism after posterior fossa surgery in children. J. Neurosurgery 72:959-963, 1990.
6. Fraoli B, Guidetti B: Effects of stereotactic lesions of dentate nucleus of the cerebellum in man. Appl. Neurophysiol 38:81-90, 1975.
7. Guidetti B, Fraoli B: Neurosurgical treatment of spasticity and dyskinesias. Acta Neurochir Suppl 24:24-39, 1977.
8. Hirsch JP, Renier D, Czernichow P, Benveniste L, Pierre-Kahn A: Medulloblastoma in childhood. Survival and functional results. Acta Neurochir 48:1-15, 1979.
9. Humphreys RP: Mutism after posterior fossa surgery, in Marlin AE (ed): Concepts in Pediatric Neurosurgery Vol 9. Basel Karger. 1989:57-64.
10. Lechtenberg R, Gilman S: Speech disorders in cerebellar disease. Ann Neurol 3:285-290, 1978.
11. Nagatani K, Waga S, Nagawaka Y: Mutism after removal of a vermian medulloblastoma: Cerebellar mutism. Surg. Neurol 36:307-309, 1991.
12. Özek MM, Pamir MN, Alptekin B: Mutism after removal of pontine gliomas. Turkish Neurosurgery 3:37-39, 1993.
13. Reketa HL, Grubb RL, Aram DM, Hahn JF, Ratcheson RA: Muteness of cerebellar origin. Arch. Neurol 42:697-698, 1985.
14. Salvati M, Missori P, Lunardi P, Orlando ER: Transient cerebellar mutism after posterior cranial fossa surgery in adult. Clin Neurol. Neurosurgery 93(4):313-316, 1991.
15. Segarra JM: Cerebral vascular disease and behavior. I. The syndrome of the mesencephalic artery (basilar bifurcation). Arch. Neuro 22:408-418, 1970.