



# A Comprehensive Computed Tomographic Analysis of Pneumatization Pattern of Sphenoid Sinus and Their Association with Protrusion/Dehiscence of Vital Neurovascular Structure in a Pakistani Subgroup

Asma AIJAZ<sup>1</sup>, Hira AHMED<sup>1</sup>, Shazia FAHMI<sup>1</sup>, Talat SAMREEN<sup>1</sup>, Biinish RASHEED<sup>2</sup>, Hina JABEEN<sup>3</sup>

<sup>1</sup>Karachi Medical and Dental College, Department of Anatomy, Karachi, Pakistan

<sup>2</sup>Dow University of Health Sciences, Department of Radiology, Karachi, Pakistan

<sup>3</sup>Dow University of Health Sciences, Department of Anatomy, Karachi, Pakistan

Corresponding author: Asma AIJAZ ✉ asmafkh83@gmail.com

## ABSTRACT

**AIM:** To determine the clinically significant association between pneumatization types of the sphenoid sinus (SS) and protrusion/dehiscence of the optic nerve (ON) and the internal carotid artery (ICA).

**MATERIAL and METHODS:** This prospective cross-sectional study was conducted between November 2020 and April 2021 at the Dow Institute of Radiology, Dow University of Health Sciences, Karachi. This study examined 300 computed tomography (CT) PNS patients aged 18–60 years. The forms of SS pneumatization, extent of pneumatization to the greater wing (GW), anterior clinoid process (ACP), and pterygoid process (PP), as well as the protrusion/dehiscence of the ON and ICA were examined. A statistical relationship was identified between pneumatization type and protrusion/dehiscence of the ON and ICA.

**RESULTS:** The study included 171 men and 129 women with an average age of  $39.28 \pm 10.9$  years. The most commonly encountered pneumatization type was postsellar (63.3%), followed by sellar (27.3%), presellar (8.7%), and conchal (0.75%). The most frequent extended pneumatization was observed up to PP (44%), followed by ACP (31.33%), and GW (16.67%). The rate of dehiscence of the ON and ICA was less than that of protrusion of the same structures. The association between postsellar and sellar pneumatization types and protrusion of the ON and ICA was statistically significant ( $p < 0.001$ ), with the postsellar type showing more protrusions of the ON and ICA than the sellar type.

**CONCLUSION:** The pneumatization type of SS has a significant impact on the protrusion/dehiscence of adjacent vital neurovascular structures and should be mentioned in CT reports to alert surgeons for any disastrous intraoperative complications and outcomes.

**KEYWORDS:** Optic nerve, Internal carotid artery, Pneumatization, Dehiscence, Protrusion

**ABBREVIATIONS:** **SS:** Sphenoid sinus, **ON:** Optic nerve, **ICA:** Internal carotid artery, **ACP:** Anterior clinoid process, **PP:** Pterygoid process, **GW:** Greater wing, **ST:** Sella turcica, **ETS:** Endoscopic trans-sphenoidal surgery, **CT:** Computed tomography

Asma AIJAZ : 0000-0003-3509-3115  
Hira AHMED : 0000-0002-4077-4620  
Shazia FAHMI : 0000-0002-8453-6720

Talat SAMREEN : 0000-0003-4846-9804  
Biinish RASHEED : 0000-0002-8894-3729  
Hina JABEEN : 0000-0002-5100-0073

## ■ INTRODUCTION

The sphenoid bone in the middle of the skull contains the sphenoid sinus (SS). It is regarded as the human body cavity with the highest diversity (34). Its high divergence is caused by the variability in its pneumatization pattern and interactions with nearby critical neurovascular structures, such as the internal carotid artery (ICA) and optic nerve (ON) (6,17). These neurovascular structures either protrude into the sinus cavity or their bony coverings may undergo dehiscence depending upon the degree of pneumatization (36). These variations place these structures at risk of injury during surgical procedures, resulting in life-threatening complications such as ICA injury, hypothalamic injury, meningitis, CSF leakage, visual deficit, or complete blindness (3,7). Excessive solicitude must be exerted during sellar opening to avoid damage to the neurovascular structures (30,31). It is mandatory to carefully analyze SS anatomical variations and their relationship with the surrounding neurovascular structures on preoperative computed tomography (CT) scans to minimize possible iatrogenic injuries during endoscopic trans-sphenoidal surgical (ETS) procedures (35).

Pneumatization of SS can be minimal or substantial (18). It may extend into the basisphenoid, anterior clinoid process (ACP), greater wing (GW), pterygoid process (PP), and vomer bones, in addition to the sphenoid bone (11,38). Increases in protrusion and dehiscence of the ON and ICA into the sinus cavity are directly correlated with increases in the degree of pneumatization. Therefore, a thorough CT sinus investigation is essential for a better understanding of the SS architecture and to determine how SS pneumatization affects the protrusion or dehiscence of neighboring key neurovascular structures (15).

Radiographic CT scans and ETS are currently the choice of radiological diagnosis and treatment for various pathologies of the hypophysis cerebri (9). The extended trans-sphenoidal approach permits surgical access to a wide area of the skull base, including the suprasellar and parasellar regions (2,23), floor of the middle cranial fossa (12), and apex of the petrous temporal bone (38,39). Hence, a comprehensive CT sinus examination would be helpful in planning the safest route to SS and the success of endoscopic sinus surgeries (32).

In various populations, SS and its surrounding components have distinct anatomical configurations (7,15,17,19,29-34). A local study highlighted the pneumatization patterns of SS (5). Accounts on the relationship between SS pneumatization types, protrusion/dehiscence of ON and ICA, and extent of pneumatization in the Pakistani population are scarce. This study aimed to show the substantial association between anatomical variations of the SS, which offers valuable knowledge to the area of ETS and is extremely important in preoperative risk assessment prior to sinus procedures.

## ■ MATERIAL and METHODS

This cross-sectional study was performed at the Dow Institute of Radiology, Dow University of Health Sciences, Karachi, from November 2020 to March 2021, with institutional review board permission (Ref: IRB-1766/DUHS/ 13<sup>th</sup> October 2020).

## Study Population

The research included 300 individuals (age 18–60 years) with absent bony pathology of SS. Individuals with nasal polyps, nasal and PNS tumors, diseases causing bony deformity of the SS, surgical intervention around the nose, and prior history of nasal trauma were excluded.

## CT Protocol

CT PNS was performed using the General Electric Healthcare Computed Tomography Optima 660 system after obtaining informed consent. The departmental protocol was followed to perform the scans using a 3-mm slice thickness, beam collimation setting of 20 mm, and currents of 60–220 mA in both bony and soft tissue algorithms. RadiAnt DICOM software was used to construct multiplanar reconstructions, and coronal and sagittal images were obtained. A consultant radiologist performed a thorough study of the CT images, and departmental consultations were conducted to resolve any query.

## Study Variables

The CT scans were examined in detail for pneumatization types, extent of pneumatization into ACP, GW, and PP, as well as the protrusion and dehiscence of the ON and ICA. The sinus was classified into four types according to the Guldner classification to determine the pneumatization type of the SS (17). In type I (Conchal), there is absent or minimal SS in which the sinus is separated from the sella turcica (ST) by approximately 10 mm mass of cancellous bone. Type II (Presellar) encompasses the posterior sinus wall in front of the anterior wall of the ST. Type III (Sellar) has a posterior sinus wall located midway between the anterior and posterior walls of the ST. In type IV (Postsellar), the posterior wall of the SS is situated behind the posterior wall of the ST (32).

To ascertain the degree of pneumatization to the ACP, PP, and GW, the following criteria were carefully evaluated. Pneumatization extending beyond the horizontal plane and into the ACP is known as ACP pneumatization. PP pneumatization was described as pneumatization extending beyond the horizontal plane crossing the vidian canal. GW pneumatization was defined as pneumatization extending beyond the vertical plane and passing through the foramen rotundum (32).

To assess the protrusion/dehiscence of the ON and ICA, protrusion was defined as a slight indentation to the presence of more than 50% of the structure's circumference in the sinus cavity (31,36), whereas dehiscence was defined as the absence of visible bony density separating the structure from the sinus (19,32).

Finally, the relationships between pneumatization types of SS, extent of pneumatization, and protrusion or dehiscence of the ON and ICA were analyzed.

## Statistical Analysis

Quantitative variables, such as mean age and standard deviation, were determined. For qualitative variables such as pneumatization type, extent of pneumatization, and protrusion/dehiscence of ON and ICA, frequencies and percentages were

computed. The chi-square test was used to determine the frequencies of anatomical variants. Spearman correlation was used to determine the strength of the association between the extent of pneumatization and protrusion/dehiscence of the ON and ICA. Statistical significance was set at  $p \leq 0.05$ . The data were analyzed using GraphPad Prism 9.

**RESULTS**

There were 300 adult patients with a mean age of  $39.28 \pm 10.99$  years. The proportion of men was 171/300 (57%) and that of women was 129/300 (43%).

**Pneumatization Types of SS**

The most frequent pneumatization pattern was the postsellar type in 190 (63.3%) patients, followed by sellar pneumatization in 82 patients (27.3%), presellar pneumatization in 26 patients (8.7%), and conchal pneumatization in 2 patients (0.7%) (Figure 1).

**Protrusion/Dehiscence of ON and ICA**

We found ICA and ON protrusions in 147 (49%) and 114 (38%) SS patients, respectively, and dehiscence in 28 (9.3%) and 48 (16%) SS patients, respectively, which are quite high, as reported in previous studies (Table I).

**ACP, GW and PP Pneumatization Extent**

The divergent pattern of pneumatization was seen in 92% of patients, with PP pneumatization in 44%, ACP pneumatization in 31.33%, and GW pneumatization in 16.67% (Table I).

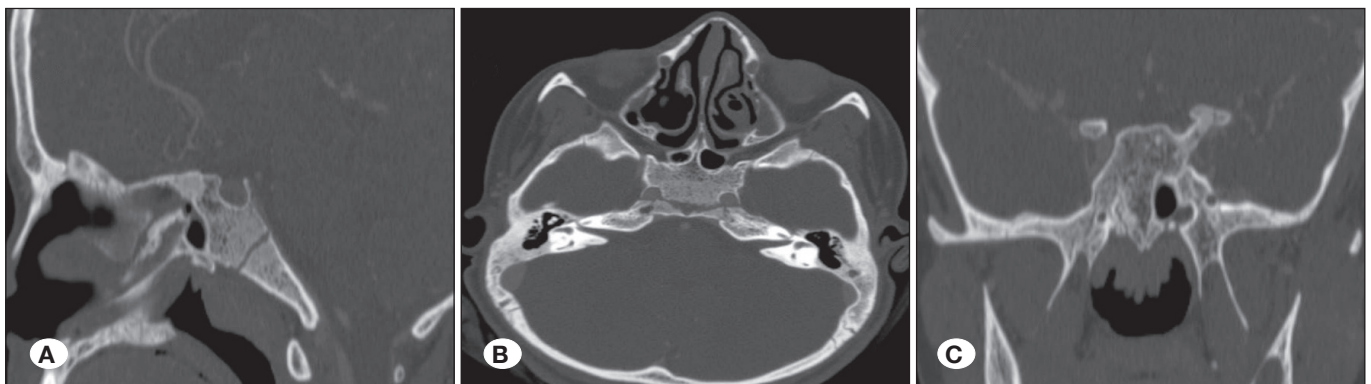
**Association Between SS Pneumatization Types with ON and ICA Protrusion/Dehiscence**

The pneumatization type of SS depends on the existence of bony protrusions and dehiscence of adjacent neurovascular structures. As pneumatization expands in the sellar and postsellar types, the bony protrusion of the ON and ICA also increases ( $p=0.001$ ,  $p \leq 0.001$  respectively) (Table II). The conchal type does not show any protrusion/dehiscence as the size of the sinus cavity is minimal or absent. In our study, no neurovascular protrusion/dehiscence of the ON or ICA was observed in the presellar pneumatization type (Figure 2). The patients with the postsellar type (Figure 3) showed the greatest number of protrusions as well as dehiscence of both the ICA and ON as compared to the sellar type (Figure 4). The ICA protruded unilaterally in 63 (21%) postsellar patients and bilaterally in 61 (20.34%) patients, followed by the sellar type, in which unilateral protrusion of the ICA was seen in 20 (6.67%) and bilateral protrusion in three (0.99%) patients, which was less than that in postsellar pneumatization. Similar results were observed for ON (Table II).

**Table I:** Frequency of Anatomical Variations of Sphenoid Sinus Seen on Computed Tomography

		Unilateral n (%)	Bilateral n (%)	Total n (%)
Extent of Pneumatization	ACP	54 (18.0)	40 (13.3)	94 (31.3)
	GW	18 (6.0)	32 (10.67)	50 (16.67)
	PP	60 (20.0)	72 (24.0)	132 (44.0)
Protrusion	ON	77 (25.67)	37 (12.34)	114 (38.0)
	ICA	83 (27.67)	64 (21.34)	147 (49.0)
Dehiscence	ON	42 (14.0)	6 (2.0)	48 (16.0)
	ICA	27 (9.0)	1 (0.3)	28 (9.30)

ACP: Anterior clinoid process, GW: Greater wing, PP: Pterygoid process, ON: Optic nerve, ICA: Internal carotid artery.

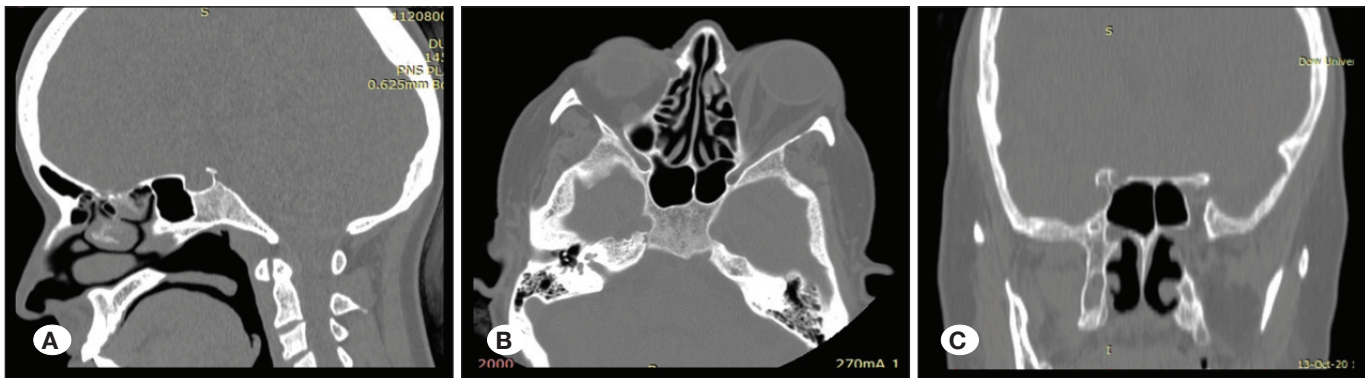


**Figure 1:** A) Sagittal CT image of sphenoid sinus shows conchal type of pneumatization. B) Axial CT image with minimal sinus cavity and no protrusion/dehiscence of ON and ICA. C) Coronal CT image with minimal sinus cavity and without any protrusion/dehiscence of ON and ICA. ON: Optic nerve, ICA: Internal carotid artery.

**Table II:** Statistical Association Between the Bony Protrusion and Dehiscence of on and ICA with Pneumatization Types of Sphenoid Sinus

		Pneumatization Types			p value	
		Sellar n (%)	Postsellar n (%)	Total n (%)		
Protrusion	ON	Unilateral	19 (6.34)	58 (19.33)	77 (25.67)	0.001*
		Bilateral	7 (2.3)	30 (10.04)		
	ICA	Unilateral	20 (6.67)	63 (21.0)	83 (27.67)	
		Bilateral	3 (0.99)	61 (20.34)	64 (21.33)	
Dehiscence	ON	Unilateral	6 (2.0)	36 (12.0)	42 (14.0)	0.059
		Bilateral	0	6 (2.0)	6 (2.0)	
	ICA	Unilateral	2 (0.6)	25 (8.4)	27 (9.0)	0.134
		Bilateral	1 (0.3)	0	1 (0.3)	

Results are expressed as number and frequency. \*: p-value ≤0.05 was considered significant. **ON:** Optic nerve, **ICA:** Internal carotid artery.



**Figure 2:** A) Sagittal CT image of sphenoid sinus shows presellar type of pneumatization. B) Axial CT with no protrusion/dehiscence of ON and ICA. C) Coronal CT image without any protrusion/dehiscence of ON and ICA. **ON:** Optic nerve, **ICA:** Internal carotid artery.

**Association Between Protrusion/Dehiscence of ON and ICA with Pneumatization Extent**

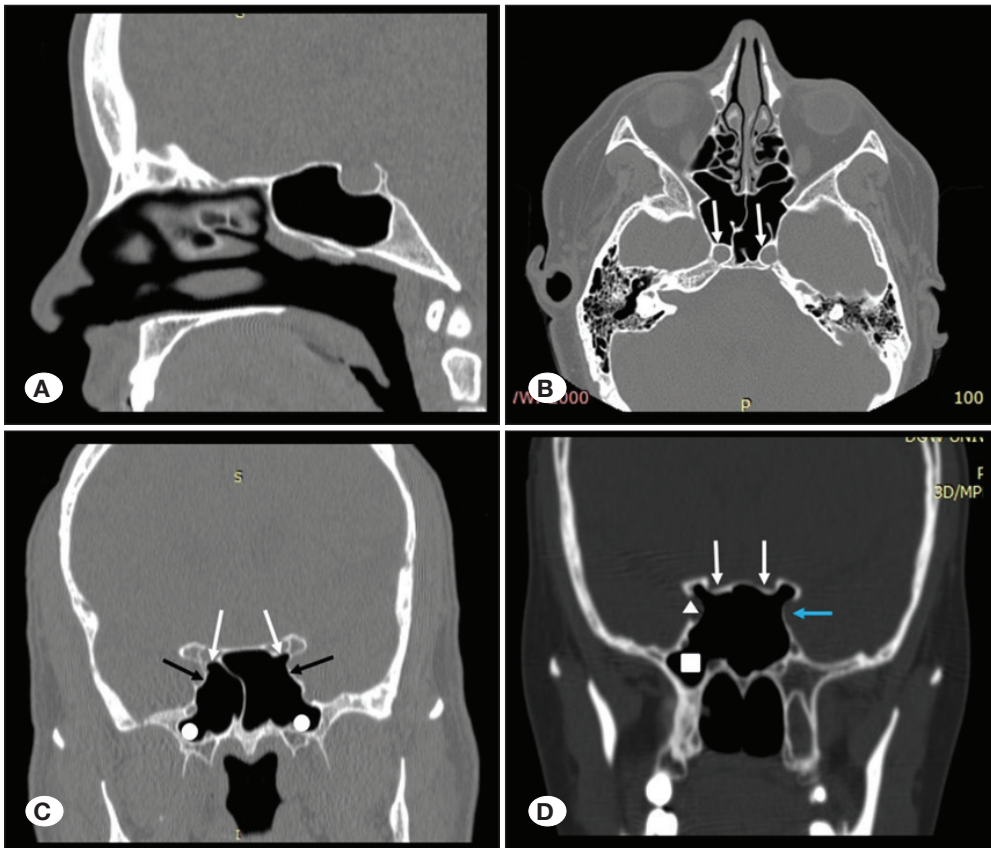
A significant relationship was observed between ACP pneumatization and ON/ICA protrusion, PP pneumatization and ON/ICA protrusion, and GW pneumatization and ON/ICA protrusion (Table III). The association was also significant between ON/ICA dehiscence and pneumatization of ACP and between GW pneumatization and ON dehiscence. The larger the value of the contingency coefficient (CC), the greater the degree of association. However, no association was observed between ON/ICA dehiscence and PP pneumatization or GW pneumatization versus ICA dehiscence (Table II).

**DISCUSSION**

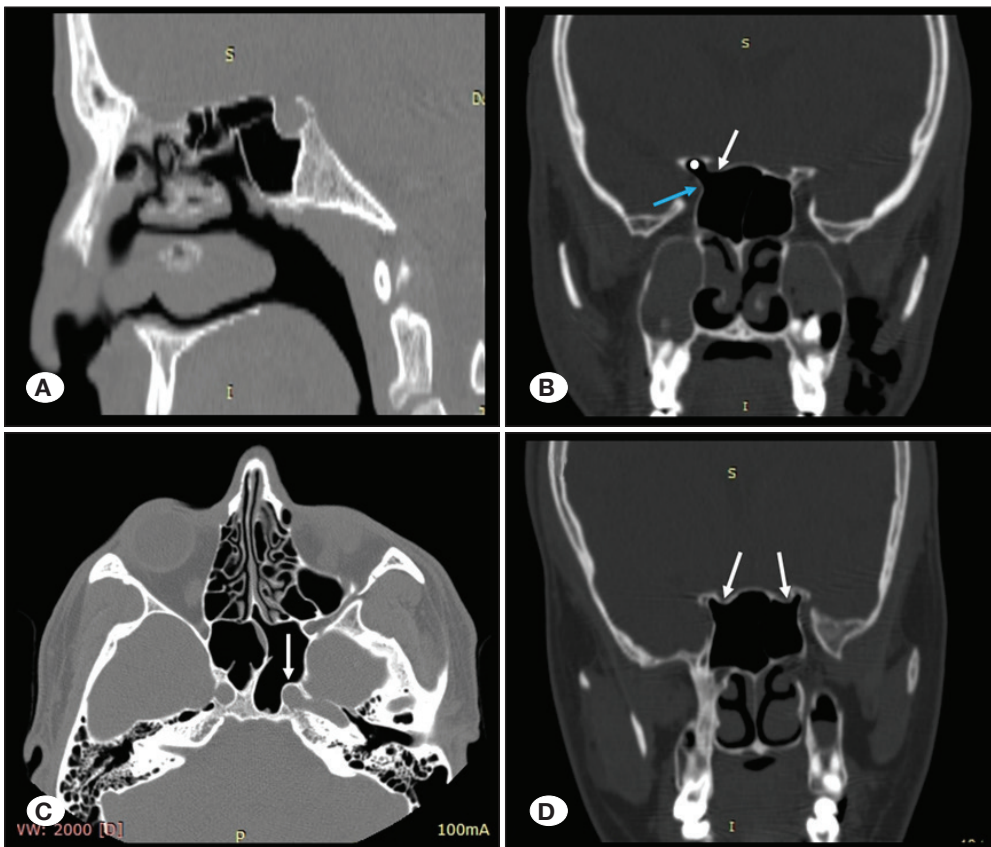
Comprehensive knowledge of the anatomical variants of SS is important for planning the safest surgical route for ETS to reach the pituitary gland. In addition, preoperative evaluation of all these variations is critical in various skull base surgeries. The pneumatization type of SS has an impact on the bony protrusion of vital neurovascular structures, such as the ON

and ICA, into the sinus cavity. As pneumatization increases, the bony protrusion and dehiscence of the ON and ICA also increase; hence, the probability of iatrogenic injury to these vital structures is greatly increased. Considering the importance of sinus variations, this study has objectively analyzed not only the overall protrusion/dehiscence, but also the individualized relationship of bony protrusion/dehiscence of the ON and ICA based on the type of SS that has great significance in preoperative risk assessment before sinus surgeries. The aim of this study was to guide radiologists in easily identifying the risk of bony protrusion/dehiscence of the ON and ICA.

It has been observed that ethno-geographical diversity could be reason for certain anatomical variations in the sinus (3,31); likewise a subset of Pakistani population is observed to have many variations in pneumatization pattern and other anatomical variants of SS. In our study, the majority (192; 63.3%) of the patients had postsellar pneumatization, followed by sellar (82; 27.3%) and presellar (26; 8.7%) types. The conchal type was observed in two patients only. The results concur with the prevalence of the postsellar type in Americans (54%), Iranians (83.5%), Brazilians (63%), Turkish



**Figure 3:** **A)** Sagittal CT image shows postsellar pneumatization of sphenoid sinus. **B)** Axial CT image shows bilateral protrusion of ICA (white arrows). **C)** Coronal CT section shows bilateral protrusion of ON (white arrows) with right ON septal insertion, bilateral protrusion of ICA (black arrows), bilateral pneumatization of GW and PP (white circles). **D)** Coronal CT scan showing bilateral pneumatization of ACP and protrusion of ON (white arrows), dehiscence of right ICA (white arrowhead) and protrusion of left ICA (blue arrow), pneumatization of right PP and GW (white square). **ON:** Optic nerve, **ICA:** Internal carotid artery, **ACP:** Anterior clinoid process, **GW:** Greater wing, **PP:** Pterygoid process.



**Figure 4:** **A)** Sagittal CT image shows sellar pneumatization of sphenoid sinus. **B)** Coronal CT image shows right ACP pneumatization (white circle), right ON dehiscence (white arrow) and right ICA protrusion (blue arrow). **C)** Axial CT image shows unilateral protrusion of ICA on left side (white arrow). **D)** Coronal CT image with bilateral protrusion of ON and bilateral ACP pneumatization (white arrows). **ON:** Optic nerve, **ICA:** Internal carotid artery, **ACP:** Anterior clinoid process.

**Table III:** Statistical Association Between Extent of Pneumatization and Neurovascular Protrusion/Dehiscence of Optic Nerve and Internal Carotid Artery

Association		CC	p value
ACP pneumatization	ON protrusion	0.518	<0.001*
	ON dehiscence	0.282	0.002*
ACP pneumatization	ICA protrusion	0.398	<0.001*
	ICA dehiscence	0.269	0.005*
PP pneumatization	ON protrusion	0.269	0.005*
	ON dehiscence	0.218	0.093
PP pneumatization	ICA protrusion	0.422	<0.001*
	ICA dehiscence	0.165	0.496
GW pneumatization	ON protrusion	0.327	<0.001*
	ON dehiscence	0.278	0.003*
GW pneumatization	ICA protrusion	0.427	<0.001*
	ICA dehiscence	0.213	0.112

**CC:** Contingency coefficient. Larger CC values indicate greater degree of association. \* $p$ -value $\leq$ 0.05 was considered significant. **ON:** Optic nerve, **ICA:** Internal carotid artery, **ACP:** Anterior clinoid process, **GW:** Greater wing, **PP:** Pterygoid process.

(57.8%), and Nepalese populations (52%) (10,27,28,30,37). Meanwhile, the prevalence of the sellar type was reported in Indian and Egyptian populations (26,32). Subsequent studies on these populations reported the postsellar type with extensive posterior and lateral extensions of pneumatization (1,20). However, confirmed results regarding the prevalence of the sellar type were observed in Malaysian (93%), German (57.2%), Sudanese (73.58%), Italian (74%), Chinese (65.5%), and Korean populations (47%) (4,8,13,16,17,25), which contradict the results of our study. This could be attributed not only to ethno-geographic variations, but also to the different classification patterns used when comparing the incidences of sellar and postsellar types. Older studies used the Radberg classification, whereas the most recent one used the Guldner classification (17,31,37). The inter-observer variability in accurately defining pneumatization at the margins of the anterior and posterior sellar walls may also be responsible for reporting the differences.

The pneumatization type of SS has a significant impact on bony protrusion or dehiscence of the ON and ICA. The risk of ON and ICA protrusion greatly increased with an increase in pneumatization of the SS ( $p < 0.001$ ). ICA protrusions were found in 49% of patients, of which the postsellar type was manifested in 41.34% and the sellar type in 7.57% of patients. Similarly, out of 38% of patients with ON protrusions, 29.37% exhibited the postsellar type, while 8.64% of patients showed the sellar type. The results were similar to those reported by Refaat and Basha (32), in which postsellar types showed a greater number of protrusions of ON (52.3%) and ICA (50.6%) than the sellar type (48.1%, 46.5%), respectively, but we found a higher frequency of ICA protrusion (49%) than ON (38%). This could be due to the fact that sinus infection

predisposes the arterial wall to degenerative changes and protruded arterial injury (33). Our results correspond with the range of international averages for ICA protrusion (5.2%–67%) and ON protrusion (2%–56%) (3). Local studies also reported ON adjacent to SS in 55.9%–61.5% of sinuses and indenting the wall in 22.3%–26.85% of sinuses, which is also within international ranges (14,24). There were no protrusions/dehiscence seen in the presellar type in our study, which is similar to the findings of Fatihoglu et al. (15) but slightly contradicts the findings of Refaat and Basha (32), in which only one (1.2%) patient with the presellar type showed ON and ICA protrusion. This finding again confirms that small sinuses with a lesser degree of pneumatization usually have no or minimal chance of protrusion/dehiscence of the surrounding neurovascular structure as compared to well-pneumatized sinuses.

The risk of neurovascular injury significantly increases during surgery if the bony wall has undergone dehiscence. There is a potential chance of injury to the ON and ICA due to the absence of bony separation, which makes the ON and ICA bare in the sinus cavity. The frequency of dehiscence of the ON and ICA was 16% and 9.3% in our study, which is lower than that reported by Hewaidi and Omami (31.6% and 30%, respectively) in the Libyan population (19) and 50% and 45% in the Indian population, as reported by Mamatha et al. (26). The dehiscence of ICA (9.3%) was comparable with the findings of Joghataei et al. (8.5%) (21) in an Iranian population and Unal et al. (5.3%) in a Turkish population (36). The findings of ON dehiscence were also comparable with those of Farhan et al., who reported 16.4% of ON dehiscence in the local population (14). Our findings are within the range of international averages for ON dehiscence between 1%–37% and ICA dehiscence

between 2%–42% (31). Our study proves that subjects with increased pneumatization also showed maximum dehiscence of the ON and ICA.

Extended pneumatization to ACP was noted in 31.3%, GW in 16.6%, and PP in 44% of the sinuses. These findings are not only within the international ranges of ACP (6%–29%), GW (10.7%–20%), and PP pneumatization (15.5%–43.6%) (7,19,31), but are also consistent with the local findings of ACP pneumatization (24.6%) and PP pneumatization (41%) (14). The wide range of differences in reported incidences is attributed to differences in the sample size and methodology adopted in different studies.

We found a significant association between ACP pneumatization and ICA/ON protrusion ( $p < 0.001$ ), consistent with the findings of Refaat and Basha, and Hewaidi and Omami (19,32). However, in some studies, a significant association was found between ACP pneumatization and ON protrusion, whereas the association between ICA protrusion and ACP pneumatization was not significant (22). The relationship between PP pneumatization and ON/ICA protrusion was also significant ( $p = 0.005$  and  $p < 0.001$ , respectively), which is consistent with the findings of Fatihoglu et al., Refaat and Basha, and Rahmati et al. (15,30,32). However, Sirikci et al. found no significant association between PP pneumatization and ICA protrusion but found a significant relationship with ON protrusion (33). In our study, a highly significant correlation was found between GW pneumatization and ON/ICA protrusion ( $p < 0.001$ ). Hence, sinuses with any type of extended pneumatization have a higher risk of protrusion of the ON or ICA, which must be considered during endoscopic sinus surgeries to prevent any inadvertent injury to these vital neurovascular structures.

### Limitations

It is important to note several limitations of this study. It was a single-center study; hence, multicenter methods should be used for better, more universal results. Second, a small sample size was used; therefore, a larger sample size must be considered to further validate the results. Third, surgical correlation with CT scans was not performed and the frequency of surgical complications was unidentified. Hence, for future studies, it is recommended to correlate the radiological findings of CT scans with the endoscopic findings.

### CONCLUSION

This study contributes novel data in the field of ETS by improving the knowledge of anatomical variants of the sphenoid sinus. The protrusions of the ON and ICA are dependent on the pneumatization type of SS. As pneumatization increases, protrusion of the adjacent vital neurovascular structures also increases. When working around the sphenoid sinus, it is necessary to use caution and be aware of different anatomical features. Hence, they must be distinctly mentioned in CT reports to avoid disastrous intraoperative complications and outcomes.

### AUTHORSHIP CONTRIBUTION

Study conception and design: AA, HA, SF, TS, BR

Data collection: AA, HA, BR

Analysis and interpretation of results: AA, SF, HJ

Draft manuscript preparation: AA, HA, SF, TS, BR

Critical revision of the article: AA, BR

All authors (AA, HA, SF, TS, BR, HJ) reviewed the results and approved the final version of the manuscript.

### REFERENCES

1. Abdo AS, Ahmed MM, Monib AH: Normal variations in sphenoid and their significance regarding endoscopic sinus surgeries: Multislice computed tomographic study. *Egypt J Neck Surg Otorhinolaryngol* 6(3):1-11, 2021
2. Abuzayed B, Tanriover N, Gazioglu N, Ozlen F, Cetin G, Akar Z: Endoscopic anatomy and approaches of the cavernous sinus: cadaver study. *Surg Radiol Anat* 32(5):499-508, 2010
3. Agam MS, Zada G: Complications associated with transsphenoidal pituitary surgery: Review of the literature. *Neurosurg* 65(1):69-73, 2018
4. Ahmed AOE: Study of anatomical variations of the sphenoid sinus among Sudanese using computed tomography. Doctoral Dissertation, Sudan University of Science and Technology, 2018. Available from: <https://repository.sustech.edu/handle/123456789/22293>
5. Ahmed M, Raheel N, Bilal S, Haroon N: Assessment of variations in sphenoid sinus pneumatization in Pakistani population at tertiary care hospital. A retrospective multidetector computed tomographic study. *Pakistan Postgrad Med J* 32(01):19-21, 2021
6. Aijaz A, Khan N, Mubeen S, Rasheed B: Anatomical variations of human sphenoid sinus in terms of volume and septation pattern in a subset of Pakistani population using computed tomographic images. *JPMA* 72(4):702-706, 2022
7. Anusha B, Baharudin A, Philip R, Harvinder S, Shaffie BM: Anatomical variations of the sphenoid sinus and its adjacent structures: A review of existing literature. *Surg Radiol Anat* 36(5):419-427, 2014
8. Anusha B, Baharudin A, Philip R, Harvinder S, Shaffie BM, Ramiza RR: Anatomical variants of surgically important landmarks in the sphenoid sinus: A radiologic study in Southeast Asian patients. *Surg Radiol Anat* 37(10):1183-1190, 2015
9. Aydin S, Cavallo LM, Messina A, Dal Fabbro M, Cappabianca P, Barlas O: The endoscopic endonasal trans-sphenoidal approach to the sellar and suprasellar area: Anatomic study/comment. *J Neurosurg Sci* 51(3):129-138, 2007
10. Bilgir E, Bayrakdar İS: A new classification proposal for sphenoid sinus pneumatization: A retrospective radio-anatomic study. *Oral Radiol* 37(1):118-124, 2021
11. Budu V, Mogoanata CA, Fanuta B, Bulesco I: The anatomical relations of the sphenoid sinus and their implications in sphenoid endoscopic surgery. *Rom J Morphol Embryol* 54(1):13-6, 2013
12. Ceylan S, Koc K, Anik I: Extended endoscopic approaches for midline skull-base lesions. *Neurosurg Rev* 32(3):309-319, 2009

13. Cho JH, Kim JK, Lee JG, Yoon JH: Sphenoid sinus pneumatization and its relation to bulging of surrounding neurovascular structures. *Ann Otol Rhinol Laryngol* 119(9):646-650, 2010
14. Farhan N, Naqvi SU, Rasheed B, Sattar A, Khan M, Rahim A, Murtaza G: Identification of significant anatomical variations in the nose and anterior skull base using computed tomography: A cross-sectional study. *Cureus* 12(6):e8449, 2020
15. Fatihoglu E, Aydin S, Karavas E, Kantarci M: The pneumatization of the sphenoid sinus and its relations. *Am J Otolaryngol* 42(4):31-36, 2021
16. Gibelli D, Cellina M, Gibelli S, Oliva AG, Codari M, Termine G, Sforza C: Volumetric assessment of sphenoid sinuses through segmentation on CT scan. *Surg Radiol Anat* 40(2):193-198, 2018
17. Güldner C, Pistorius SM, Diogo I, Bien S, Sesterhenn A, Werner JA: Analysis of pneumatization and neurovascular structures of the sphenoid sinus using cone-beam tomography (CBT). *Acta Radiologica* 53(2):214-219, 2012
18. Hammer G, Rådberg C: The sphenoidal sinus: An anatomical and roentgenologic study with reference to transsphenoid hypophysectomy. *Acta Radiologica* (6):401-422, 1961
19. Hewaidi GH, Omami GM: Anatomic variation of sphenoid sinus and related structures in Libyan population: CT scan study. *Libyan J Med* 3(3):1-9, 2008
20. Hiremath SB, Gautam AA, Keerthy Sheeja GB: Assessment of variations in sphenoid sinus pneumatization in Indian population: A multidetector computed tomography study. *Indian J Radiol imaging* 28(3):273-279, 2018
21. Joghataei MT, Hosseini A, Ansari JM, Golchini E, Namjoo Z, Mortezaee K, Pirasteh E, Dehghani A, Nassiri S: Variations in the anatomy of sphenoid sinus: A computed tomography investigation. *J Pharm Res Int* 26(3):1-7, 2019
22. Kazkayasi M, Karadeniz Y, Arikan OK: Anatomic variations of the sphenoid sinus on computed tomography. *Rhinology* 43(2):109-114, 2005
23. Kim EH, Ahn JY, Kim SH: Technique and outcome of endoscopy-assisted microscopic extended transsphenoidal surgery for suprasellar craniopharyngiomas. *J Neurosurg* 114(5):1338-1349, 2011
24. Lakhani M, Ali M, Sadiq M: Analysis of optic nerve types in relation to posterior paranasal sinuses: A computed tomographic (CT) Study. *Ann ASH-KMDC* 22(4):249-254, 2017
25. Lu Y, Pan J, Qi S, Shi J, Zhang XA, Wu K: Pneumatization of the sphenoid sinus in Chinese: The differences from Caucasian and its application in the extended transsphenoidal approach. *J Anat* 219(2):132-142, 2011
26. Mamatha H, Saraswathi G, Prasanna LC: Variations of sphenoid sinus and their impact on related neurovascular structures. *Curr Neurobiol* 1(2):121-124, 2010
27. Nepal PR, Karki K, Rajbanshi JN: Types of sphenoid sinus pneumatization among nepalese population. *Eastern Green Neurosurg* 2(3):14-18, 2020
28. Oliveira JM, Alonso MB, De Sousa MJ, Fuziy A, Scocate AC, Costa AL: Volumetric study of sphenoid sinuses: Anatomical analysis in helical computed tomography. *Surg Radiol Anat* 39(4):367-374, 2017
29. Priyadarshini D, Prabhu L, Kumar A, Mangala PA, Dananjay KV: The anatomical variations in the neurovascular relations of the sphenoid sinus: An evaluation by coronal computed tomography. *Turk Neurosurg* 25(2):289-293, 2015
30. Rahmati A, Ghafari R, Anjom Shoa M: Normal variations of sphenoid sinus and the adjacent structures detected in cone beam computed tomography. *J Dent* 17(1):32-37, 2016
31. Raseman J, Guryildirim M, Beer-Furlan A, Jhaveri M, Tajudeen BA, Byrne RW, Batra PS: Preoperative computed tomography imaging of the sphenoid sinus: Striving towards safe transsphenoidal surgery. *J Neurol Surg B Skull Base* 81(3):251-262, 2020
32. Refaat R, Basha MA: The impact of sphenoid sinus pneumatization type on the protrusion and dehiscence of the adjacent neurovascular structures: A prospective MDCT imaging study. *Acad Radiol* 27(6):132-139, 2020
33. Sirikci A, Bayazit YA, Bayram M, Mumbuc S, Gungor K, Kanlikama M: Variations of sphenoid and related structures. *Eur Radiol* 10(5):844-848, 2000
34. Stokovic N, Trkujla V, Dumic-Cule I, Cukovic-Bagic I, Lauc T, Vukicevic S, Grgurević L: Sphenoid sinus types, dimensions and relationship with surrounding structures. *Ann Anat* 203:69-76, 2016
35. Tomovic S, Esmaili A, Chan NJ, Shukla PA, Choudhry OJ, Liu JK, Eloy JA: High-resolution computed tomography analysis of variations of the sphenoid sinus. *J Neurol Surg B Skull Base* 74(02):82-90, 2013
36. Unal B, Bademci G, Bilgili YK, Batay F, Avci E: Risky anatomic variations of sphenoid sinus for surgery. *Surg Radiol Anat* 28(2):195-201, 2006
37. Wiebracht ND, Zimmer LA: Complex anatomy of the sphenoid sinus: A radiographic study and literature review. *J Neurol Surg B Skull Base* 75(6):378-382, 2014
38. Yune HY, Holden RW, Smith JA: Normal variations and lesions of the sphenoid sinus. *Am J Roentgenol* 124(1):129-138, 1975
39. Zanation AM, Snyderman CH, Carrau RL, Gardner PA, Prevedello DM, Kassam AB: Endoscopic endonasal surgery for petrous apex lesions. *Laryngoscope* 119(1):19-25, 2009