

## Endoscopic Procedures in Neurosurgery: Report of Two Case and Review of The Literature

AYTAÇ AKBAŞAK, OĞUZHAN SARIYÜCE, SEMİH ÖZKAN, MEHMET GÜREL

İnönü University, School of Medicine, Department of Neurosurgery, (AA) Department of Urology (OS, SÖ),  
and Department of General Surgery (MG), Malatya - Türkiye

**Abstract** : Endoscopic systems have now been used with relatively low complication rates in numerous situations including the aspiration and resection of colloid cysts of the third ventricle, biopsy and resection of cystic and intraventricular tumours, evacuation of intracerebral haematomas, and a terminal third ventriculostomy through the foramen of Monro for hydrocephalus.

In this paper, we present our experience in two cases, the retrieval of a retained ventricular catheter and the drainage of an intracerebral abscess respectively.

**Key Words** : Brain Abscess, Endoscopic Neurosurgery, Foreign Bodies, Hydrocephalus, Ventriculostomy

### INTRODUCTION

The first endoscopic neurosurgical procedure was performed in 1910 by an urologist, V.L. l'Espinase (7) in Chicago. He used a rigid systoscope to fulgurate choroid plexus bilaterally in two infants. The event received little attention and passed almost unnoticed at that time.

Dany in 1918 (6), reported bilateral open choroid plexectomy as an attempt to treat hydrocephalus. In 1922, he described a third ventriculostomy for the treatment of hydrocephalus, later, combining these two ideas, he performed the first endoscopic choroid plexectomy in two patients with communicating hydrocephalus (5).

In 1923, Fay and Grant (8) used a ventriculoscope to take intraventricular photographs. Mixter (20), same year, performed the first succesful endoscopic ventriculostomy.

Scarf (26) became interested in ventriculostomy during this era and developed a ventriculoscope for use in cauterizing the choroid plexus.

In the late 1940s and early 1950s, the development of a coherent fiber-optic bundle for image transmission and an incoherent bundle for light transmission by Hopkins (11), a British scientist, greatly aided the improvement of endoscopes.

In 1943, Putnam (25) reported on 42 cases of endoscopic choroid plexectomy. Guiot et al (12), in 1963, utilized the internal reflective properties of a solid quartz rod to devise an external light source to provide a bright light to be used in ventriculostomy. In 1974, Olinger and Ohlhaber (23) used an 18 gauge needle scope in the spinal canal of dogs.

By the late 1960s and early 1970s, as the technology advanced, endoscopic visualization of body areas became routine. Urological surgeons had used endoscopy for many years, and were quickly followed by their general surgical (4), paediatric surgical (9), and gynecological (18) colleagues. Interest in endoscopy grew in orthopaedics (28), otorhinolaryngology (19), and cardiovascular surgery (10). Visualization of the spinal cord, conus and cauda equina became possible through a "myeloscope" developed by Pool (24).

The first principle of the endoscopic technique is to minimize trauma to the intact cerebral tissues around deep-seated lesions during a surgical intervention. To achieve this goal, endoscopes were improved to be used with stereotactic systems (1), laser (3), and superfine instruments (29). Today, ultrasound-guided, laser assisted-stereotaxic endoscopic techniques are widely used in neurosurgery for a variety of intracranial operations.

Auer and co-workers (2) reported the results of endoscopic surgery versus conservative treatment of spontaneous supratentorial intracerebral haematoma in 100 cases.

Although experience is limited regarding tumour resection by endoscopic procedures, evidence indicates that the treatment of brain tumours with the use of this method will soon be widespread. Auer (3) has already reported 24 brain tumors operated by endoscopic technique.

Jones and co-authors (16) reported the results of endoscopic third ventriculostomy in 24 patients with noncommunicating hydrocephalus of various pathogenesis, and inferred that it had been successfully managed by this method. Heilman (13) reported eight children who underwent ventriculoscopic saline torch fenestration of symptomatic loculated CSF collections. They concluded that the technique is simple, safe, and effective.

Another potential use for endoscopy is ventricular catheter placement. Under direct vision, the catheter can be placed in the ideal position (27).

## REPORT OF THE CASES

### Materials and Methods

The endoscopic system used in our clinic consists of an 11 cm long, straight forward 0° angle telescope with a diameter of 1.9 mm, a sheath with obturator for examination and irrigation, and a grasping and biopsy forceps (Karl Storz GmbH & Co., Tuttlingen, West Germany). By attaching an infusion bottle containing fluid at 37°C to the irrigation system, irrigation of the operating field at a constant pressure can be achieved. A suction device can be attached to the outlet valve for evacuation of liquids. A three-way stop-cock on the outlet valve allows the simultaneous use of both irrigation and drainage functions.

The system is attached to an endovision camera system (Endovision telecam, Karl Storz GmbH & Co., Tuttlingen, West Germany), and interfaced with a colour TV monitor, a video recorder, and a video printer. Therefore, all operations are performed under video-assisted visualization of the operating field; video records and colour prints of desired surgical procedures and anatomical structures can be obtained.

### Case 1

This 11-month-old boy was admitted to hospital with fever, neck stiffness, vomiting and seizures. He was diagnosed as tuberculous meningitis, and antituberculous therapy was established. Ventricular cerebrospinal fluid (CSF) pressure was slightly above normal (210 mm H<sub>2</sub>O). Although the ventricular size in computed tomography (CT) appeared to be normal, there was significant periventricular hypodensity. This finding led us to consider a diagnosis of "hydrocephalus in progress". As soon as the cerebrospinal protein level returned to normal, a ventriculoperitoneal shunt was placed through a parietal burr hole. The patient was discharged under antituberculous therapy.

The child returned for follow-up examination 3 months later. The shunt was obstructed, and the head circumference had increased. CT revealed considerable ventricular enlargement. The ventricular catheter appeared to be blocked. A shunt revision was performed. During the replacement, the ventricular catheter slipped from the grasping forceps accidentally, plunged in the ventricle and disappeared.

It was impossible to see the shunt piece in the ventricle through the cortical hole it was previously inserted, and attempts to remove it in blind manner could have been disastrous because of the possibility of injury to the ventricular walls and periventricular brain parenchyma. Endoscopic removal of the catheter piece was planned. The endoscopic telescope and grasping forceps described in the materials and methods section were introduced in the right lateral ventricle through the cortical incision created in the previous operation, the shunt piece was detected, caught by the forceps, and removed under video assisted visualisation of the operating field on a TV screen (Fig. 1).

Neither perioperative, nor postoperative complications occurred.

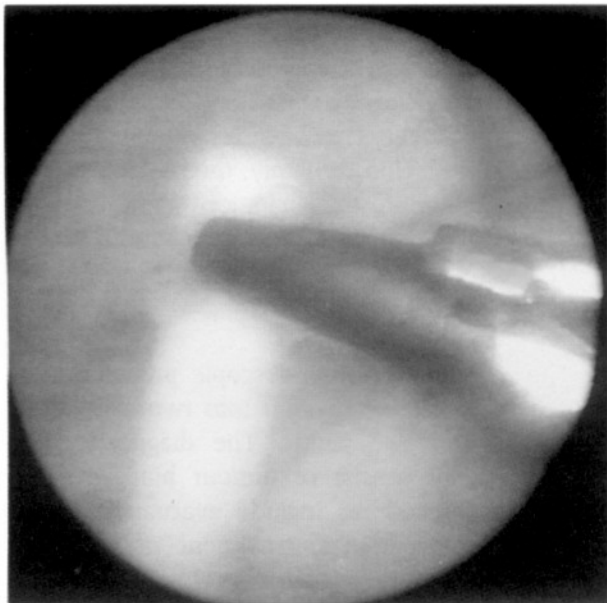

Fig. 1: The free ventricular catheter in the right lateral ventricle grasped by the forceps prior to removal. On the rear plan ventricular wall and branches of the thalamostriate vein are shown. The picture has been created from a still video scene by a colour video printer after the operation.

### Case 2

This 41-year-old woman was admitted to hospital with complaints of nausea, vomiting and headache. Except for minimal meningeal irritation, neurological examination was normal. CT was also normal. On the second day, fever, increased neck stiffness, and confusion dominated the clinical picture. In lumbar puncture, CSF pressure was 280 mm H<sub>2</sub>O, and 390 cells, mostly polymorphonuclear leucocytes, were counted in 1 cubic mm of CSF. Staphylococcus aureus was identified as the infectious organism from both CSF and haemocultures. Echocardiography and other cardiological examinations revealed an infective endocarditis. Computed tomography on the third day after admission indicated hypodense areas in the left frontal, right fronto-temporal, and right cerebellar regions (Fig. 2), as well as in the right kidney. Diagnosis was established as multiple intracerebral and intraabdominal abscess formation on the basis of sepsis, caused by bacterial endocarditis.

Since there was no definite ventricular compression or large oedema, the patient was not considered in imminent danger from increased intracranial pressure, and non-operative therapy was applied for

two weeks. During this period, encapsulation around the lesion in the left frontal lobe was detected by serial CTs (Fig. 3). In order to provide some relief for the patient, and to obtain a specimen for identification of the infective organism, operative intervention to the lesion was planned. The poor clinical condition of the patient and multiplicity of the lesions led us to consider burr hole aspiration under local anaesthesia.

Video assisted endoscopic aspiration of the lesion was performed through a left frontal burr hole placed at a location selected so as to approach the

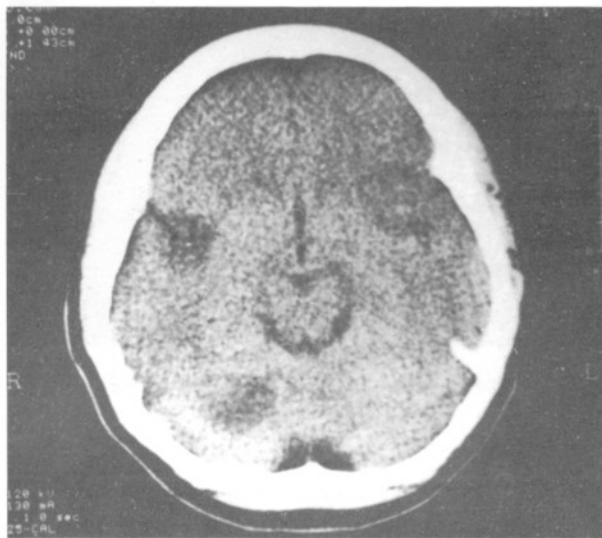

Fig. 2: Hypodense areas in the left frontal, right temporal, and right cerebellar areas on the CT performed three days after the admission.

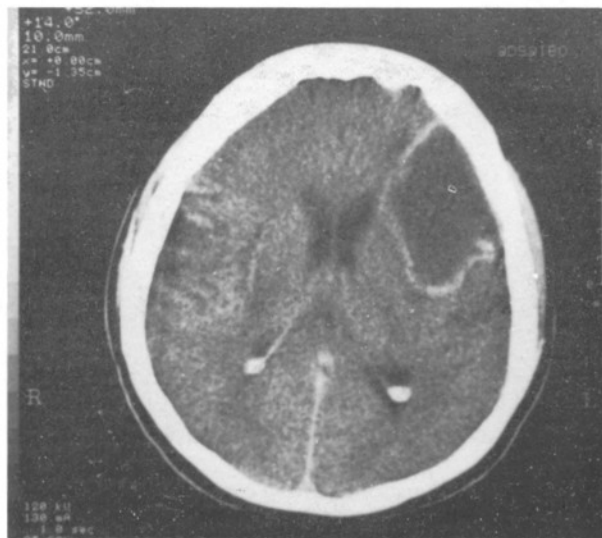


Fig. 3: Capsule formation around the left fronto-temporal hypodense lesion shown in fig. 2.

abscess pouch through the shortest distance of vital brain tissue. There were solidified, caseous materials in the abscess cavity, and the cavity was compartmentalized by these structures (Fig. 4). Less viscous abscess material was trapped in these compartments. Fenestration of these separations, and complete evacuation and irrigation of the pouch was successfully performed under visual control of the operating field on the TV screen.

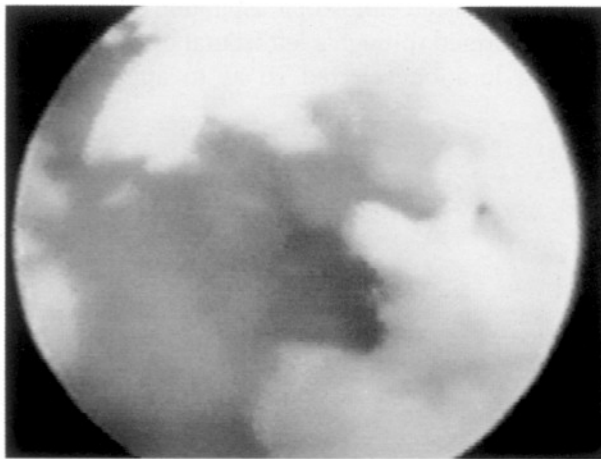


Fig. 4: Abscess cavity as shown on the TV screen during the operation. Note condensed pus material in the cavity.

The neurological condition of the patient improved after the operation. Postoperative CT revealed that the attenuation coefficient of the material in the pouch was very close to the CSF value, whereas the value before surgery had been considerably higher (Fig. 5-A and B). Unfortunately, the patient died of a profuse gastrointestinal haemorrhage caused by gastric ulcers 2 months after the operation.

### DISCUSSION

The indications for endoscopic procedures in neurosurgery can be divided into two categories, diagnostic and therapeutic. The diagnostic procedures chiefly consist of tumour biopsies. The therapeutic procedures include evacuation of intracerebral haematomas, treatment of intraventricular tumours, third ventriculostomy, communication of multiloculated intraventricular cysts, placement and removal of catheters, drainage of abscesses.

Shunts are troublesome devices causing perturbation by complications including infection, misplacement, overdrainage, underdrainage, and foreign body reaction. Detachment of ventricular or corporeal

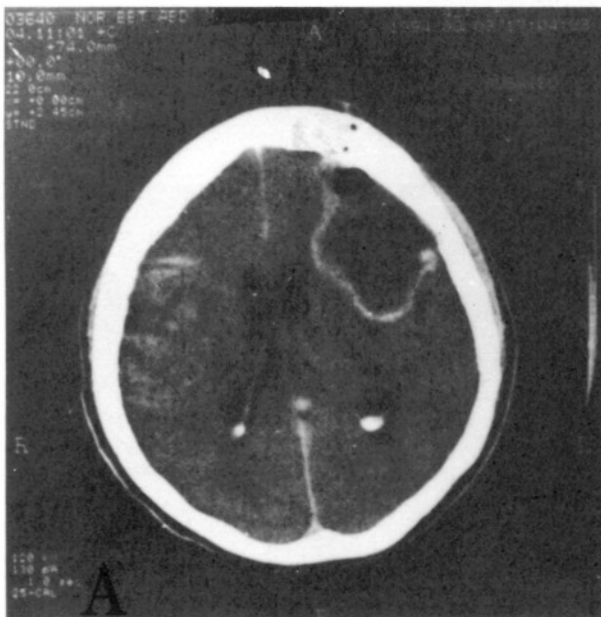
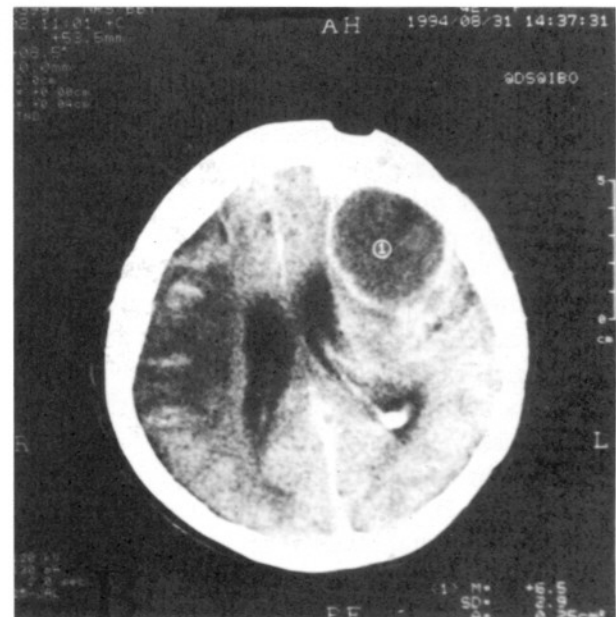


Fig. 5 A, B: Post operative follow-up computed tomograms.  
A. Two days after the operation. The attenuation coefficient of the material in the cavity was very close to the CSF value.



B. Fifteen days after the operation. Abscess cavity has started to shrink, and the attenuation coefficient was equal to the CSF value.

parts of the device are frequently encountered. The endoscope can be used for removal of foreign bodies and retained ventricular catheters, as presented in our first case. Removal of foreign bodies from the ventricles by conventional methods usually requires a large cortical incision, which may elicit further deterioration of the existing clinical picture. On the other hand, with very fine endoscopic instruments already available, it is possible to perform this operation through the catheter hole, whose diameter is no wider than 2 mm. Videoassisted screening of intraventricular space allows the surgeon to detect and seize foreign bodies easily. We conclude that the method is safe, simple, and reliable.

Although Hellwig and Bauer (14) mentioned briefly their experiences on the endoscopic drainage of brain abscesses, they did not give details. We could not find any other references in the literature regarding this method. Although excision of the lesion is logically appealing in the treatment of brain abscesses because it removes all infected and necrotic tissues, it may not be feasible in certain cases. Patients who are seriously ill may not tolerate general anaesthesia and the risk of excision. If an abscess is not well encapsulated or is in a deep area of the brain, attempts at excision may produce significant morbidity. Finally, excision of all infected and necrotic tissue is usually not possible in patients with multiple abscesses.

When complete removal of the abscess is not possible for the reasons just cited, aspiration is the best alternative and several studies have demonstrated excellent results (17,21,22). On the other hand, Joama (15) and associates indicated that the recurrence rate was lower among patients who underwent excision of the abscess than among those who underwent excision of the abscess than among those who underwent aspiration. The recurrence rate among the patients whose abscesses were aspirated or drained was 8 per cent, whereas none of the patients who underwent excision were reported to have recurrence. Although our experience in endoscopic aspiration of brain abscess is as yet confined to only one case and conclusions drawn from this experience would be insignificant, we can speculate that compartmentalization and condensation of the pus material in the abscess cavity could prevent the pouch from being evacuated thoroughly by simple needle-drainage technique, and might be responsible for high-recurrence rates. Video-assisted aspira-

tion of the material, however, enables the disruption of these compartments and removal of the semi-solid material without compromising the vital brain parenchyma. The introduction of new equipment, such as very fine probes for ultrasonic aspiration, would increase the operability of the technique further.

We think that application of endoscopic procedures proved to be a safe and rapid technique. Surgical trauma to the vital brain tissues can be kept to a minimum, mortality and morbidity are very low and intraoperative hemorrhage is also minimal.

**Correspondence :** Dr. Aytaç Akbaşak  
İnönü Üniversitesi Tıp Fakültesi  
Araştırma ve Uygulama Hastanesi  
Nöroşirürji Anabilim Dalı  
44300, Malatya - Türkiye

## REFERENCES

1. Apuzzo MLJ, Chandrasoma PT, Zelman V, Giannota SL, Weiss MH: Computed tomographic guidance stereotaxis in the management of lesions of the third ventricular region. *Neurosurgery* 15:502-508, 1984.
2. Auer LM, Deinsenber W, Niederkorn K, Gell G, Kleinert R, Schneider G, Holzer P, Bone G, Mokry M, Körner E, Kleinert G, Hanusch S: Endoscopic surgery versus medical treatment for spontaneous intracerebral hematoma: a randomized study. *J Neurosurg* 70:530-535, 1989.
3. Auer LM, Holzer, P, Ascher PW, Heppner F: Endoscopic neurosurgery. *Acta Neurochir (Wien)* 90:1-14, 1988.
4. Cohen MR: The laparoscope and other equipment. Friedman EA (Ed), in *Laparoscopy, Culdoscopy and Gynecography*. Philadelphia, Saunders, 1970:38-39.
5. Dandy WE: An operative procedure for hydrocephalus. *Bull Johns Hopkins Hosp* 33:189-190, 1922.
6. Dandy WE: Extirpation of the choroid plexus of the lateral ventricles in communicating hydrocephalus. *Ann Surg* 68:569-579, 1918.
7. David L: *Neurological Surgery*. Philadelphia: Lea & Fabiger, 1936:405.
8. Fay T, Grant FC: Ventriculography and intraventricular photography in internal hydrocephalus. *JAMA* 80:461-463, 1923.
9. Gans SL, Berci G: Advances in endoscopy of infants and children. *J Pediatr Surg* 6: 199-233, 1971.
10. Greenstone SM, Shore JM, Heringman EC: Arterial endoscopy (arterioscopy). *Arch Surg* 98:811-812, 1966.
11. Griffith HB: Endoneurosurgery, endoscopic intracranial surgery. *Proc R Soc Lond* 195:261-268, 1978.
12. Guiot G, Rougerie J, Fourestier M, Fournier A, Comoy C, Vulmiere J, Groux R: Une nouvelle technique endoscopique: Explorations endoscopiques intracraniennees. *Presse Med* 71: 1225-1228, 1963.
13. Heilman CB, Cohen AR: Endoscopic ventricular fenestration using a "saline torch". *J Neurosurg* 74: 224-229, 1991.

14. Helwig D, Bauer BL: Endoscopic procedures in stereotactic neurosurgery. *Acta Neurochir Suppl* 52:30-32, 1991.
15. Joama OV, Pennybacker JB, Tutton GK: Brain abscesses: Aspiration, drainage or excision. *J Neurol Neurosurg Psychiatry*. 14:308-313, 1951.
16. Jones RFC, Stening WA, Brydon M: Endoscopic third ventriculostomy *Neurosurgery* 26:86-92, 1990.
17. Joubert MJ, Stephanov S: Computerized tomography and surgical treatment in intracranial suppuration. Report of 30 consecutive unselected cases of brain abscess and subdural empyema. *J Neurosurg* 47:73-78, 1977.
18. Mandelbaum R, Pontarelli D, Brushenko A: Amnioscopy for prenatal transfusion. *AM J Obstet Gynecol* 98: 1140-1143, 1967.
19. Merr SS, Derbyshire AJ, Brushenko A: Fiberoptic endoscopes for examining the middle ear. *Reach Otolaryngol* 85:387-393, 1967.
20. Mixter WJ: Ventriculoscopy and puncture of the floor of the third ventricle. *Boston Med Surg J* 188:277-278, 1923.
21. Morgan H, Wood MW, Murphy F: Experience with 88 consecutive cases of brain abscess. *J Neurosurg* 38:698-704, 1973.
22. Ohaegbulam SC, Saddegi NU: Experience with brain abscesses treated by simple aspiration. *Surg Neurol* 13:289-291, 1980.
23. Olinger CP, Ohlhaber: Eighteen-gauge microscopic-telescopic needle endoscope with electrode channel: Potential clinical and research application. *Surg Neurol* 2:151-160, 1974.
24. Pool JL: Myeloscopy: Intraspinal endoscopy. *Surgery* 2:169-182, 1942.
25. Putnam TJ: The surgical treatment of infantile hydrocephalus. *Surg Gynecol Obstet* 76:171-182, 1942.
26. Scarf JE: Endoscopic treatment of hydrocephalus: Description of a ventriculoscope and preliminary report of cases. *Arch Neurol Psychiatry* 35:853-861, 1935.
27. Vries JK: Endoscopy as an adjunct to shunting for hydrocephalus. *Surg Neurol* 13:69-72, 1983.
28. Watanabe M, Takeda S, Ikeuchio H: Atlas of arthroscopy. New York, Springer, 1970.
29. Yamakawa, K, Kondo T, Yoshioka M, Takakura K: Application of superfine fiberscope for endovascularoscopy, ventriculoscopy, and myeloscopy. *Acta Neurochir Suppl* 54:47-52, 1990.