



Decision Making via 3D Computed Tomography in the Surgical Treatment of Cubital Tunnel Syndrome: Surgical Technique and Results

Guray BULUT¹, M. Ozgur TASKAPILIOGLU²

¹Medipol University School of Medicine, Department of Neurosurgery, Istanbul, Turkey

²Bursa Uludag University School of Medicine, Department of Neurosurgery, Bursa, Turkey

This study was presented at 32th Annual Scientific Meeting of Turkish Neurosurgical Society, Antalya, Turkey

Corresponding author: M Ozgur TASKAPILIOGLU ✉ ozgurt@uludag.edu.tr

ABSTRACT

AIM: To investigate the importance of elbow 3D computed tomography in surgical planning when deciding on the treatment surgical treatment method of the ulnar nerve entrapment in the cubital tunnel.

MATERIAL and METHODS: In this study, 21 patients with cubital tunnel syndrome in our clinic were included and retrospectively analyzed. All of the patients were diagnosed with EMG, and surgical planning was performed based on the anatomy of the cubital tunnel diagnosed via 3D computed tomography. In addition to the classical simple decompression of the ulnar nerve, 15 patients underwent cubital tunnel reconstruction with high-speed drill, whereas 6 patients underwent ulnar nerve anterior subcutaneous transposition. The results were evaluated based on the modified Wilson & Krout criteria.

RESULTS: Fourteen of the patients were female and seven were male. The average age was 42.2 years. Fifteen patients underwent simple decompression of the ulnar nerve and cubital tunnel reconstruction. Transposition was performed in six patients. The patients were followed up for an average of 107.5 months (3-144). Based on the Wilson & Krout criteria, excellent results were obtained in 14 patients (66.7%), good results in 6 (28.6%), and poor results in 1 (4.8%).

CONCLUSION: The evaluation of the cubital tunnel via 3D computed tomography before the operation is effective in determining the optimal surgical technique and obtaining more successful clinical results. The cubital tunnel reconstruction in addition to simple decompression increases surgical success and minimizes complications and the possibility of relapse due to the fact that the nerve remains in its natural position.

KEYWORDS: Ulnar nerve, Cubital tunnel, 3D computed tomography, Entrapment neuropathy, Simple decompression

ABBREVIATIONS: EMG: Electromyography, 3D CT: 3D computed tomography

INTRODUCTION

Ulnar nerve entrapment can occur at the elbow level, wrist, forearm, arm, and axillary region. Clinically, trapping is most common at the elbow level. It is the second most common in all trap neuropathies after carpal tunnel syndrome (1,3,6).

The most common causes of entrapment are compression and trauma. Bone fractures, synovitis due to rheumatological diseases, osteophytes, soft tissue tumors, ganglion cysts, bone and muscle anomalies, and perineural adhesions also play an important role in etiology (1,6).

The complaints of the patients are often numbness and paresthesia in the half of the fourth and fifth finger. Symptoms

increase when the elbow is in the flexion position. Patients may describe pain and tenderness at the elbow level which may radiate proximally and distally. In advanced cases, “claw hand” deformity may develop in the hand due to weakness of intrinsic muscles (1,2,6).

The diagnosis is made through neurological examination and electromyography (EMG). Examination findings include atrophy in the thenar and interosseous muscles, Tinel test positivity (occurrence of ulnar sensory complaints or increase in existing complaints with percussion into the cubital tunnel trace), and positivity of Froment’s sign (weakness in holding when a paper or similar object is inserted between the thumb and index finger) (1,2,6).

Conservative treatment is the first treatment of choice in the ulnar nerve entrapment. Surgical treatment should be considered if no response to the conservative treatment is observed for 6 to 12 weeks or progressive paralysis/long-term lesion (claw hand, muscle atrophy) is present. Surgical treatment options are simple decompression, medial epicondylectomy, transposition (anterior subcutaneous, anterior intermuscular, and anterior submuscular), and endoscopic decompression (7,8).

In our clinic, the surgical method to be used for ulnar nerve entrapment is decided via preoperative 3D computed tomography (3D CT). Reconstruction of the tunnel in addition to simple decompression was performed in bone pathologies that distort the anatomy of the tunnel. Anterior muscular transposition of the ulnar nerve was performed in patients who had previously undergone simple decompression and had normal cubital tunnel anatomy. Therefore, the aim of this study is to investigate the surgical and clinical results of these two surgical techniques.

■ MATERIAL and METHODS

All procedures performed in studies involving human participants were in accordance with the ethical standards of the institutional and/or national research committee (Institutional Review Board of Istanbul Medipol University 25.06.2020/513), and with the 1964 Helsinki Declaration and its later amendments or comparable ethical standards. Informed consent was obtained from all individual participants included in the study.

Fifteen patients who underwent simple decompression and cubital tunnel reconstruction and six patients with ulnar nerve transposition were included in the study. Surgical indications were increasing pain, progressive paralysis, muscle atrophy, and electrophysiologically significant denervation findings despite 6 weeks of conservative treatment. Clinical and electrophysiological examinations (EMG) were performed in the diagnosis. Preoperative ulnar tunnel anatomy was evaluated via 3D CT (Figure 1). We performed ulnar nerve anterior transposition in patients with normal cubital tunnel anatomy or in those who have previously undergone simple decompression. The preoperative and postoperative motor power values of the cases were evaluated using the British

Medical Research Council scale. Ulnar neuropathy severity was evaluated using the modified McGowan classification (Table I) (10). All cases were followed up for an average of 107.5 months (3–144 months) after the operation.

The results were evaluated based on the modified Wilson & Krout criteria (Table II) (16). Spearman and chi-square tests were performed for the statistical analysis of the data. P values less than 0.05 were considered statistically significant.

Surgical Method

An elbow-centered skin incision of approximately 5–6 cm was performed in the elbow flexion, arm abduction, and external rotation position. First, the ulnar nerve was decompressed proximally by opening the band and ligaments where it was compressed throughout its course until it entered the flexor carpi ulnaris muscle. Then, the base of the cubital tunnel was scraped off the periosteum, the bone pathologies compressing the nerve as detected on CT were removed using a high-speed drill, and the cubital tunnel was reconstructed. The periosteum was recovered and the nerve was returned to its normal position. Moreover, it was checked whether the nerve was fully decompressed (Figure 2A, B). Elbow immobilization was not performed after surgery to prevent fibrosis. In cases wherein ulnar nerve transposition was performed, the nerve was freed with simple decompression and moved to the anterior aspect of the medial epicondyle. Subcutaneous fatty tissue was sutured to the fascia over the medial epicondyle to prevent the nerve from returning to the tunnel (Figure 2,3). Surgical microscopes were used in all patients.

■ RESULTS

Fourteen of the 21 patients were female and 7 were male. The mean age of the patients was 42.2 years (28–63). The average time elapsed between the onset of symptoms and their admission was 5.5 months. None of the patients had trauma, mass, or anatomical anomaly at the elbow area. No patient was reoperated. Both arms were operated in a female patient. Table 1 shows the modified McGowan stages.

The patients were followed up for an average of 107.5 months (3–144 months). Neurological improvement was observed in all patients except the patient who was stage 3 according to the modified McGowan classification. Based on the Wilson & Krout criteria, 14 (66.7%) of the patients had excellent results, 6 (28.6%) good results, and 1 (4.8%) poor results (Table II). One patient with poor results was stage 3 preoperatively based on the modified McGowan classification. She had claw hand deformity and intrinsic muscle atrophy for 1 year.

A statistically significant correlation was observed between the preoperative McGowan staging of the patients and the Wilson & Krout scores in the postoperative follow-up period. As the McGowan stage decreased, the Wilson & Krout score increased ($p < 0.05$, $r = -0.43$). It was determined that the longer the time from the onset of the symptoms, the less successful the treatment was ($p < 0.05$). No complications were observed and a reoperation was not performed.

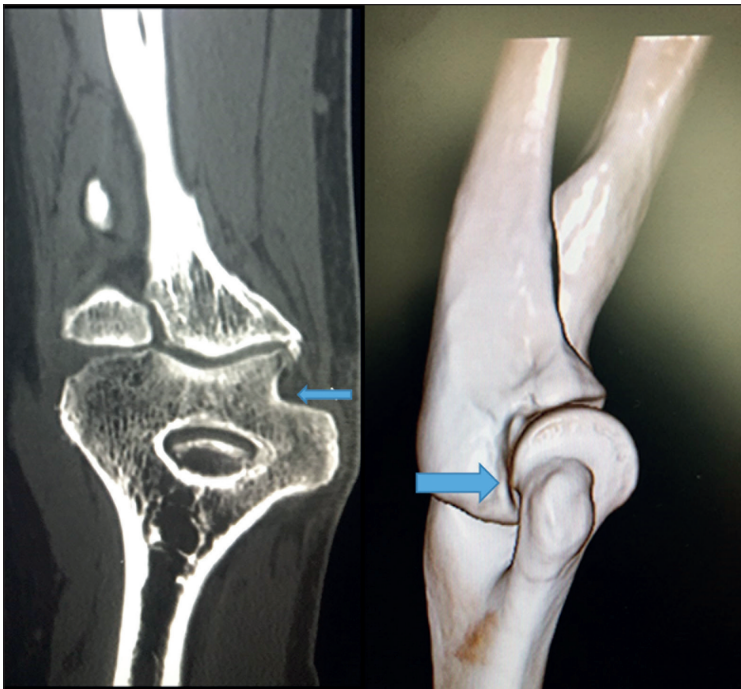


Figure 1: 3D CT image of the cubital tunnel. Obstruction of the cubital tunnel with osteophytes.

Table I: Modified McGowan Distribution of Patients at Preoperative Period

		Simple decompression	Transposition
1	Purely subjective symptoms	1	0
2A	No atrophy of intrinsic muscles	11	4
2B	Some atrophy of intrinsic muscles	3	1
3	Significant sensory and motor deficits with noticeable atrophy of intrinsic muscles	0	1

Table II: Modified Wilson & Krout Criterias

		n
Excellent	Minimal motor and sensory changes, no sensitivity at the incision site	14
Good	Symptoms have disappeared, but regional sensitivity is intermittent	6
Fair	Improvement, but milder ongoing sensory and motor deficits	0
Poor	There is no improvement or worsening	1

DISCUSSION

In the entrapment neuropathy of the ulnar nerve, conservative treatment should be considered for 6 weeks in the early stages of the disease and in cases without neurological deficits. Surgical treatment should be planned in patients who do not benefit from this treatment and whose neurological deficits persist or increase.

Simple decompression is the most commonly used surgical technique for ulnar nerve entrapment. This method is considered to be the most suitable surgical method in patients

whose nerve integrity is not damaged and in those who have not been operated before. The possibility of damaging the vascularization and terminal branches of the nerve with this technique is very low. The disadvantages of simple decompression may be recurrent ulnar nerve entrapment and recurrent ulnar nerve dislocation (4,12,16). In the present study, all of the patients were evaluated via 3D CT before surgery. If a bone pathology (e.g., osteophyte, flattening of the tunnel) affecting the tunnel anatomy and causing neuropathy in the nerve was detected after simple decompression, reconstruction of the cubital tunnel with a high-speed drill was

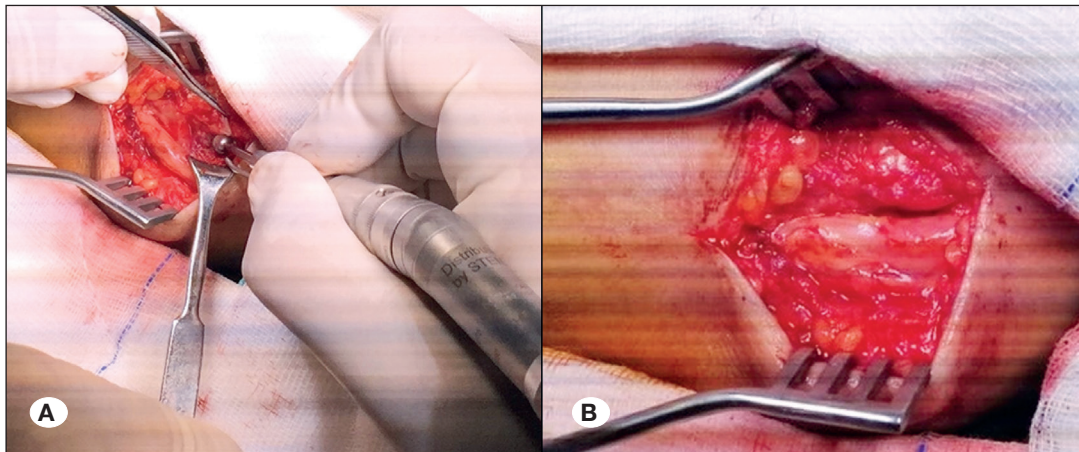


Figure 2:
A) Reconstruction of the cubital tunnel using a high-speed drill.
B) Ulnar nerve in the cubital tunnel after simple decompression and reconstruction.

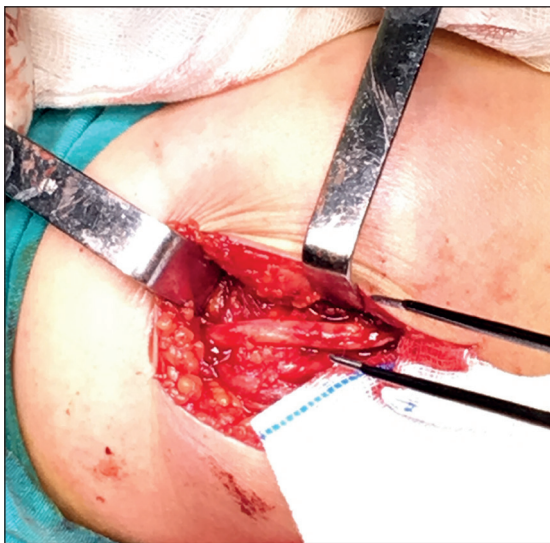

Figure 3: Anterior subcutaneous ulnar nerve transposition after simple decompression.

performed. With this technique, the nerve remains in its normal position and is protected from repeated compression. The average follow-up period was 107.5 months postoperatively, and no recurrence or nerve dislocation was detected. In cases wherein simple decompression is considered, the evaluation of the cubital tunnel via 3D CT and reshaping it if necessary may increase the surgical success.

Endoscopic ulnar nerve decompression is a minimally invasive technique that results in fast wound healing and less scar tissue. However, it has disadvantages, such as high cost, insufficient clinical data, and inadequate decompression of the ulnar nerve in obese patients and patients with severe nerve entrapment (11,15).

Mowlavi et al. stated that the best results were obtained after medial epicondylectomy (14). It is an aggressive surgical method with local tenderness, painful subluxation of the nerve with elbow motion, flexor pronator weakness, medial elbow instability, and joint contracture (14).

Transposition techniques are generally preferred in cases wherein the anatomical integrity of the elbow is impaired or the patient has undergone previous unsuccessful surgical treatment. In this method, the ulnar nerve is removed from the cubital tunnel and placed in the elbow anteromedially. It is a well-known entity that the extrinsic and intrinsic blood supply of the ulnar nerve is disrupted during transposition and the small proximal branches of the nerve are damaged (5,9,13,17,18). Messina and Messina stated that when anterior transposition is performed together with the vascular bundle of the nerve, a quicker recovery can be observed (13). We performed transposition in six patients who were previously operated with other techniques, such as simple decompression or medial maxillectomy. During the transposition, the ulnar nerve was released in accordance with the microsurgical principles, and it was assured that the vessel package will not be damaged. Except from one patient who was stage 3, good results were obtained. In our postoperative follow-up, no neurological deterioration was observed in the ulnar nerve functions.

In the literature, EMG is the gold standard for the diagnosis of ulnar nerve entrapment neuropathy with neurological examination, and it is considered sufficient for surgical planning. In our series, besides EMG, we had performed elbow 3D CT in patients diagnosed with ulnar nerve entrapment. The evaluation of the anatomical structure of the cubital tunnel helped the surgeon in surgical planning. Bone-related pathologies that compress the structure of the cubital tunnel were treated by performing cubital tunnel reconstruction with a high-speed drill in addition to simple decompression. Although recurrence has been reported in cases operated with simple decompression in the literature, no recurrence was observed in our series. No surgical complications were encountered in any of the patients, and no additional neurological deficits developed after surgery in our series. The average follow-up period of the cases was 107.5 months (3–144 months). Based on the Wilson & Krout criteria, we obtained excellent results in 66.7% of the cases and good results in 28.6%. The limitations of this study include the lack of postoperative EMG results and small patient groups.

■ CONCLUSION

The evaluation of the elbow anatomy via 3D CT is useful in deciding on the treatment method for ulnar nerve entrapment surgery. Restoring the cubital tunnel is an easy-to-apply technique that increases surgical success and reduces the likelihood of recurrence in patients who are considered to undergo classical simple decompression.

■ AUTHORSHIP CONTRIBUTION

Study conception and design: GB

Data collection: GB

Analysis and interpretation of results: GB

Draft manuscript preparation: GB, MOT

Critical revision of the article: MOT, GB

All authors (GB, MOT) reviewed the results and approved the final version of the manuscript.

■ REFERENCES

- Artico M, Pastore FS, Nucci F, Giuffre R: 290 surgical procedures for ulnar nerve entrapment at the elbow: Physiopathology clinical experience and results. *Acta Neurochir (Wien)* 142: 303-308, 2000
- Baek GH, Kwon BC, Chung MS: Comparative study between minimal medial epicondylectomy and anterior subcutaneous transposition of the ulnar nerve for cubital tunnel syndrome. *J Shoulder Elbow Surg* 15:609-613, 2006
- Bartels RH: History of the surgical treatment of ulnar nerve compression at the elbow. *Neurosurgery* 49:391-400, 2001
- Bartels RH, Termeer EH, van der Wilt GJ, van Rossum LGM, Meulstee J, Verhagen WIM, Grotenhuis JA: Simple decompression or anterior subcutaneous transposition for ulnar neuropathy at the elbow: A cost-minimization analysis-part 2. *Neurosurgery* 56:531-536, 2005
- Bartels RH, Verhagen WI, van der Wilt GJ, Meulstee J, van Rossum LG, Grotenhuis JA: Prospective randomized controlled study comparing simple decompression versus anterior subcutaneous transposition for idiopathic neuropathy of the ulnar nerve at the elbow: Part 1. *Neurosurgery* 56:522-530, 2005
- Bozentka DJ: Cubital tunnel syndrome pathophysiology. *Clin Orthop* 351:90-94, 1998
- Cho YJ, Cho SM, Sheen SH, Choi JH, Huh DH, Song JH: Simple decompression of the ulnar nerve for cubital tunnel syndrome. *J Korean Neurosurg Soc* 42:382-387, 2007
- Erol B, Tetik C, Sirin E: The mid-term results of minimal medial epicondylectomy and decompression for cubital tunnel syndrome. (Article in Turkish) *Acta Orthop Traumatol Turc* 38:330-336, 2004
- Frantz LM, Adams JM, Granberry GS, Johnson SM, Hearon BF: Outcomes of ulnar nerve anterior transmuscular transposition and significance of ulnar nerve instability in cubital tunnel syndrome. *J Shoulder Elbow Surg* 28(6):1120-1129, 2019
- Goldberg BJ, Light TR, Blair SJ: Ulnar neuropathy at the elbow: results of medial epicondylectomy. *J Hand Surg Am* 14:182-188, 1989
- Hoffmann R, Siemionow M: The endoscopic management of cubital tunnel syndrome. *J Hand Surg Br* 31:23-29, 2006
- Huang JH, Samadani U, Zager EL: Ulnar nerve entrapment neuropathy at the elbow: Simple decompression. *Neurosurgery* 55:1150-1153, 2004
- Messina A, Messina JC: Transposition of the ulnar nerve and its vascular bundle for the entrapment syndrome at the elbow. *J Hand Surg (Br)* 20:638-648, 1995
- Mowlavi A, Andrews K, Lille S, Verhulst S, Zook EG, Milner S: The management of cubital tunnel syndrome: A meta-analysis of clinical studies. *Plast Reconstr Surg* 106: 327-334, 2000
- Oertel J, Keiner D, Gaab MR: Endoscopic decompression of the ulnar nerve at the elbow. *Neurosurgery* 66:817-824, 2010
- Wilson DH, Krout R: Surgery of ulnar neuropathy at the elbow: 16 cases treated by decompression without transposition. Technical note. *J Neurosurg* 38:780-785, 1973
- Yamaguchi K, Sweet FA, Bindra R, Gelberman RH: The extraneural and intraneural arterial anatomy of the ulnar nerve at the elbow. *J Shoulder Elbow Surg* 8:17-21, 1999
- Zhao M, Tian D, Wu J: Anatomical study on anterior transposition of ulnar nerve accompanied with arteries for cubital tunnel syndrome. *Zhongguo Xiu Fu Chong Jian Wai Ke Za Zhi* 21:1196-1198, 2007