

Distal Posterior Cerebral Artery (P3) Aneurysm: Occipital Interhemispheric Approach (Case Report)

EMRE METİN GÜNER, TANSU MERTOL, KEMAL YÜCESOY, ARIF ÖSÜN, OĞUZ DİCLE

Dokuz Eylül Üniversitesi Tıp Fakültesi Neurosurgery (EMG, TM, KY, AÖ) and Radiology (OD) Departments İzmir-Turkey

Abstract : We report a case of a ruptured saccular aneurysm of the distal posterior cerebral artery (P3). The aneurysm was successfully clipped through an occipital interhemispheric approach and the patient was discharged without any neurological deficit.

Aneurysms in this location are rarely encountered and their occurrence and treatment are discussed in the light of recent literature.

Key Words : Cerebral aneurysm, Posterior cerebral artery, P3

INTRODUCTION

Aneurysms of the posterior cerebral artery (PCA) are rare, comprising only 0.7 to 2.2 % of all cerebral aneurysms (1,2,3,9). Yaşargil subdivided these aneurysms into four groups according to the location of the lesion; P1, P1/P2 junction, P2, and P3 aneurysms (20). Distal PCA aneurysms occur less often than proximal ones (1). Surgical treatment of PCA aneurysms has long been associated with high rates of morbidity and mortality. These rates increase when they rupture and result in subarachnoid haemorrhage (SAH) (12,13,14,19).

CASE REPORT

This thirty-eight-year old right-handed man had a sudden headache after exertion which continued for a few days, with concomitant emesis. On the fifth day, the patient became unconscious and was admitted to a local hospital. A CT scan with and without contrast showed subarachnoid hemorrhage with aneurysmatic dilatation in the right PCA area. On the thirty-second day of admission, the patient was transferred to our hospital.

Examination: On admission there was mild neck stiffness with no neurological deficit. No visual field

defect was found. Routine blood and urine analyses were normal. Digital subtraction angiography showed an aneurysm of 1 cm in diameter in the P3 segment of the right PCA, and local vasospasm of the same artery (Figure 1.2).

Operation: On the 5th hospital day, a right occipital craniotomy was performed and using interhemispheric approach, the calcarine artery was identified. Dissection was directed to the bifurcation of the medial occipital artery. The P4 segment was

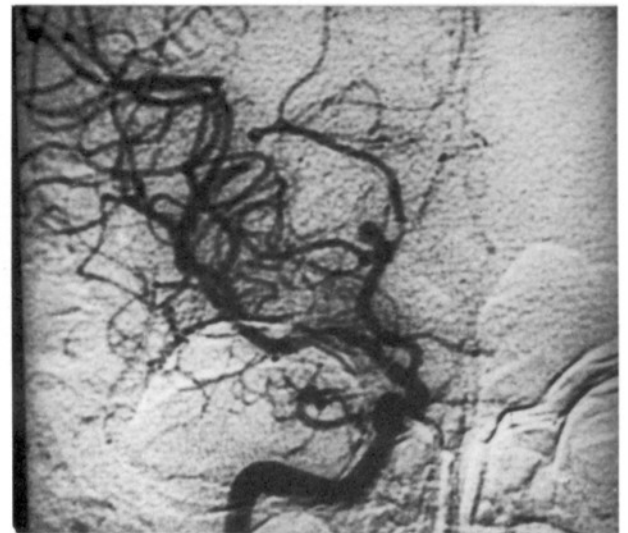

Fig. 1 : Pre-operative DSA (Antero-posterior view)

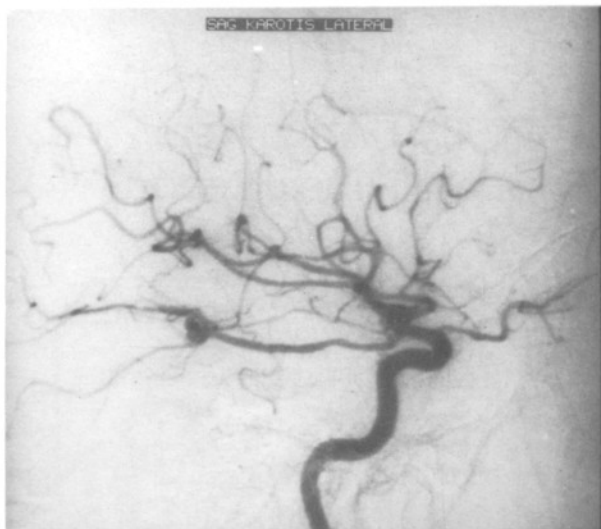


Fig. 2 : Pre-operative DSA (Lateral view)

dissected through the lateral occipital artery junction. At the bifurcation the aneurysm was seen and dissected after temporary clipping (110 seconds). The neck of the aneurysm was clipped with a Yaşargil clip and coagulated by bipolar cautery. Intraoperatively no complications were noted.

Angiography performed on the ninth day after operation showed good distal PCA blood flow and complete occlusion of the aneurysm (Figure 3,4). The patient was discharged without any neurological deficit. The control visual field tests were normal. At a one-year follow-up he continued to remain symptom-free.

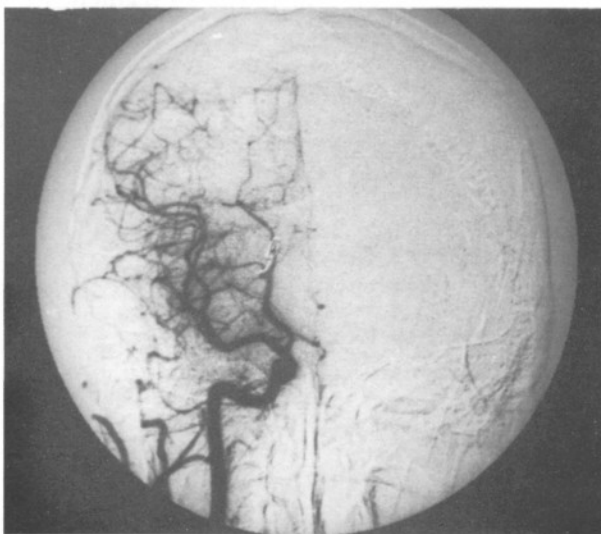


Fig. 3 : Post-operative DSA (Antero-posterior view)

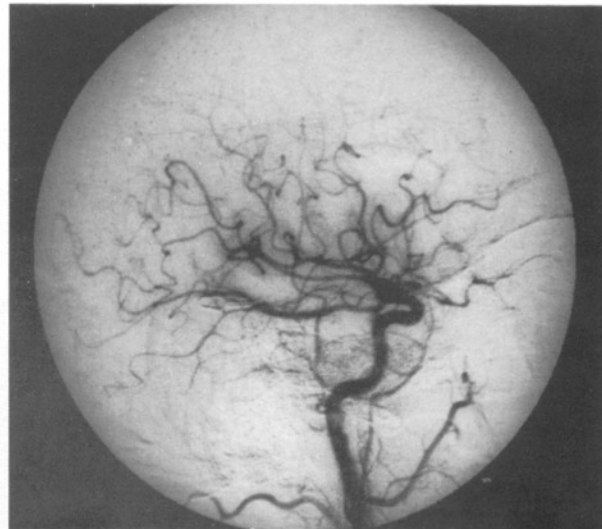


Fig. 4 : Post-operative DSA (Lateral view)

DISCUSSION

PCA aneurysms account for only 0,7 to 2,2 % of all cerebral and 7 to 15 % of all vertebrobasilar aneurysms (3,4,10,12,18,20). We have seen 3 patients with PCA aneurysms among 208 cerebral aneurysm (1,5 %) and 31 vertebrobasilar aneurysm (10,1 %) patients. Patients with PCA aneurysms tend to be younger than those with other cerebral aneurysms and males slightly predominate (12). They tend to be giant in young people (1).

Yaşargil subdivided these aneurysms into four groups according to the segment of the PCA involved (20). P3 aneurysms are very rare; to date, only thirteen patients have been reported (Table 1).

Several authors have described surgically-treated cases of PCA aneurysm (1,3,4,5,6,8,9,12,17,18). The operative approach will vary depending on the site of the aneurysm: the subtemporal and / or pterional approach may be used for P1 and P1/P2 junction aneurysms and the subtemporal approach for P2 and P3 aneurysms (14,16,20). However, Yaşargil and other authors preferred the occipital interhemispheric approach in their patients with P3 aneurysms (12,14,16,18).

The morbidity and mortality rates for patients with PCA aneurysms are higher than other cerebral aneurysms. As the patient's age decreases and the aneurysm's size increases, morbidity and mortality increases (2,7,11,15).

Table 1 : Previously Reported Cases With P3 Aneurysm

Author	Year	Age	Sex	Symptoms	Sah	Site	Approach	Complications
Obrador	1967	20	F	Blindness, left hemiparesia	(-)	P3 R	Subtemporal	Hemiplegia, Asterognosis
Bertrams	1968	49	M	Left dilated pupil, neck stiffness	(-)	P3 Bilat.	Subtemporal	No deficit
Ishilawa	1974	40	M	Headache, right hemianopsia	(+)	P3 L	Temporooccipital	ICH
Pia	1976	43	F	Blindness, sudden coma	(+)	P3 L	Occipital	Occ.lobe resection
Yaşargil	1977	45	M	Right hemianopsia	(+)	P3 R	Occipital	Transient hom.hemianopsia
	1978	46	M	Confusion	(+)	P3 L	Occipital	No deficit
	1979	44	M	Left hemiparesia, ataxia	(-)	P3 R	Occipital	No deficit
Chang	1985	43	F	Neck stiffness	(+)	P3 R	Subtemporal	Left hom. hemianopsia
Ishibashi	1989	69	F	Headache, vomiting, right homonymus hemianopsia	(+)	P3 L	Occipital	No deficit

Dissection through the subtemporal approach in PCA aneurysm patients needs to be performed very carefully since ipsilateral third nerve paresis and palsy may be produced (3,14,18).

Occlusion of the posterior thalamoperforating and thalamogeniculate arteries which arise from the P1 segment may result in contralateral hemiplegia, cerebellar ataxia, dysarthria, and cerebral tremor associated with ipsilateral oculomotor nerve paresis. Infarction of the area perfused by the thalamogeniculate arteries arising from the P2 segment causes the thalamic syndrome of Dejerine and Roussy (14,21).

Also, thalamic ischaemia may cause confusion and impairment of short-term memory (14).

On the contrary, in the occipital interhemispheric approach only injury of the lateral and medial occipital arteries and their branches may occur (20,21).

Because the complication rates are higher with the subtemporal approach (1,3,4,12,14), we believe that if occipital interhemispheric approach is preferred for distal PCA aneurysms the complication rate will be decreased.

Corresponding : Metin Güner

Dokuz Eylül Üniversitesi Tıp Fakültesi
Nöroşirürji ABD Başkanı 35330
İnciraltı, İzmir-Turkey

REFERENCES

- Amacher AL, Drake CG, Ferguson GG: Posterior circulation aneurysms in young people. *Neurosurgery* 8:315-320, 1981
- Asari S, Yamamoto Y: Unruptured cerebral aneurysms: Clinical analysis of 80 cases and its new classification. *No To Shinkei* 38:693-700, 1986
- Chang HS, Fukushima T, Miyazeki S, Tamagawa T: Fusiform posterior cerebral artery aneurysm treated with excision and end-to-end anastomosis. *J Neurosurg* 64:501-504, 1986
- Chang HS, Takanori F, Kintoma T, Tsuneo S: Aneurysms of the Posterior Cerebral Artery: Report of ten cases. *Neurosurgery* 19:1006-1011, 1986
- Drake CG, Amacher AL: Aneurysms of the posterior cerebral artery. *J Neurosurg* 30:468-474, 1969
- Fukomachi A, Hirato M, Wakao T, Kawafuchi J: Giant serpentine aneurysm of the posterior cerebral artery. *Neurosurgery* 11:271-276, 1982
- Heishenen O, Poranen A: Surgery of incidental intracranial aneurysms. *Surg Neurol* 28:432-436, 1987
- Hunt WE, Hess RM: Aneurysms of the posterior cerebral artery with unexpected postoperative neurological deficit. Case report. *J Neurosurg* 26:633-635, 1967
- Little JR, St Louis P, Weinstein M: Giant fusiform aneurysm of cerebral arteries. *Stroke* 12: 183-188, 1981
- Locksley HB: Report of the Cooperative Study of Intracranial Aneurysms and Subarachnoid Hemorrhage. Section V, Part I. Natural history of subarachnoid hemorrhage, intracranial aneurysms and arteriovenous malformations based on 6368 cases in the cooperative study. *J Neurosurg* 25:219-239, 1966
- Mizoi K, Suzuki J, Yoshimoto T: Results of the surgical treatment of multiple aneurysms: Review of 372 cases. *No Shinkei Geka* 16:133-139, 1988
- Pia HW, Fontana H: Aneurysms of the Posterior Cerebral Artery. *Acta Neurochir* 38:13-35, 1977
- Pia HW: Classification of Vertebrobasilar Aneurysms. *Acta Neurochir* 47:3-30, 1979
- Rice BT, Peerless SJ, Drake CG: Surgical treatment of unruptured aneurysms of the posterior circulation. *J Neurosurg* 73:165-173, 1990
- Salazar JL: Surgical treatment of asymptomatic and incidental intracranial aneurysms. *J Neurosurg* 53:20-21, 1980
- Schmidek HH, Sweet WH: Operative Neurosurgical techniques. W.B. Saunders Company 1988, Volume 2 p97
- Stund TM Jr: Surgical technique for giant intracranial aneurysms. *Neurosurg Rev* 5:161-168, 1982
- Suzuki, Hari S, Sakurai Y: Intracranial aneurysms in the Neurosurgical clinics in Japan. *J Neurosurg* 35:34-39, 1971
- Tamiesan KG: Aneurysms of the vertebrobasilar system. Surgical intervention in 19 cases. *J Neurosurg* 21:781-797, 1964
- Yaşargil MG: *Microneurosurgery*. Stuttgart, Gerog Thieme Verlag, 1984, Volume 2 pp: 260-269
- Zeal AA, Rhoton AL Jr: Microsurgical anatomy of the posterior cerebral artery. *J Neurosurg* 48:534-559, 1978