



DOI: 10.5137/1019-5149.JTN.18213-16.1

Received: 19.05.2016 / Accepted: 15.07.2016

Published Online: 10.08.2016

Case Report

Indocyanine Green Videoangiographic-Guided Cannulation of the Superior Ophthalmic Vein for Endovascular Treatment of Carotid-Cavernous Fistulas

Francesco ACERBI, Giuseppe FARAGO, Morgan BROGGI, Claudio CAVALLO, Michela RANIERI, Valentina CALDIERA, Elisa CICERI, Paolo FERROLI

Fondazione IRCCS Istituto Neurologico Carlo Besta, Department of Neurosurgery, Milan, Italy

ABSTRACT

Direct exposure and cannulation of the superior ophthalmic vein (SOV) provides an alternative access to reach the cavernous sinus for carotid-cavernous fistula (CCF) embolization, when classic transvenous routes through the inferior petrosal sinus (IPS) or facial vein are not feasible. We have used indocyanine green (ICG)-videoangiography to study intraoperatively the flow inside the SOV in two cases of indirect CCF. In this paper, we report the operative technique and the result of ICG videoangiographic-guided cannulation of the SOV for endovascular treatment of CCF. Two male patients, of 59 and 66 years of age respectively, presented at our Institution with right decreased visual acuity, persistent binocular diplopia and painful ophthalmoplegia, chemosis and proptosis, due to right unilateral indirect CCF fistula. The endovascular transvenous approach failed in one case due to thrombosis of the inferior petrosal sinus (IPS) and the extreme tortuosity of the angular vein. In the other case, it was considered unfeasible due to an unfavourable vascular angioarchitecture. For this reason, an ICG videoangiographic-guided cannulation of the SOV, followed by endovascular obliteration of the CCF, was performed. CCF was cured in both cases with this approach. No additional neurological deficits and no complications due to SOV cannulation were registered during the hospital stay. There were no fistula recurrences during the mean follow-up of 18 months. ICG-videoangiography is a simple, fast and cost-effective technique that can be reliably applied in SOV cannulation for subsequent indirect CCF embolization.

KEYWORDS: Indocyanine green, Videoangiography, Superior ophthalmic vein, Carotid-cavernous fistula, Embolization

INTRODUCTION

Transvenous coil embolization is the treatment of choice of indirect carotid-cavernous fistula (CCF), usually by a transvenous route accessed via the inferior petrosal sinus (IPS) or the facial vein (2,12,14). In cases of thrombosis, stenosis, or irregular course of these routes, a direct exposure and cannulation of superior ophthalmic vein (SOV) provides an alternative access to reach the cavernous sinus for subsequent CCF embolization (6,10,15,16,18,20,22). Because of the vein's location inside the orbit, dissection and cannulation can be

difficult. In addition, there might be some issues in identifying the flow direction in cases of vein arterialization making its proper cannulation (22) toward the cavernous sinus even more problematic.

We have used indocyanine green (ICG)-videoangiography to study intraoperatively the flow inside the ophthalmic vein in two cases of indirect CCFs. We report the operative technique and the result of ICG videoangiographic-guided cannulation of the SOV for endovascular treatment of CCF.



Corresponding author: Francesco ACERBI

E-mail: francesco.acerbi@istituto-besta.it

■ CASE REPORTS

In November 2014, 2 male patients, 59 and 66 years of age respectively, presented at the Fondazione IRCCS Istituto Neurologico Carlo Besta. No previous history of intracranial surgery, infection, radiation, exposure or trauma was reported. Symptoms involved the right orbital region and consisted of decreased visual acuity and persistent binocular diplopia with painful ophthalmoplegia, chemosis and proptosis. In both cases, brain magnetic resonance imaging (MRI) and computed tomography (CT) angiography suggested a right indirect CCF. Digital subtraction angiography (DSA) was performed upon admission and confirmed a right unilateral CCF type D1 fistula according to the Barrow classification (1).

In one case, an endovascular transvenous approach to the cavernous sinus failed due to the thrombosis of the IPS and the extreme tortuosity of the angular vein. Therefore, a direct surgical puncture of the SOV was proposed (Figure 1A-D). In the second case, direct surgical SOV cannulation was considered as the first choice treatment, due to the unfavorable vascular angioarchitecture. Both patients gave their written informed consent to the procedure. Clinical and radiological data were retrieved by the prospective database of surgical cases operated on at Unit 2 of Fondazione IRCCS Istituto Neurologico Carlo Besta, approved by our Institutional Review Board.

Surgical Technique

A direct surgical exposure of the SOV for retrograde micro-

catheterization and subsequent CCF embolization was performed in both cases in the angiographic suite under ICG-guidance. Patients were positioned supine and maintained intubated under general anesthesia during the procedure. The ipsilateral eyebrow, forehead, cheek and groin were prepped and draped (Figure 2A). Under direct microscopic view (Pentero with ICG FLOW 800 module, Carl Zeiss Meditec, Germany), a 2 cm incision was performed above the upper eyelid, medially in the skin crease, favored by Miller et al.(15). The orbital septum was opened and orbital fat exposed. Then, through blunt dissection with cotton tipped applicators, the SOV was identified and dissected free for about 5 to 10 mm. The 2/0 silk loops were then placed around each end of the exposed segment to control the vein (Figure 2B). At this point, 12.5 mg of ICG was injected and ICG-videoangiography was performed to study the flow direction inside the SOV to guide its cannulation (Figure 2C). A small incision in the vein wall was performed and the SOV was cannulated with an 18-gauge sheath of an arterial line, following the direction opposite to the arterialized flow as depicted by the ICG videoangiography (Figure 2D). The trocar sheath was then connected to a Y-shaped valve and to heparinized saline solution for continuous irrigation (Figure 3A,B). The proximal silk tie was closed to fix the trocar sheath and to prevent venous bleeding. The distal silk tie was used to ligate the distal part of the SOV.

Through the SOV sheath, a dedicate microcatheter (Echeleon™-10, Covidien) was easily navigated over the microwire (Hibryd™ 1214, Balt) in the posterior compartment of the cav-

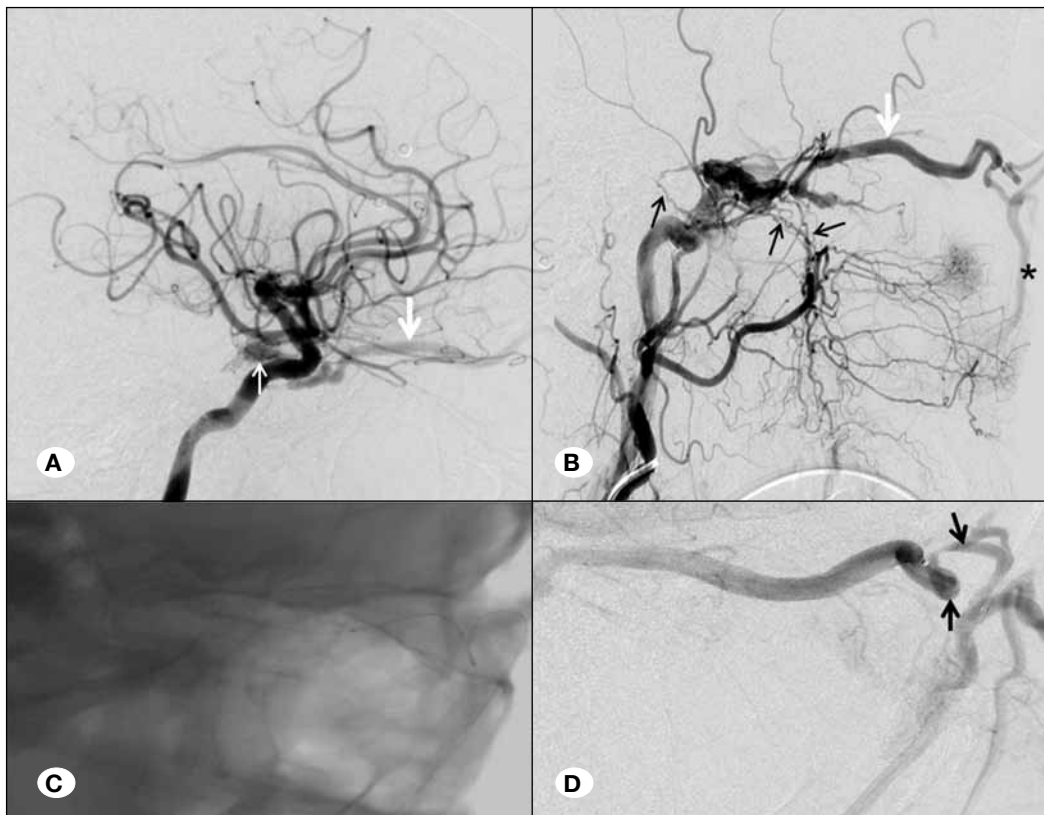


Figure 1: A, B) Right internal and external carotid arteries (ICA and ECA) angiograms in lateral view in case 1 showed early filling of the right cavernous sinus, supplied by branches of meningo-hypophyseal trunk (small white arrow in **A**) and by branches of the internal maxillary artery (black arrows in **B**) with thrombosis of the inferior petrosal sinus (IPS). Retrograde venous drainage through enlarged superior ophthalmic vein (SOV) (large white arrow) and facial vein (asterisk) was evident. **C, D)** An attempt to reach the cavernous sinus with microcatheter and microwire was performed but failed due to the tortuosity of the vessel (black arrows).

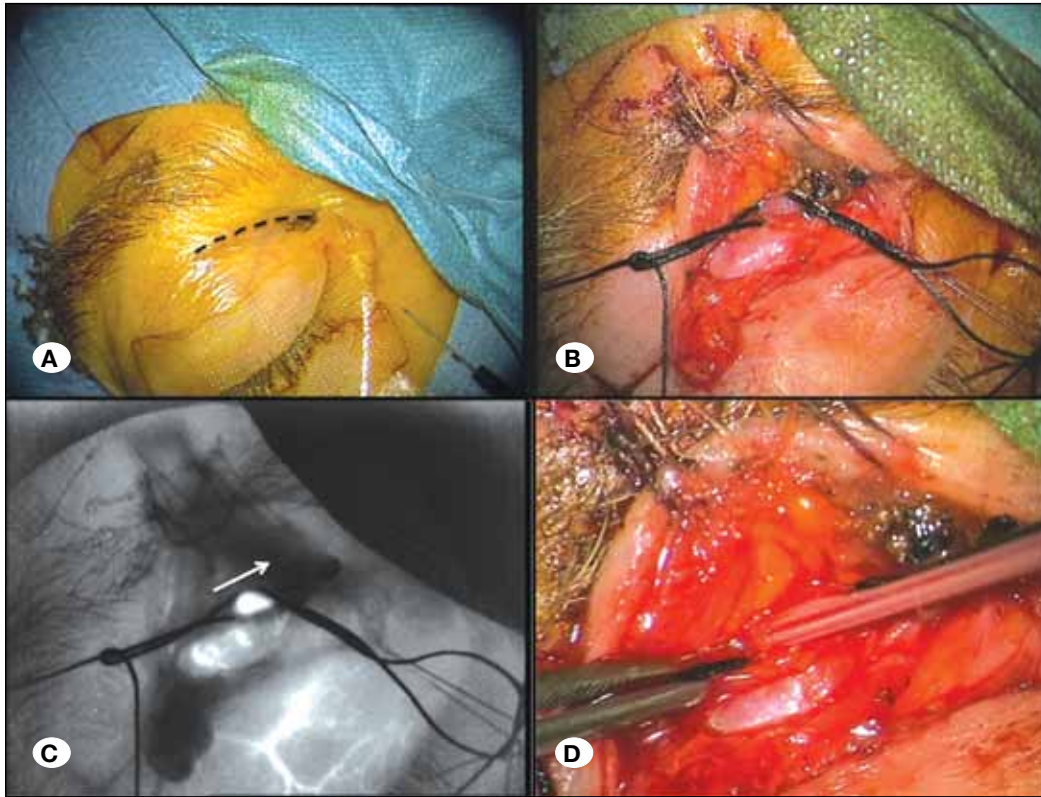


Figure 2: Surgical procedure in case 2. **A)** The ipsilateral eyebrow, forehead, cheek and groin prepped and draped for the surgical procedure. The 2 cm incision is shown as a dotted line in the picture. **B)** Identification and exposure of the superior ophthalmic vein under magnification. The 2/0 silk loops were placed around each end of the exposed segment to control the vein. **C)** ICG videoangiographic visualization of the arterialized flow in the superior ophthalmic vein, after injection of 12.5 mg of ICG. Flow direction is depicted by the white arrow. **D)** Cannulation of the superior ophthalmic vein with an 18-gauge sheath, opposite to the flow direction as showed by ICG videoangiography.

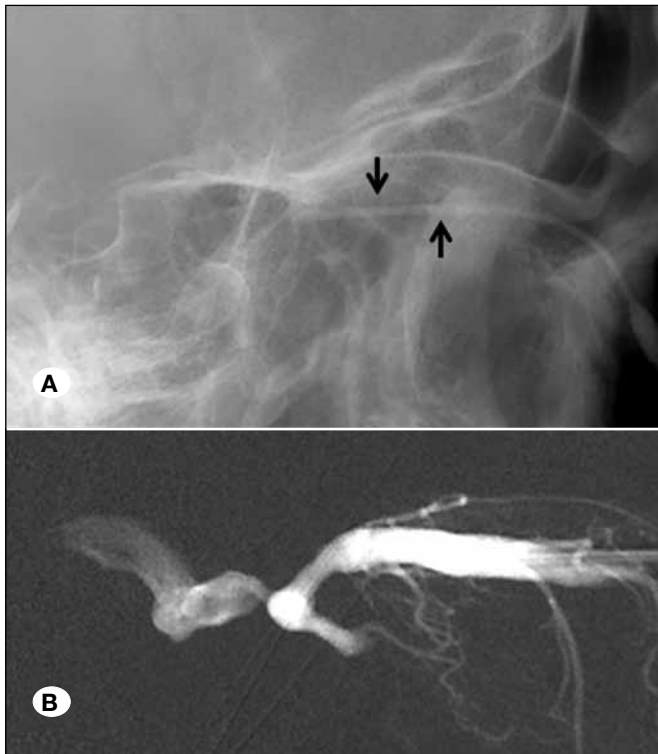


Figure 3: **A)** Unsubtracted image shows the intraorbital venflon (arrows) after direct surgical exposure of the SOV and road mapping image of superior ophthalmic vein cannulation, in case 1 **(B)**.

ernous sinus (CS). Subsequently, obliteration of the fistula was successfully achieved through the use of 3D and filler coils, which progressively reduced the arteriovenous (AV) shunt. Finally the fistula was completely obliterated by the diluted histo-acrylic glue injection (Glubran/lipiodol, 33%) performed under blank road-map. Each step of the embolization was carefully monitored by numerous angiographic DSA injections through the internal and external carotid arteries. At the end of the procedure, once the final DSA excluded any residual AV shunts, the SOV sheath was easily removed without significant bleeding (Figure 4A-C). The surgical eyebrow suture was finally completed.

CCFs were successfully cured in both cases and patients woke up from general anesthesia without any additional neurological deficits. No complications related to SOV cannulation were registered during the hospital stay. Low-molecular-weight heparin (LMWH) was maintained for the next week to prevent thromboembolic events. Cosmetic results were excellent. There were no fistula recurrences during the mean follow-up of 18 months.

DISCUSSION

Our report showed the successful use of ICG-videoangiography to guide SOV cannulation for retrograde venous embolization of CCF.

Indirect CCF are abnormal vascular communications between the CS and meningeal branches of the internal carotid artery (ICA) or external carotid artery (ECA). According to the specific

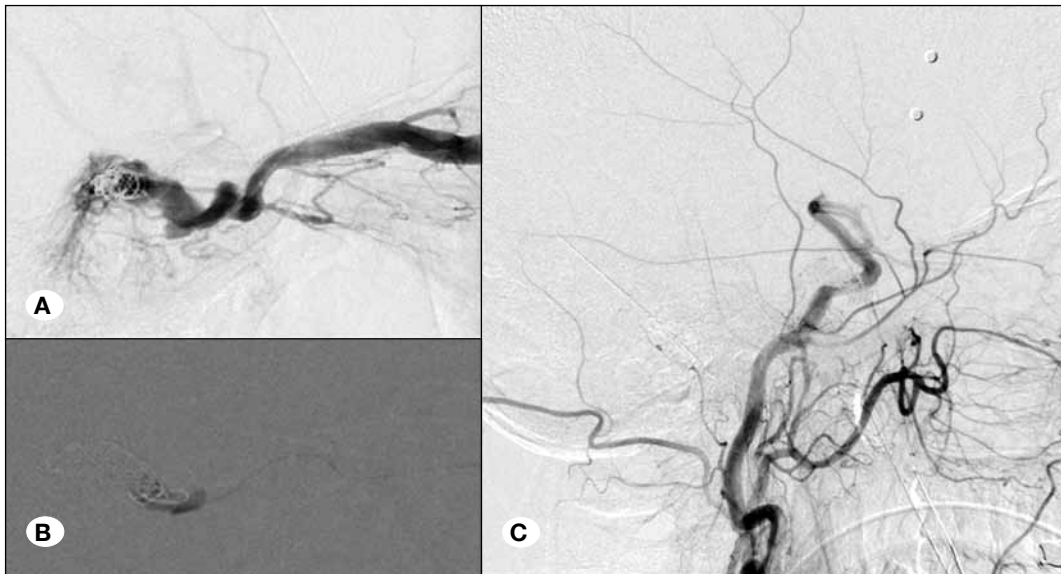

Figure 4:
A-B) Endovascular treatment of the indirect CCF with coils and glue in case 1. Right CCA angiogram after treatment confirmed the complete obliteration of the AV shunt **(C)**.

drainage patterns of these dural connections the clinical presentation may be extremely variable, including cranial nerve dysfunctions, intracranial bruits, and rarely hemorrhage. In the presence of a retrograde venous drainage towards the orbit, CCF may present with proptosis, ophthalmoplegia, ocular neuropathy, chemosis and glaucoma with loss of vision. Endovascular treatment represents the primary treatment option in the management of indirect CCF and several routes of access have been described with different occlusion modalities. Although the introduction of new embolic agents like Onyx re-flourished the interest in transarterial approaches, the transvenous techniques are usually preferred to address indirect CCF (5,11,22).

The direct surgical cannularization of the SOV is an attractive alternative among these in instances in which other transvenous approaches through the IPS, the facial vein or the angular vein cannot be successfully performed, precluding safe cannulations as in our two cases (4,13). The SOV derives from the confluence of the medial angulus oculi vein and the superior orbital vein, and together with the inferior ophthalmic vein is the major venous vessel of the anterior drainage of the CS. The relatively straight course of the vein in combination to the absence of valves, make the SOV an ideal endovenous pathway for cannulation. This is especially true in the presence of high venous pressure which causes the SOV to become thickened and dilated enabling the probing through a steerable guidewire. However, the significant tortuosity of the SOV and its arterialization due to indirect CCF can potentially derange the normal antero-posterior axis of the vein and it may cause an intraoperative misidentification of the direction of the blood flow inside the vessel.

To overcome this issue, we proposed an ICG videoangiographic-guided cannulation of the SOV for the treatment of indirect CCF. Microscope-integrated near-infrared (NIR) indocyanine green ICG-videoangiography is a recent technique that takes advantage of the properties of ICG fluorescent tracer

to obtain high-resolution intraoperative images that provide critical data regarding the flow direction and allow blood-flow measurements.

This technique has been extensively applied in cerebrovascular neurosurgery to evaluate the blood flow during microsurgical clipping of intracranial aneurysms, surgical resection of AV malformations and bypass procedures (19,21,23). In addition, ICG-videoangiography application has been successfully investigated in neurooncological surgery to obtain intraoperative data of brain tumor vascularization during surgical resection (7), and to guide venous sacrifice through the study of the veins' pathophysiology (8,9).

In the two presented cases, the ICG-videoangiography technique has been used and adapted to clarify intraoperative doubts regarding the blood flow direction during direct surgical exposure and cannulation of SOV. This technique is especially useful in the presence of retrograde blood flow in an arterialized fistulous SOV because it allows to properly place a microcatheter through the vascular sheath, in an opposite direction to the retrograde flow, for the subsequent obliteration of the CS with coils and glue. Another possible surgical adjunct in this perspective could be the use of Doppler ultrasound (US), as for proper cannularization of subclavian or jugular veins (3,24). However, to our knowledge, this technique has never been applied in direct surgical exposure for SOV cannulation. One of the reasons may be related to the relatively small incision and difficulties related to application of the US probe.

No complications or recurrences were registered in our 2 cases, and both patients showed clinical improvement after surgery. However, potential risks from this direct surgical SOV cannulation, independently from ICG videoangiographic use, include hemorrhage with both orbital and retro-orbital hematoma, damage to ocular structures, misidentification of the SOV and failure to thread the catheter into the vein. It can be hypothesized that the better flow interpretation by ICG-

videoangiography could avoid mistakes in SOV cannulation and its related complications.

Although other authors previously reported the direct surgical cannulation of the SOV in patients presenting an indirect CCF (5,11,15,17,18,20,22), the innovative use of ICG-videoangiography represents a safe and practical technical adjunct that can successfully contribute in confirming the blood flow direction during the approach.

■ CONCLUSION

ICG-videoangiography could be considered as a simple, fast and cost-effective technical adjunct to help in direct surgical SOV cannulation for subsequent indirect CCF embolization.

■ ACKNOWLEDGEMENT

Dr. Francesco Acerbi received honoraria, travel costs, and financial support for scientific lectures from Carl Zeiss Meditec, Germany.

■ REFERENCES

- Barrow DL, Spector RH, Braun IF, Landman JA, Tindall SC, Tindall GT: Classification and treatment of spontaneous carotid-cavernous sinus fistulas. *J Neurosurg* 62(2):248-256, 1985
- Biondi A, Milea D, Cognard C, Ricciardi GK, Bonneville F, van Effenterre R: Cavernous sinus dural fistulae treated by transvenous approach through the facial vein: Report of seven cases and review of the literature. *AJNR Am J Neuroradiol* 24(6):1240-1246, 2003
- Brass P, Hellmich M, Kolodziej L, Schick G, Smith AF: Ultrasound guidance versus anatomical landmarks for internal jugular vein catheterization. *Cochrane Database Syst Rev* 1:CD006962, 2015
- Bulsara KR, Vasudevan R, Erdem E: Superior ophthalmic vein approach to carotid-cavernous fistulas. *Technical note. Neurosurg Focus* 18(2):ECP3, 2005
- Chalouhi N, Dumont AS, Tjoumakaris S, Gonzalez LF, Bilyk JR, Randazzo C, Hasan D, Dalyai RT, Rosenwasser R, Jabbour P: The superior ophthalmic vein approach for the treatment of carotid-cavernous fistulas: A novel technique using Onyx. *Neurosurg Focus* 32(5):E13, 2012
- Derang J, Ying H, Long Y, Reifa S, Qiming W, Yimu F, Guoxiang S, Shimin C, Lihua X, Shi W, Zunhua C: Treatment of carotid-cavernous sinus fistulas retrograde via the superior ophthalmic vein (SOV). *Surg Neurol* 52(3):286-292, 1999
- Ferrolli P, Acerbi F, Albanese E, Tringali G, Broggi M, Franzini A, Broggi G: Application of intraoperative indocyanine green angiography for CNS tumors: Results on the first 100 cases. *Acta Neurochir Suppl* 109:251-257, 2011
- Ferrolli P, Acerbi F, Tringali G, Albanese E, Broggi M, Franzini A, Broggi G: Venous sacrifice in neurosurgery: New insights from venous indocyanine green videoangiography. *J Neurosurg* 115(1):18-23, 2011
- Ferrolli P, Nakaji P, Acerbi F, Albanese E, Broggi G: Indocyanine green (ICG) temporary clipping test to assess collateral circulation before venous sacrifice. *World Neurosurg* 75(1):122-125, 2011
- Hanneken AM, Miller NR, Debrun GM, Nauta HJ: Treatment of carotid-cavernous sinus fistulas using a detachable balloon catheter through the superior ophthalmic vein. *Arch Ophthalmol* 107(1):87-92, 1989
- Jiang C, Lv X, Li Y, Wu Z, Shi J: Surgical access on the superior ophthalmic vein to the cavernous sinus dural fistula for embolization. *J Neurointerv Surg* 5(3):e13, 2013
- Klisch J, Huppertz HJ, Spetzger U, Hetzel A, Seeger W, Schumacher M: Transvenous treatment of carotid cavernous and dural arteriovenous fistulae: Results for 31 patients and review of the literature. *Neurosurgery* 53(4):836-856, 2003
- Lee JW, Kim DJ, Jung JY, Kim SH, Huh SK, Suh SH, Kim DI: Embolisation of indirect carotid-cavernous sinus dural arteriovenous fistulae using the direct superior ophthalmic vein approach. *Acta Neurochir* 150(6):557-561, 2008
- Lv X, Jiang C, Li Y, Yang X, Wu Z: Percutaneous transvenous embolization of intracranial dural arteriovenous fistulas with detachable coils and/or in combination with Onyx. *Interv Neuroradiol* 14(4):415-427, 2008
- Miller NR, Monsein LH, Debrun GM, Tamargo RJ, Nauta HJ: Treatment of carotid-cavernous sinus fistulas using a superior ophthalmic vein approach. *J Neurosurg* 83(5):838-842, 1995
- Monsein LH, Debrun GM, Miller NR, Nauta HJ, Chazaly JR: Treatment of dural carotid-cavernous fistulas via the superior ophthalmic vein. *AJNR Am J Neuroradiol* 12(3):435-439, 1991
- Naqvi J, Laitt R, Leatherbarrow B, Herwadkar A: A case of a spontaneous intraorbital arteriovenous fistula: Clinico-radiological findings and treatment by transvenous embolisation via the superior ophthalmic vein. *Orbit* 32(2):124-126, 2013
- Quiñones D, Duckwiler G, Gobin PY, Goldberg RA, Viñuela F: Embolization of dural cavernous fistulas via superior ophthalmic vein approach. *AJNR Am J Neuroradiol* 18(5):921-928, 1997
- Raabe A, Nakaji P, Beck J, Kim LJ, Hsu FP, Kamerman JD, Seifert V, Spetzler RF: Prospective evaluation of surgical microscope-integrated intraoperative near-infrared indocyanine green videoangiography during aneurysm surgery *J Neurosurg* 103(6):982-989, 2005
- Reis CV, Gonzalez FL, Zabramski JM, Hassan A, Deshmukh P, Albuquerque FC, Preul MC: Anatomy of the superior ophthalmic vein approach for direct endovascular access to vascular lesions of the orbit and cavernous sinus. *Neurosurgery* 64(5 Suppl 2):318-323; discussion 323, 2009.
- Woitzik J, Horn P, Vajkoczy P, Schmiedek P: Intraoperative control of extracranial-intracranial bypass patency by near-infrared indocyanine green videoangiography. *J Neurosurg* 102(4):692-698, 2005
- Wolfe SQ, Cumberbatch NMA, Aziz-Sultan MA, Tummala R, Morcos JJ: Operative approach via the superior ophthalmic vein for the endovascular treatment of carotid cavernous fistulas that fail traditional endovascular access. *Neurosurgery* 66(6 Suppl Operative):293-299; discussion 299, 2010
- Zaidi HA, Ablal AA, Nakaji P, Chowdhry SA, Albuquerque FC, Spetzler RF: Indocyanine green angiography in the surgical management of cerebral arteriovenous malformations: Lessons learned in 130 consecutive cases. *Neurosurgery* 10 Suppl 2:246-251; discussion 251, 2014
- Zhong X, Hamill M, Collier B, Bradburn E, Ferrara J: Dynamic multiplanar real time ultrasound guided infraclavicular subclavian vein catheterization. *Am Surg* 81(6):621-625, 2015