



Sciatic Nerve Hypertrophy with Klippel-Trenaunay Syndrome: A Case Report

Siyatik Sinir Hipertrofisi ve Klippel-Trenaunay Sendromu Birlikteliği: Olgu Sunumu

Ilker ILHANLI¹, Ozlem KESKIN², Erhan ARSLAN³, Mehmet EKIZ⁴

¹Giresun University, School of Medicine, Department of Physical Medicine and Rehabilitation, Giresun, Turkey

²Giresun University, School of Medicine, Department of Cardiovascular Surgery, Giresun, Turkey

³Giresun University, School of Medicine, Department of Neurosurgery, Giresun, Turkey

⁴Giresun University, School of Medicine, Department of Emergency Medicine, Giresun, Turkey

Corresponding Author: Ilker ILHANLI / E-mail: ilkerilhanli@hotmail.com

ABSTRACT

A 73-year-old female patient who had severe neuropathic pain due to sciatic nerve hypertrophy with the Klippel-Trenaunay Syndrome has been presented. Localized hypertrophic neuropathy is in one region and characterized by concentric proliferation of Schwann cells around the axon. It is very rare in the absence of generalized hypertrophic neuropathy. Very little is known about the etiology and the course of this neuropathy. Klippel-Trénaunay-Syndrome (KTS) is a rare syndrome characterized by hemangioma, abnormalities of the venous and lymphatic systems, and limb enlargement due to soft tissue and bone hypertrophy.

KEYWORDS: Sciatic nerve, Hypertrophic neuropathy, Klippel Trenaunay syndrome

ÖZ

Siyatik sinir hipertrofisine bağlı ciddi nöropatik ağrısı olan Klippel Trenaunay Sendromlu 73 yaşında bir bayan hasta sunulmuştur. Lokalize hipertrofik nöropati tek bölgededir ve akson etrafındaki Schwann hücrelerinin proliferasyonu ile karakterizedir. Yaygın bir polinöropati olmadan görülmesi nadirdir. Bu nöropatinin etiolojisi ve seyri hakkında çok az şey bilinmektedir. Klippel Trenaunay Sendromu ise همانجیوم, венöz ve lenfatik sistem anormallikleri, yumuşak doku ve kemik hipertrofisine bağlı ekstremité büyümesiyle karakterize nadir bir sendromdur.

ANAHTAR SÖZCÜKLER: Siyatik sinir, Hipertrofik nöropati, Klippel Trenaunay sendromu

INTRODUCTION

Localized hypertrophic neuropathy (LHN) is a rare clinical condition characterized by progressive motor deficits in a single peripheral nerve. Clinically, progressive weakness and sensory loss arise due to loss of nerve function. Macroscopically, thickening is observed in the affected segment of peripheral nerve. Microscopically, concentric proliferation of Schwann cells around axons are seen, which is characterized by typical onion-shell formation (4).

The most frequently entrapped nerves in the lower extremities are the lateral femoral cutaneous nerve, femoral nerve, saphenous nerve, obturator nerve, sciatic nerve, common peroneal nerve, its superficial and deep branches, tibial nerve, and interdigital nerve (3,14). Due to sciatic nerve entrapment, hip pain, and sciatic nerve pain radiating along the trace are seen.

The Klippel-Trenaunay Syndrome (KTS) has been described in 1900, and is characterized by (a) soft tissue and bone hypertrophies of the extremity, (b) mostly port-wine style cutaneous vascular nevi in the affected extremity, and (c)

varicose veins and lymphatic anomalies. Other features are the lack of clinical arteriovenous shunts and the presence of deep venous anomalies including atresia of deep veins, hypoplasia or aneurysmal dilatation, external compression of fibrous bands, valve insufficiency or agenesis (1, 6,12). KTS etiology is still not definitive. Although it is mostly sporadic, it has been reported that there is an autosomal dominant hereditary component caused by gene defects (15).

CASE REPORT

A 73-year-old female patient who had been hypertensive and diabetic for nearly 20 years was admitted to our clinic with severe burning pain in the right lower extremity. The right hip and knee were in flexion posture. Because of the severe burning pain, the straight leg raising test, muscle strength and sensory tests could not be done. Varicose veins in the right lower extremity, increased diameter of the thigh and calf of the right lower extremity, and hyperpigmentation of the skin were found (Figure 1). Bilateral lower extremity arterial system pulses were palpable. There was no evidence of ischemia. There was no temperature difference on venous examination. Homan's test was negative. On lumbar magnetic

resonance imaging (MRI) of the patient, there was no pathology that could cause pain in the legs. However, sciatic nerve hypertrophy was detected from the sacrum to the shaft of the femur in the hip MRI (Figure 2,3). In the MRI and venous Doppler ultrasonography of the right lower extremity, reflux of the right saphenofemoral junction and expansion of deep venous structures were identified (Figure 4).

Tramadol treatment, pregabalin 150 mg per day divided into 2 doses, and calcium dobesilate 1000 mg per day divided into 2 doses were started. After 1 week, pregabalin was increased to 300 mg daily divided into 2 doses because of ongoing complaints. One week later, the patient's complaints began to decrease, and tramadol was stopped, and the dose of pregabalin increased to 600 mg per day divided into 2 doses. After 3 days, the patient's complaints showed almost complete recovery. On physical examination, the straight leg raising test was negative, muscle strength test was 5/5, Valleix points were minimal painful, L3-L4-L5-S1 dermatomes were hypoesthetic on the right leg, there was 14 cm diameter difference between left and right, and the right lower limb was one cm longer than the left. The patient was diagnosed with neuropathic pain due to sciatic nerve hypertrophy and Klippel-Trenaunay Syndrome, and compression stockings were prescribed. 1 month later, the pregabalin dose was reduced to 300 mg per day, but because of an increase in the pain and numbness we decided to continue with pregabalin 600 mg per day, and calcium dobesilate 1000 mg per day. In the 4-month follow-up, there was no increase in the patient's complaints.

DISCUSSION

Various peripheral nerves may be involved in localized hypertrophic neuropathy. Frequently the brachial plexus, and the peroneal, tibial, sciatic, radial, and median nerves are affected. Facial nerve and spinal root involvement has also been reported (7, 9, 11, 13, 16).

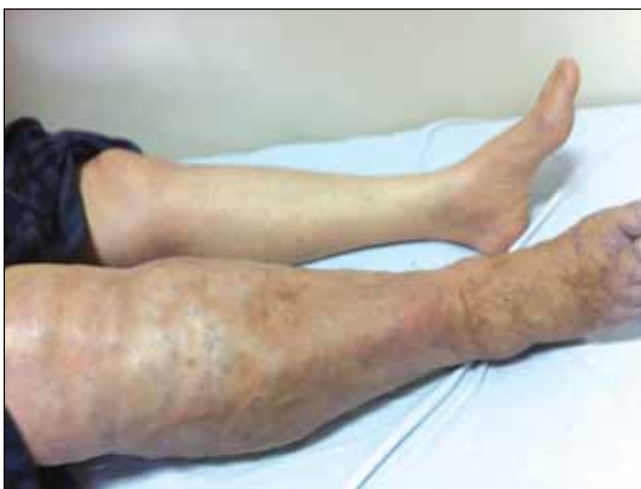

Figure 1: Varicose veins in the right lower extremity, increased diameter of the thigh and calf of the right lower extremity, and hyperpigmentation of the skin.

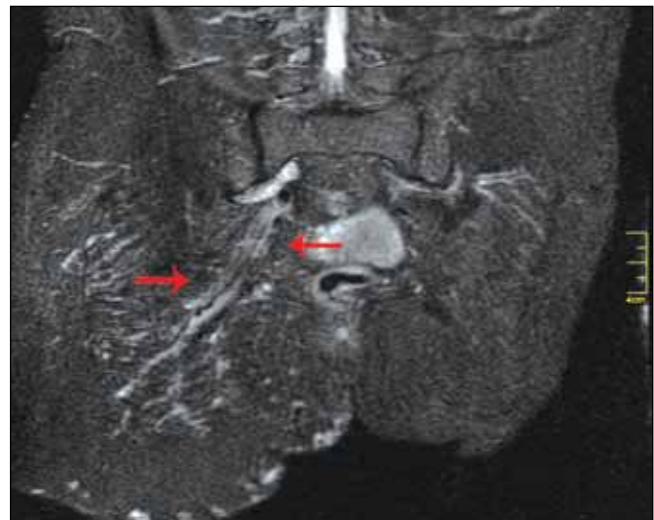


Figure 2: Sciatic nerve hypertrophy in hip MRI.

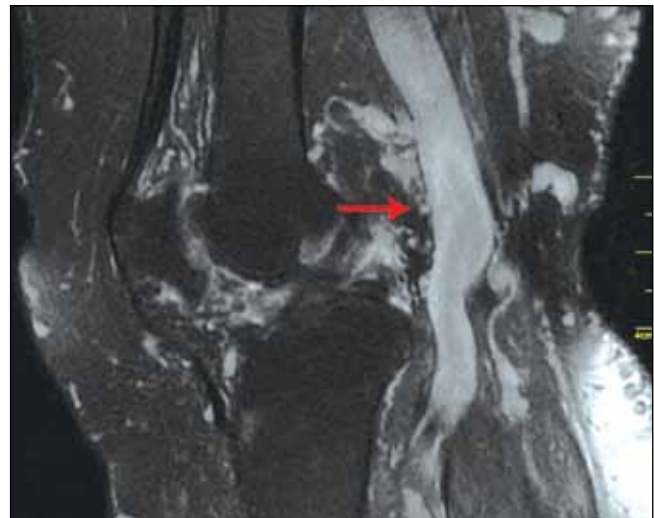


Figure 3: Sciatic nerve hypertrophy in hip MRI.

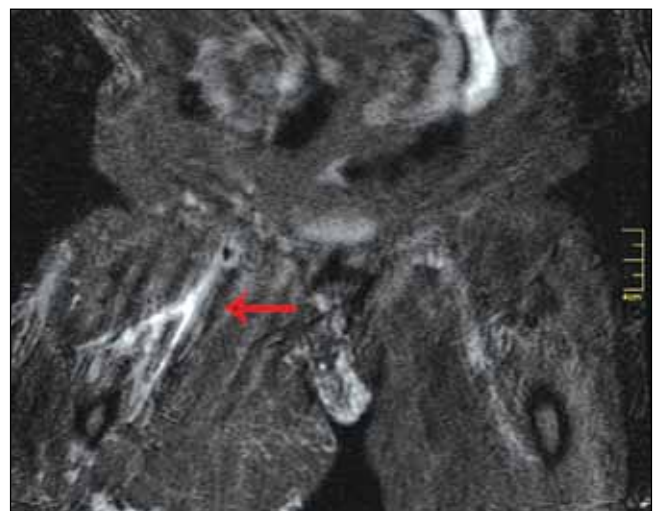


Figure 4: Expansion of deep venous structures in limb MRI.

Typical onion-shell formation is reported in the histological examination of the lesions of biopsied patients (7, 9, 11, 16). This is a dedicated structure that is formed by the concentric proliferation of Schwann cells. Onion-shell formation is seen in many polyneuropathies, and it is not a specific finding (4). The main differential diagnosis is that there is a single peripheral nerve neuropathy in a particular segment, without a generalized polyneuropathy. When we look at the literature, the majority of patients with LHN are painless. In the 15-year retrospective study of Gruen et al., it was reported that 6 of 14 patients with surgical treatment had pain (7). In our patient, the presence of severe neuropathic pain is different than in some articles on sciatic nerve hypertrophy (11,13). In addition to our patient, pain and tenderness that occur while pressing on the sciatic nerve trace were observed in the majority of patients. Because of the severe burning pain, muscle strength could not be tested in the initial examination. However, in contrast to the progressive loss of muscle strength that is reported in some literature, we did not observe muscle strength loss in our patient's examinations after her complaints subsided. We could show the hypertrophy of the sciatic nerve with MRI. In the diagnosis and localization of the lesion, early MRI is very important as mentioned in the literature (11). The Klippel-Trenaunay syndrome (KTS) is a congenital syndrome with the combination of varicosities, skin blemishes, and limb hypertrophy. Our patient declared that she was aware of the changes in her right leg since her youth. In a study of 252 patients, 63% had the triad of varicose veins, limb hypertrophy and cutaneous vascular naevi, 37% had just two of the triad, and in 94% of patients with KTS, one of the triad was noted shortly after birth (2).

None of the reports emphasize any gender differences or significant family history. The lower limbs are more often affected (88% to 95%), unilateral involvement occurs in 85% of cases, upper and lower limb involvement in 15% of cases, and four-extremity involvement is very rare (2, 5, 10). Due to the venous congestion and the lymphedema, pain, heaviness and fatigability are some of the common presenting complaints. In our case, there was only involvement of one limb.

In a study conducted at the Mayo Clinic on KTS, port-wine hemangiomas were found in 98%, varicose veins or venous malformations in 72% and limb hypertrophy in 67% (8).

Limb hypertrophy usually manifests at a later age. The main reason is the excess of soft tissue and fat. Hypertrophy of bone tissue contributes to the enlargement of the extremity, and venous expansions are seen. Amaragiri and Labropoulos et al. reported that in a study with 144 patients, limb hypertrophy was observed in 93%. Increase in the length was observed in 66% and increase in the girth in 69% (2).

The venous anomalies in KTS are mainly varicosities, which are more extensive and larger than the usual. The other common anomalies of the venous system in KTS are hypoplasia, agenesis, venous and valvular failure and aneurysmal dilation of the deep venous system. In our case, there were varicose veins along the right lower limb, and deep venous system expansion was identified.

The present case differs from the literature due to neuropathic pain secondary to hypertrophy of the sciatic nerve, and demonstration of the association of the Klippel-Trenaunay syndrome. With an increased number of cases, clinicians will be able to revise the possible diagnosis earlier in these cases, especially when they present with leg pain. In the long-term follow-up of this disorder, pregabalin treatment would be appropriate in patients with neuropathic pain.

REFERENCES

1. Al-Salman MM: Klippel-Trénaunay syndrome: Clinical features, complications, and management. *Surg Today* 27: 735-740, 1997
2. Amaragiri SV, Labropoulos N: Congenital venous malformations. In: Labropoulos N, Stansby G (eds), *Venous and Lymphatic Disease*. New York: Taylor & Francis, 2006: 472
3. Dumitru D, Amato A, Zwarts M: *Electrodiagnostic Medicine*. Philadelphia: Hanley & Belfus, 2002
4. Dyck PJ, Chance P, Lebo R, Carnley JA: Hereditary motor and sensory neuropathies. In: Dyck PC, Thomas PK, Griffin JW, Low PA, Poluslo JF (eds), *Peripheral Neuropathy*. Philadelphia: Saunders, 1993: 1102-1110
5. Gloviczki P, Hollier LH, Telander RL, Kaufman B, Bianco AJ, Stickler GB: Surgical implications of Klippel-Trenaunay syndrome. *Ann Surg* 197: 353-362, 1983
6. Gloviczki P, Stanson AW, Stickler GB, Johnson CM, Toomey BJ, Meland NB: Klippel-Trenaunay syndrome: The risks and benefits of vascular interventions. *Surgery* 110: 469-479, 1991
7. Gruen JP, Mitchell W, Kline DG: Resection and graft repair for localized hypertrophic neuropathy. *Neurosurgery* 43(1): 78-83, 1998
8. Jacob AG, Driscoll DJ, Shaughnessy WJ, Stanson AW, Clay RP, Gloviczki P: Klippel-Trénaunay syndrome: Spectrum and management. *Mayo Clin Proc* 73: 28-36, 1998
9. Kania R, Hatem DC, Bouccara D, Cyna-Gorse F, Lisvoski F, Hénin D, Sterkers O: Hypertrophic neuropathy of the facial nerve. *Ann Otol Rhinol Laryngol* 110: 257-262, 2001
10. Mulliken J, Young A: Combined vascular malformations. In: Mulliken J (ed), *Vascular Birthmarks: Hemangiomas and Malformations*. Philadelphia:WB Saunders, 1988: 159-172
11. Saurez GA, Giannini C, Smith BE, Windebank AJ: Localized hypertrophic neuropathy. *Mayo Clin Proc* 69: 747-748, 1994
12. Servelle M: Klippel and Trenaunay's syndrome 768 operated cases. *Ann Surg* 201:365-373, 1985
13. Simmons Z, Mahadeen ZI, Kothari MJ, Powers S, Wise S, Towfighi J: Localized hypertrophic neuropathy: Magnetic resonance imaging findings and long term follow-up. *Muscle Nerve* 22(1): 28-36, 1999
14. Stewart JD: Compression and entrapment neuropathies. In: Dyck PJ, Thomas PK, Griffin JW, Low PA, Poluslo JF (eds), *Peripheral Neuropathy*. Philadelphia:Saunders, 1993: 961-979
15. Whelan AJ, Watson MS, Porter FD, Steiner RD: Klippel-Trenaunay-Weber syndrome associated with a5: 11 balanced translocation. *Am J Med Genet* 59: 492-494, 1995
16. Yassini PR, Sauder K, Sydney SS, Kaufma HH, Bloomfield SM: Localized hypertrophic mononeuropathy involving spinal roots and associated with sacral meningocele. *J Neurosurg* 79: 774-778, 1993