

## THE USE OF MUSCLE FASCIA FOR MICROVASCULAR INTERPOSITIONAL GRAFTS (\*)

Nezih Özkan, M.D. Ali Çetin Sarıoğlu, M.D.

Haydarpaşa Numune Hospital, Department of Neurosurgery,  
Cerrahpaşa Medical Faculty, Department of Neurosurgery

Turkish Neurosurgery 1 :114-118, 1990

### SUMMARY :

*In this study, muscle fascia removed from over the biceps femoris muscle was used as microvascular interpositional graft material in 67 rats. The faces of the cleaned fascia were rolled in order to form the luminal surface of the graft and were sutured in the form of a tube in different diameters and lengths. In group I, the grafts were 2.5mm in diameter and 2 to 7mm in length in the common carotid artery. In group II, the abdominal aorta was preferred in order to apply longer grafts. These were prepared 4mm in diameter and 10-13mm in length.*

*The evaluations of the anastomoses were made 2 hours, 24 hours and 3 weeks after operation. Twenty anastomoses were examined by SEM for morphological inspection. At the end of 3rd week, patency rates demonstrated 22.2 and 23.1 percent in groups I and II respectively. Patent anastomoses revealed remarkable endothelialization on SEM by 3 weeks postoperatively. Technical difficulties have been also evaluated for this kind of anastomoses.*

### KEY WORDS :

*Graft patency, Microvascular anastomosis, Muscle fascia.*

Damage to vessel walls may develop as a result of trauma, autoimmune, infection, tumoral and other effects, and can cause serious nutritional abnormalities in tissues which do not have enough collateral circulation. Therefore, vascular grafts are used to provide the circulation for physiological conditions and in a way, to fit the damaged vessel segment.

The grafts used for different purposes can be formed from natural tissues as well as artificial materials. Among natural grafts, vein grafts are used frequently. Vein grafts are widely used in arterial bypass operations. Other natural grafts are umbilical vein and amnion membrane which are used as interpositional graft material(3,6). Artificial grafts like polytetrafluoroethylene (PTFE), fibrous polyurethane, silicon and dacron tube can also be used in anastomoses (5,8,11,14,17).

In this study, muscle fascia, shaped in tube form is used as the graft material. The purpose here is to show whether the muscle fascia can be used as an interpositional graft. The technical difficulties and patency rates in this type of anastomosis are also evaluated.

### MATERIALS AND METHODS

#### A – Surgery Method :

Sixty-seven rats were used in this study. The rats which had an average weight of 350 grams were anesthetized with innover-vet (fentanyl 0.4mg+droperidol 120mg+metlyprobenl. 8mg+probyl paraben 0.2mg) intramuscularly. They were positioned supine, on a standart rat experimental table. First, the skin on the right thigh was incised, and a portion of fascia, approximately the desired length for the graft was dissected from the biceps femoris muscle, very carefully. The loose connective tissue and fatty tissue on the fascia was completely dissected, in order not to leave any remnants. The faces of the cleaned fascia portions were turned over on themselves to form the luminal surface of the graft, and sutured in the form of a tube, using 10.0 suture material. In all experiments, grafts of different lengths were prepared with this technique.

The animals in this experiment were separated in to two groups.

a. Group I (carotid group): This group contained 54 rats. The grafts used were 2.5mm diameter and

(\*) This study carried out by Nezih Özkan in the Microneurosurgery Laboratory of the Neurosurgery Department in Zurich University Hospital in 1988 was supported by "Erziehungsdirektion des Kantons Zurich"

2 to 7mm length. The skin was incised transversely in the neck, and the right common carotid artery was found by retraction of the sternocleidomastoid muscle laterally. Along its length this vessel was separated from the surrounding tissues by dissection, and microvascular clips were put on the distal and proximal ends. After that, portions of 2 to 4 mm in length were cut, according to the desired graft length. An end-to-end anastomosis was made to the carotid artery with the tube-shaped fascia graft (Fig.1).




Fig.1 : Interposition of tube shaped fascia graft to carotid artery by end-to-end anastomosis.

b. Group II (Aorta group) : This group contained 13 rats. Here the use of the abdominal aorta was preferred, in order to apply a longer graft. For anastomoses a median incision is made in the skin. Aorta dissection was done, after cutting the peritoneum and retracting of intestine laterally. The aorta segment was clipped at distal and proximal sections protecting the renal arteries. For a 10-13mm graft, a 5 to 6 mm aorta segment was excised. In place of it, the tube shaped fascia graft, 4mm in diameter, was placed with end-to-end anastomosis technique.

## B – Control of Anastomoses :

a. Doppler ultrasound and angiography: two hours after the anastomoses were performed, they were checked with doppler ultrasound and then the wounds were closed. This was repeated after 24 hours and patent anastomoses were left for a period of 3 weeks, the end of which the anastomoses were re-explored and the patency of the grafts was checked directly with doppler. The patent anastomoses were also checked with angiography. In group I, 5cc urographin 60 % was given with a catheter placed into the aorta transabdominally. An x-ray of the anastomosis area was then obtained. For grup II, 5cc contrast material was given with a catheter, inserted into the aorta, from the right carotid artery, then the x-ray of the aorta was taken.

b. Scanning electron microscope (SEM) inspection: Examination of 20 anastomoses was made by SEM for morphological inspection. For this, a plastic catheter was placed in the aorta to give 80ml of Ringer's lactate solution, to flush out any thrombosis be in the graft. The inferior vena cava was incised to permit free exit of the perfusion fluid. After this, the anastomoses were carefully excised and then cut into a V shape to distinguish the proximal end. Finally, they were placed in formaldehyde, and investigated with SEM method.

## RESULTS

In total, 67 anastomoses were performed with tube shaped fascia grafts. 54 of these were in the common carotid artery segment, and form group I. The remaining 13 were in the aorta segment (group II). The length of the graft materials ranged from 2 to 13mm. 33(49.2 %) of 67 anastomoses were patent in the first 3 hours and were considered in this evaluation. In group I, 29(53.7 %) of the 54 anastomoses and in group II, 4(30.7 %) of the 13 anastomoses were determined as patent by doppler.

In 9 of the 29 anastomoses in group I, hematomas occurred between the 5th and 21st days. When these were re-explored, widespread hematomas were found in the operative field and the grafts were not patent. Thrombosis was found in five. Thrombosis formation was seen during the third week in two, in the first day in one and in the third hour in another. The remaining anastomoses were re-opened at the end of the third week and re-checked. 12(22.2 %) of them were patent. In group II, in one of the four patent anastomoses, thrombosis was found during the second week. The remaining 3 (23.1 %) were patent.

Angiographic investigations of the 15 patent anastomoses in both groups were made at the end of the third week. Blood flow was seen along the graft in nine of these, and aneurysmal formation was seen in six. These were in fusiform, round or lobular shapes, from 4 to 10mm in diameter. It was observed that all aneurysmal dilatation occurred in grafts smaller than 4mm.

In the carotid group, three animals had patent anastomoses in the first hours. But died from anesthesia complications within 6 hours. The anastomoses of these animals were inspected and thrombosis was not seen in the graft or in the vessel.

In the carotid group, the diameter of the grafts used was 2.5mm and the length from 2 to 7mm. The pre-operative graft length and patency rate are demonstrated in Table I. A decreased patency of the anastomoses is seen when the graft length exceeded 5mm. In short anastomoses patency lasted longer, but in longer anastomoses there is no blood flow due to thrombosis formation. Of the 54 anastomoses 22(40.7 %) were nonpatent in the carotid group. Thrombosis formation was seen around the sutures, and sometimes along the graft in all these animals when the anastomosis site was re-opened.

As mentioned the abdominal aorta, usually 4mm in diameter was chosen in group II, in order to try longer grafts. Of anastomoses which had lengths from 10-to 13mm performed, 9(69.2 %) were not patent in the first hours after operation due to thrombosis. Among the four patent anastomoses, one of them was opened in the 15th day since general condition of the animal worsened, and thrombosis was seen. The remaining three were re-opened during the third week and checked with ultrasound doppler and angiography.

Vessel grafts taken from the experimental animals were investigated with SEM to evaluate endothelium development. It was seen that endothelial growth started from the proximal part. It was also found that new endothelium formed on the fibrin and white cells on the graft. The new endothelial layer was seen in the proximal parts of the graft after one week (Fig.2). In the graft, after three weeks, endothelium was also seen in the middle partion (Fig.3).

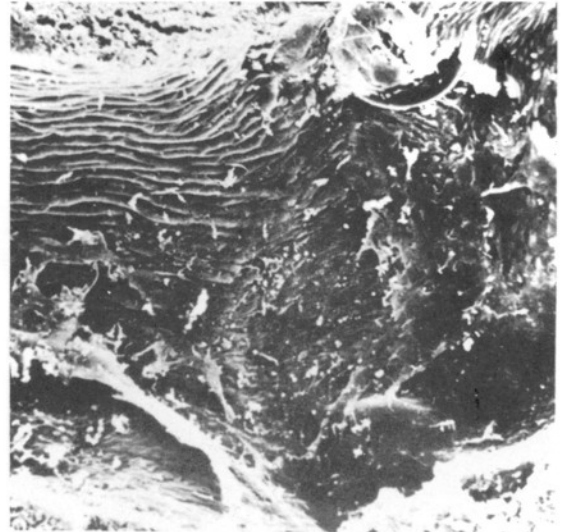


Fig.2 : Scanning electron micrographs of anastomotic site at one week X300



Fig.3 : Scanning electron micrograph of the graft luminal surface at three weeks. X450.

Table : 1

Graft length	Patency of graft		
	3rd hr	24th hr	3rd week
2mm	8	7	6
3mm	5	5	3
4mm	5	4	2
5mm	6	4	1
6mm	1	1	—
7mm	4	2	—
Total	29	23	12
Rate (%)	53.7	42.6	22.2

## DISCUSSION

Interpositional grafts are frequently used in vascular and reconstructive surgery to prevent severe dystrophias resulting from circulation disorders caused by a number of diseases affecting the vessel wall. Vein grafts rank first among the most frequently used interpositional grafts. Others, are polytetrafluoroethylene (PTFE) fibrous polyurethane, silicon and dacron tubes (5,8,11,14,17).

Although the results obtained with vein grafts are satisfactory, difficulty in obtaining the graft can occasionally be encountered. It is also suggested that dissection and preparation of vein grafts requires extra time and this consequently increases the morbidity rate (8). For this reason synthetic grafts have been employed but they have not been as good as the vein grafts (8,11,17). It has also been reported that amnion membrane and umbilical vein can be used as an interpositional graft (3,6). Taking into consideration that the umbilical vein is impervious, valveless, unbranched, uniform in diameter and can be obtained easily. Dardic et al (3), used it as a graft. Gray et al (6), used amnion membrane as a graft material on account of its availability, low antigenicity, cost-effectiveness, storability, biological properties and permeability.

In this study, muscle fascia was used as an interpositional graft material, but it was not possible to obtain a 100 % patency in the anastomoses performed. In the carotid group, the first check of the anastomoses demonstrated a patency rate of 53.7 % while the rate fell to 22.2 % by the end of the third week. In the aorta group these rates were 30.7 % and 23.1 % respectively. Thrombosis was observed immediately after anastomosis in 31 of 67 rats of both groups. A multitude of reasons can be given for the occurrence of early thrombosis: Inadequate removal of loose connective tissue and adipose tissue from the muscle fascia which will form vascular lumen, failure to give the tube graft of muscle fascia a uniform cylindrical shape, destruction of the tissue while suturing the tube and removing the connective tissue, inequality of the thickness of the fascia and the vascular wall. In addition, it is also necessary to mention technical failures during the anastomosis operation and the changes in blood flow.

Buncke et al (2), claim that thrombosis of grafts, unless otherwise proven is due to technical failure. Sundt III et al (15), have reported that in vein bypass grafts, thrombosis usually occurs within the first few hours to the first few days of the operation. Harashina (7) has not been completely successful in anas-

tomosis operations on the rat femoral artery heterograft. It is suggested that this could be due to technical reasons, in particular discrepancy in size.

Lidman et al. (11) have shown that synthetic materials are superior to homologous vein grafts for vascular substitutes. They reported a patency rate of 96 % for 2-3mm diameter grafts by the end of the second week in their study using PTFE.

Gray et al (6), have prepared the amnion membrane in a tube shape and used this as graft material in 120 rats. They obtained patency rates of 66.6 % and 96.6 % in femoral artery and aorta respectively. They explained the lower patency rate in the femoral artery group by the smaller diameter of the graft and slowness of the blood flow.

In our study, examination of the 20 materials by the SEM method revealed that, re-endothelialization of the proximal anastomosis sites and the luminal surface of the graft material occurred by the first and third week respectively. During the first few days fibrin and white cells covered the inner surface of the graft and subsequently they were covered by new endothelial cells.

Isogai et al (9), cut the femoral arteries of rats and performed end-to-end anastomoses. They then examined the anastomoses at various time periods and classified the morphological changes in four groups. The first stage lasted five minutes following anastomosis and was characterized by the formation of platelets on the exposed subintimal components. Stage II commenced approximately after the operation and was 3-4 days in duration. In this period, they recorded various degrees of platelet reaction, from the adhesion of platelets to the formation of a fibrin network, in which numerous platelets and red blood cells were trapped at the needle hole. Stage III was characterized by the formation of the endothelial layer. This stage was determined by the 6th day. Stage IV was characterized by a complete endothelium layer coverage of the thick fibrin network and the entire wound surface. This stage was completed by the 7th day.

Gelderman et al(4), have reported that in the end-to-side anastomoses of the distal portion of the right carotid artery with the left carotid artery, endothelium regeneration began on the 3rd day and was completed within one week. Baxter et al (1), have observed in their study that the endothelium started growing from the luminal border of the thrombus on the 8th to 12th days. O'Brien (13) observed in his own series of anastomoses that re-endothelialization was completed within four weeks and recorded that this pro-



cess was more rapid in the arteries compared to the veins.

Nightingale et al (12). has shown with SEM that endothelium formation was achieved through the migration of endothelial cells from the clamp sites to the anastomosis region. He observed that re-endothelialization was completed within two weeks. Thurston et al (16). reported that in microvascular damage, re-endothelialization was carried out by proliferation of endothelial cells in the adjacent intact region and completed within one week. Reichle et al (14). have observed that dacron grafts were partially covered with endothelium by the 27th month. Tizian (17) has shown that the endothelium layer grew within one month in silicon grafts and within three months in expanded PTFE grafts.

Graham et al (5). performed 26 to 29 cm long thoracoabdominal bypasses with dacron graft and have covered a 6 cm middle portion of the graft externally with the endothelial surface of the jugular vein dissected beforehand in grup I. In group II, they covered the middle part of the graft externally with fascia of the abdominal oblique apponeurosis. All protheses were evaluated on the 28th day. This study revealed that the luminal surfaces on the portion of the graft covered externally by vein was much better endothelialized than the region covered externally with fascia. Jacobs et al (10). have made a strip of a 1.5x0.4cm muscle fascia adjacent to the femoral vein, leaving the distal end attached to the muscle and passed the free end through the vein and left it free in the the lumen. They observed that the portion of the fascia strip which was in the lumen was covered with endothelium on the 2nd day and by the 4th day the whole surface was almost completely covered..

In our study, in 6 of the 12 anastomoses which were patent by the end of the 3rd week aneurysmal dilatation was seen.

Harashina (7) encountered six large aneurysms in the rat anastomoses which were performed with heterografts of rabbit femoral arteries. It was suggested that aneurysms which inevitably occurred in heterografts, were caused by the loss of elastic fibers in the graft wall by antigenic mechanisms. Dardic et al (3). considering that the umbilical vein is mainly formed by a collagen layer, treated the vein with tanning agents like gluteraldehyde and surrounded it with a polyester mesh. Among the eight patients on he has performed arterial bypasses aneurysm formation was not encountered.

## CONCLUSION

In this study, we have used muscle fascia as a new interpositional graft material for microvascular anastomoses. It was not possible to routinely achieve adequate anastomoses. This may be due to speical technical difficulties related to muscle fascia anastomoses, in addition to known difficulties of autologous vein and synthetic graft anastomoses. Nevertheless, SEM examination has shown that in this kind of graft, like autologous vein grafts, endothelialization readily occurred.

**Correspondence :** Nezih Özkan, M.D.  
Saatcibayırı Sebat Sokak 17/15 Hayriye 2 Apt.  
Gayrettepe-İSTANBUL

## REFERENCES

1. Baxter TJ, O'Brien BM, Henderson N, et al: The histopathology of small vessels following microvascular repair. *Br J Surg* 59:617-622, 1972
2. Bunche HJ, Alpert B, Shah KG: Microvascular grafting. *Clin Plast Surg* 5:185-194, 1978
3. Dardic H, Ibrahim IM, Sprayregen S; et al: Clinical experience with modified human umbilical cord vein for arterial bypass. *Surgery* 79:618-624, 1976
4. Gelderman PW, Berendsen W: Re-endothelialization of microvascular carotid end to side anastomosis in the rat. *J Neurosurg* 51:785-795, 1979
5. Graham LM, Harrell KA, Sell RL, et al: Enhanced endothelialization of dacron grafts by external vein Wrapping. *J Surg Res* 38:537-545, 1985
6. Gray KJ, Shenaq SM, Engelmann UH, et al: Use of human amnion for microvascular interpositional grafts. *Plast Reconstr Surg* 79:778-785, 1987
7. Harashina T: Arterial allografts and heterografts in microvascular surgery. *Br J Plast Surg* 31:16-18, 1978
8. Hess F, Jerusalem C, Braun B: A fibrous polyurethane microvascular prosthesis. *J Cardiovasc Surg* 24:509-515, 1983
9. Isogai N, Kamiishi H, Chichibu S: Re-endothelialization stages at the microvascular anastomosis. *Microsurgery* 9:87-92, 1988
10. Jacobs JWM, Limborgh JW: Implantation of a strip of fascia in the venous wall. *Acta Morphol Neerl-Scand* 22:115-122, 1984
11. Lidman DH, Faibi B, Daniel RK: Expanded polytetrafluoroethylene as a microvascular graft. *J Microsurg* 1:447-456, 1980
12. Nightingale G, Fogdestam I, O'Brien BM: Scanning electron microscope study of experimental microvascular anastomoses in the rabbit. *Br J Plast Surg* 33:283-298, 1990
13. O'Brien BM: Microvascular reconstructive surgery. In: *Histopathology of microvascular repairs*. London and New York: Churchill Livingstone, 1977. pp.79-101
14. Reichle FA, Stewart GJ, Essa N: A transmission and scanning electron microscopic study of luminal surgaces in dacron and autogenous vein bypasses in man and dog. *Surgery* 74:945-960, 1973
15. Sundt III TM, Sundt TM: Principles of preparation of vein bypass grafts to maximize patency. *J Neurosurg* 66:172-180, 1987
16. Thurston JB, Bunche HJ, Chater NL, et al: A scanning electron microscopy study of micro-arterial damage and repair. *Plast Reconstr Surg* 57:197-203, 1976
17. Tizian C: Patency rates in microvascular protshesis. *Br J Plast Surg* 34:72-75, 1981