

ADULT RESPIRATORY DISTRESS SYNDROME DUE TO CENTRAL NERVOUS SYSTEM LESIONS

Cengiz Kудay, M.D., Murat Hancı, M.D.,

Istanbul University, Cerrahpaşa Medical Faculty, Department of Neurosurgery

Turkish Neurosurgery 1 : 109-113, 1990

SUMMARY :

We present two patients without primary cardiopulmonary disease, who developed adult respiratory distress syndrome in response to lesions of the central nervous system. Clinical and laboratory investigations are described in detail and pertinent literature is reviewed.

KEY WORDS :

Adult respiratory distress syndrome, Pulmonary edema, Spinal cord injury, Subarachnoid hemorrhage.

Adult Respiratory Distress Syndrome (ARDS) is a clinical entity which occurs as a result of damage sustained by the alveoli which are the units ensuring gas exchange in the lungs and by the capillary bed surrounding them. It is the common result of direct or indirect damage to the alveolocapillary membrane rather than a disease, presenting with inflammation of the pulmonary parenchyma, decrease of lung compliance related to the increase of permeability, serious hypoxemia and widespread infiltration on pulmonary X-rays.

It may occur by such direct effects as aspiration of gastric content, smoke inhalation, diffuse pneumonia, lipid embolus and non-penetrating thoracic trauma as well as by indirect injuries such as systemic sepsis, polytrauma related to such drugs as chlorodiazepoxide, salicylates, blood transfusion, pancreatitis, shock due to various causes, injuries of the medulla spinalis or intracranial hemorrhage. Although different rates have been reported, the common opinion is that mortality is high (3,8).

CASE REPORTS

1. M.U., a 49-year-old female patient with no history of pulmonary trouble was brought urgently to our clinic on 29.6.1989 with headache, vomiting and loss of consciousness. As a result of examinations, she was diagnosed as having grade IIa subarachnoid hemorrhage and was hospitalized. On 2.7.1989 dyspnea and tachypnea of acute onset, diffuse crackling rattles, more on the lung bases and diffuse infiltration on pulmonary X-ray were established and, assuming she had ARDS, oxygen inhalation, antibiotics and diuretics were started. On 4.7.1989 bronchodilators and corticosteroids were added to the treatment as there was no improvement in the general condition of the patient. On 7.7.1989, the steroid dose was reduced as clinical and radiological improvement was observed. On 24.7.1989, the patient underwent surgery for ICA aneurysm clipping. She recovered and was discharged on 31.7.1989. There have been no problems at follow-up since then. (Table 1, Fig.1, 2).

Table : 1

PH	PO ₂	PCO ₂	HCO ₃	ABE	SAT	BR.	TYP	FIO ₂	DATE
7.455	40.7	34.3	25.2	1.9	80.0	SB	f26/min	0.21	02/07
43.200	56.8	31.8	17.8	-6.5	87.9	SB		0.21+41t	03/07
47.900	196.2	39.1	19.7	-5.5	90.0	SB		0.21+10lt	04/07
46.000	166.0	32.2	16.9	-7.6	99.1	SB		0.2+10lt	09/07
31.100	107.0	26.4	21.0	-1.5	98.5	SB		0.21+21t	21/07

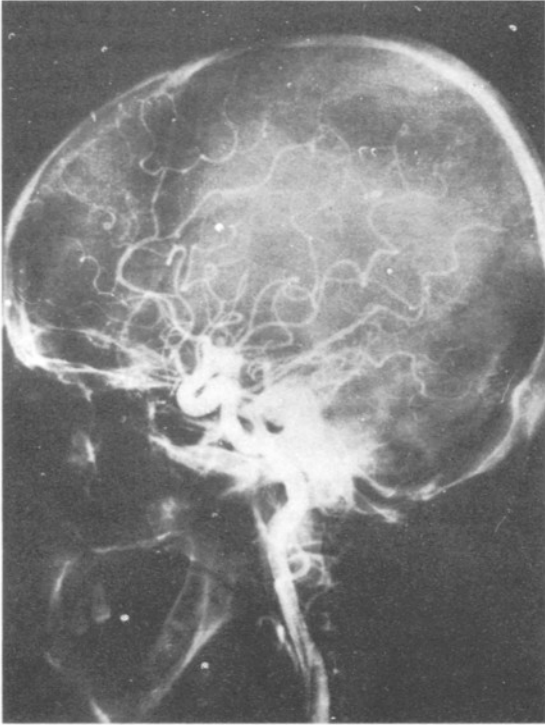


Fig.1 : Lateral carotid angiogram showing an ICA anevrysm.

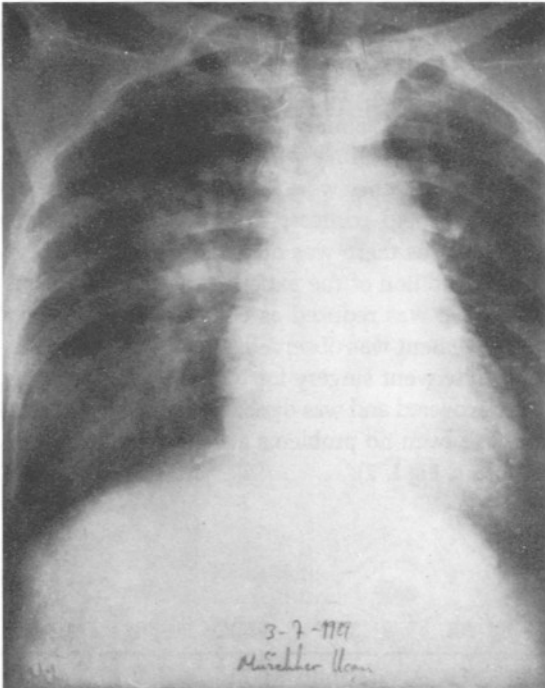


Fig.2 : Chest X-ray showing diffuse infiltration.

II. D.M., a 45-year-old female had no history of lung disease. On 17.4.1989 the patient, who had complained of progressive tetraplegia for one year, was hospitalized. It was established that there was medullary compression related to the posterior displacement of the dens axis. The patient had a C1-C2 posterior fusion on 29.5.1989 but when her complaints increased she again underwent operation on 8.6.1989 and C1 laminectomy + Occ-C2 fusion was performed. However when tetraparesis changed into spastic tetraplegia in the post-operative period, it was observed that the compression on the medulla of dens axis continued and the patient underwent surgery for the third time on 22.6.1989 when dens resection was carried out by the transoral route. The post-operative tetraplegia changed to spastic tetraparesis. After carrying out tracheotomy, dyspnea was observed on 27.6.1989 and oxygen inhalation was started which relieved the condition. Later the same day when bloody froth came out of the tracheotomy tube, pulmonary edema was considered and a cardiotonic and a diuretic were administered, but it was established that in the arterial gas obtained there was no improvement and the patient was put on a respirator. Pentothal perfusion was started and corticosteroids of high dosage and colloid perfusion were administered. Diffuse infiltration was observed on pulmonary X-rays. From the sample of blood gases it was detected that oxygenation was insufficient so PEEP was started. Shortly after, a drop in the blood pressure and braycardia appeared and dopamin perfusion was started. Oxygenation was observed to be better after the elevation in blood pressure, but the patient's blood pressure began to drop again at 7 am. despite vasopressor agents, and she died at 11 am. (Table : 2, Fig. 3,4).

Table II

PH	PO2	PCO2	HCO3	ABE	SAT	BR.	TYP	FIO2	DATE
42.200	100.0	42.2	21.8	-2.7	97.3	SB		0.21+41t	20/06
36.200	53.4	34.0	22.9	-0.5	88.6	SB		0.21	27/06(10:44)
7.451	115.9	34.3	23.8	0.0	98.5	SB	f28/min	0.21+81t	27/06(16:00)
7.409	37.7	44.1	26.7	2.8	72.9	SB	f35/min	0.21+81t	27/06(21:00)
7.405	44.2	43.0	26.6	2.0	80.2	CMV		1.VT 500 f14/min	28/06(00:30)
7.329	42.5	54.5	28.4	2.3	74.1	CMV		1.VT 500 f16/min	28/06(02:00)
7.384	78.6	43.3	25.5	0.8	95.1	CMV +REEP 10cm1,		VT 500 f16/min	28/06(04:00)

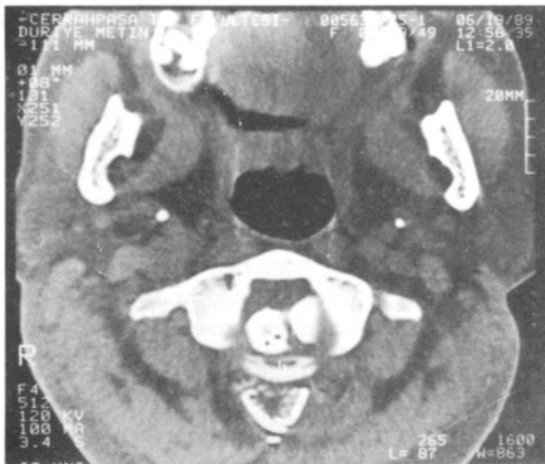

Fig 3 : IT iohexol-enhanced axial CT scan showing medullary compression by displaced dens axis.

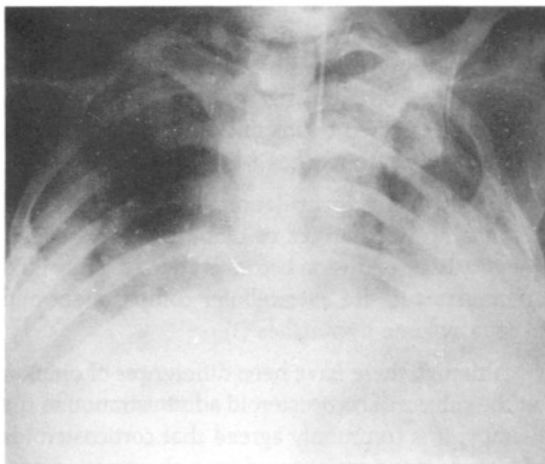


Fig 4 : Chest X-ray showing diffuse infiltration and a small ventral wedge-shaped opacity by displaced dens axis.

DISCUSSION

Although ARDS was described for the first time in the World War I years, it gained recognition by studies published especially after the Korean and Vi-

etnamese Wars. Ashbaugh described the clinical picture developing after injuries in civilian life and suggested the now widely-accepted term ARDS because of its similarity to IRDS. This syndrome which has had many synonyms such as wet lung, shock lung, congestive atelectasia, Danang lung, was widely known as ARDS after Ashbaugh's suggestion.

The clinical picture of ARDS was studied by Gomez who divided it into four periods (7):

1. The period when dyspnea and tachypnea occur but the lesion is not detected on pulmonary X-rays.
2. When hypoxemia begins, cyanosis appears and minimal lesions are seen on pulmonary X-rays.
3. The period when pulmonary compliance is decreased, deep hypoxemia occurs and respiratory insufficiency is established.
4. The terminal period with the presence of unrelieved hypoxemia, respiratory insufficiency and metabolic acidosis despite oxygen administration.

This syndrome may or may not progress depending on the seriousness and nature of the causative factors and the resistance of the patient. The instability of the ventilation/perfusion ratio and intrapulmonary shunts are the primary causes of hypoxemia. As a result of opened shunts, alveoli which are ventilated cannot be perfused, hence physiological dead space increases and pulmonary compliance diminishes due to the accumulation of fluid in the interstitium and alveoli. As a result, terminal air passages become clogged, pulmonary vascular resistance increases because of hypoxia, vasoconstriction and increased fluid pressure and as a result ventilation/perfusion instability becomes aggravated. With the resultant hypoxemia, lactic acid accumulates and tissue metabolism is considerably disturbed, (22).

Although it has been known that the damage in ARDS is in the alveocapillary membrane, the mechanism is not precisely known. Arachydonic acid and

its metabolites, beta endorphines, fibrin, FDP, complement, platelets, free fatty acids and proteolytic enzymes are considered as mediators which play a part in the condition.

Now let us examine ARDS, which we know appears depending on the lesions of the central nervous system, in the historical context. Weismann attracted attention by indicating that, in a series of 686 postmortem samples from intracranial hemorrhage cases, there were pulmonary edema and congestion in two-thirds of them and that the hemorrhage, traumatic or spontaneous, did not differ and edema and congestion might have appeared shortly after the hemorrhage (23).

Richards, in an article published in 1961, demonstrated that pulmonary edema was not only associated with cerebral hemorrhage but also appeared in tumors of the central nervous system, bulbar poliomyelitis, suppurative myelitis and after spinal cord injuries (17).

In 1967, Ashbaugh in an article on his observations coined the term ARDS and reported that the use of corticosteroids and PEEP would prove useful in the treatment (2).

Ducker in an article published the same year reported that in his clinical and experimental studies, pulmonary edema developed in traumas and tumors of the central nervous system and also after epileptic seizures and emphasized that the incidence might change from country to country. He tried to explain the physiopathology by autonomous stimuli carried by tracts which began from the hypothalamus and extended to the lateral and ventral funiculi of the medulla spinalis (5,6).

Simmons and Martin in a study carried out during the Vietnam War established that although hemorrhagic shock developing as a result of various injuries was treated properly, pulmonary edema and hyaline membranes were found on postmortem examination of cases lost later. They demonstrated that while in the evaluation of 56 cases with penetrating head injuries pulmonary edema was only present in the cases who died a few minutes after the injury, this clinical picture was not observed in cases with cervical cord transection or associated with massive hemorrhages. However, they established that a atelectasis developed in cases kept alive for a period of time. They explained this critical picture by the shift of excessive amounts of fluid from the peripheral to the pulmonary circulation as a result of excessive sympathetic discharge (9,21).

Moss, in an article in 1972, tried to explain the event by pulmonary vascular spasm caused by

autonomous dysfunction related to hypothalamic hypoxia and emphasized the value of PEEP in the treatment in his experimental studies (11).

Weir, in 1978, reported that he found pulmonary edema in 71 % of cases, citing clinicopathological analyses of 78 SAH cases and suggested that mechanical ventilation, fluid restriction and sympatholytic therapy would be useful (22).

Brisman, in 1974 drew attention in his experimental studies to the similarities between pulmonary edema caused by excessive sympathetic discharge in intracranial pathologies and the clinical picture of acute spinal cord injury (4).

Poe, in a case report published in 1978 suggested that from his clinical observations acute cervical medullary injury might be the cause of noncardiogenic pulmonary edema (15).

Reines, in an article in 1987, studied 123 cases of spinal cord injury and emphasized that in early diagnosis of non-cardiogenic pulmonary edema, pulmonary X-rays and determination of blood gases were important. He suggested that the essential therapy was the administration of oxygen and application of PEEP and for an efficient follow-up, catheterization of the pulmonary artery was necessary (16).

ARDS is not only a pathology involving the lungs but also a systemic disease causing multiple organ insufficiency produced by microembolism as a result of inhibition of the fibrinolytic system (19).

The systems involved affect the mortality considerably. While in cases of ARDS which have no involvement of other organs the mortality is 41 %, in cases accompanied by insufficiency of three organs the mortality rate reaches 84 % (20).

In ARDS, microcirculation becomes disturbed because of irregularities of blood flow and consequently tissue perfusion becomes affected. Body fluid accumulates in the extracellular compartment and plasma volume diminishes (1).

Although there have been differences of opinion on the subject of corticosteroid administration in the therapy, it is commonly agreed that corticosteroids of high dosage administered for a short period contribute to positive results, especially in ARDS appearing after sepsis. The basic requisites of cortico-therapy are lysosome stabilisation, positive inotrope effect and increase in the surfactant amount (12,18).

The common point on which all authors agree is the provision of proper oxygenation, and the suggested method for this is PEEP. When PEEP is applied,

by keeping FiO₂ under 0.6 oxygen toxicity does not occur. If sufficient oxygenation cannot be obtained by this method, extra corporeal oxygenation is suggested (13).

Although proper antibiotic administration, changes of posture, fluid restriction, colloid therapy, inhalation of moist air are the methods of choice of all authors, a limited number suggest alpha blockage (14,10).

Although it is impossible for us to generalize on this subject because of our limited number of cases, our aim is to prove that very different pathologies such as SAH and spinal cord injury may cause ARDS, and that the clinical course may change depending on the causative pathology and the patient's response.

Correspondence : Cengiz Kудay, M.D.
İstanbul Üniversitesi
Cerrahpaşa Tıp Fakültesi
Nöroşirürji Anabilim Dalı
Aksaray-İSTANBUL

REFERENCES

1. Albin MS, Bunegin L, Wolf S: Brain and lungs at risk after cervical spinal cord transection. *Surg Neurol* 24:191-205, 1985
2. Ashabugh DG, Bigelow DB, Levine BE: Acute respiratory distress in adults. *Lancet* August 12:319-323, 1967
3. Balk R, Bone RC: The adult respiratory distress syndrome. *Med Clin North Am* 67 (No 3): 685-700, May 1983
4. Brisman R, Kovach RM, Johnson DO, et al: Pulmonary edema in acute transection of the cervical spinal cord. *Surg Gynecol Obs* 139:363-366, 1974
5. Ducker TB: Increased intracranial pressure and pulmonary edema. *J Neurosurg* 28:118-122, 1968
7. Fein AM, Goldberg K, Lippmann R, et al: Adult respiratory distress syndrome. *Br J Anaesth* 54:723-736, 1982
8. Kaya S, Bahar M.: ARDS bir olgu nedeniyle. *Türk Anest Rean Cemiyeti Mecmuası* 15:89-94, 1987
9. Martin AM, Simmons RL, Heisterkamp CA: Respiratory insufficiency in combat casualties I. *Ann Surg* 170:30-38, 1969
10. Merlin M: Neuroanaesthesia. pp 68-69, 1978
11. Moss G, Staunton C, Stein A: Cerebral etiology of the "Shock Lung Syndrome". *J Trauma* 12(10):885-890, 1972
12. Nicholson DP: Corticosteroids in the treatment of septic shock and adult respiratory distress syndrome. *Med Clin North Am* 67:717-724, 1983
13. Nordwood SH, Civette M: Ventilatory support in patients with ARDS. *Surg Clin North Am* 65(4):895-916, 1978
14. Petty L, Ashabaugh DG: The adult respiratory distress syndrome. Ed: Intensive and Rehabilitative respiratory care. Philadelphia 1974, pp 205-222
15. Poe R, Reisman JL, Todenhouse TG: Pulmonary edema in cervical spinal cord injury. *J Trauma* 18(1):71-77, 1978
16. Reines HD, Harris RC: Pulmonary complications of acute spinal cord injuries. *Neurosurgery* 121(2):193-196, 1987
17. Richards P: Pulmonary edema and intracranial lesions. *Brit Med J* 13 July:83-86, 1963
18. Rosen AJ: Shock lung: Fact or fancy. *Surg Clin North Am* 55(3):613-626, 1975
19. Saldeen T: Clotting, microembolism and inhibition of fibrinolysis in adult respiratory distress syndrome. *Surg Clin North Am* 65(4):931-963, 1985
20. Shoemaker WC: Controversies in the pathophysiology and fluid management of postoperative adult respiratory distress syndrome. *Surg Clin North Am* 65(4):931-963, 1985
21. Simmons LR, Martin AM, Heisterkamp CA, et al: Respiratory insufficiency in combat casualties II. *Ann Surg* 170(1):39-44, 1969
22. Weir BK: Pulmonary edema following fatal aneurysm rupture. *J Neurosurg* 49:502-507, 1978
23. Weismann SJ: Edema congestion of the lungs resulting from intracranial hemorrhage. *Surgery*: 722-729, 1989