



Ganglioglioma Mimicking the Cerebral Abscess in Advanced Age: A Case Report

İleri Yaşta Görülen Serebral Abseyi Taklit Eden Gangliogliom: Bir Olgu Sunumu

Cem ATABEY¹, Ahmet EROGLU¹, Cem DINC², Ahmet COLAK¹

¹GATA Haydarpaşa Training Hospital, Clinic of Neurosurgery, Istanbul, Turkey

²Atasehir Memorial Hospital, Clinic of Neurosurgery, Istanbul, Turkey

Corresponding Author: Ahmet EROGLU / E-mail: drahemeroglu@gmail.com

ABSTRACT

Ganglioglioma is one of the rare mixed neuronal glial tumors of the central nerve system. It is responsible for 0.4 – 2% of the intracranial tumors observed in infants and young matures. Its most common localization is the supratentorial region. Typically, the first symptom is epilepsy. Due to the glial structure, that rare tumor can exhibit a malign transformation. Growing slowly through several months or years, it forms neurological dysfunction. The standard treatment of that supratentorial tumor is usually total resection. If an anaplastic quality is observed, the patient undergoes radiotherapy after the surgical intervention. In this article, we presented a 53-year-old patient who presented with headache and dysphasia. The patient was operated for the cystic mass in the left parietal lobe reported as an abscess. The pathology was reported as ganglioglioma and we discussed the case according to the literature.

KEYWORDS: Ganglioglioma, Abscess, Glial tumor

ÖZ

Gangliogliom santral sinir sisteminin nadir görülen mikst nöronal glial tümörlerindendir. Çocuklarda ve genç erişkinlerde görülen intrakranial tümörlerin %0,4 ile %2' sinden sorumludur. En sık yerleşim yeri supratentoriyal bölgededir. Tipik olarak ilk belirti nöbetir. Nadir görülen bu tümörler glial yapısı nedeniyle malign transformasyon gösterebilir. Birkaç ay ile birkaç yıl içerisinde yavaş yavaş büyüyerek nörolojik disfonksiyon oluşturur. Tercih edilmesi gereken tedavi yöntemi, tümörün cerrahi olarak gross total rezeksiyonu olup tümör anaplastik özellik de gösteriyorsa cerrahi tedavi sonrası radyoterapi uygulanmasıdır. Bu makalede 53 yaşında baş ağrısı ve disfazi şikayetleriyle doktora başvuran, sol parietalde kistik kitle tanısı konularak ameliyat edilen ve patolojisi gangliogliom olarak raporlanan vaka bildirilerek literatür eşliğinde tartışılmıştır.

ANAHTAR SÖZCÜKLER: Gangliogliom, Apse, Glial tümör

INTRODUCTION

Ganglioglioma (GG) is a tumor of the nerve system, which forms from its rarely seen neuronal and glial cells (6). It is responsible for 0.4–2% of the intracranial tumors observed in infants and young adults (10). Most childhood tumors are infratentorial, but GG is mostly located in supratentorial region in infancy and early maturation (5). It is mostly observed in temporal and frontal lobes and frequently presents with clinical symptoms, which cause refractory epilepsy (7, 17). The malign presentation percentages of these tumors, which generally follow a slow growth pattern, are low (6, 11, 12). Radiologically, they are usually seen as cystic and/or calcified lesions. If they have a solid structure on cranial computed tomography (CT) and magnetic resonance imaging (MRI) examinations, they have contrast involvement and include scarce calcification (6). Thus, they are mistaken for malign tumors. The generally accepted therapy is the total resection of the tumor (3). If tumor pathology also exhibits an anaplastic quality, radiotherapy must be administered

after surgical intervention (6). In this case presentation, an advanced-age cerebral ganglioglioma patient has been presented, and quality of this rare tumor has been discussed along with literature.

CASE PRESENTATION

A 53-year-old female patient applied to the neurology outpatient clinic of a state hospital with the complaints of headache, vomiting, and difficulty speaking for one week. On cranial magnetic resonance imaging (MRI), cystic mass lesion was reported in the left parietal lobe; thus, the patient was referred to our department. The lesion was 5x6 cm in size and had cystic anteroparietal contrasting on the cranial MRI in the left parietal region. It was reported as abscess (Figure 1A-C). There was no history of epilepsy. Physical examination was normal. In her neurological examination, the patient was conscious, cooperated, but dysphasic. Light reflex (LR) was bilateral (+/+). There were no additional findings and no pathological reflexes. Due to the neighborhood of the lesion to the motor cortex, the surgical approach was determined

as transcortical path in the coronal column anterior, and the cyst content was removed. The cyst was not purulent or xanthochromic; thus, it was not considered an abscess. The walls of the cyst were examined thoroughly, which revealed nodular component at the anterior inferior wall. The lesion was removed totally. Postoperative course was uneventful, and the dysphasia was corrected. On the postoperative first-year follow-up MRI, the patient had no findings other than the post-operational changes and porencephalic cyst (Figure 2A,B).

DISCUSSION

The incidence rate of gangliogliomas, one of the rare tumors of the central nervous system (CNS), is 1% (3). In Hakim's and others' series, this rate was 0.3% in 5384 intracranial tumor patients (6). The case reported here is the first ganglioglioma case we encountered among a total of 1154 intracranial tumor patients between 2001 and 2011.

These tumors generally grow slowly and have good prognosis, and approximately 5% are accompanied with congenital diseases such as Down syndrome, corpus callosum agenesis, polymicrogia, and Turcot syndrome (4). In terms of localization, the tumor is frequently located in the temporal lobe, while other locations such as the frontal lobe and 3rd ventricle are also common. The parietal lobe, occipital lobe, 4th ventricle, cerebellum, thalamus, hypothalamus, pineal zone, brain stem and spinal cord are the other locations reported in the literature (1, 6). In the present case, the tumor was in the parietal lobe.

Although the tumor location in the present case complies with the earlier reports of rarely encountered ganglioglioma locations, it is unique with respect to the age of the patient.. These mixed type CNS tumors, including neuroplastic neuronal and glial cells, are seen more frequently in the pediatric age and early adulthood (under age 30) (6,9). However, our patient who was diagnosed with ganglioglioma was 53 years old, which is significant in terms of the literature.

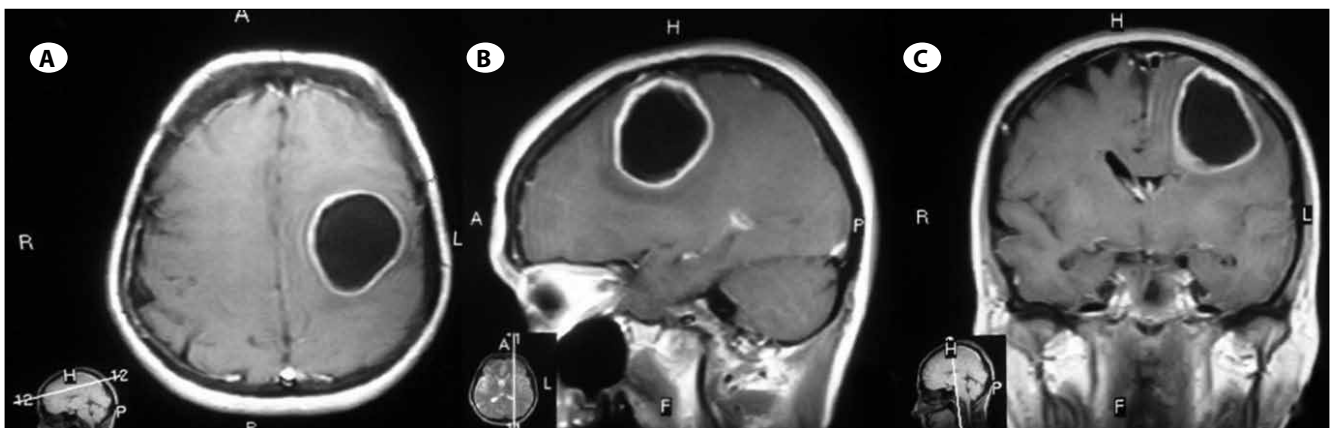


Figure 1: Preoperative T1-weighted contrast enhanced magnetic resonance images confirm intracerebral abscess in **A)** axial, **B)** sagittal **C)** coronal planes.

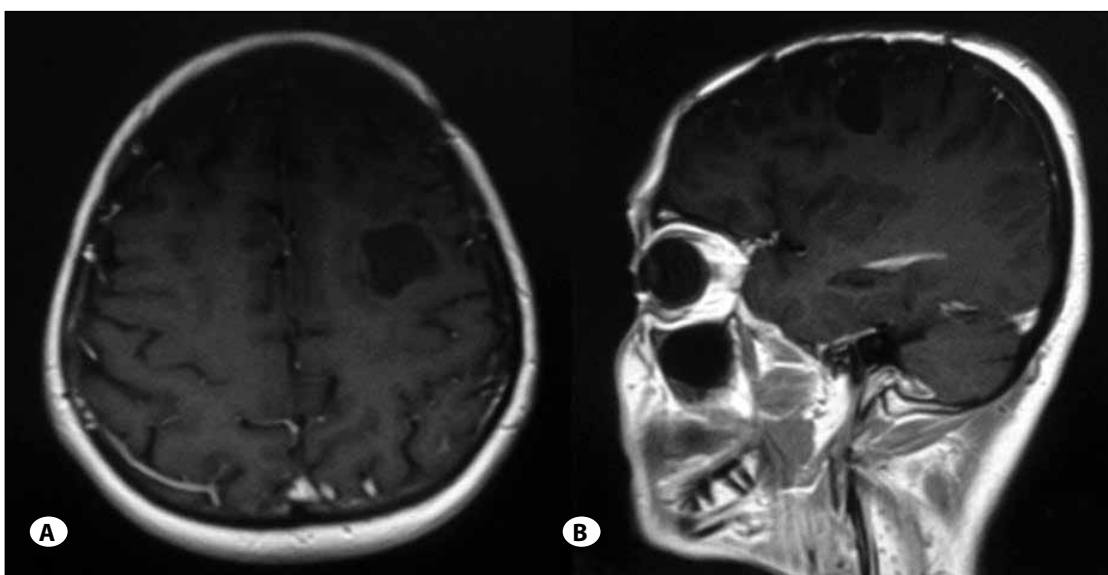


Figure 2: Postoperative T1-weighted contrast enhanced magnetic resonance images confirm porencephalic cyst in **A)** axial, **B)** sagittal planes.

Gangliomas frequently cause chronic epileptic attacks resistant to antiepileptic treatment and exhibit clinical symptoms (7, 20). In the presented case, the tumor did not cause epilepsy, which is the most common symptom and was present "silently" while manifesting through recent headaches and dysphasia.

Radiologically, gangliogliomas are usually seen as cystic and/or calcified lesions. If GGs are in a solid structure on Cranial CT and MRI examinations, they show contrast enhancement and rarely contain calcifications (6). On cranial CT, they have well-defined margins and focal calcifications, present in the form of contrast matter-involving lesions, which are formed of cystic and solid components: tumor tissue is generally isodense or hyperdense. In T1-weighted MRI examination, the tumor is seen as hypo- or isodense, and in T2-weighted MRI, it is seen as hyperintense and exhibits strong contrast matter enhancement (6,21). Differential diagnosis based on radiological evaluation includes astrocytoma, oligodendroglioma, arachnoid cysts, and porencephalic cysts (2). In our case, there were no solid components on the MRI, and the radiological diagnosis was abscess.

The histopathologic diagnosis of ganglioglioma is made by showing neuronal cells that are diffused among the glial component (6, 16). The ratios of these components within the tumor differ from each other, and both groups may exhibit cytological features of the neoplasia (6). Neuronal component consists of well differentiated but abnormal ganglion cells. Glial component frequently consists of astrocytic cells (6, 14). For histopathologic evaluation, Miller and others have explained four qualities. These qualities are a) large mass batches that potentially resemble neurons, b) glial cells not exhibiting flocculation around neoplastic neuron cells, c) fibrosis and d) calcification existence (14). Together with these findings, it is necessary to investigate the immunohistochemical neuronal and glial markers such as Synaptophysin, S-100, vimentine, chromogranin A, neuropeptide Y, NSE and GFAP (14,19) for a complete histopathological diagnosis. In the histopathologic evaluation of ganglioglioma, finding abnormal shaped and two-nucleus neurons is diagnostic (2).

In GG treatment, the basic approach is total removal of the tumor (6). It is stated that in post-operative period, the effect of radiotherapy and chemotherapy is not definitive. In tumors that residue or recur after operation, in tumors that have anaplastic and oligodendroglial cell component, in cases with the tumor in the brain stem, RT and CT must be administered after surgical treatment (6). Adjuvant radiotherapy is especially indicated in patients exhibiting anaplasia or recurrence (13, 19), while some authors have stated that this is of no use (15, 18). The literature shows that histological grade or resection grade do not affect the relapse and that tumor localization or grade do not have any effects on post-operative adjuvant therapy administration (15). As in the present case, the mass is completely removed. We followed the patient in the light of the recommendations in literature. The patient was not administered radiotherapy.

CONCLUSION

The tumor of our patient was in the form of a purulent abscess; in cases with suspected ganglioglioma, the cystic walls must be examined carefully, and mural nodule should be explored. It should also be kept in mind that gangliogliomas may be rarely seen in advanced ages, with different neurological findings such as dysphasia, and anatomical localizations.

REFERENCES

1. Araki M, Fan J, Haraoka S: Extracranial metastasis of anaplastic ganglioglioma through a ventriculoperitoneal shunt: A case report. *Pathol Int* 49:258-263, 1999
2. Burger PC, Scheithauer BW: Atlas of tumor pathology. Tumors of the Central Nervous System. Washington, D.C: Armed Forces Institute of Pathology 1994: 163-172
3. Dash RC, Provenzale JM, McComb RD, Perry DA, Longee DC, McLendon RE: Malignant Supratentorial ganglioglioma (ganglion cell- giant cell glioblastoma). A case report and review of the literature. *Arch Path Lab Med* 123:342-345, 1999
4. Elmaci I, Bayrakli F, Kurtkaya O, Peker S, Sav A, Pamir N: Erişkin hastada serebellar gangliogliom. *Türk Patoloji Dergisi* 17: 81-84, 2001
5. Haddad SF, Moore SA, Menezes AH, VanGilder JC: Ganglioglioma: 13 years of experience. *Neurosurgery* 31: 171- 178, 1992
6. Hakim R, Loeffler JS, Anthony DC, Black PM: Gangliogliomas in Adults. *Cancer* 79:127-131, 1997
7. Hirose T, Scheithauer BW, Lopes MB, Gerber HA, Altermatt HJ, Vandenberg SR: Ganglioglioma: An ultrastructural and immunohistochemical study. *Cancer* 70: 989- 1003, 1997
8. Im SH, Chung CK, Cho BK, Wang KC, Yu IK, Song IC, Cheon GC, Lee DS, Kim NR, Chi JG: Intracranial ganglioglioma: Preoperative characteristics and oncologic outcome after surgery. *J Neurooncol* 59: 173-183, 2002
9. Jay V, Squire J, Blaser S, Hoffman HJ, Hwang P: Intracranial and spinal with unusual cytogenetic abnormalities in a patient with complex partial seizures. *Childs Nerv Syst* 13(10):550-555, 1997
10. Koch von CS, Schmidt MH: Neuronal tumors. In: Gupta N, Banerje A, Haas-Kogan D (eds), *Pediatric CNS Tumors*. Berlin: Springer, 2004:143-156
11. Lagares A, Gomez PA, Lobato RD, Ricoy JR, Ramos A, Lama A: Ganglioglioma of the brainstem: Report of three cases and review of the literature. *Surg Neurol* 56: 315-322, 2001
12. Lang FF, Epstein FJ, Ransohoff J, Allen JC, Wisoff J, Abbott R: Central nervous system gangliogliomas. Part 2. Clinical Outcome. *J Neurosurg* 79:867-873, 1993
13. Liauw SL, Byer JE, Yachnis AT, Amdur RJ, Mendenhall WM: Radiotherapy after subtotally resected or recurrent ganglioglioma. *Int J Radiation Oncology Biol Phys* 67: 244-247, 2007
14. Miller DC, Lang FF, Epstein FJ: Central nervous system gangliogliomas. Part 1: Pathology. *J Neurosurg* 79(6):859-866, 1993

15. Milligan BD, Giannini C, Link MJ: Ganglioglioma in the cerebellopontine angle in a child. Case report and review of the literature. *J Neurosurg* 107: 292-296, 2007
16. Peretti-Viton P, Perez-Castillo AM, Raybaud CH, Grisoli F, Bernard F, Poncet M, Salamon G: Magnetic resonance imaging in gangliogliomas and gangliocytomas of the nervous system. *J Neuroradiol* 18:189-199, 1991
17. Rousseau A, Kujas M, Bergemer-Fouquet AM, van Effenterre R, Hauw JJ: Surviving expression in ganglioglioma. *J Neurooncol* 15:1-17, 2005
18. Selch M, Goy B, Lee S, El-Sadin S, Kincaid P, Park SH: Gangliogliomas: Experience with 34 patients and review of the literature. *Am J Clin Oncol* 21: 557-564, 1998
19. Suzuki H, Otsuki T, Iwasaki Y, Katakura R, Asano H, Tadokoro M: Anaplastic ganglioglioma with sarcomatous component: An immunohistochemical study and molecular analysis of p53 tumor suppressor gene. *Neuropathology* 22(1):40-47, 2002
20. Wolf HK, Wiestler OD: Neuropathologic findings in chronic epilepsy. *Laryngorhinootologie* 74:127-129, 1995
21. Zentner J, Wolf HK, Ostertun B, Jufnagel A, Campos MG, Solymosi L: Gangliogliomas: Clinical, radiological and histopathological findings in 51 patients. *J Neurol Neurosurg Psychiatry* 57:1497-1502, 1994