

# Venous MR Angiography and MR Imaging in the Diagnosis and Follow-up of Dural Sinus Thrombosis

## Dural Sinüs Trombozunun Tanı ve İzleminde Venöz MR Anjiografi ve MR Görüntüleme

ÜLKÜ SİBEL BENLİ, UFAK CAN, HAKAN CANER, NUR ALTINÖRS,  
MUHTEŞEM AĞILDERE

Başkent University Hospital, Department of Neurology (ÜSB, UC),  
Department of Neurosurgery (HC, NA) and Department of Radiology (MA), Ankara

**Abstract:** The purpose of this study was to determine the value of venous magnetic resonance angiography (Venous MRA) as the sole procedure for diagnosing and following up dural sinus thrombosis (DST). We also reviewed the etiology, clinical features, and therapeutic aspects of this neurological emergency. Ten patients, five males and five females, with clinical findings suggestive of DST were examined using magnetic resonance imaging (MRI) and venous MRA. The main symptom in adults (n=8, age: 17-55) was headache. Visual loss, convulsions, and motor signs were present in two infants. Three patients had chronic renal failure and were on a hemodialysis program. One patient was diagnosed with Behçet's disease, and another was in the postpartum period. Both infants had congenital heart disease. Infection accompanied DST in four patients. MRI revealed edema and white matter signal abnormalities in four patients. Venous MRA showed superior sagittal sinus thrombosis in 6 patients, and lateral sinus thrombosis in 10 patients. All the patients were anticoagulated, and those with infection were given antibiotic treatment. In six patients, follow-up venous MRA and/or MRI revealed recanalization. No mortality or morbidity was documented in the adults. Venous MRA and MRI are noninvasive, sensitive, and reliable techniques for early diagnosis and follow-up of DST.

**Key Words:** Dural sinus thrombosis, magnetic resonance, venous magnetic resonance angiography

**Özet:** Bu çalışmanın amacı dural sinüs trombozunun (DST) tanı ve izleminde venöz manyetik rezonans anjiografisinin (Venöz MRA) temel bir yöntem olup olamayacağını belirlemektir. Bununla birlikte bu nörolojik acil durumun etiyolojisi, klinik özellikleri ve tedavi seçenekleri de gözden geçirilmiştir. Klinik bulguları DST; deotekleyen 10 hasta (5K, 5E) manyetik rezonans görüntüleme (MRG) ve venöz MRA yöntemleri ile incelendi. Erişkin hastalarda (n=8, yaş: 17-55) ana yakınma baş ağrısı idi. İki infantda görme kaybı, nöbet ve motor semptomlar saptandı. Üç hasta kronik böbrek yetmezliği nedeniyle hemodiyaliz tedavisi almaktaydı. Bir hasta Behçet Hastalığı tanısı almıştı, bir diğer hasta ise postpartum dönemde idi. Her iki infantda konjenital kalp hastalığı vardı. DST ile birlikte 4 hastada enfeksiyon görüldü. Dört olgunun MRG'sinde ödem ve beyaz cevher sinyal değişiklikleri saptandı. Venöz MRA'da 6 hastada superior sagittal sinüs trombozu görülürken 10 hastanın hepsinde lateral sinüs trombozu vardı. Olguların tümü antikoagüle edildi, enfeksiyonu olan hastalara antibiyotik tedavisi verildi. Altı hastanın izleminde venöz MRA ve/veya MRG'de rekanalizasyon saptandı. Erişkinlerde mortalite veya morbidite görülmeydi. Venöz MRA ve MRG DST'li olgularda hem erken tanı hem de izleminde kullanılabilecek noninvazif ve sensitif uygun bir tekniktir.

**Anahtar Kelimeler:** Dural sinüs trombozu, manyetik rezonans, venöz manyetik rezonans anjiografi

## INTRODUCTION

Dural sinus thrombosis (DST) is clinically characterized by headache, nausea, vomiting, papilledema, visual acuity disturbances, diplopia, seizures, focal neurological deficits, confusion, and even progressive coma and death. Ribes first described the clinical and autopsy findings in 1825, and numerous cases have been reported since. The onset of the disease is usually acute, but may be subacute, or may even take a chronic course. Mastoiditis, sinusitis, otitis media and other infections of the face, dehydration, and use of oral contraceptive drugs can precipitate DST. Certain hematological disorders, such as polycythemia, sickle-cell anemia, leukemia, and hereditary deficiencies of protein C, protein S, and antithrombin III may also be predisposing factors. DST has also been reported in association with collagen vascular disease, antiphospholipid antibody syndrome, Behçet's disease, pregnancy, and the postpartum period. In some cases, it is idiopathic (1). Early diagnosis is important because the mortality and morbidity rates for DST remain high (6).

Various neuroradiological methods, including computed tomography (CT) and angiography, can be helpful for evaluating patients with clinical pictures that are suspicious of DST (2). In recent years, magnetic resonance imaging (MRI) and venous magnetic resonance angiography (venous MRA) have been documented as sensitive noninvasive methods for diagnosing and following up DST cases (4,8). The aims of this study were to determine the value of venous MRA as the sole procedure for the diagnosis and follow-up of DST, and to review the etiological, clinical, and therapeutic aspects of this neurological emergency.

## PATIENTS and METHODS

We studied 10 patients, 5 males and 5 females, whose clinical findings were suggestive of DST. Eight of the individuals were adults (mean age  $34 \pm 13.5$  years, range 17-55). Two of the patients were infants with cyanotic congenital heart disease. One infant was in the postoperative period and the other was in the preoperative period.

Routine laboratory investigations were performed, including complete blood count, biochemistry, erythrocyte sedimentation rate, and coagulation studies. Each patient underwent magnetic resonance examination with a 1-T Siemens

Magnetom scanner. Spin-echo sequences were performed at 600 / 15 for T1-weighted sequences, and at 3000 / 22 - 60 - 120 (for children) and 3000 / 15 - 105 (for adults) for T2-weighted sequences. Axial and sagittal sections were imaged in all cases, and coronal sections in most. In some patients, T1-weighted sequences were repeated after contrast material was administered.

Venous MRA was performed using a two-dimensional time-of-flight technique (2nd FLASH sequences). The parameters for venous MRA were 40 / 9.8 (TR / TE), 35° flip angle, and the section thickness was 134.8 mm. The clinical features of the patients are summarized in Table I. The MRI and venous MRA findings of some of the patients are shown in Figures 1 - 5.

Once the diagnosis of DST was established, treatment consisted of anticoagulation. When necessary, diuretics and/or glucocorticoids for brain edema and antibiotic therapy were also administered. All the adult patients had symptoms of headache, nausea, and vomiting. Onset was acute in seven patients, subacute in two patients, and developed as a chronic headache in one individual. Four patients reported visual loss. All patients had papilledema. Focal neurological signs were present in four patients. Six individuals had changes in their level of consciousness. Seizures occurred in four patients, two of whom were infants. Four of the

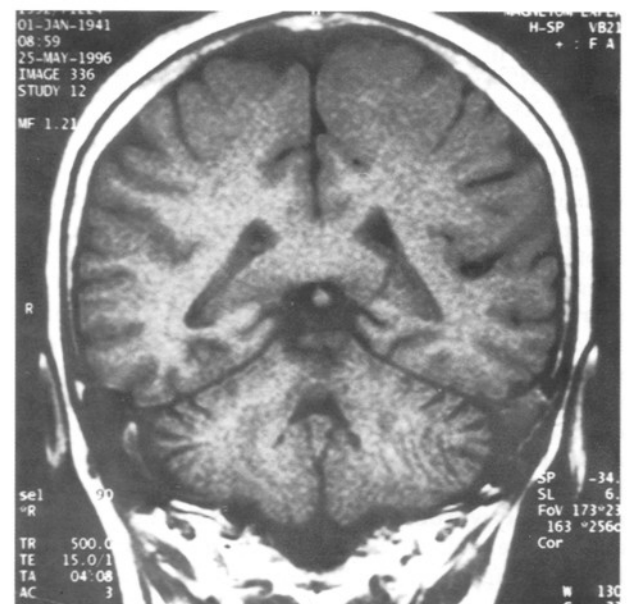


Figure1: Patient No 5. Behçet's Disease. Loss of physiologic signal void in left sigmoid sinus secondary to thrombus.

Table I: Clinical features and MR findings of the patients

No	Age-Sex	Associated Disease	Neurologic Signs and Symptoms	Inf.	Venous MRA Findings
1	45 - F	CRF - HD	Subacute headache, PE	+	Thrombi in superior sagittal, left transverse and sigmoid sinuses
2	26 - F	CRF - HD - Meningitis	Acute onset headache, confusion; nuchal rigidity and Kernig and Brudzinski signs (+), PE	+	Thrombi in the left transverse and sigmoid sinuses
3	34 - M	Migraine	Acute onset headache, nausea and vomiting; PE	-	Thrombi in the superior sagittal and left transverse sinuses
4	22 - F	Eclampsia, in postpartum period	Subacute onset headache, nausea and vomiting, visual disturbance,	-	Thrombi in the superior sagittal and left transverse sinuses; bilateral occipital
5	55 - F	Recurrent oral aphthous ulcers, uveitis: B.D.	seizure, stupor; PE Chronic headache; PE	-	venous infarction, WMSA and edema Thrombus in the left sigmoid sinus
6	40 - M	CRF - HD	Acute onset headache, confusion, visual and hearing loss; focal neurologic deficit, PE	-	Thrombi in the left transverse and sigmoid sinuses; central pontine myelinolysis
7	50 - F	Meningitis secondary	Acute onset headache, nausea and vomiting; PE, Kernig and Brudzinski signs (+)	+	Thrombi in the left transverse sinus
8	17 - M	Renal Tx - Compensated CRF - sinusitis	Acute onset headache, nausea and vomiting, confusion; PE	+	Thrombi in the superior sagittal and left transverse sinuses
9	2 - M	Cyanotic CHD, in postoperative period	Seizure, stupor, visual loss, focal neurologic deficit; PE	-	Thrombi in the superior sagittal and left transverse sinuses; WMSA - edema in both occipital lobes.
10	3/12-M	Cyanotic CHD, in preoperative period	Seizure, focal neurologic deficit, visual loss (?),	-	Thrombi in the superior sagittal and left transverse sinuses and also in the internal jugular vein and superficial cerebral veins; venous infarction in the left parietal region, edema and also infarction in the territory of the right MCA.

Abbreviations: (CRF : Chronic Renal Failure, HD : Hemodialysis, PE: Papilledema, WMSA: White Matter Signal Abnormality, Tx : Transplantation, CHD : Congenital Heart Disease, MCA: Middle Cerebral Artery, MRA : MR Angiography, (+) : Present, (-) : Absent, B.D. : Behçet's Disease, Inf.: Infection

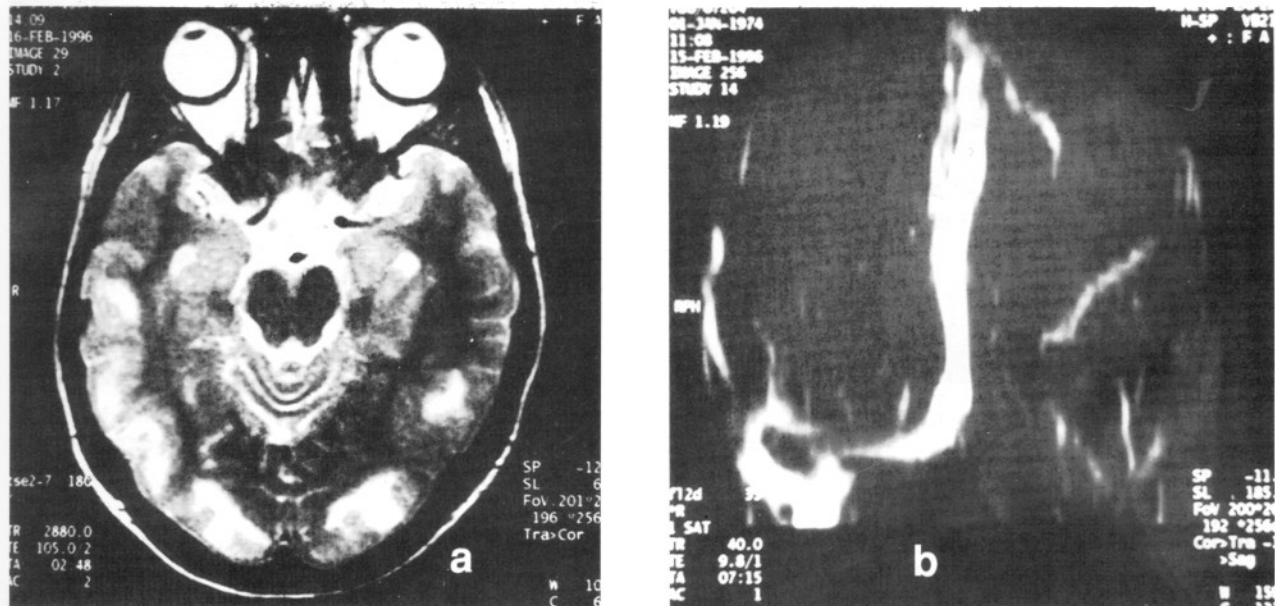


Figure 2: Patient No - 4. Eclampsia, postpartum period. a) Bilateral hyperintense white matter signal abnormalities (WMSA) and edema in occipital lobes, b) Complete loss of flow in the left transverse sinus as a result of thrombus formation.

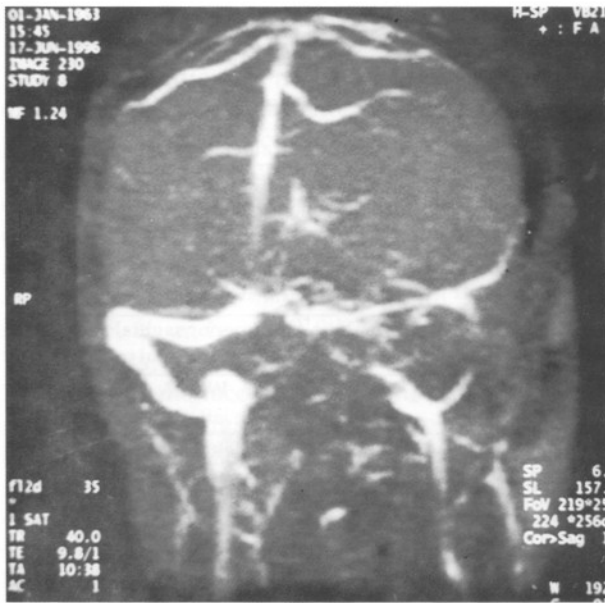


Figure 3: Patient No 3. Migraine. Venous MRA shows thrombi in the superior sagittal sinus and the left sigmoid sinus. Incomplete or low-volume flow in the superior sagittal sinus, and complete loss of flow in the left sigmoid sinus have resulted due to thrombosis.

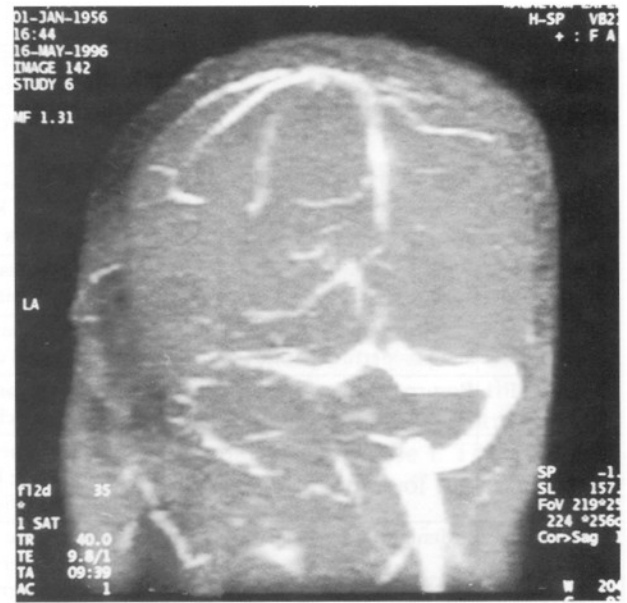

Figure 4: Patient No 1. Chronic renal failure and on hemodialysis program. Low signal intensity in the superior sagittal and the left transverse sinus (viewed from the posterior).

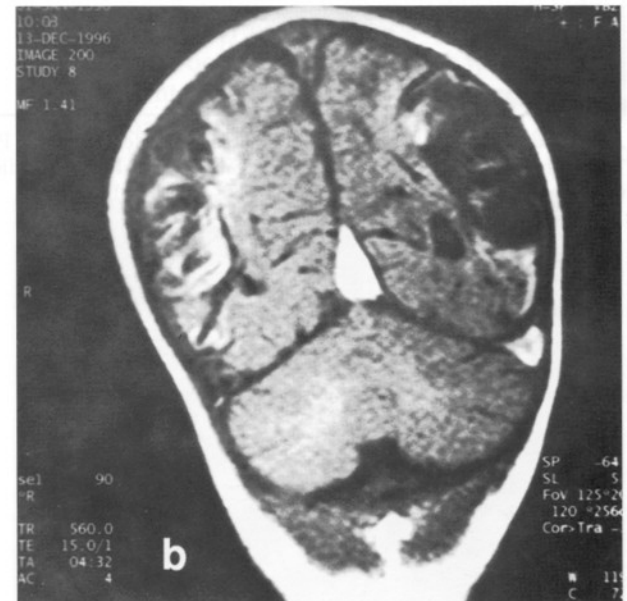
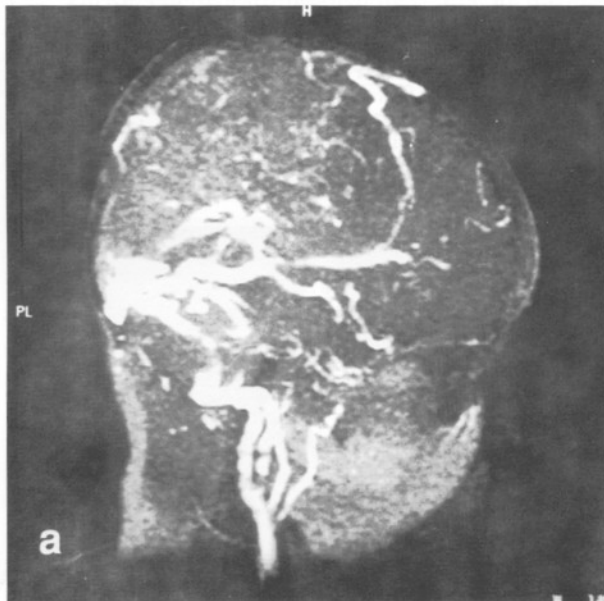


Figure 5: Patient No 10. Cyanotic congenital heart disease. a) Venous MRA shows thrombi in the SSS, the left transverse sinus, and the left internal jugular vein, b) Infarction in the left parietal convexity and infarction in the region of the right MCA.

patients had chronic renal failure, and three of these individuals were on a three-times-weekly hemodialysis program. Two of the patients had undergone renal transplantation. One was still on immunosuppressive treatment, and the other had

gone back on hemodialysis due to graft rejection.

Infection occurred in four patients. Two of these patients were diagnosed with bacterial meningitis secondary to otitis media and pansinusitis,



respectively. In one patient who had a history of recurrent oral aphthous ulcers and simultaneously occurring uveitis, the diagnosis was Behçet's disease. One patient had a history of eclampsia in the postpartum period. Both of the infants had cyanotic congenital heart disease, and protein C deficiency was detected in one of them. Cerebrospinal fluid (CSF) was examined in eight patients. The CSF pressure was high in all cases (210 to > 300 mm H<sub>2</sub>O) at the time of diagnosis.

## RESULTS

Thrombosis of the superior sagittal sinus (SSS) was detected in six patients, and lateral sinus thrombosis (transverse and/or sigmoid sinuses) was found in all 10 patients. The six patients with SSS thrombosis also had thrombosis of one lateral sinus. In four patients, cerebral edema and white matter signal abnormalities were also detected. We also observed arterial infarction in one of the infants, and found venous infarction in two patients. Follow-up venous MRA was done in six cases, and changes in signal intensity as a consequence of recanalization were found in all six. There was no mortality, and the associated morbidity was of a considerably low grade, occurring only in the infants. The elevated intracranial pressure was reduced with medical treatment in all but one adult patient. This individual was treated with lumboperitoneal shunting, and had only mild, bilateral, peripheral narrowing of the visual fields.

## DISCUSSION

Computed tomography has been helpful in diagnosing DST since 1980, but its sensitivity is low (2). In CT without contrast, thrombosed veins or sinuses may be extremely hyperdense because the thrombus shows more absorption than circulating blood. Hemorrhagic venous infarction can also be identified on CT without contrast. The "empty" delta sign following contrast enhancement is another abnormality identified on CT, and is thought to arise from congestion of dural vascular collateral channels surrounding the thrombus in the sinus. Thin sections and coronal reformatting are necessary for diagnosis. Arachnoid cysts, epidural abscesses and the cisterna magna have all been reported to mimic this finding (4,9).

Though angiography is a sensitive method for detecting thrombi, it is invasive and there is always risk of complication. This fact has caused clinicians to gravitate toward venous MRA, a noninvasive but

sensitive imaging technique. The advantages of venous MRA over conventional angiography, and its superiority to CT in detecting DST, has, to date, made venous MRA the method of choice for definitive diagnosis of this condition (4,8).

Any thrombus in the dural sinus is represented as increased signal intensity on both T1- and T2-weighted sequences. Edema and hemorrhagic venous infarction can be easily detected on MRI, but it can still be difficult to diagnose DST with this method. In acute thrombosis, DST can be confused with patent dural sinuses. Changes in flow velocity, and inflammatory debris within the thrombus, can also make MRI diagnosis a tougher challenge. Venous MRA is said to overcome all these disadvantages, and in recent years, several authors have found it a reliable method of investigating DST (4,5,7,8).

In our study, MRI and venous MRA confirmed the presence of DST in every patient we suspected might have the condition. Early diagnosis using these two methods led to appropriate and timely treatment with anticoagulation, diuretics and/or glucocorticoids, and antibiotics. Early diagnosis and appropriate treatment of DST are reported to reduce mortality and morbidity associated with this condition (3). Although the mortality rate in patients with cerebral venous thrombosis was once 25% to 30%, there were no deaths in our series (3). Follow-up venous MRA in our patients also enabled us to visualize and confirm the occurrence of recanalization.

In conclusion, venous MRA in association with routine spin-echo MRI is a safe and reliable technique for diagnosing and following up DST. Early definitive diagnosis, with a thorough etiologic investigation that includes hematologic studies, decreases patient morbidity and mortality.

\*This paper was presented at the 16th World Congress of Neurology on September 14-19, 1997 in Buenos Aires, Argentina.

**Correspondence:** Ü. Sibel Benli,  
Başkent University Hospital,  
12. Sokak, No: 17  
06490 Bahçelievler,  
Ankara, Turkey  
Tel : 312 - 212 04 34 / 104-115  
Fax : 312 - 233 73 33

## REFERENCES

1. Bousser MG, Chiras J, Bories J, Castaigne P: Cerebral venous thrombosis. A review of 38 cases. *Stroke* 16 (2): 199 - 213, 1985
2. Golderg AL, Rosenbaum AE, Wang H, Kim WS, Lewis VL, Hanley DF: Computed tomography of dural sinus thrombosis. *J Comput Assist Tomogr* 10: 16 - 20, 1986
3. Karabudak R, Caner H, Öztekin N, Özcan OE, Zileli T: Thrombosis of intracranial venous sinuses: Aetiology, clinical findings and prognosis of 56 patients. *J Neurosurg Sci* 34 (2): 117 - 121, 1990
4. Padayachee TS, Bingham JB, Graves MJ, Colchester ACF, Cox TCS: Dural sinus thrombosis; Diagnosis and follow-up by magnetic resonance angiography and imaging. *Neuroradiology* 33: 165 - 167, 1991
5. Rippe DJ, Boyko JB, Spritzer CE: Demonstration of dural sinus occlusion by the use of MR angiography. *AJNR* 199 - 201, 1990
6. Schell CL, Rathe RJ: Superior sagittal sinus thrombosis: still a killer. *West J Med* 149: 304 - 307, 1988
7. Vogl TJ, Balzer JO, Stemmler J, Bergman C, Egger E, Lissner J: MR angiography in children with cerebral neurovascular diseases: findings in 31 cases. *AJR* 159: 817 - 823, 1992
8. Vogl TJ, Bergman C, Villringer A, Einhüpl K, Lissner J, Felix R: Dural sinus thrombosis: value of venous MR angiography for diagnosis and follow-up. *AJR* 162: 1191 - 1198, 1994
9. Zilkha A, Diaz AS: Computed tomography in the diagnosis of superior sagittal sinus thrombosis. *J Comput Assist Tomogr* 4: 124 - 126, 1980