

Totally Cystic Intradural Extramedullary Schwannoma

Tamamen Kistik Oluşum Gösteren Intradural Ekstrameduller Şwannoma Olgusu

ABSTRACT

Totally cystic intradural extramedullary lesions are uncommon and form a different spectrum of conditions as compared to the commonly seen intradural extramedullary tumors. Spinal schwannomas are benign tumors arising from spinal nerve root sheaths and are the most common intradural extramedullary spinal tumors. Though cystic changes in schwannomas are well described, most spinal schwannomas are solid or heterogeneous solid tumors and a totally cystic schwannoma is uncommon. The authors describes a case of totally cystic intradural extramedullary schwannoma and stress the importance of complete contrast imaging to differentiate this rare but almost completely curable tumor from other common intradural cystic lesions of the spine.

KEY WORDS: Cystic formation, Extramedullary, Intradural, Schwannoma, Tumor

ÖZ

Tamamen kistik, intradural ve ekstrameduller yerleşimli lezyonlar nadir görülür ve bu tip lezyonlar daha sık görülen ve intradural ve ekstrameduller yerleşim gösteren tümörlerden farklı bir tipi oluşturmaktadır. Spinal şivannomalar iyi huylu tümörlerdir ve spinal sinir kılıflarından kaynaklanırlar. Spinal şivannomalar en sık görülen intradural ekstrameduller tümörlerdir. Şivannomalar solid ya da heterojen yapılı olabilir; ancak tamamen kistik görünümü olan şivannomalar sık değildir. Yazarlar, tamamen kistik olan intradural ekstrameduller şivannoma vakasını tanımlamaktadırlar. Bu vakada kontrast madde ile tamamen boyanan kistik lezyonların tamamen kistik olabilen ve tedavi edilebilen şivannoma tanısında ayırıcı tanı sırasında düşünülmesi gerektiği vurgulanmaktadır.

ANAHTAR SÖZCÜKLER: Kistik oluşum, ekstrameduller, İnadural, Şivannoma, Tümör

Manish Kumar KASLIWAL¹
Shashank S. KALE²
Bhawani Shanker SHARMA³
Vaishali SURI⁴

^{1,2,3} Department of Neurosurgery and Pathology⁴, Neurosciences Centre All India Institute of Medical Sciences, New Delhi – 110029, India

Received : 20.04.2008

Accepted : 04.06.2008

Correspondence address:

Shashank S KALE

Department of Neurosurgery,
Neurosciences Centre,
All India Institute of Medical Sciences,
New Delhi (INDIA) 110029.

Phone: 919868398234

Fax : 91 11 26589650

Email : skale67@gmail.com

INTRODUCTION

Totally cystic intradural extramedullary (IDEM) lesions are uncommon and form a different spectrum of conditions as compared to the commonly seen IDEM tumors. (3) Schwannomas, the most common IDEM tumors are mostly solid or heterogeneous solid tumors; a completely cystic schwannoma is very rare. (1-5) The authors describe a case of totally cystic IDEM schwannoma and stress the importance of complete contrast studies to diagnose this potentially curable cystic IDEM tumor. The consideration of diagnosis is important in view of the different prognosis of the cystic schwannomas as compared to the other cystic IDEM lesions.

CASE DESCRIPTION

A 70-year-old male patient presented to us with complaints of nonspecific low back for 6 months. There was no history of any sensory involvement, bowel-bladder symptoms and the neurological examination was normal with no deficits. MR imaging of the spine revealed the presence of an intradural extramedullary lesion isointense on T1WI, hyperintense on T2WI with characteristic ring enhancement suggestive of a totally cystic intradural extramedullary tumor. (Figure 1A,B and 2A,B) A diagnosis of a cystic schwannoma or a neurofibroma

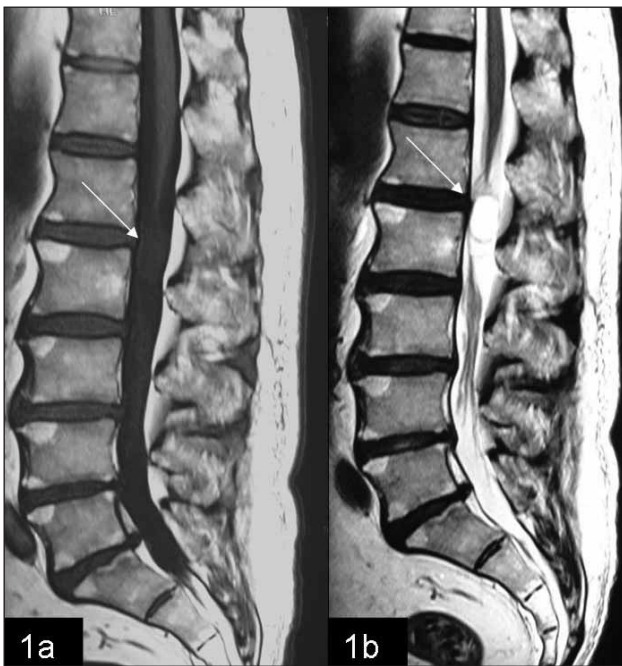


Figure 1: Sagittal T1WI (1A) and T2WI (1B) showing a very well defined IDEM lesion isointense on T1WI and hyperintense on T2WI.

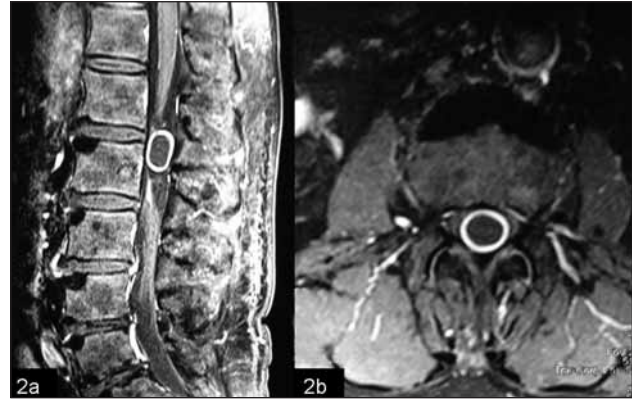


Figure 2: Characteristic ring enhancement is seen on post contrast sagittal (2A) and axial MR images (2B).

was considered. Total excision of the tumor was performed by L 1 L 2 laminectomy during which the tumor delivered itself completely on incising the dura. Intra-operatively there was a completely cystic intradural extramedullary tumor arising from one of the fascicles of the sacral nerve root which was excised in toto. Microphotograph showing a tumor composed of spindle shaped cells with elongated nuclei and tapering ends, arranged in a pallisading fashion suggestive of a schwannoma. (Figure 3) The patient had an uneventful post operative course with no fresh onset neurological deficits

DISCUSSION

Intradural extramedullary location is a common site for occurrence of spinal tumors. (1-5) The majority of these are benign consisting of either nerve sheath tumors or meningiomas.(1-5) Though a

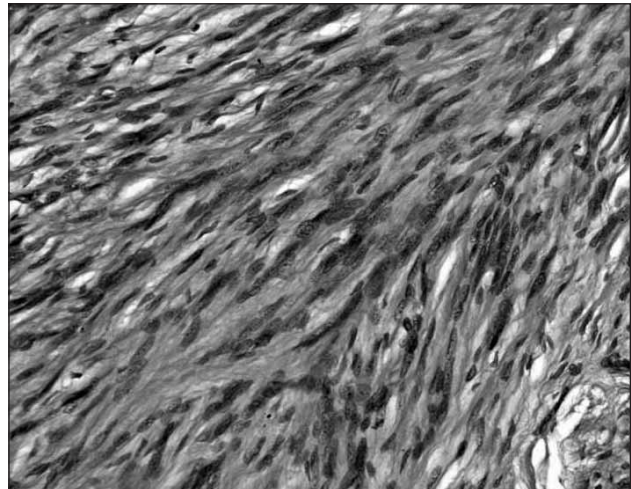


Figure 3: Microphotograph showing a tumor composed of spindle shaped cells with elongated nuclei and tapering ends, arranged in a pallisading fashion suggestive of a schwannoma. (H&Ex100)

myriad of tumors may occur in an intradural extramedullary location (IDEM); totally cystic lesions at this location are relatively uncommon and form a different spectrum of conditions as compared to the commonly seen IDEM tumors. (3)

Schwannomas, the most common IDEM tumors are mostly solid or heterogeneous solid tumors. Though cystic degeneration can occur, a completely cystic schwannoma is rare and needs to be distinguished from other cystic lesions at such a location like perineural, Tarlov, arachnoid, neuroenteric, epidermoid or bronchogenic cysts and cystic teratoma. (1-5) Nonspecific pain may be the only manifestation of the tumor and imaging, mainly MRI, forms the mainstay of the diagnosis. However as number of these lesions can appear the same on a plain spinal MRI; a complete MR contrast study should be performed to diagnose this rare form of cystic schwannoma as it has a well-

enhancing wall compared to other cystic lesion that usually lack this structure. (1) The importance of diagnosing these tumors cannot be overemphasized in view of their varied biological behavior and prognosis. (1-5)

REFERENCES

1. Beall DP, Googe DJ, Emery RL, Thompson DB, Campbell SE, Ly JQ, DeLone D, Smirniotopoulos J, Lisanti C, Currie TJ: Extramedullary intradural spinal tumors: a pictorial review. *Curr Probl Diagn Radiol* 36:185-98, 2007
2. Chongyi S, Meng Y, Dejun Y, Yingjie L, Qingpeng L: Lumbar intradural extramedullary bronchiogenic cyst. *Eur Surg Res* 40:26-28, 2008
3. Parmar H, Patkar D, Gadani S, Shah J: Cystic lumbar nerve sheath tumors: MRI features in five patients. *Australas Radiol* 45:123-127, 2001
4. Scarrow AM, Levy EI, Gerszten PC, Kulich SM, Chu CT, Welch WC: Epidermoid cyst of the thoracic spine: Case history *Clin Neurol Neurosurg*. 103:220-222, 2001
5. Stevens QE, Kattner KA, Chen YH, Rahman MA: Intradural extramedullary mature cystic teratoma: Not only a childhood disease. *J Spinal Disord Tech*. 19:213-216, 2006