



A Novel Retractor for Reducing Operation Time and Radiation Exposure in Percutaneous Pedicle Screw Placement

Lei NIU, Rui HE, Liqun DUAN, Wenzhi ZHANG, Xu LI, Haiping CAI

Department of Orthopedics, The First Affiliated Hospital of University of Science and Technology of China

Corresponding author: Lei NIU ✉ 179644522@qq.com

ABSTRACT

AIM: To design a novel hand-held retractor in order to reduce both operation time and radiation exposure in percutaneous pedicle screw placement.

MATERIAL and METHODS: A total of 126 patients with single segment thoracolumbar vertebral fracture were surgically treated with percutaneous pedicle screws through our novel hand-held retractor technique (group A) or conventional fluoroscopic method (group B), the operation time and fluoroscopy shot times were compared, and the accuracy of screw placement were assessed.

RESULTS: There was no serious complications occurring during our study, such as infection, blood vessel injury, spinal cord or nerve root injury. We did not find any statistically difference between the two groups in corrected rate of regional Cobb's angle or vertebral body height percentage ($p>0.05$), however, the mean operation time was found to be 75.9 ± 2.37 min in the novel hand-held retractor method group and 94.2 ± 2.19 min in the conventional method group. The difference was statistically significant ($p<0.001$). Fluoroscopy shot times averaged 9.01 ± 0.41 in the novel hand-held retractor group versus 16.8 ± 0.56 in the conventional group ($p<0.001$), the novel hand-held retractor group had apparent advantages over the conventional method in postoperative improvement on visual analog scale (VAS) scores and Oswestry Disability Index (ODI) at 2 days, 3 months after operation and last follow-up ($p<0.05$). There was no statistical difference between group A and B in the radiographic results and screw position violation grade.

CONCLUSION: The novel hand-held method retractors have several advantages, including shorter operation time, less fluoroscopy shot times, and better postoperative improvement on visual analog scale (VAS) scores and Oswestry Disability Index (ODI). It provides a new alternative method for effective management of thoracolumbar fractures.




KEYWORDS: Percutaneous pedicle screw, Novel retractor, Surgery time, Fluoroscopy shot time, Thoracolumbar vertebral fracture




ABBREVIATIONS: VAS: Visual analog scale, ODI: Oswestry disability index, TLICS: Thoracolumbar injury classification and severity score

INTRODUCTION

Percutaneous pedicle screw fixation provides a less invasive method that reduces damage to surrounding muscle tissue, reduces blood loss recovery time (1,2,4,6,7). These characteristics may translate into better long-term clinical outcomes, reduced paravertebral muscle

denervation, atrophy, and pain. During traditional percutaneous pedicle screw placement (11,17,26), recognition of bone markers is overly dependent on fluoroscopic guidance (4,24), which may result in severe radiation exposure for both the surgeon and the assistant (17,28). Therefore, a tool or system that can help to place pedicle screws accurately and reduce the

Lei NIU  : 0000-0002-0799-7515
Rui HE  : 0000-0001-5214-1743
Liqun DUAN  : 0000-0001-7131-0098

Wenzhi ZHANG  : 0000-0002-4072-0964
Xu LI  : 0000-0001-5209-0747
Haiping CAI  : 0000-0001-5232-7484

exposure time of fluoroscopy is extremely valuable (6,7,19). In this article, a novel hand-held retractor was designed to assist exposing the bony landmarks of the spine. The purpose of this study was to compare the clinical outcomes, fluoroscopy shot times, operative time, and the accuracy of the novel hand-held retractor method with the traditional fluoroscopic technique for percutaneous pedicle screw fixation.

■ MATERIAL and METHODS

General Information

126 patients with thoracolumbar vertebral fracture who underwent posterior percutaneous transpedicular screw fixation were retrospectively reviewed in our department from March 2014 to January 2018. Patient inclusion criteria were: (a) single segmental acute or subacute thoracolumbar fracture (T10-L2); (b) clinical and imaging data were complete; (c) the postoperative follow-up time was over 12 months. We excluded patients with pathological fractures, severe osteopenia (defined as bone mineral density [BMD] t score < -2.5), or with symptoms of spinal cord or cauda equina injury, the patients with prior spinal surgery history were also excluded.

All patients underwent thoracolumbar X-ray, computed tomography combined with three-dimensional reconstruction, magnetic resonance imaging (MRI) and bone density measurement before surgery. The injury severity was determined by the thoracolumbar injury classification system (TLICS) (8,16,18). Within the 126 patients, 57 cases received surgery with the application of the novel retractor (novel retractor group, group A), the other 69 patients were treated through the traditional fluoroscopic method (traditional group, group B). The general character and distribution of fractured vertebra were demonstrated in Table I.

The Character of the Novel Retractor System

The retractor system consist of a series of ten “s” shaped

retractors; for each retractor, it was constituted of two straight heads and a slender shaft, The length of the head increased 2 cm step by step, change from 2 cm to 10 cm, for each retractor, the width of one head was 1 cm, and 1.5 cm for the other head; for all retractor heads, an inside learning angle of 30° was designed in the distant 5 mm end. The novel retractor system can be used to pull soft tissue, and the head of the retractor can be stuck in the base of transverse process, thus Herringbone crest, namely pedicle screw entrance point can be fully exposed (The character of the novel retractor was illustrated in Figure 1A, B).

Surgical Procedure

All operations were performed under general anesthesia. The chest and ilium were cushioned with bolsters, the abdomen was suspended, and the spine was in the hyperextension position. By C-arm X-ray examination, the pedicles of fractured vertebra and its upper and lower vertebral pedicles (known as upper and lower vertebra) are located and marked on the skin correspondingly, then pressure was applied to the spinous process of the fractured vertebral body for a partial possible reduction.

In traditional method group, the skin was incised approximately 1 cm lateral to the corresponding pedicle marker on the skin. Lumbodorsal fascia was then incised. Guided by the C-arm, the needle passed through the pedicle into the vertebra body, the guide wire was then inserted into the vertebral body along the hollow needle. The dilation tube was gradually placed through the guide wire and the last stage of the dilation tube was retained. The pedicle was tapped forward to the junction between pedicle and vertebral body for screw insertion, then the hollow pedicle screw was inserted into the vertebra body through pedicle. Finally, the guide wire and the last stage dilation tube were removed. Four monoaxial pedicle screws were inserted into the upper and lower vertebrae of the fractured vertebra, and two polyaxial pedicle screws were inserted into the fractured vertebra. Neither cross-linking nor

Table I: Overview of Patient Demographic and Distribution of Fractured Vertebra in Group A and Group B

	Novel retractor group (group A)	Traditional group (group B)	p
Patients (n)	57	69	
Age	45.2 ± 1.94	44.7 ± 1.40	0.830
Gender (male/female)	37/20 (64.9%/35.1%)	46/23 (66.7%/33.3%)	
Injured spinal level			
T11	5	8	
T12	22	25	
L1	26	28	
L2	4	8	
TLICS score	4.5 ± 0.17	4.6 ± 0.15	0.874
Preoperative duration (days)	5.2 ± 2.0	5.1 ± 2.5	0.833

TLICS: Thoracolumbar injury classification system.

drainage tube was placed. After the screw placement, C-arm X-ray was performed to check the accuracy of the pedicle screws, and titanium rods prebent according to the normal sagittal curvature of the fracture area were used for fixation, finally, cephalic and caudalis distractions were performed, respectively.

In novel retractor group, after the incision of skin and lumbodorsal fascia, the natural space between the multifidus and the longissimus muscles was separated with the index finger, the facet joint was located with the help of the finger, with one retractor of suitable length and width stuck in the base of transverse process, the multifidus was pulled to the lateral of facet joint, another retractor was used to pull the longissimus muscle to the medial, separation was then performed through the intermuscular space between the multifidus and the longissimus muscles to the outer edge of the facet joint, then the Herringbone crest was exposed clearly, after tapping of the pedicle, the pedicle screw was inserted by freehand under direct vision; similarly, after the titanium rods were installed and the distraction and reduction was completed, C-arm X-ray examination was performed again to confirm the location of the pedicle screws and the reduction of the fractured vertebra (the use of novel retractor in percutaneous pedicle screw placement was illustrated in Figure 1C-F. Preoperative and postoperative images of a case treated with our novel retractor is shown in Figure 3A-K).

Evaluation Methods

The operation time and fluoroscopy shot times of the two groups were recorded. The position accuracy of the screws were evaluated based on postoperative CT scan, screw accuracy was assessed using a 4-point grading scale (5,25): grade 0 (ideal): screw without any cortical perforation; Grade 1 (minimally displaced): safety screw, cortical perforation less than 3 mm; Grade 2 (moderate displacement): displacement greater than 3 mm but less than 5 mm; Grade 3 (critical displacement): displacement greater than 5 mm. Lateral X radiograph preoperative and postoperative was used to evaluate the sagittal regional Cobb angle and the anterior column height. The height of the anterior column of the fractured vertebra was defined as half of the total height of the upper and lower vertebra. The anterior column height percentage was calculated by the ratio of the actual height of the fractured vertebra to the reference height of the anterior column. The sagittal regional Cobb angle was calculated as the angle between the upper and lower endplate of the fractured vertebral body. VAS (Visual Analog Scale) scores and ODI (Oswestry Disability Index) before surgery, 2 days, 3 months after operation, and last follow-up were assessed. Two spinal surgeons, who were not involved in the surgery, examined all the images twice within an interval of two weeks. Each retest was blinded to the first result. The average of the four measurements was used as the final score.

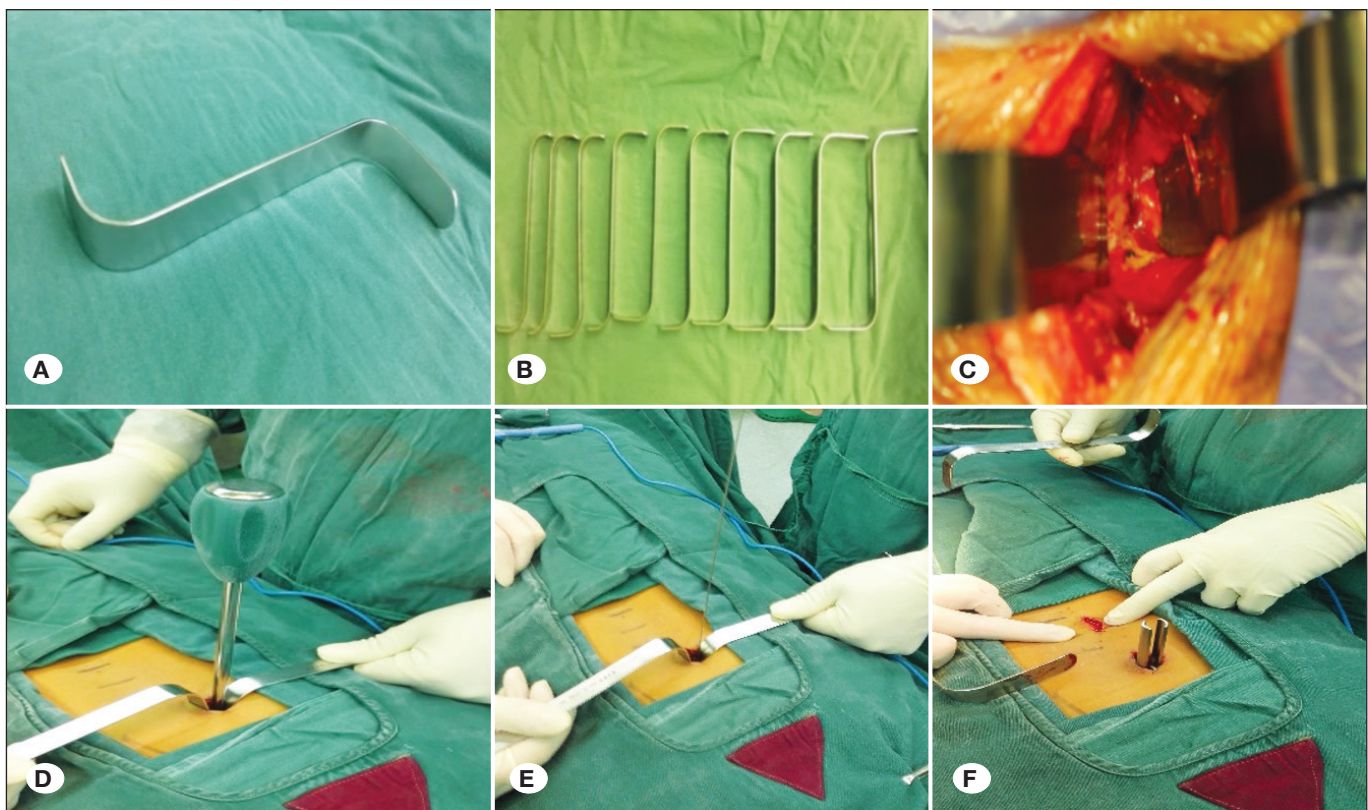


Figure 1: The series of novel retractors and their application in the surgery: **A)** The “s” shaped single retractor; **B)** the series of ten retractors with different length and width of head; **C)** with the help of two retractors, the Herringbone crest, thus entry point of pedicle screw, can be exposed; **D)** preparation of the pedicle with a tap; **E)** after conforming that there was no penetration with a probe, the guide-wire was inserted into the pedicle; **F)** the pedicle screw was inserted freehand.

Statistical Analysis

SPSS 22.0 was used for statistical analysis. The accuracy of the screws in the two groups was compared using a rank-sum test, $p < 0.05$ was considered significant. Clinical and radiographic data were expressed as mean \pm SE, the measurements between the two groups were compared using two-sample-t test with $p < 0.05$ considered statistically significant.

RESULTS

In this study, 342 and 414 pedicle screws were placed in group A and B respectively. The mean operation time was 75.9 ± 2.37 min in the novel retractor method group (group A) and 94.2 ± 2.19 min in the traditional method group (group B). The difference was statistically significant ($p < 0.001$). Fluoroscopy shot times averaged 9.01 ± 0.41 times in the novel retractor group versus 16.8 ± 0.56 times in the traditional group ($p < 0.0001$) (Table II). This represents an average decrease of

7.7 (45.8%) fluoroscopy shot times with the use novel retractor. Of those pedicle screws, 292 screws (85.4%) in group A and 349 screws (84.3%) in group B were ideally inserted within the pedicle (grade 0), the rest were misplaced to different degrees and in different directions, of which most pedicle violations are grade 1 (37(10.8%) screws in group A, 45(10.9%) screws in group B), without any grade 3 displacement. The screw position of grade 0 and violation grade (grade 1, 2, and 3) between group A and B were not statistically difference ($Z = 0.452$, $p = 0.651$). The pedicle violations information is demonstrated in Figure 2.

Differences were not found in vertebral body height percentage and Cobb's angle between the two groups at each different time points (Table II) ($p > 0.05$). All patients were followed up for 12-30 months. The average was 15.5 months in group A, and 15.9 months in group B. The VAS score and ODI at different time point of the two groups were shown in table 2. VAS score and ODI of both groups were significantly improved 2 days after surgery compared with the preoperative level,

Table II: Comparison of the Outcomes Between Novel Hand-Held Retractor Group (Group A) and Conventional Fluoroscopic Method Group (Group B)

	Novel retractor group (group A)	Conventional group (group B)	p
Surgery Time (min)	75.9 ± 2.37	94.2 ± 2.19	<0.001
Fluoroscopy Shot times	9.01 ± 0.41	16.8 ± 0.56	<0.001
Follow-up duration (months)	15.5 ± 0.65	15.9 ± 0.67	0.679
Anterior column height percentage (%)			
Preoperative	69.4 ± 1.36	68.9 ± 1.26	0.808
2 days postoperative	92.9 ± 0.90	90.7 ± 0.84	0.07
3 months postoperative	90.4 ± 1.75	90.2 ± 0.64	0.908
Last follow-up	90.0 ± 0.64	89.0 ± 0.57	0.243
Sagittal regional Cobb angle (°)			
Preoperative	16.2 ± 0.60	16.6 ± 0.58	0.628
2 days postoperative	8.9 ± 0.34	9.4 ± 0.38	0.441
3 months postoperative	10.2 ± 0.25	9.7 ± 0.37	0.284
Last follow-up	10.3 ± 0.25	10.1 ± 0.37	0.630
VAS score			
Preoperative	4.90 ± 0.16	4.73 ± 0.16	0.457
2 days postoperative	2.53 ± 0.11	3.0 ± 0.10	0.002
3 months postoperative	1.6 ± 0.14	2.3 ± 0.13	0.002
Last follow-up	1.1 ± 0.11	1.5 ± 0.09	0.012
ODI			
Preoperative	57.0 ± 2.00	55.2 ± 1.60	0.481
2 days postoperative	23.3 ± 1.25	27.2 ± 1.27	0.031
3 months postoperative	11.7 ± 0.41	14.1 ± 0.50	<0.001
Last follow-up	10.4 ± 0.47	10.8 ± 0.36	0.619

VAS: Visual analog scale, ODI: Oswestry disability index.

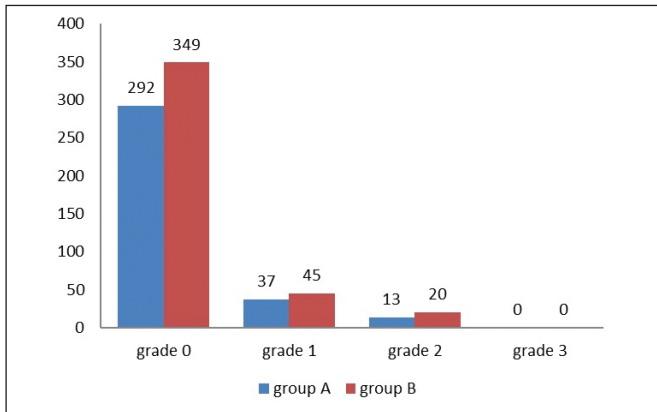


Figure 2: A bar graph representation of the amount of screws classified according to Gertzbein-Robbins classification category.

compared with group B, VAS score and ODI of group A were lower, with statistically significant difference ($p < 0.05$). VAS score and ODI of two groups were both improved 3 months after operation and at the last follow-up, and the outcomes of group A were significantly better than group B. Except for ODI at the last follow-up, the differences between the two groups were statistically significant ($p < 0.05$).

DISCUSSION

In 1977, The technique of percutaneous pedicle screw was first proposed by Magerl as a temporary external fixation for spinal fractures and spondylodiscitis (12). Numerous studies (11,17,22,26) have shown that the technique reduced blood loss and transfusions, improving perioperative outcomes. In addition, it reduced back pain and hospital stays, improving

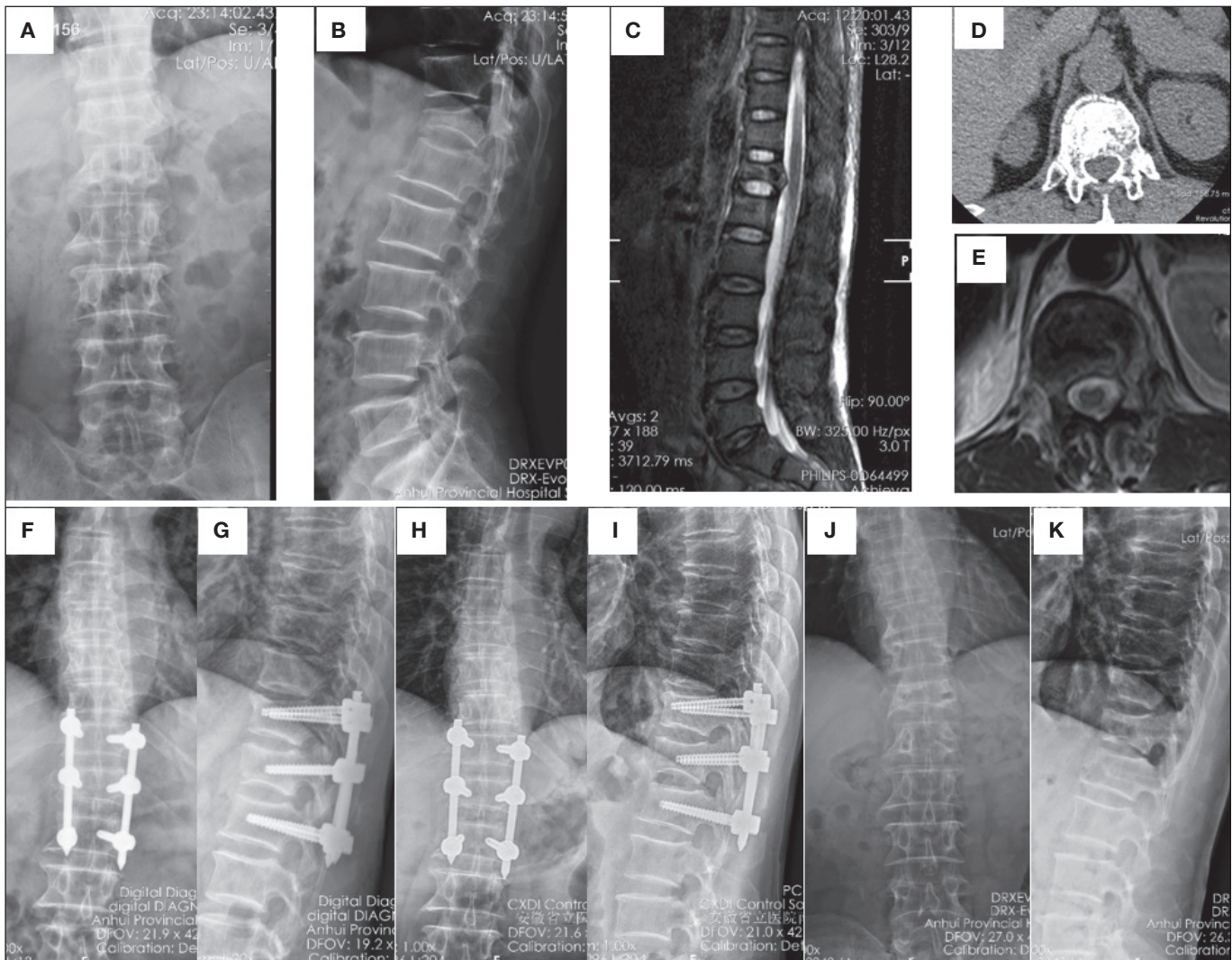


Figure 3: A 50 years old man with T12 burst fracture (B, D), MRI (C) showed posterior ligament complex damaged, preoperative TLICS score was 5, the surgery was done through the novel retractor method. Before surgery (A, B), anterior column height percentage was 46.9%, Sagittal regional Cobb angle was 25.5°; 2 days postoperative (F, G), anterior column height percentage was 93.0%, Sagittal regional Cobb angle was 10.6°; three months postoperative (H, I), anterior column height percentage was 92.1%, Sagittal regional Cobb angle was 11.3°. 13 months postoperative, the screws were taken out, three months after the screws taken out (J, K), anterior column height percentage was 89.2%, Sagittal regional Cobb angle was 9.6°.

postoperative outcomes, with similar surgical efficacy compared with the traditional open pedicle screw fixation (26). More importantly, the incidence of nerve injury has been shown to be as low as open techniques (27).

Percutaneous pedicle screw also had obvious potential limitations. These limitations include (4,6,13,28): longer duration of surgery and more frequency of fluoroscopy for both patients and medical staff. Previous studies have shown that conventional percutaneous pedicle screw placement has a high incidence of erroneous placement (29), and a steep learning curve (3). In the traditional method, obtaining a proper screw trajectory relies heavily on fluoroscopy. Inserting the guide wire into the pedicle requires extensive radiographic imaging (20). In recent years, a lot of systems or equipment were introduced to facilitate the placement of percutaneous pedicle screw (15,19,23). These systems might improve the safety and decrease the radiation exposure, but added a lot of time to the surgery procedure at the same time, what's more, most hospitals cannot afford the high cost of these systems. Compared with these complicated systems, our novel retractor was relatively simple and practical, and affordable for every patient. Our novel retractor combines the advantages of percutaneous pedicle screw and Wiltse approach, exposure of the entry point was facile with the help of our novel retractor, just like the mini-open Wiltse approach that most spinal surgeons familiar with. In a study (3), the efficacy of percutaneous pedicle screw and mini-open Wiltse approach fixation in the treatment of thoracolumbar fractures without neurological impairment was compared, the C-arm exposure times in percutaneous pedicle screw group was 16.3 ± 2.6 seconds and 4.8 ± 1.7 seconds in the mini-open Wiltse approach group. Compared with traditional fluoroscopic method, the practicability and feasibility of our novel retractor greatly reduces the operation time and radiation exposure. In our study, the operation time in novel retractor group was 81.5% of that of traditional group, the fluoroscopic shot times was 43.8% less compared with traditional group.

VAS scores were significantly different between group A and B, showing that our novel retractor method was advantageous in this aspect over the traditional method. In our novel retractor method, we can set the percutaneous pedicle screw through natural space between the multifidus and the longissimus, from which the transverse process and facet joint could be easily exposed, making a good operative field, care should be taken to avoid facet joint impingement. In traditional percutaneous technique, because the surgeon relies solely on fluoroscopy to place the screws, the anatomical marks cannot be seen directly. The facet joint is not easily visible on standard fluoroscopic images and may be damaged by puncture instruments if it is not carefully avoided. A previous study show that violation of facet joint can be found in about 20% of screws and 30%–35% of patients (9), in theory it may lead to accelerated facet degeneration and premature alteration of adjacent segments, all were the reasons of postoperative low back pain. In the traditional group, repeated punctures were always needed before the needle passing through the pedicle into the vertebral body in satisfactory position and direction, which was associated with facet joint capsule

damage (9), it was a common reason of low back pain and could lead to chronic pain and disability in adults (21). In the traditional group, in the dilation tubes expanding and screw-in process of the percutaneous pedicle screw, it may not pass through the intermuscular space between the multifidus and the longissimus accurately, causing extensive stripping of paraspinal muscle, resulting in severe back pain and longer hospitalization time.

The novel retractor system was particularly suitable for obese patients. In obese patients, anatomical markers are often blurred and indistinguishable on intraoperative fluoroscopy or imaging, and the quantity of the multifidus muscle is an important risk factor for pedicle screw displacement (10,14). In bulky patients, the surgery should be done in a deeper space, which was more difficult to be performed. In our novel retractor method, the longest head was 10cm, it was long enough to reach the facet joint directly. This novel retractor is in high demand because it provides a general sense of visualization and tactile feel, by using the novel retractor, we could expose the entry point effectively and the percutaneous pedicle screw could be inserted accurately.

What's more, no difference was shown in correcting rate of Cobb's angle and vertebral body height percentage between the two groups, suggesting radiographic outcomes of novel retractor method was similar to that of traditional method. Currently the major limitation of the novel retractor is that it is not suitable for posterior decompression and fusion surgery. Therefore, our inclusion criteria were strictly limited to cases of thoracolumbar vertebral fracture without neurological defect.

■ CONCLUSION

Compared with the traditional fluoroscopic method, the novel retractor method has several advantages, including shorter operative time, less fluoroscopy shots, and improved visual analog scale (VAS) scores and ODI. It provides a new alternative operation method for effective management of thoracolumbar fractures.

■ REFERENCES

1. Alander DH, Cui S: Percutaneous pedicle screw stabilization: Surgical technique, fracture reduction, and review of current spine trauma applications. *J Am Acad Orthop Surg* 26:231-240, 2018
2. Chapman TM, Blizzard DJ, Brown CR: CT accuracy of percutaneous versus open pedicle screw techniques: A series of 1609 screws. *Eur Spine J* 25(6):1781-1786, 2016
3. Fan Y, Zhang J, He X, Huang Y, Wu Q, Hao D: A comparison of the mini-open wiltse approach with pedicle screw fixation and the percutaneous pedicle screw fixation for neurologically intact thoracolumbar fractures. *Med Sci Monit* 23:5515-5521, 2017
4. Gu G, Zhang H, He S, Cai X, Gu X, Jia J, Fu Q, Zhou X: Percutaneous pedicle screw placement in the lumbar spine: A comparison study between the novel guidance system and the conventional fluoroscopy method. *J Spinal Disord Tech* 28(9):E522-527, 2015

5. Innocenzi G, Bistazzoni S, D'Ercole M, Cardarelli G, Ricciardi F: Does navigation improve pedicle screw placement accuracy? Comparison between navigated and non-navigated percutaneous and open fixations. *Acta Neurochirurgica Supplement* 124:289-295, 2017
6. Ishii K, Kaneko Y, Funao H, Ishihara S, Shinohara A, Nakanishi K, Hikata T, Fujita N, Iwanami A, Hosogane N, Watanabe K, Nagura T, Nakamura M, Toyama Y, Matsumoto M: A novel percutaneous guide wire (s-wire) for percutaneous pedicle screw insertion: Its development, efficacy, and safety. *Surgical Innovation* 22:469-473, 2015
7. Ishii K, Shiono Y, Funao H, Singh K, Matsumoto M: A novel groove-entry technique for inserting thoracic percutaneous pedicle screws. *Clin Spine Surg* 30:57-64, 2017
8. Joaquim AF, de Almeida Bastos DC, Jorge Torres HH, Patel AA: Thoracolumbar injury classification and injury severity score system: A literature review of its safety. *Global Spine J* 6:80-85, 2016
9. Jones-Quaidoo SM, Djurasovic M, Owens RK 2nd, Carreon LY: Superior articulating facet violation: Percutaneous versus open techniques. *J Neurosurg Spine* 18:593-597, 2013
10. Kim MC, Chung HT, Cho JL, Kim DJ, Chung NS: Factors affecting the accurate placement of percutaneous pedicle screws during minimally invasive transforaminal lumbar interbody fusion. *Eur Spine J* 20(10):1635-1643, 2011
11. Li K, Li Z, Ren X, Xu H, Zhang W, Luo D, Ma J: Effect of the percutaneous pedicle screw fixation at the fractured vertebra on the treatment of thoracolumbar fractures. *Int Orthop* 40:1103-1110, 2016
12. Magerl FP: Stabilization of the lower thoracic and lumbar spine with external skeletal fixation. *Clin Orthop Relat Res* 189:125-141, 1984
13. Mobbs RJ, Raley DA: Complications with K-wire insertion for percutaneous pedicle screws. *J Spinal Disord Tech* 27(7):390-394, 2014
14. Mobbs RJ, Sivabalan P, Li J: Technique, challenges and indications for percutaneous pedicle screw fixation. *J Clin Neurosci* 18:741-749, 2011
15. Molligaj G, Schatlo B, Alaid A, Solomiichuk V, Rohde V, Schaller K, Tessitore E: Accuracy of robot-guided versus freehand fluoroscopy-assisted pedicle screw insertion in thoracolumbar spinal surgery. *Neurosurgical Focus* 42:E14, 2017
16. Park HJ, Lee SY, Park NH, Shin HG, Chung EC, Rho MH, Kim MS, Kwon HJ: Modified thoracolumbar injury classification and severity score (TLICS) and its clinical usefulness. *Acta Radiol* 57:74-81, 2016
17. Phan K, Rao PJ, Mobbs RJ: Percutaneous versus open pedicle screw fixation for treatment of thoracolumbar fractures: Systematic review and meta-analysis of comparative studies. *Clin Neurol Neurosurg* 135:85-92, 2015
18. Pneumaticos SG, Karampinas PK, Triantafilopoulos G, Koufos S, Polyzois V, Vlamis J: Evaluation of TLICS for thoracolumbar fractures. *Eur Spine J* 25(4):1123-1127, 2016
19. Richter PH, Gebhard F, Salameh M, Schuetze K, Kraus M: Feasibility of laser-guided percutaneous pedicle screw placement in the lumbar spine using a hybrid-OR. *Int J Comput Assist Radiol Surg* 12:873-879, 2017
20. Smith BW, Joseph JR, Kirsch M, Strasser MO, Smith J, Park P: Minimally invasive guidewireless, navigated pedicle screw placement: A technical report and case series. *Neurosurgical Focus* 43:E9, 2017
21. Snidvongs S, Taylor RS, Ahmad A, Thomson S, Sharma M, Farr A, Fitzsimmons D, Poulton S, Mehta V, Langford R: Facet-joint injections for non-specific low back pain: A feasibility RCT. *Health Technol Assess* 21:1-130, 2017
22. Sun XY, Zhang XN, Hai Y: Percutaneous versus traditional and paraspinal posterior open approaches for treatment of thoracolumbar fractures without neurologic deficit: A meta-analysis. *Eur Spine J* 26(5):1418-1431, 2017
23. Tian W, Fan MX, Liu YJ: Robot-assisted percutaneous pedicle screw placement using three-dimensional fluoroscopy: A preliminary clinical study. *Chinese Medical Journal* 130:1617-1618, 2017
24. Tsuang FY, Chen CH, Kuo YJ, Tseng WL, Chen YS, Lin CJ, Liao CJ, Lin FH, Chiang CJ: Percutaneous pedicle screw placement under single dimensional fluoroscopy with a designed pedicle finder-a technical note and case series. *Spine J* 17(9):1373-1380, 2017
25. von Jako R, Finn MA, Yonemura KS, Araghi A, Khoo LT, Carrino JA, Perez-Cruet M: Minimally invasive percutaneous transpedicular screw fixation: Increased accuracy and reduced radiation exposure by means of a novel electromagnetic navigation system. *Acta Neurochirurgica* 153:589-596, 2011
26. Wang H, Zhou Y, Li C, Liu J, Xiang L: Comparison of open versus percutaneous pedicle screw fixation using the sextant system in the treatment of traumatic thoracolumbar fractures. *Clin Spine Surg* 30(3):E239-E246, 2017
27. Yang M, Zhao Q, Hao D, Chang Z, Liu S, Yin X: Comparison of clinical results between novel percutaneous pedicle screw and traditional open pedicle screw fixation for thoracolumbar fractures without neurological deficit. *International Orthopaedics* 43:1749-1754, 2019
28. Zhang L, Zhou X, Cai X, Zhang H, Fu Q, He S: Reduction in radiation during percutaneous lumbar pedicle screw placement using a new device. *Minim Invasive Ther Allied Technol* 23(3):173-178, 2014
29. Zhao Q, Zhang H, Hao D, Guo H, Wang B, He B: Complications of percutaneous pedicle screw fixation in treating thoracolumbar and lumbar fracture. *Medicine (Baltimore)* 97(29):e11560, 2018