



## Original Investigation

DOI: 10.5137/1019-5149.JTN.27471-19.2

Received: 21.07.2019

Accepted: 21.10.2019

Published Online: 10.02.2020

# The Impact of Intraoperative Monitoring on Extent of Resection and Long-Term Neurological Outcomes: A Series of 39 Intramedullary Ependimomas

Mihailo MILICEVIC<sup>1</sup>, Domenico SOLARI<sup>2</sup>, Rosanda ILLIC<sup>1</sup>, Federico FRIO<sup>2</sup>, Aleksandar STANIMIROVIC<sup>3</sup>, Dragan SAVIC<sup>1</sup>, Teresa SOMMA<sup>2</sup>, Luigi Maria CAVALLO<sup>2</sup>, Danica GRUJICIC<sup>1</sup>

<sup>1</sup>Medical Faculty University of Belgrade, Clinical Center of Serbia, Clinic of Neurosurgery, Belgrade, Serbia

<sup>2</sup>Università degli Studi di Napoli Federico II, Department of Neurosciences and Reproductive and Odontostomatological Sciences, Division of Neurosurgery, Naples, Italy

<sup>3</sup>Clinical Center of Serbia, Clinic of Neurosurgery, Belgrade, Serbia

**Corresponding author:** Teresa SOMMA ✉ teresa.somma85@gmail.com

**ABSTRACT**

**AIM:** To analyze the impact of intraoperative neurophysiological monitoring (IONM) on the extent of removal and long-term neurological outcomes in a series of grade II ependymomas.




**MATERIAL and METHODS:** We retrospectively reviewed 88 consecutive patients who underwent surgical resection of an intramedullary spinal cord tumor (IMSCT) at the Clinic of Neurosurgery of the Clinical Center of Serbia in Belgrade between January 2012 and December 2017. In all, 39 patients (25 males and 14 females; mean age 46.16 years) with grade II ependymomas were enrolled in this study; the mean follow-up time was 49.84 months. The modified McCormick Scale (mMCS) was used to assess the short- and long-term outcomes, and the patients were divided into two groups based on whether they underwent IONM.




**RESULTS:** The gross-total removal rate was 89.7%, and it was not influenced by use of IONM, location or tumor size. Upon admission, 43.2% of the patients were dependent (grades IV and V), while 56.8% were independent (grades I, II and III), according to the mMCS. After 3 months of follow-up, 76.9% of the patients maintained or improved their neurological status, but this percentage was reduced after long-term follow-up.


**CONCLUSION:** Total surgical resection with good neurological outcomes can be achieved in the vast majority of patients with grade II ependymomas; it is important to emphasize that the use of IONM allows acceptable extent of resection and provides better results in terms of functional outcomes, with lower morbidity rates. Therefore, no correlation was demonstrated between the decrease in the basal amplitudes of IONM and D-waves and poor neurological outcomes.

**KEYWORDS:** Ependymomas, Spinal surgery, Intraoperative monitoring, Laminoplasty, Recurrence-free survival

**ABBREVIATIONS:** IONM: Intraoperative neurophysiological monitoring, IMSCT: Intramedullary spinal cord tumor, mMCS: Modified McCormick Scale, WHO: World Health Organization, EOR: Extent of resection, GTR: Gross total removal, STR: Subtotal resection, ECOGPS: Eastern Cooperative Oncology Group scale of Performance Status, QoL: Quality of life, KS: Score Klekamp and Samii Clinical Scoring System, SSEPs: Spinal somatosensory-evoked potentials, MEPs: Motor-evoked potentials, RT: Radiation therapy, MRI: Magnetic resonance imaging, ASNM: American Society of Neurophysiological Monitoring

Mihailo MILICEVIC  : 0000-0001-9793-0471  
Domenico SOLARI  : 0000-0003-1535-8737  
Rosanda ILLIC  : 0000-0002-4883-7999

Federico FRIO  : 0000-0002-0010-2942  
Aleksandar STANIMIROVIC  : 0000-0002-7361-8333  
Dragan SAVIC  : 0000-0003-1465-9693

Teresa SOMMA  : 0000-0001-7864-1607  
Luigi Maria CAVALLO  : 0000-0003-4576-5667  
Danica GRUJICIC  : 0000-0002-1634-3898

## ■ INTRODUCTION

Intramedullary spinal cord tumors (IMSCTs) are relatively rare tumors with an incidence rate of approximately 1.1 cases per 100,000; these tumors represent up to 4% of all neoplastic lesions of the central nervous system (5), and almost 60% of all intramedullary lesions (13,16,34,35,46).

Ependymomas arise from ependymal cells, which border the central canal of the spinal cord (10). Ependymomas have been traditionally classified by the World Health Organization (WHO) Classification of Tumors of the Nervous System as grade I, II, and III according to the extent of cell anaplasia (27). Grade I ependymomas (myxopapillary type) occur at the level of the filum terminale and are quite infrequent, whereas grades II and III are the most common ependymomas with an overall prevalence of 50-60% among all intramedullary neuroepithelial tumors (10).

Surgical resection with the aim to achieve total tumor removal seems to have the most significant contribution in terms of progression-free survival and overall survival (1,2,4,17).

In lesions classified as grades I and II, gross total removal (GTR) can often be achieved, as these masses present a well-demarcated and circumscribed plane of cleavage (40, 44); therefore that these lesions can be isolated from the surrounding healthy tissues. Nevertheless, it should not be underestimated that intramedullary tumors, although benign, can lead to serious risks of neurological impairment. In this scenario, the introduction of intraoperative nerve monitoring has been an important development for the refinement of this field of surgery (9).

During recent decades, evidence of the effectiveness of IONM in spinal surgery has been consolidated and has provided the possibility of achieving safer and more accurate procedures. Many authors have properly addressed the value of Motor Evoked Potential (MEP) monitoring in guiding surgery, and accordingly, have suggested that tumor resection be abandoned when the waveform amplitudes deteriorate (36,42,45). However, no univocal consensus has been established regarding the exact threshold below which it should be mandatory to stop resection and to prevent postoperative neurological defects and predict good neurological outcomes (28-30).

To the authors' knowledge, only a few reports describing surgical outcomes in a series of grade II ependymomas have been published (6,17), but no published series have reported a comparison between patients with intramedullary ependymomas who underwent surgery with or without intraoperative nerve monitoring.

In the present study, we aimed to define the impact of intraoperative neurophysiological monitoring (IONM) on the extent of removal and the long-term neurological outcomes in a series of grade II ependymomas that were resected at a single center over a six-year timespan.

## ■ MATERIAL and METHODS

We retrospectively reviewed 88 consecutive patients who

underwent surgery for the treatment of an IMSCt at the Clinic of Neurosurgery of the Clinical Center of Serbia in Belgrade between January 2012 and December 2017. This study was approved by the institutional review board (IRB) of the School of Medicine of the University of Belgrade (SRB), which waived the necessity for informed consent due to the retrospective nature of the study. Written informed consent was obtained from the patients prior to any invasive clinicodiagnostic or surgical procedures; consent was also obtained for the eventual publication - for scientific purposes - of any anonymous patient records/information.

In this study, we enrolled 65 patients, who underwent surgery for a spinal ependymoma. Twenty-six patients with myxopapillary ependymomas (WHO grade I), located at the level of the conus medullaris, cauda equina and/or filum terminale, were excluded because they were classified as having extramedullary lesions. Therefore, the remaining 39 patients who presented with intramedullary cervical, thoracic and upper lumbar ependymomas were included in this study.

Age, type and tumor histology were collected from the medical records and analyzed with a focus on the following: symptoms and neurological status at admission, tumor localization and size (3/4 x p x ABC/2) (11), Eastern Cooperative Oncology Group scale of Performance Status (ECOGPS), quality of life (QoL), type of resection, use of intraoperative monitoring, days of hospitalization, adjuvant radiotherapy and chemotherapy and new postoperative motor/sensory defects at discharge and at the 1-year follow-up. The mean follow-up time was 49.87 months (range 12-90 months).

All patients underwent preoperative, 3-month and 12-month postoperative postgadolinium magnetic resonance imaging (MRI).

The preoperative and postoperative functional neurological status was defined according to the modified McCormick Scale (mMCS) (33), and after surgery, it was measured at discharge and after 3 months and 12 months of follow-up. A modified McCormick Scale (Grades I-V) was used to evaluate the ambulatory abilities (I=normal ambulation; II=mild motor sensory deficit, independent without external aid; III=independent with external aid; IV=care required; and V=wheelchair required). The Klekamp and Samii Clinical Scoring System (KS score) was used for the preoperative and immediate postoperative evaluation of motor and sensory functions, gait and urinary/anal sphincter capabilities (Figure 1). A patient's postoperative overall clinical status was measured using QoL grading.

We divided the patients into two groups based on the use of IONM: 17 patients underwent surgery with IONM (Group A), and 22 patients underwent surgery without IONM (Group B).

### Surgical Strategy and Postoperative Protocol

All surgical procedures were performed according to the conventional microsurgical paradigm, as described elsewhere (20), with each approach tailored to the tumor location and features. In all cases, we adopted posterior approaches with the patient in a prone position. Usually, a bilateral

Klekamp-Samii Neurological Scoring System					
Score	Sensory deficit	Motor weakness	Gait ataxia	Bladder function	Bowel function
5	No symptoms	Full power	Normal	Normal	Normal
4	Present, not significant	Movement against resistance	Unsteady, no aid	Slight disturbance, no catheter	Slight disturbance, full control
3	Significant, function not restricted	Movement against gravity	Mobile with aid	Residual, no catheter	Laxatives, full control
2	Some restriction of function	Contraction without gravity	Few steps with aid	Sometimes catheter	Sometimes loss of control
1	Severe restriction of function	Contraction without movement	Standing with aid	Often catheter	Often loss of control
0	incapacitated function	Plegia	Wheelchair	Permanent catheter	No control

modified Mc Cormick Scale	
Grade	Definition
I	Neurologically intact, ambulate normally, may have minimal dysesthesia
II	Mild motor or sensory deficit; patient maintains functional independence
III	Moderate deficit, limitation in function, independent with external aid
IV	Severe motor or sensory deficit, depend on external assistance
V	Paraplegia or quadriplegia

**Figure 1:** The Klekamp Samii clinical scoring system and the modified McCormick Scale.

posterior laminectomy was performed, except in 11 cases in which selective laminoplasty was preferred; only in 2 cases was duraplasty with a dural substitute layer completed in order to restore the integrity and sealing of the breach.

The use of IONM was chosen based on the radiological findings and according to the surgical plans (22); somatosensory-evoked potentials (SSEPs) and MEPs were recorded in all cases, while a D-wave was only recorded in selected cases (above level Th10). When D wave monitoring was not available, the mean values of MEP - measured in the different muscles in each limb - represented the most reliable information that could define the surgical strategy. As required, total intravenous anesthesia was administered without muscle relaxant drugs. A warning sound was produced upon significant alterations in any IONM parameter, so surgery could be temporarily interrupted. Warm irrigation and mild hypertension for at least 3 minutes were used before the surgical maneuvers were continued (41).

GTR was defined as complete tumor removal according to both intraoperative microscopic findings and postoperative MRI findings (Figure 2A-D). Subtotal resection (STR) was defined as a resection of the tumor mass with identifiable residual tumor  $\leq 20\%$ . STR was achieved either because of technical issues related to tumor features and/or anatomy, or because of the irreversible decrease in IONM parameters.

In the postoperative period, all patients received a low dosage of dexamethasone and fraxiparine for five days regardless of their neurological status, and physical neurorehabilitation was initiated regardless of whether motor defects were observed (POD 3).

Adjuvant therapy was suggested according to the decision of the interdisciplinary tumor board and usually consisted of fractionated radiation therapy (RT) with a total dose of 45–50.4 Gy (1.8Gy per dose, 5 days per week).

### Statistical Analysis

Statistical analyses were performed using SPSS Statistics 21 (IBM analytics); clinical outcomes were determined according to the functional status. A correlation between the KS score and mMCS score was evaluated using the Pearson correlation test. Given the good correlation between the two variables measured at hospital admission (KS Sensory,  $r=-0.387$   $p=0.015$ ; KS Motor,  $r=-0.891$   $p=0.0001$ ; KS Gait,  $r=-0.914$   $p=0.0001$ ; KS Urinary,  $r=-0.708$   $p=0.0001$ , KS Anal,  $r=-0.728$   $p=0.0001$ ), we decided to adopt the mMCS as a viable index of short-term outcomes (measured at discharge) and of long-term neurological outcomes (measured at the 12-month follow-up). We classified patients as improved, unchanged or impaired compared with their preoperative status. Intraoperative monitoring records were classified into groups according to the type of impairment: a) No impairment: normal activity values; b) Mild impairment: decrease in the IONM values to 50% of the initial levels; and c) Severe impairment: decrease in the IONM values to  $< 50\%$  of baseline.

Between-group comparisons were conducted by linear regression analysis and Student t-test, while ANOVA and Pearson correlation tests were applied for repeated measures, i.e., the three time points, preoperative, postoperative and long-term follow-up, to determine the influence of IONM on postoperative neurological status. Statistical significance was set at  $p<0.05$ .

## RESULTS

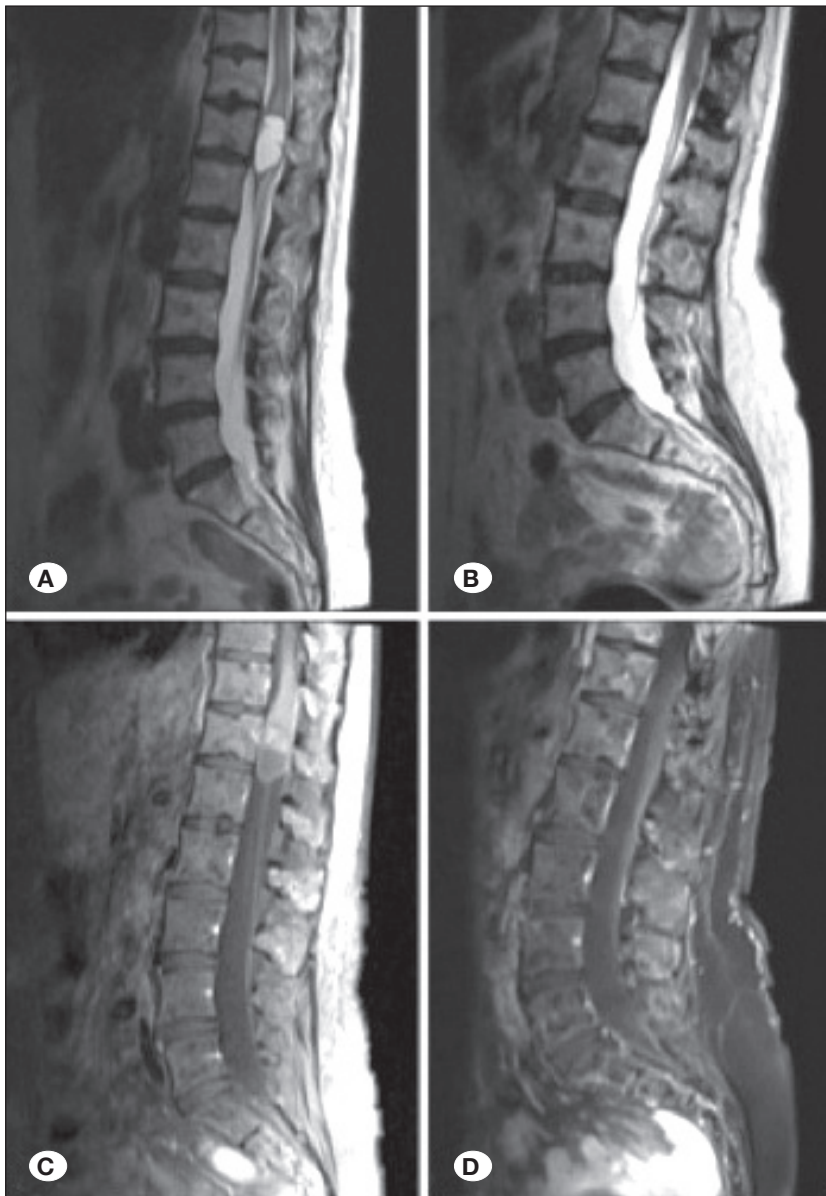
### Patient Characteristics

Among the 39 consecutive patients who underwent surgery for the removal of a WHO grade II intramedullary ependymoma, there were 25 male (64.1%) and 14 female (35.9%) subjects, with no differences in gender prevalence; the mean age at primary surgery was  $46.16 \pm 16.26$  years (range 19-75 years). Sixteen patients had cervical lesions (41%), 21 had thoracic lesions (54%) and 2 patients presented with lumbar involvement (5%); in 21 patients (53.85%), ependymomas were associated with a syrinx. The demographic and clinical features of the patients are summarized in Table I. The mean tumor volume was  $13.6 \text{ cm}^3 \pm 9.3$  ( $2.8\text{-}46.89 \text{ cm}^3$ ), and the mean follow-up time was 49.87 months, (SD 20.997; range 12-90 months). At hospital admission, the most common symptoms were

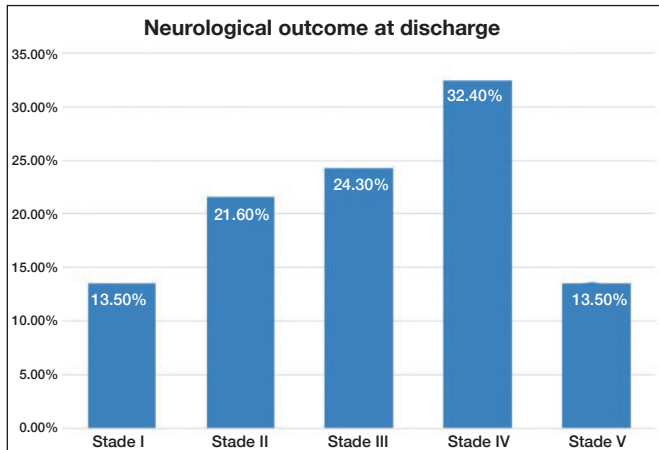
motor defects (41%; 16/39), tactile hypoesthesia (28.2%; 11/39), and pain in the lower limbs (30.8%; 12/39); 17 patients (43.6%) had complained of spinal symptoms for more than 1 year before surgery, and the mean duration of symptoms prior to the diagnosis was 13.74 months (range 1-48 months) (Table I). In terms of neurological status, 43.2% of patients were classified as grade IV or V based on the McCormick Scale (severe motor or sensory deficit, gait disturbance), while 56.8% were classified as grade I-II-III (Figure 3).

### Surgical Outcomes

The extent of removal was gross total removal in 35 patients (89.7%), subtotal removal in 3 patients (7.7%) and partial removal in 1 patient (2.6%). Adjuvant RT was administered in 2 cases including in 1 patient three months after surgery upon STR and in a second patient for the control of early



**Figure 2:** Preoperative and postoperative MRI with gadolinium: **A** and **B** show a grade II ependymoma at the level of T12 that was completely resected. **C** and **D** display a multilevel grade II ependymoma (T11-T12) without visible remnants on the postoperative MRI.



**Figure 3:** Bar graph showing the immediate postoperative neurological status at admission in the whole series. The modified McCormick Scale (Grades I-V) was used to assess ambulatory ability (I = normal ambulation; II = mild motor sensory deficit, independent without external aid; III = independent with external aid; IV = care required; and V = wheelchair required).

recurrence; no patient received adjuvant chemotherapy. Tumor progression was observed in 4 patients (10.3%) after 14.5 months (on average), and of these, 2 of the patients underwent a second operation. No independent predictive factor of GTR was identified (Table II).

At the 3-month follow-up, 8 patients (20.5%) exhibited improved neurological status after surgery, 22 patients (56.4%) remained unchanged, and 9 patients (23.1%) exhibited impairment and/or the occurrence of a newly developed neurological defect. At the 12-month follow-up, we found that the rate of improvement increased to 28.2% (11 patients); 20 patients (51.3%) remained stable, and a worse condition was observed in 8 patients (20.5%) (Figure 4). Among these patients, 1 patient presented with severe and prolonged intraoperative hypotension that was indicated as the cause of an early postoperative transient neurological deterioration; one patient with multilevel cervical ependymoma died 27 days after surgery because of severe spinal cord edema that resulted in cardio-respiratory arrest.

A multivariate analysis of different factors, i.e., age, sex, location of tumor, tumor volume, presence of syrinx, and extent of resection, showed that none of these factors can be considered negative predictors of the postoperative neurological status (see Table III). A regression analysis found that better neurological outcomes were measured in patients who underwent IONM ( $p=0.019$ ) and who had a lower preoperative mMCS score ( $p=0.029$ ).

### Surgical Outcomes and IONM

According to the use of intraoperative nerve monitoring (SSEPs, MEPs and D-wave), two different groups were considered and separately analyzed: the monitored group (17 patients) and the unmonitored group (22 patients).

It should be emphasized that the preoperative neurological status was significantly different between groups; in the group

**Table I:** Clinical Characteristics of 39 Grade II Spinal Ependymomas

Age group (months)	n	%
19-29	8	20.5
30-39	7	17.9
40-49	5	12.8
50-59	8	20.5
60-69	10	25.6
70-79	1	2.6
Gender	n	%
Male	25	64.1
Female	14	35.9
Duration of symptoms (months)	n	%
< 3	8	20.5
3 to 6	5	12.8
6 to 12	9	23.1
>12	17	43.6
mMCS at admission	n	%
I	4	10.3
II	10	25.6
III	9	23.1
IV	13	33.1
V	3	7.7
Location	n	%
Cervical	16	41
Thoracic	21	53.8
Lumbar	2	5.1
N° of affected levels	n	%
<3	26	66.7
>=3	13	33.3
EOR	n	%
GTR	35	89.7
STR	3	7.7
Reduction	1	2.6
IONM	n	%
Yes	17	43.6
No	22	56.4
Recurrence	n	%
Yes	5	12.8
No	33	84.6

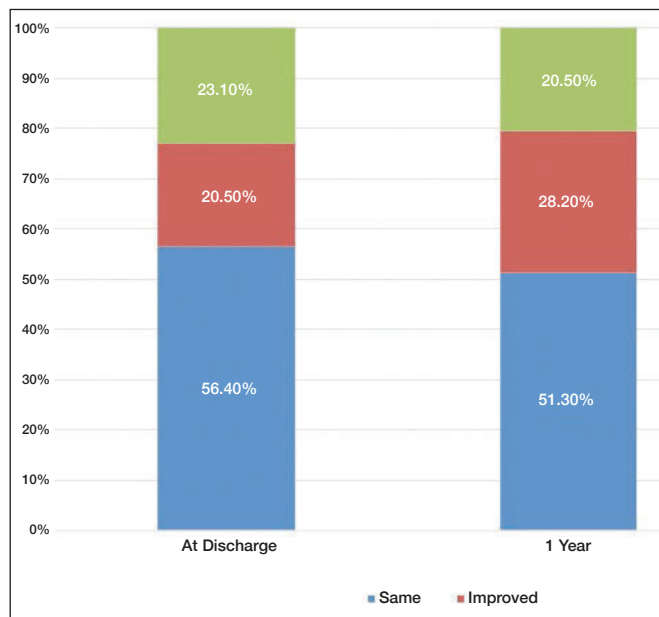
that underwent surgery with the aid of IONM, 76.5% were independent without severe motor or sensory deficits (mMCS I-II-III) compared with 45.5% in the group that did not receive IONM (p=0.026) (Table IV).

Regarding the modified McCormick grading at the 1-year follow-up, 88.2% of monitored patients improved or were unchanged, while a lesser number of patients in the unmonitored group improved or were unchanged (63.6%); this difference was statistically significant (p=0.021) (Figure 5).

Moreover, the rate of immediate postoperative impairment in the monitored group was initially 23.5% but was reduced to 11.8% at the 1-year follow up; this rate was inferior to the 36.4% observed in the group of patients who did not receive IONM during surgery, but this difference was not statistically significant (p=0.066). In terms of the extent of resection, no statistically significant difference was observed between the groups: 16 of 17 patients (94%) achieved GTR in the monitored group, while 85.7% achieved GTR in the unmonitored group.

**Table II:** Results of the Multivariate Regression Analysis Identifying Possible Factors Influencing the EOR

Factors	p
Age	0.374
Location	0.995
Tumor size	0.479
Preop McCormick	0.763
IONM	0.220



**Figure 4:** Bar graph showing early and 1-year postoperative neurological status of patients who underwent resection for intramedullary ependymoma. mMCS:-modified McCormick Scale neurological evaluation.

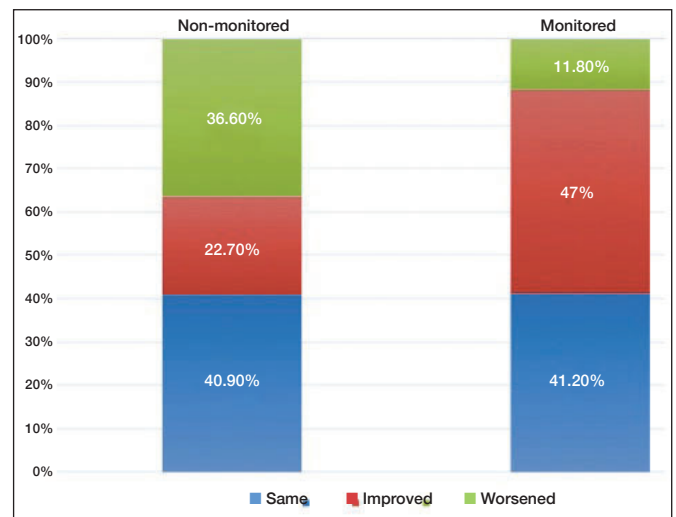
However, it should be noted that any temporary modifications during surgery, superior to 50% of basal amplitudes, were not strictly related to the onset of neurological sequelae (Table V). Actually, among the 3 monitored patients with a decline of more than 50% of the baseline values, we noted one case that did not present any modifications in postoperative neurological status, while surprisingly, 2 patients improved. In patients with a decrease in motor potential amplitude of less than 50% of the normal baseline values, only one experienced a worsening postoperative condition (Table V).

Finally, in the remaining 8 patients in whom IOM did not change during surgery (normal potentials), the postoperative mMCS score was improved in 5 cases and remained stable in 2.

Regarding the therapeutic effectiveness of IONM in our series, we observed 70.6% true negative responses, 11.8% false-negative and false-positive responses and 6% true positive responses, compared with the 1-year neurological outcome. Notably, in two patients, the decrease in IONM (false-positive) was restored after the administration of emergency maneuvers so that the true negative responses at the end of the tumor removal increased to 82.4%.

**DISCUSSION**

Grade II ependymomas are the most frequent intramedullary benign tumors, with an incidence of 55-75% among all lesions of the spinal cord. These tumors develop from ependymal cells lining the spinal cord and often exhibit cystic components with a slow-growth pattern. The tumor margins are round and well-defined so that a cleavage plane can be recognized during surgical resection. Indeed, accordingly, surgery represents the best treatment strategy and results in higher rates of gross total resection with limited morbidity (Figure 1). Pertinent literature has reported a significantly lower recurrence rate and



**Figure 5:** Bar graph showing the different clinical outcomes with and without the use of IONM. Clinical outcome was evaluated using a variation of the modified McCormick Scale at admission and at the 1-year follow-up.

better overall survival when GTR is accomplished compared with patients who achieve STR (overall survival: 79.3% in GTR vs 73.3% in STR; progression-free survival: more than 80% at 5 years if GTR is achieved) (9,23,26,31,39).

In these lesions, it should be taken into account that surgical management differs for intramedullary and extramedullary ependymomas (3,17,18,32); regarding intramedullary lesions, further considerations are needed to distinguish infiltrating tumors from those that are round and well-defined (19). Indeed, WHO grade II ependymomas are considered circumscribed lesions, as per their proper histological features.

Tremendous advancements in surgical techniques and surgeon experience in the field of intramedullary spinal lesion treatment (17), along with the adoption of the operating microscope and IONM, have contributed to the achievement of satisfactory results in terms of the extent of resection (EOR) in spinal surgery with lower morbidity rates.

Considering the above, it is not surprising that we observed a GTR rate of 89.7% in the present series, since this rate is slightly higher than that in the pertinent literature (15,17,23,40,47); this difference is mainly because larger series in the literature included all types of ependymomas, whereas we focused on grade II ependymomas. Oh et al. (40) analyzed the conspicuous number of 175 ependymomas and found a better rate of GTR in grade II (78.8%) rather than grade I (58.9%) lesions, and they also demonstrated that GTR represents a positive predictive factor for progression-free survival only in grade II ependymomas. Tarapore et al. (44) and Oh et al. (40), also analyzed the technical reasons that led to better results in the removal of intramedullary ependymomas; contrary to extramedullary tumors, usually no nerve roots are involved, and there is the possibility of identifying a cleavage plane so that the gentle manipulation of the lesion within the spinal parenchyma eases the resection, thus permitting *en bloc* removal. In a recent series that focused on intramedullary grade II/III ependymomas, the strategy of *en bloc* resection

**Table III:** Multivariate Linear Regression Analysis Evaluating Possible Preoperative Factors Affecting the McCormick Neurological Outcome

		mMCS improved	mMCS unchanged	mMCS deteriorated	p	Beta
Age	<40y	2 (25)	4 (50)	2 (25)	NS	0.134
	>40y	8 (25.8)	17 (54.8)	6 (19.4)		
Gender	Male	4 (16.4)	14 (56)	7 (28)	NS	-0.284
	Female	6 (42.9)	7 (50)	1 (7.1)		
Tumor volume	< 10 cm <sup>3</sup>	6 (30)	10 (50)	4 (20)	NS	0.046
	≥ 10 cm <sup>3</sup>	5 (26.3)	10 (52.63)	4 (21.1)		
Duration of symptoms	Motor	3 (18.8)	11 (68.8)	2 (12.5)	NS	0.161
	Sensory	2 (18.2)	5 (45.5)	4 (36.4)		
	Pain	5 (41.6)	5 (41.7)	2 (16.7)		
Location	Cervical	3 (18.7)	8 (50)	5 (31.3)	NS	-0.001
	Thoracic	6 (28.6)	12 (57.1)	3 (14.3)		
	Lumbar	1 (50)	1 (50)	0 (0)		
Syrinx	Yes	5 (23.8)	10 (47.6)	6 (28.6)	NS	0.038
	No	5 (27.8)	11 (61.1)	2 (11.1)		
IONM	Yes	8 (47.1)	7 (41.2)	2 (11.8)	<b>0.019</b>	-0.423
	No	2 (6.3)	14 (43.8)	6 (18.8)		
Preoperative mMCS	1	0 (0)	3 (75)	1 (25)	<b>0.029</b>	0.065
	2	5 (55.6)	2 (22.2)	2 (22.2)		
	3	4 (40)	3 (30)	3 (30)		
	4	8 (66.6)	3 (25)	1 (8.3)		
	5	0 (0)	3 (75)	1 (25)		

**mMCS:** Modified McCormick scale neurological evaluation.

**Table IV:** Comparison of Patient's Characteristics Relative to the Use of Intraoperative Monitoring (Monitored and Unmonitored)

	Monitored (17 patients)	Unmonitored (22 patients)	Fisher's exact test (p)
<b>Age</b>			NS
19-39	4 (23.5)	4 (18.2)	
40-79	13 (76.5)	18 (81.8)	
<b>Gender</b>			NS
Male	10 (58.8)	15 (68.2)	
Female	7 (41.2)	7 (31.8)	
<b>Location</b>			NS
Cervical	8 (47.1)	8 (36.4)	
Thoracic	9 (52.9)	12 (54.5)	
Lumbar	0 (0)	2 (9.1)	
<b>Size (cm<sup>3</sup>)</b>			NS
< 10	11(64.7)	9 (40.9)	
> 10	6 (35.3)	13 (59.1)	
<b>N°involved level</b>			<b>&lt; 0.05</b>
< 2	14 (82.3)	11 (50)	
> 3	3 (17.7)	11 (50)	
<b>EOR</b>			NS
GTR	16 (94.1)	19 (86.4)	
STR	1 (5.9)	3 (13.6)	
<b>Recurrence</b>			NS
Yes	1 (5.9)	4 (18.2)	
No	16 (94.1)	18 (81.8)	
<b>mMCS at admission</b>			<b>0.026</b>
Independent (grade I-II-III)	13 (76.5)	10 (45.5)	
Dependent or wheelchair (grade IV-V)	4 (23.5)	12 (54.5)	
<b>mMCS at 1 year</b>			<b>0.021</b>
Improved or unchanged	15 (88.2)	13 (63.6)	
Impaired	2 (11.8)	8 (36.4)	

**EOR:** Extent of resection, **GTR:** Gross total resection, **STR:** Subtotal resection, **mMCS:** modified McCormick scale neurological evaluation.

**Table V:** Comparison of Intraoperative Monitoring Findings and Clinical Outcome

	Monitored Group			Total	
	Normal	IONM Findings			
		<50%	>50%		
mMC at 1-year					
Improved	5 (50%)	3 (30%)	2 (20%)	10 (58.8%)	NS
Unchanged	2 (40%)	3 (60%)	0 (0%)	5 (29.4%)	
Impaired	1 (50%)	0 (0%)	1 (50%)	2 (11.8%)	



led to a GTR rate of 94,12% (43), which is very similar to the rate we achieved.

Klekamp claimed that better preoperative neurological status and a short duration of symptoms correlate with better postoperative outcomes (17). These data confirm the analysis of Aghakhani et al. (2), who described a series of 82 adults with intramedullary ependymomas and reported no new postoperative neurological defects, as they were asymptomatic prior to surgery. Our results did not reveal a correlation between a long duration of symptoms and a poor neurological outcome, as shown by the multivariate regression analysis, and we noted that the preoperative functional performance (mMCS and KSScore) was correlated with better outcomes. In our opinion, these results are not only related to tumor features and surgical technique but also related to spinal cord plasticity and adaptability phenomena. Indeed, the slow and progressive growth pattern of grade II ependymomas might favor those adaptations and recover capabilities along a wide duration of compression, thus preserving functional performance. Again, a good preoperative functional neurological status is of utmost importance compared with the time of onset of neurological symptoms for the purpose of good surgical results.

In this field of surgery, IONM has been widely adopted in recent years in order to ensure wider EOR, and above all, in an attempt to reduce the postoperative morbidity rates (7,14,21); several other publications revealed that IONM is an effective tool to predict the risk of postoperative neurological deterioration (8,38), especially in cases of intramedullary tumors.

In the present series, we had the opportunity to use IONM in 17 of 39 patients, and we recorded SSEPs, MEPs and D-waves in order to define the tumor resection strategy. The analysis of variance demonstrated the effectiveness of this tool in preventing postoperative neurological impairment ( $p=0.045$ ). However, the preoperative mMCS score was higher in the group of patients who underwent surgery with IONM; although this result could be considered to be due to bias, it provided further support in the attempt to preserve a better neurological functional status and to avoid any damage.

The D wave signal was taken into account upon reduction of the amplitude of its potentials during surgery according to the prognostic value of this tool. The combination of data from IONMs and D waves resulted in very useful information for the prediction of the postoperative neurological status. The correlation between good neurological outcomes and the absence of D wave changes during surgery in our series is clear and is in accordance with data present in the pertinent literature (12). Conversely, one patient who underwent D wave monitoring, despite no changes in its amplitude, had worse neurological outcomes.

The identification of a strong correlation between the intraoperative changes in amplitudes and the risk of late neurological sequelae is still a challenge. The risk of transient postoperative neurological decline has been reported to be between 20 and 60% (4,9,17,25), and we achieved a very similar result in the

present series (23.10%). Our data, as also reported in other publications (24,37), revealed that intraoperative variations in basal amplitude apparently do not lead to the onset of any postoperative neurological defects when the threshold signal warning has been set at 50% of the basal amplitude, according to the American Society of Neurophysiological Monitoring (ASNM). This observation is of utmost importance because, as reported by Kurokawa et al. (24), when the threshold was set to 50% of the basal amplitude, the rates of false-positive cases only increased slightly, whereas when the threshold was set to 20% of the basal amplitude, the sensitivity was enhanced.

Several other groups advocated for the suspension of the procedure upon a warning signal, but we preferred to accomplish rescue maneuvers; the temporary arrest of the surgical manipulations and further irrigation with saline solution of the surgical field, indeed can promote the removal of irritating products and metabolites. Then, the local application of papaverine and the increase in the mean arterial pressure are essential to facilitate local perfusion as per the restoration of blood flow. In the case of poor signal recovery, steroid bolus (methylprednisolone or dexamethasone) administration was considered; finally, upon evidence of neurophysiological improvement, we discontinued tumor resection. In these latter cases, although subtotal resection was achieved, we did not observe any risk of tumor progression and/or regrowth or significant differences in recurrence rates between GTR and/or STR patients.

In addition to being useful for guiding resection, we noted that the use of IONM helped to reduce unnecessary manipulation of the spinal cord; regardless of whether a decrease in amplitudes occurred, surgical maneuvers were suspended and retargeted. The temporary effect of retraction and dissection maneuvers should be mentioned as a possible cause of IONM alteration, as these maneuvers definitely alter MEP amplitude; if their effect is underestimated, additional postoperative neurological defects can occasionally develop. These observations were confirmed by our rates of EOR and neurological impairment at the 1-year follow-up (11.8%); additionally, in a large series of intramedullary tumors (16), although permanent morbidity rates were as high as 19.5%, it has been demonstrated that use of IONM does not reduce the rates of EOR.

## ■ CONCLUSION

Grade II ependymomas are mostly benign intramedullary tumors, and it is well known that total surgical resection is the best management strategy according to tumor features and the surgeons' experience in order to achieve a "maximum-allowed" resection and to limit postoperative morbidity. However, the role of total resection has not yet been thoroughly defined. Per the results of the present series, the use of IONM provided satisfactory EOR along with lower complication rates, which resulted in better neurological outcomes.

Further efforts are required to identify the most valid and reliable parameters that can guide surgery and predict

functional outcomes in patients who undergo surgery for ependymoma.

## ■ REFERENCES

1. Abdullah KG, Lubelski D, Miller J, Steinmetz MP, Shin JH, Krishnaney A, Mroz TE, Benzel EC: Progression free survival and functional outcome after surgical resection of intramedullary ependymomas. *J Clin Neurosci* 22:1933-1937, 2015
2. Aghakhani N, David P, Parker F, Lacroix C, Benoudiba F, Tadie M: Intramedullary spinal ependymomas: Analysis of a consecutive series of 82 adult cases with particular attention to patients with no preoperative neurological deficit. *Neurosurgery* 62:1279-1285; discussion 1285-1286, 2008
3. Borges LF: Spinal intramedullary ependymoma: Surgical approaches and outcome. *J Neurosurg Sci* 62:51-62, 2018
4. Boström A, von Lehe M, Hartmann W, Pietsch T, Feuss M, Boström JP, Schramm J, Simon M: Surgery for spinal cord ependymomas: Outcome and prognostic factors. *Neurosurgery* 68:302-308; discussion 309, 2011
5. Chamberlain MC, Tredway TL: Adult primary intradural spinal cord tumors: A review. *Curr Neurol Neurosci Rep* 11:320-328, 2011
6. Chang UK, Choe WJ, Chung SK, Chung CK, Kim HJ: Surgical outcome and prognostic factors of spinal intramedullary ependymomas in adults. *J Neurooncol* 57:133-139, 2002
7. Choi I, Hyun SJ, Kang JK, Rhim SC: Combined muscle motor and somatosensory evoked potentials for intramedullary spinal cord tumour surgery. *Yonsei Med J* 55:1063-1071, 2014
8. Fehlings MG, Brodke DS, Norvell DC, Dettori JR: The evidence for intraoperative neurophysiological monitoring in spine surgery: Does it make a difference? *Spine (Phila Pa 1976)* 35:S37-46, 2010
9. Garcés-Ambrossi GL, McGirt MJ, Mehta VA, Sciubba DM, Witham TF, Bydon A, Wolinsky JP, Jallo GI, Gokaslan ZL: Factors associated with progression-free survival and long-term neurological outcome after resection of intramedullary spinal cord tumors: Analysis of 101 consecutive cases. *J Neurosurg Spine* 11:591-599, 2009
10. Godfraind C: Classification and controversies in pathology of ependymomas. *Childs Nerv Syst* 25:1185-1193, 2009
11. Guan S, Shen R, Lafortune T, Tiao N, Houghton P, Yung WK, Koul D: Establishment and characterization of clinically relevant models of ependymoma: A true challenge for targeted therapy. *Neuro Oncol* 13:748-758, 2011
12. Hadley MN1, Shank CD1, Rozzelle CJ1, Walters BC1. Guidelines for the Use of Electrophysiological Monitoring for Surgery of the Human Spinal Column and Spinal Cord. *Neurosurgery*. 2017 Nov 1;81(5):713-732.
13. Harrop JS, Ganju A, Groff M, Bilsky M: Primary intramedullary tumors of the spinal cord. *Spine (Phila Pa 1976)* 34:S69-77, 2009
14. Hsu W, Bettgowda C, Jallo GI: Intramedullary spinal cord tumor surgery: Can we do it without intraoperative neurophysiological monitoring? *Childs Nerv Syst* 26:241-245, 2010
15. Karikari IO, Nimjee SM, Hodges TR, Cutrell E, Hughes BD, Powers CJ, Mehta AI, Hardin C, Bagley CA, Isaacs RE, Haglund MM, Friedman AH: Impact of tumor histology on resectability and neurological outcome in primary intramedullary spinal cord tumors: A single-center experience with 102 patients. *Neurosurgery* 76 Suppl 1:S4-13; discussion S13, 2015
16. Khalid SI, Adogwa O, Kelly R, Metha A, Bagley C, Cheng J, O'Toole J: Adult spinal ependymomas: An epidemiologic study. *World Neurosurg* 111:e53-e61, 2018
17. Klekamp J: Spinal ependymomas. Part 1: Intramedullary ependymomas. *Neurosurg Focus* 39:E6, 2015
18. Klekamp J: Spinal ependymomas. Part 2: Ependymomas of the filum terminale. *Neurosurg Focus* 39:E7, 2015
19. Klekamp J: Treatment of intramedullary tumors: Analysis of surgical morbidity and long-term results. *J Neurosurg Spine* 19:12-26, 2013
20. Klekamp J, Samii M: Intramedullary tumors. In: Klekamp J, Samii M (ed). *Surgery of Spinal Tumors*. Berlin, Heidelberg: Springer-Verlag, 2007:19-141
21. Korn A, Halevi D, Lidar Z, Biron T, Ekstein P, Constantini S: Intraoperative neurophysiological monitoring during resection of intradural extramedullary spinal cord tumors: Experience with 100 cases. *Acta Neurochir (Wien)* 157:819-830, 2015
22. Kothbauer KF: Intraoperative neurophysiologic monitoring for intramedullary spinal-cord tumor surgery. *Neurophysiol Clin* 37:407-414, 2007
23. Kucia EJ, Bambakidis NC, Chang SW, Spetzler RF: Surgical technique and outcomes in the treatment of spinal cord ependymomas, part 1: Intramedullary ependymomas. *Neurosurgery* 68:57-63; discussion 63, 2011
24. Kurokawa R, Kim P, Itoki K, Yamamoto S, Shingo T, Kawamoto T, Kawamoto S: False-positive and false-negative results of motor evoked potential monitoring during surgery for intramedullary spinal cord tumors. *Oper Neurosurg (Hagerstown)* 14:279-287, 2018
25. Lee SH, Chung CK, Kim CH, Yoon SH, Hyun SJ, Kim KJ, Kim ES, Eoh W, Kim HJ: Long-term outcomes of surgical resection with or without adjuvant radiation therapy for treatment of spinal ependymoma: A retrospective multicenter study by the Korea Spinal Oncology Research Group. *Neuro Oncol* 15:921-929, 2013
26. Li TY, Chu JS, Xu YL, Yang J, Wang J, Huang YH, Kwan AL, Wang GH: Surgical strategies and outcomes of spinal ependymomas of different lengths: Analysis of 210 patients: Clinical article. *J Neurosurg Spine* 21:249-259, 2014
27. Louis DN, Perry A, Reifenberger G, von Deimling A, Figarella-Branger D, Cavenee WK, Ohgaki H, Wiestler OD, Kleihues P, Ellison DW: The 2016 World Health Organization Classification of Tumors of the Central Nervous System: A summary. *Acta Neuropathol* 131:803-820, 2016
28. Macdonald DB: Intraoperative motor evoked potential monitoring: Overview and update. *J Clin Monit Comput* 20:347-377, 2006
29. MacDonald DB: Overview on criteria for MEP monitoring. *J Clin Neurophysiol* 34:4-11, 2017

30. Macdonald DB, Skinner S, Shils J, Yingling C; American Society of Neurophysiological Monitoring: Intraoperative motor evoked potential monitoring - a position statement by the American Society of Neurophysiological Monitoring. *Clin Neurophysiol* 124:2291-2316, 2013
31. Malis LI: Intramedullary spinal cord tumors. *Clin Neurosurg* 25:512-539, 1978
32. McCormick PC: Microsurgical resection of intramedullary spinal cord ependymoma. *Neurosurg Focus* 37 Suppl 2: Video 9, 2014
33. McCormick PC, Torres R, Post KD, Stein BM: Intramedullary ependymoma of the spinal cord. *J Neurosurg* 72:523-532, 1990
34. McGuire CS, Sainani KL, Fisher PG: Both location and age predict survival in ependymoma: A SEER study. *Pediatr Blood Cancer* 52:65-69, 2009
35. McGuire CS, Sainani KL, Fisher PG: Incidence patterns for ependymoma: A surveillance, epidemiology, and end results study. *J Neurosurg* 110:725-729, 2009
36. Morota N, Deletis V, Constantini S, Kofler M, Cohen H, Epstein FJ: The role of motor evoked potentials during surgery for intramedullary spinal cord tumors. *Neurosurgery* 41:1327-1336, 1997
37. Muramoto A, Imagama S, Ito Z, Ando K, Tauchi R, Matsumoto T, Nakashima H, Matsuyama Y, Ishiguro N: The cutoff amplitude of transcranial motor evoked potentials for transient postoperative motor deficits in intramedullary spinal cord tumor surgery. *Spine (Phila Pa 1976)* 39:E1086-1094, 2014
38. Nuwer MR, Emerson RG, Galloway G, Legatt AD, Lopez J, Minahan R, Yamada T, Goodin DS, Armon C, Chaudhry V, Gronseth GS, Harden CL, Medicine AAoNaE: Evidence-based guideline update: Intraoperative spinal monitoring with somatosensory and transcranial electrical motor evoked potentials. *J Clin Neurophysiol* 29:101-108, 2012
39. Oh MC, Kim JM, Kaur G, Safaee M, Sun MZ, Singh A, Aranda D, Molinaro AM, Parsa AT: Prognosis by tumor location in adults with spinal ependymomas. *J Neurosurg Spine* 18:226-235, 2013
40. Oh MC, Tarapore PE, Kim JM, Sun MZ, Safaee M, Kaur G, Aranda DM, Parsa AT: Spinal ependymomas: Benefits of extent of resection for different histological grades. *J Clin Neurosci* 20:1390-1397, 2013
41. Sala F, Bricolo A, Faccioli F, Lanteri P, Gerosa M: Surgery for intramedullary spinal cord tumors: The role of intraoperative (neurophysiological) monitoring. *Eur Spine J* 16 Suppl 2:S130-139, 2007
42. Scibilia A, Terranova C, Rizzo V, Raffa G, Morelli A, Esposito F, Mallamace R, Buda G, Conti A, Quartarone A, Germanò A: Intraoperative neurophysiological mapping and monitoring in spinal tumor surgery: Sirens or indispensable tools? *Neurosurg Focus* 41:E18, 2016
43. Sweeney KJ, Reynolds M, Farrell M, Bolger C: Gross total resection rates of grade II/III intramedullary ependymomas using the surgical strategy of en-bloc resection without intraoperative neurophysiological monitoring. *Br J Neurosurg* 31:364-368, 2017
44. Tarapore PE, Modera P, Naujokas A, Oh MC, Amin B, Tihan T, Parsa AT, Ames CP, Chou D, Mummaneni PV, Weinstein PR: Pathology of spinal ependymomas: An institutional experience over 25 years in 134 patients. *Neurosurgery* 73:247-255; discussion 255, 2013
45. Taskiran E, Brandmeier S, Ozek E, Sari R, Bolukbasi F, Elmaci I: Multimodal intraoperative neurophysiological monitoring in spinal cord surgery. *Turk Neurosurg* 27:436-440, 2017
46. Villano JL, Parker CK, Dolecek TA: Descriptive epidemiology of ependymal tumours in the United States. *Br J Cancer* 108:2367-2371, 2013
47. Wild F, Hartmann C, Heissler HE, Hong B, Krauss JK, Nakamura M: Surgical treatment of spinal ependymomas: Experience in 49 patients. *World Neurosurg* 111:e703-e709, 2018