

Review

Practical Aspects of Neuroendoscopic Techniques and Complication Avoidance: A Systematic Review

Yad Ram YADAV, Jitin BAJAJ, Vijay PARIHAR, Shailendra RATRE, Anurag PATERIYA

NSCB Medical College Jabalpur MP India, Neurosurgery, Jabalpur, India

ABSTRACT

Although endoscopic techniques have many advantages including improved visualization and magnification, they are also associated with limitations. The objective of this review is to discuss the practical aspects that can reduce complications after endoscopic procedures, and their management. The review is based on the personal experience of more than 2000 neuroendoscopic procedures performed by the senior author. Topic search was made on PubMed using Neuroendoscopy, complications and neuroendoscopy, complication avoidance and neuroendoscopy, endoscopic neurosurgery, and minimally invasive neurosurgery. Relevant articles were selected after analyzing abstracts and/or topics. Endoscopic procedures are also associated with limitations such as obstruction in instruments manipulation, steep learning curve, blind area, difficulty in visualization, disorientation, loss of stereoscopic image and others. Neuroendoscopy is distinct from microsurgery and the surgeon has to learn endoscopic skills in addition to microsurgical techniques. Difficulties in controlling bleeding, working in a limited area, higher complication rate during the initial learning curve and longer operative time are some of the limitations. Attending live workshops, practicing on models, and hands on cadaveric workshops can reduce the learning curve. Proper case selection, multidisciplinary team approach, watching operative video, visiting other departments, observing a skillful endoscopic surgeon, lab training, and simulators can improve results and shorten the learning curve. Limitations of this review are that the search is limited to the English literature and personal experience of a single surgeon that may create some bias. Although neuroendoscopic techniques are associated with improved results in some indications, they have many limitations. Neuroendoscopic skills need to be learned to improve results.

KEYWORDS: Complication, Endoscopic surgical procedure, Minimal invasive procedure, Neuroendoscopy, Training program

■ INTRODUCTION

Neuroendoscopy is being increasingly used in brain (37,41), spine (13,27) and skull base (9,12) pathologies in neurosurgery because of its improved visualization and better illumination. It has been used in wide variety of indications such as cranial cyst (33), hematoma evacuations (22,42), infective conditions (3,35), endoscopic third ventriculostomy (1,16), intraventricular lesions (18,19), rhinorrhea (21,25,40), craniopharyngioma (23), pituitary tumors (34,39), aneurysm surgery (2), vascular pathology (6), trigeminal neuralgia (11) and surgeries performed with the help of tubular retractor (38) etc. Although endoscopic techniques have many advantages, they are also associated

with limitations. Surgeon needs to acquire endoscopic skills to avoid complications (5,8,10,14,15,20,26). This article is aimed to discuss some practical aspects that can be used to reduce complications in endoscopic procedures, and their management.

■ METHOD

This review is based on personal experience of more than 2000 neuroendoscopic procedures performed by the senior author (Table I). Topic search on PubMed using search words “neuroendoscopy”, “complications and neuroendoscopy”, “complication avoidance in neuroendoscopy”, “endoscopic neurosurgery”, “minimally invasive neurosurgery” was done



Corresponding author: Yad Ram YADAV

E-mail: yadavyr@yahoo.co.in

and relevant articles were selected. Extensive search of 30 years was done of articles published in the English literature.

Relevant abstracts and/or topics, which discussed various complications and steps to avoid such complications in neuroendoscopy, were selected. The references for each article were also analyzed. We also manually searched the "related articles" feature of PubMed of the selected articles. Full texts of these selected articles were reviewed. Advantages and limitations of neuroendoscopic techniques were studied in detail and the steps to overcome such limitations were also recorded.

■ RESULTS

More than 1000 abstracts of articles were reviewed after the topic search (neuroendoscopy and complications, endoscopic neurosurgery and complications, complication avoidance and neuroendoscopy, also adding similar article or related articles, and manual search of cross references from full text article). A total of 42 articles were included in this study after detailed study of 87 relevant articles which were found to have discussion about limitations/complications of endoscopic procedures and the steps to overcome such limitations.

■ DISCUSSION

Camera, light source and image quality of the endoscopes needs to be checked before induction of anesthesia (26). Every single detail should be checked including side rod of table for holder attachment. If this is loose, there may be dangerous jerky movement of scope. All body parts should be in relaxed position with minimal muscle contractions. The back and neck should be straight, shoulder in the adducted position with the elbow in some flexion posture and the wrist in neutral position (29). The ulnar side should be well supported and a pen-type grip should be used. All instruments, such as sheaths, biopsy forceps, scissors, and graspers etc. should be inspected for proper functioning. Scissors or any other instrument opening should be smooth without any jerk.

All cables should be properly tied to avoid these wires to come in the way during surgery. Although small length of scopes is good for better control, a long scope should be used for working in a deep area to avoid obstruction in introduction and manipulation of instruments by the camera head, light cable shaft attachment, and scope holder arm. The camera should be placed in the correct position and proper orientation should be checked by anterior-posterior and side movement (26). The camera head (buttons) should be directed towards the monitor, which is placed opposite the surgeon, to view the image in the same way as seen in open surgery. The camera should not rotate during surgery; otherwise orientation will be disturbed.

Round shaft instruments are better than flat or rectangular shaft (29). The telescope can be damaged by the drill or by lifting it from near the lens tip (26). Scope damage can be avoided by removing the drill when it is completely stopped. One should protect the telescope by keeping it inside the sheath and holding it near the camera attachment, rather

than near the lens tip. Angled tip of instrument allows better visualization of its end during introduction and manipulation of the instrument (20,29).

Most of the procedure should be done under high magnification, which can be achieved by using the zoom button or going close to the desired structure. If the full area of interest is not visualized under high magnification, de-zooming or moving the scope away from the target area allows that object to be visualized properly.

The surgeon should be able to clearly visualize the operative corridor. He/she should adjust the height, by keeping a platform if needed, to avoid shoulder abduction for instrument manipulation. This maneuver also helps to visualize and introduce instruments in a blind area (area between skin and lens tip), especially when a scope holder is used. Site and size of the incision should be properly planned, as there is less flexibility in a small exposure (17,26). Second option of microscopic surgery, using the same incision, should be planned especially at the beginning of the learning curve and in difficult cases.

It is better to keep the tubular retractor or endoscopic sheath as vertical as possible, as angulation of this sheath invites surrounding structures to enter inside the tube, which may stain the lens tip or may interfere with proper visualization (30,36). It is therefore advisable to use two incisions to address two levels of spinal pathology rather than too much angulation using a single incision. A single larger incision for two-level pathologies can make the whole endoscopic assembly unstable and it does not help in hemostasis (a small but proper size incision helps in stopping bleeding by a tamponade effect).

There may be some limitations when an angled working channel is used in removing pathologies present in the opposite direction to the natural angulation of the channel. For example, if the working channel of the Destandau set is cranially directed, it is easy to remove compressive tissue in the cranial part of the field (Figure 1A), but it becomes difficult to excise caudal pathology. The whole assembly needs to be rotated 180° (Figure 1B) or the angulation of the working channel has to be corrected by caudal inclination of the assembly (Figure 1C). An angled tip instrument can be used effectively to address caudally lying pathology. Sometimes, more than two functions (suction, irrigation, drilling, grasping, cutting etc.) are required in a narrow operative field where it is difficult to introduce a third instrument. Two functions (such as grasping and cutting, or irrigation and suction, or drilling and irrigation, etc.) can be incorporated in one instrument.

Differences Between Endoscopy and Microsurgery Techniques

Although there is better illumination and visualization in endoscopic surgery, there are some limitations in endoscopic surgery compared to microscope (Table II). Straight instruments are preferred in endoscopic surgery for better instrument manipulation and rotation compared to bayonet shaped ones, which are usually better in microsurgery. Focus of the surgical field is usually kept in the center for surgery using the

microscope whereas it is preferred to keep the desired surgical field at the corner in endoscopy to prevent instrument obstruction by the scope (Figure 2A). In microscopic surgery, the whole operative corridor is available for instrument manipulation, whereas in endoscopic surgery one needs to sacrifice

some area to station the scope and therefore should create extra space (Figure 2B). 2D visualization is another limitation of endoscopic surgery. Other limitations of endoscopic surgery are blind area, change in orientation due to camera rotation, and difficulty in drilling, etc.

Straight Versus Triangular Arrangement

One can very well visualize the surgical target when there is no object between the scope and target tissue (Figure 3A). When the instrument, target and scope are in a straight line, the target object is not visualized (Figure 3B). Triangular arrangement (Figure 3C) (by moving scope or instrument to the side) allows good visualization of target tissue and the instrument (31). This situation may arise when both limbs of the biopsy or grasping forceps are in a straight line with the scope and the surgical target. The distal limb of the forceps and the surgical target are not visualized in such cases (Figure 4A). Rotation of the forceps (Figure 4B) can overcome this problem. The telescope can also be moved to the side to avoid a straight arrangement. Although an instrument passed through a working channel can reach the target area in some well-planned trajectory cases (Figure 4C), it is wise to rotate the whole assembly to the right, left or back side when the instrument is not able to get there or when targets are multiple (Figure 4D) rather than a linear movement, especially when the scope has passed through a narrow vital structure. Likewise, if the tissue is pulled towards the lens tip, its bed and distal part of tissue is not visualized and might contain adherent vessel or nerve (Figure 5A). On the other hand, if the structure

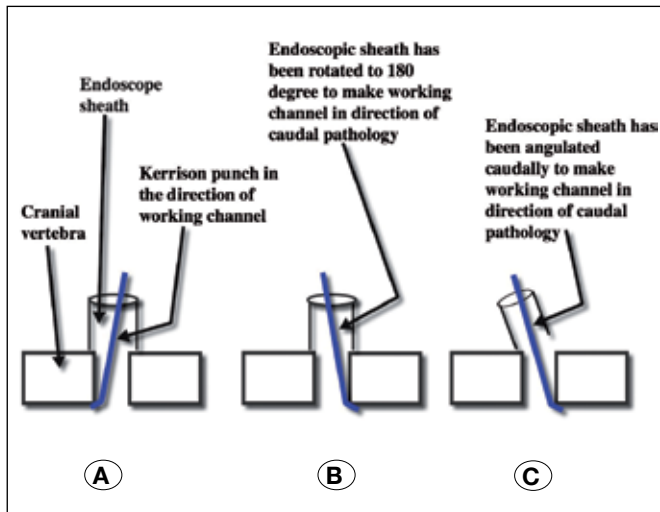


Figure 1: Cranial lying compressive tissue can be removed easily when the working channel is directed cranially (A). The whole assembly needs to be rotated 180° (B) or the working channel's cranial angulation should be corrected by caudal angulation (C) to remove a lesion lying in the caudal field.

Table I: Personal Experience of Neuroendoscopic Procedures Performed by Senior Author

Name of procedure	Numbers of patients
Cranium	
1. Endoscopic third ventriculostomy	558
2. Intraventricular bleed with obstructive hydrocephalus	92
3. Hypertensive bleed using tubular brain retractor	93
4. Deep seated intracranial tumors using tubular retractor	112
5. Brain abscess	67
6. Arachnoid cyst	38
7. Colloid cyst	87
8. Septum pellucidum perforation	14
9. Microvascular decompression of 5 th & 7 th nerve	191
10. Biopsy of posterior third ventricle	24
11. Pituitary adenoma	96
12. Trans-nasal approach for craniopharyngioma	49
13. Cerebrospinal fluid rhinorrhea	104
14. Others	12
Total	1537
Spine	
1. Lumbar spine including disc and canal stenosis	912
2. Anterior cervical for 1-2 level disc,	97
3. Posterior bilateral decompressions using unilateral approach for cervical lesions up to 6 levels	76
4. Basilar invasion / AAD	57
5. Intradural spinal tumor	21
6. Foramen magnum decompression in Arnold Chiari Malformation type 1	16
Total	1179

to be dissected is moved to the side (cranial, caudal, medial, lateral or away from the lens), the tissue to be dissected and its bed will be visualized nicely which can avoid injury to the structures lying in the bed. (Figure 5B)

Difficulty in Hand Support

Hand support during surgery improves precision and avoids fatigue (31). There may be difficulty for hand support in endoscopic surgery. Gentle hand support on the working channel, at the end of the light cable or any other surrounding surface is helpful to improve control (Figure 6A). An unsupported hand increases fatigue and tremor (Figure 6B).

Avoid Power Grip

Precision grip is better than power grip (Figure 7A). It allows hand support, helps in using small intrinsic muscles of the thumb and index finger and also helps in precise movement

(17,29,31). The instruments used in endoscopic surgery are usually long with a power grip design. Sometimes, instruments meant for delicate and fine work (fine scissors) are poorly designed with power grip. The disadvantages of power grip are no hand support, use of long muscles, and involvement of multiple joints, which results in less precision during surgery (Table III). If power grip is used in surgery (Figure 7B) due to poor instrument design or due to the required function, the pen type of precision grip should be added (Figure 7C) to improve accuracy (30,31).

Limited Space Available for Instrument Manipulation

There is usually limited space available for surgery in endoscopic techniques. Some area is occupied by the scope in an already limited space (24). Instrument manipulations may become difficult in this limited area (24). The side or tip of the scope could obstruct instrument manipulation. Use of a single

Table II: Differences Between Endoscopy and Microsurgery Techniques

Microscope	Endoscope
More space for instrument manipulation.	<ul style="list-style-type: none"> • Endoscope occupies some space, so less space for instrument manipulation. • Need to create extra space to station endoscope
3D visualization	2D visualization
Inferior illumination compared to telescope	Superior compared to microscope
Inferior visualization compared to telescope	Better visualization, Panoramic view, can look into the corners
Use of Bayonet shape instruments are preferred	Straight instruments are preferred
Surgical object is usually focused in center of field	It is better to keep area of interest in the corner
No blind area	Blind area
Orientation does not change	Orientation may change
Easy drilling	Difficulty in drilling
No obstruction	Scope may obstruct instrument manipulation

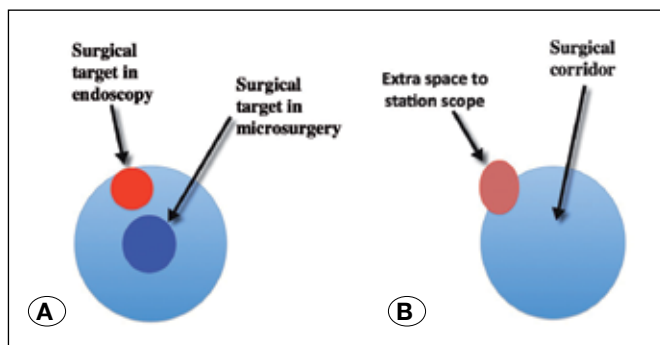


Figure 2: Focus of the surgical field is usually kept in the center for microscopic surgery whereas it is preferred to keep the desired surgical field in the corner in endoscopy to prevent instrument obstruction by scope (A). Some space is utilized by the scope in an already limited space in endoscopic surgery, so one needs to create extra space to station the scope (B).

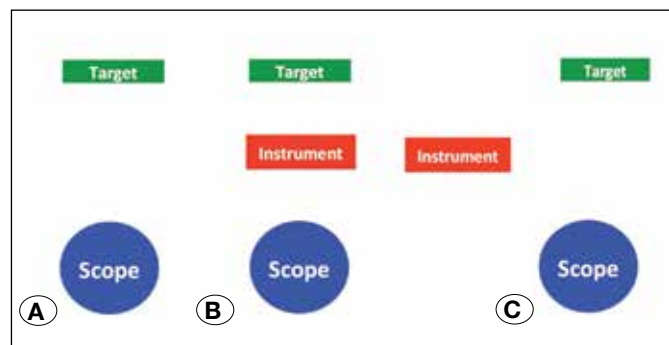


Figure 3: The surgical target can be very well visualized by the scope when there is no object between the scope and target tissue (A). Target tissue is not visualized when the scope, instrument, and target object are in a straight line (B). Triangular arrangement (by moving the scope or instrument to the side) allows good visualization of the target tissue and the instrument (C).

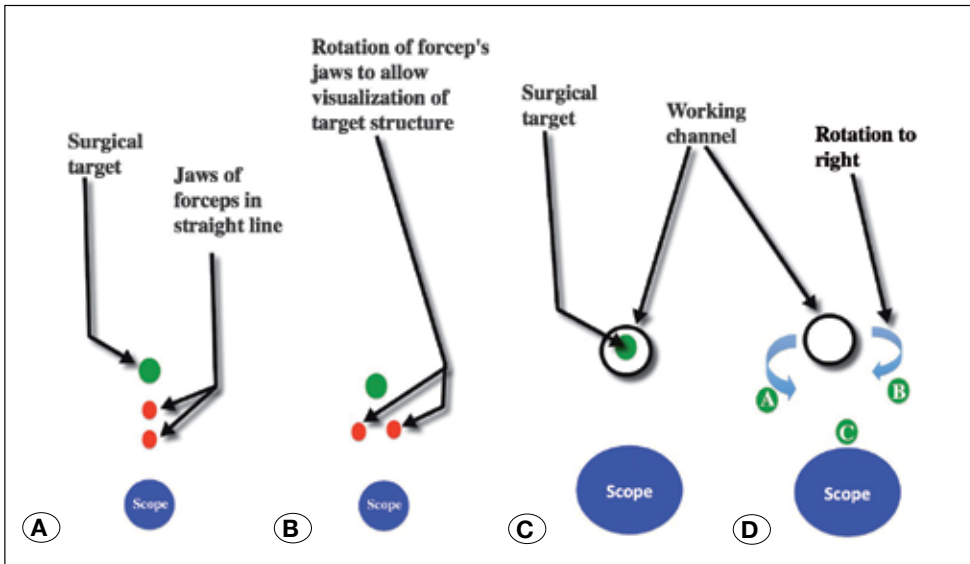


Figure 4: The distal limb of the forceps and target tissue are not visualized when both limbs of the forceps are in a straight line with the scope and the surgical target (A). Rotation of the forceps (B) or telescope can overcome this problem. Although an instrument can reach the target area in some well-planned trajectory cases (C), it is wise to rotate the whole assembly to the right, left or back side when the instrument is not able to reach the targeted structure or when targets are multiple (D).

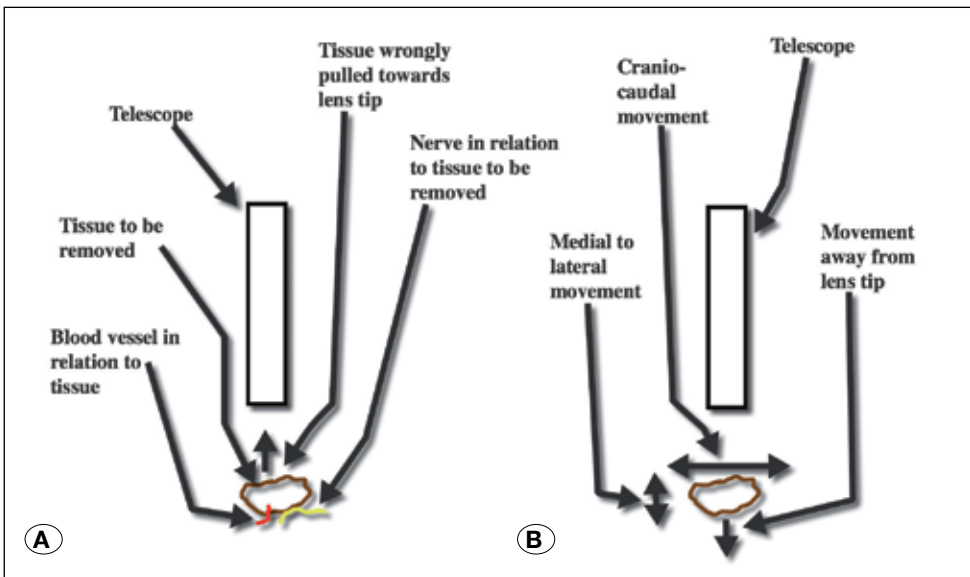


Figure 5: The deeper part of tissue and its bed are not visualized when it is pulled towards the lens tip (A). On the other hand, if the structure to be dissected is moved to the side (cranial, caudal, medial, lateral or away from lens), tissue, as well as its bed, can be visualized nicely (B).

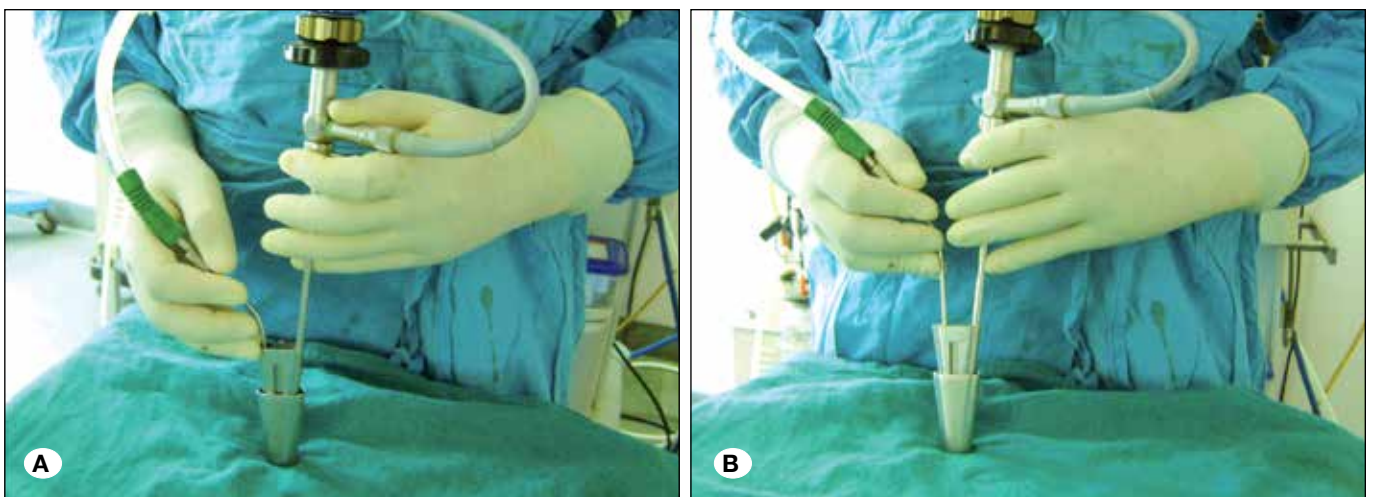


Figure 6: Gentle hand support on the working channel, or on any other surrounding surface is helpful to improve control (A). An unsupported hand increases fatigue and tremors (B).

shaft and slender instruments are preferred over double shaft and bulky instruments (17,26,29). Instrument manipulation may become difficult if the scope is near the target (Figure 8A). Although the telescope cannot be placed too far away from the required object due to its shorter focal length, it should be stationed as much away as possible (Figure 8B) to prevent obstruction of instrument manipulation (17). There should not be any sword fighting effect (scope is pointing in one direction and the instrument in the opposite direction). The scope and instrument should be angulated in the same direction for proper visualization of the surgical target and to avoid obstruction in instrument manipulation. Linear movement of the instrument is difficult in limited space; rotation could be helpful to achieve the goal (such as in endoscopic suturing). If introduction of the instrument is difficult even after keeping

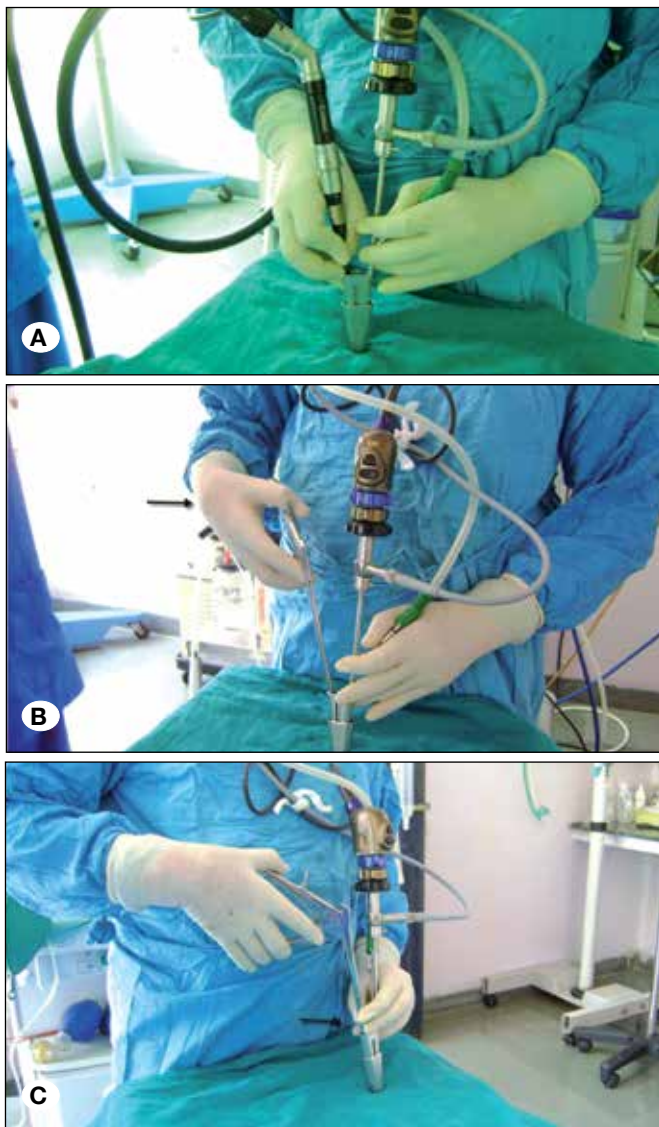


Figure 7: Precision grip is better than power grip (A). If power grip (arrow) is required in surgery (B) due to poor instrument design or due to required function, the pen type of precision grip (arrow) should be added (C).

the scope as much away as possible from the target tissue, and by stationing it at the corner, the instrument should be introduced first to the desired area and then the scope should follow and should be stationed in the available space. When straight instrument is unable to reach extreme corner of the target structure (Figure 8C), angled tip instruments help to get the desired area (Figure 8D).

Endoscopic Blind Spot

A blind area (Figure 9A) is a dangerous feature of the endoscopic technique (26). It is an inability to visualize the pathway between the skin and the endoscope tip (20). This may result in injury to tissue in the blind area if the scope is moved (28) or when the instrument is introduced by the side of the scope (Figure 9A). This can be prevented by removing the endoscope with each insertion of instrument and following the instrument into the field under direct endoscopic visualization (Figure 9B). Visualize the instrument directly with the naked eye in the blind area (Figure 9C) of the operative field (intermittently looking at the monitor and instrument tip) when the holder is used to engage the scope (24). Side movements should be avoided especially when the scope has passed through a narrow opening, and rotation can be used (Figure 4D) if the instrument is not reaching the desired area (31).

Lack of Bimanual Dissection

Although bimanual techniques are superior to one hand dissection, it is difficult in some situations in endoscopic surgery. The surgeon can do one-hand dissection only when he/she is holding the scope himself or when there is only one working channel in the endoscopic set (26). Control of bleeding, drilling, cutting, traction on tissue, dissection of tissue from other structures, etc. become difficult when the one-hand technique is used. Use of a telescope holder, an assistant holding the scope, and adding another working channel help in bimanual dissection in endoscopic surgery. The irrigation or suction channel can be utilized to pass flexible instruments that can be very helpful in the surgical procedure.

Causes of Poor Visualization and Steps to Overcome

Telescope out of focus, bone dust, drop of fluid, improper connection from the scope to the monitor, damaged scope lens, unwanted tissue in front of the telescope lens, blood or any turbid fluid when fluid media is used, excessive moisture content in the air medium, straight arrangement, scope in the wrong direction etc. (Table IV) may give rise to poor visualization (26,30). Adjusting the focus of the camera and suctioning of the air containing excessive moisture improves visualization. Unwanted tissue can be retracted or removed as needed to improve visualization of the target area. The telescope can be moved in the proper direction to overcome difficulty in target tissue visualization when unwanted tissue is in the way. When turbid fluid or blood in the fluid media is the cause of poor visualization, that fluid should be sucked with a catheter tip about 1 cm ahead of the scope lens tip (if the fluid is sucked with catheter in the working channel, it will suck turbid fluid towards the lens tip and will cause more blurring of vision). To properly view a tissue lying in the left corner of the surgical field, one needs to direct the scope towards the left side; if

Table III: Types of Surgical Grips

Precision grip	Power grip/Piston grip
Useful for fine work	Useful when power is required
Uses thumb, index and middle fingers as a tripod, with the ulnar border of hand, wrist, and the elbow well supported.	Uses multiple joint movements and long muscles of hand, wrist, elbow etc.
Fine movement and rotation are performed by thumb and index finger	Crude movement involving multiple joints and long muscles.
The intrinsic muscles perform accurate movement.	Long muscles are used with less precision
Tremor is minimized.	More physiological tremor
Hand support is present	No hand support

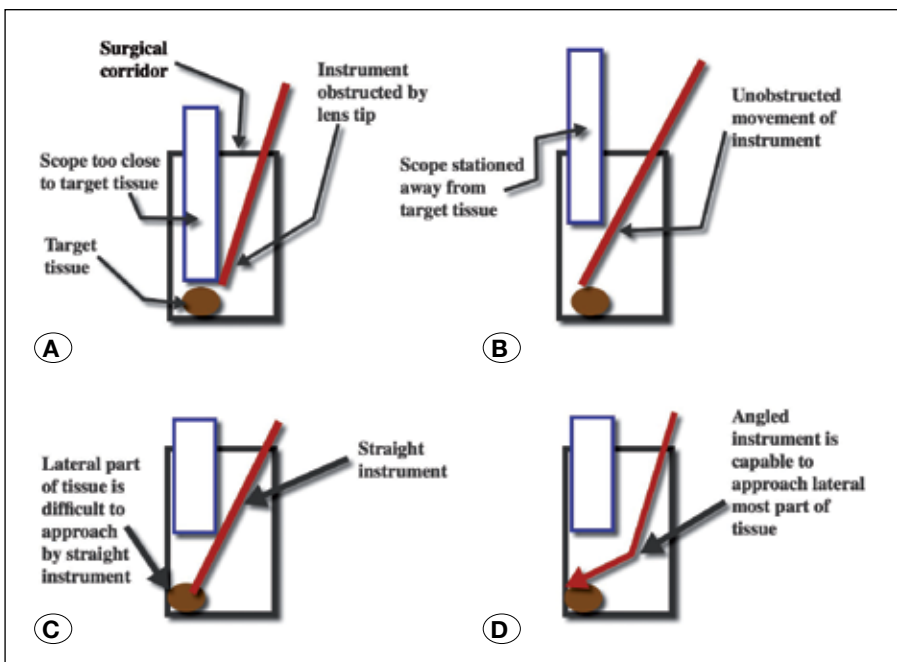


Figure 8: Instrument manipulation may become difficult if the scope is near the target (A). The telescope should be stationed as much away as possible to prevent obstruction in instrument manipulation (B). Angled tip instruments help in reaching the desired extreme corner of the target structure when a straight instrument fail to reach the site (C,D).

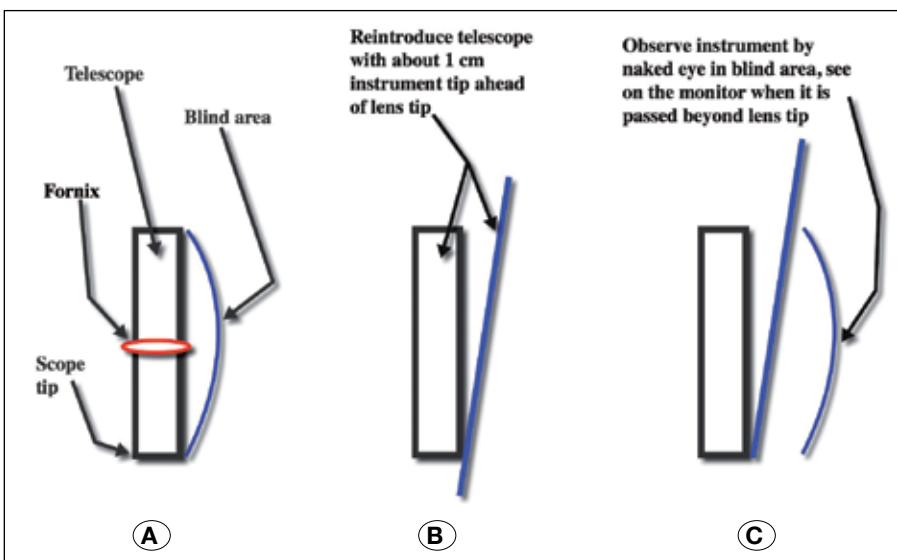


Figure 9: There could be injury to tissue in the blind area when the scope is moved or when instrument is introduced by the side of scope (A). This can be prevented by removing the endoscope with each insertion of the instrument and following the instrument into the field under direct endoscopic visualization (B), or by visualizing the instrument directly with the naked eye in the blind area (C).

Table IV: Causes of Some Limitations of Neuroendoscopy, and Steps to Avoid These Limitations

Causes of the limitations in Neuroendoscopy	Steps to avoid these limitations
<p>Poor visualization:</p> <ul style="list-style-type: none"> • Lens tip staining by blood, bone dust. • Drop of fluid, and brain tissue. • Improper connection from scope to the monitor. • Damaged lens. • Telescope out of focus. • Unwanted tissue in front of the telescope lens. • Blood or turbid fluid in front of lens tip: Suction of hemorrhagic or turbid fluid by catheter in working channel. • Excessive moisture content in the air medium. • Straight arrangement of lens, surgical object and instrument. • Scope is angulated to opposite direction to the object to be visualized 	<ul style="list-style-type: none"> • Anti-fogging agents, commercially available lens cleaner or manual irrigation by saline and suction. • Bone dust staining of lens can be avoided by keeping scope as much away as possible using comparatively larger size telescope and zooming facilities. • Intermittent irrigation in between the short period of drilling. • Proper connection from scope to monitor. • Proper focusing. • Remove or retract tissue coming between scope and target structure, or move scope. • Suction of turbid fluid with tip of catheter ahead of lens tip. • Suction of humid air. • Triangular arrangement. • Scope is angled in same direction towards the object.
<p>Difficulty in controlling of bleeding:</p> <ul style="list-style-type: none"> • Movement of scope and injury to structure in blind area. • Blood trickling from superficial area. • Injury to vessel. • Inflamed pathology. • Vascular lesion. • Difficulty in visualization of bleeding point especially when fluid media is used. 	<ul style="list-style-type: none"> • Control of bleeding by using tamponade effect on bleeding point using Fogarty catheter or instrument already in the field (resisted removal of instrument in field and bringing of cautery forceps) • Stay in field with scope and sheath and irrigate (most minor bleed stops after some time) • Keep sheath in place and can remove scope if its tip is soiled. • Dry field technique can be used if bleeding does not stop after about 10 minutes of irrigation (fluid should be carefully and slowly removed and replaced by equal amount of air. • Exoscope or microscope can be used if brisk bleeding is not controlled after irrigation, waiting for some time, and by using air media for visualization.
<p>Difficulties in instrument manipulation:</p> <ul style="list-style-type: none"> • Scope occupies some space. • Scope too close to the object in AP (depth) direction. • Scope in center of field. • Sword effect (scope and instrument going in opposite direction). • Bulky instruments. • When there is need to use more than two instruments (such as cutting in an oozing field). 	<ul style="list-style-type: none"> • Scope as much away as possible, zoom for better visualization. • Scope placement at margin. • Can use angled scope. • Scope should be angled in same direction of the area of interest. • Withdraw scope, take instrument to desired place and then move scope towards the object slowly. • Use slender instruments. • Two functions in single instrument.
<p>Endoscopic blind spot: It is a feature of inability to visualize the pathway between the skin and the endoscope tip.</p>	<ul style="list-style-type: none"> • Remove the endoscope with the insertion of each new instrument and follow instrument into the field under direct endoscopic visualization, • Visualize instrument directly by naked eye in blind area and not on the monitor, intermittently look at monitor and in endoscopic blind area. • Avoid side movement to prevent tissue injury in blind area especially when scope has passed through narrow opening.

Table IV: Cont.

Causes of the limitations in Neuroendoscopy	Steps to avoid these limitations
<p>Dural injury:</p> <ul style="list-style-type: none"> • More common in severe canal stenosis. • Large central or extruded disc. • Dealing with opposite side pathology. • Thin and adherent dura to bone. 	<ul style="list-style-type: none"> • Simple case selection initially. • Keep ligamentum flavum intact until all bony work is finished. • 45° Kerrison punch for cranial and 90° for caudal work when working channel has cranial angulation. • Partially retract Kerrison punch and hold proximal part of nibbled bone or soft ligament. • Hold bone or ligament under proper visualization using rotation technique when Kerrison punch is used. • Drill away from or parallel to dura. • Use dura guard, bone shaver. • Eggshell drilling technique. • Patties, Abgel, bone wax between bone and dura.
<p>Suturing:</p> <ul style="list-style-type: none"> • Limited space. • Deep field. • Difficulty in linear movement of needle holder and suturing needle. • Difficulty in making knot 	<ul style="list-style-type: none"> • Rotation movement of needle holder and needle rather than linear movement. • Loop can be made inside the field with the help of needle holder and suction tip. • Loop can be made outside, that loop can be brought inside the endoscopic view. • Special suturing instrument such as endosuturing instrument, or clip • First knot can be applied at the opposite end of suture.
<p>Steep learning curve: Transition from microscope to endoscope is difficult due to:</p> <ul style="list-style-type: none"> • Difficulties in controlling bleeding. • Blind area. • Unique endoscopic skills. • 2D images. • Limited space. • More operative time. 	<ul style="list-style-type: none"> • Simple to progressively more complex cases. • Multidisciplinary team approach. • Practice on models. • Cadaveric dissection. • Live operative workshop. • Watching operative video. • Visiting other departments. • Observing skillful endoscopic neurosurgeon. • Lab training. • Simulators.

the scope is angled to right side, that tissue will be poorly visualized. Anti-fogging agents, commercially available lens cleaner, manual cleaning of the lens tip or manual irrigation of the scope by saline and removal of a drop of fluid by suction can be used to clean the lens tip. Bone dust staining of the lens can be avoided by keeping the scope as much away as possible from the drilling area and by using zooming facilities (26,32). Intermittent irrigations in between the short period of drilling and keeping the suction tip near the drill help to prevent lens soiling in drilling.

Endoscopic Suturing

Suturing in a limited space in endoscopic surgery is difficult. A loop can be made inside the field with the help of a needle holder and suction tip. The loop can be made by rotating the needle holder (the needle holder tip should grab the suture), and the suction tip helps in making the loop. The loop can also be made outside, which can be grabbed by needle holder, which in turn can be brought inside the endoscopic view. Rotation of

the needle holder is better than any linear movement (anterior, posterior or side) due to the limited space. One can pre-place a knot at the end of the suture to make the first knot to avoid time wastage in producing a knot. Although a special suturing instrument such as the Covidien® endosuturing instrument is available, the present system is not suitable in neurosurgery because of its bulky nature.

Prevention of Dural Tear

Dural tear is not uncommon when there is severe canal stenosis in spine surgery. This is more common when dealing with opposite side compression in spinal surgery (32,36). There is also a predisposition when the dura is adherent to the cranial bone. Simple case selection in the initial learning curve, and keeping ligamentum flavum intact until all bony work is finished is useful in avoiding dural tear. Using a 45° Kerrison punch for cranial and 90° for caudal bone removal are helpful in preventing dural tear, especially when using a working channel angled cranially in spine surgery. It is preferred to

use a drill to remove bone by the eggshell technique and the thinned out part of the bone can be removed using a micro-instrument (32). Drilling parallel to or away from the dura, use of a dural guard or bone shaver, and placing Abgel® or bone wax between the bone and dura help to prevent dural injury.

If a Kerrison punch is used for the removal of bone, one should not remove nibbled bone in a single stroke, especially in severe stenosis. The surgeon needs to disconnect the part of the bone to be removed first, and then should partially retract the punch, hold that part and remove it. Bone or ligament ought to be removed under proper visualization using a rotation technique as compared to pulling it towards the lens tip so that the underlying dura can be properly observed. Removal of the opposite side disc or central part could be difficult and may risk dural injury. It is better to decompress the disc from the ipsilateral side, push the central prolapsed disc and opposite side fragment inside the disc with a 90°-angled instrument, and then take them out from the ipsilateral side.

Control of Bleeding

Achieving hemostasis during endoscopic technique is a challenge especially inside fluid media. Small amounts of blood can obscure visualization, making subsequent surgery difficult. There is a general tendency to bring in cautery forceps to control bleeding which should be resisted in such a situation. Visualization of the bleeding vessel becomes very difficult by the time the cautery forceps is introduced (31). It is better to use the tamponade effect of the instrument already in the endoscopic field, such as re-inflating of a Fogarty catheter, or gentle pressure of the ventriculostomy forceps on the bleeding point (37).

It is not wise to remove the scope from area of bleeding. It may be slightly retracted and placed in the larger cavity. For example if the scope is in the third ventricle, it can be withdrawn into the lateral ventricle. It is better to stay in the field and irrigate (37). The scope can be removed if lens tip is soiled, and can be reintroduced after cleaning but the sheath should be in place. Minor bleeding usually stops after some time. If bleeding does not stop after about 10 minutes of irrigation, a dry field technique can be used. Visualization of the bleeding point is better in air media as compared to fluid media. Fluids should be carefully and slowly removed and replaced by an equal amount of air (37). If the bleeding is brisk in endoscopic surgery, the scope can be removed and hemostasis can be achieved using a microscope or exoscope especially when a tubular retractor is used (30).

Learning Curve

There is a steep learning curve in endoscopy (24,26). Transition from microscope to endoscope is difficult. The surgeon needs to acquire special techniques which are unique for endoscopy. Obstacles in learning endoscopic surgery are difficulties in the control of bleeding, problems associated with the blind area, 2D visualization, difficulty in instrument manipulation in a limited space, more operative time etc. The learning curve can be improved by proper case selection (4), using a multidisciplinary team approach, practice on models,

cadaveric dissection, attending live operative workshops, using Lab training and simulators, etc. (29,31). Training of endoscopic surgery using cadaveric dissection is limited because of shortage of cadavers. There may be insufficient clinical case volume or opportunity in routine operative hours for young neurosurgeons to learn endoscopy (29). Models and simulators can be used for training, but unfortunately these are also costly. Indigenously made inexpensive models can be used for learning endoscopic skills such as hand eye coordination, dissection, cutting, and suturing in limited space (31). Working in a deep operative field and in limited area along with acquiring hemostasis skills can be learnt on models. Papaya, capsicum, surgical gloves, silastic tubes, ice-cream stick for lamina simulation, low-cost commercially available camera and LED light source etc. can be utilized for skill training. Such models can be kept in the surgeon's chamber to practice endoscopy. A 0° and 30° view can be obtained by tilting the camera (7).

Limitations of Study

Search included in this article is from the English literature and personal experience of a single surgeon, which may create some personal bias.

CONCLUSION

Although neuroendoscopy techniques are associated with improved results in many neurosurgical diseases, they have many limitations. Neuroendoscopic skills need to be learned to improve results. Attending live workshops, practice on models, and hands on cadaveric workshops can reduce the learning curve. Proper case selection of comparatively simple procedures in the beginning, a multidisciplinary team approach, watching operative videos, visiting other departments, observing a skillful endoscopic surgeon, Lab training, and simulators can shorten the learning curve.

REFERENCES

1. Azab W, Al-Sheikh T, Yahia A: Preoperative endoscopic third ventriculostomy in children with posterior fossa tumors: An institution experience. *Turk Neurosurg* 23:359-365, 2013
2. Ceylan S, Anik I, Koc K, Ciftci E, Cabuk B: Endoscopic approach to cavernous sinus aneurysm. *Turk Neurosurg* 23: 404-406, 2013
3. Chen G, Xiao Q, Zheng J, Wu J, Ao Q, Liu Y: Endoscopic transaqueductal removal of fourth ventricular neurocysticercosis: Report of three cases. *Turk Neurosurg* 25:488-492, 2015
4. Chibbaro S, Di Rocco F, Makiese O, Reiss A, Poczos P, Mirone G, Servadei F, George B, Crafa P, Polivka M, Romano A: Neuroendoscopic management of posterior third ventricle and pineal region tumors: Technique, limitation, and possible complication avoidance. *Neurosurg Rev* 35:331-338; discussion 338-340, 2012
5. Chowdhry SA, Cohen AR: Intraventricular neuroendoscopy: Complication avoidance and management. *World Neurosurg* 79(2 Suppl): S15.e1-10, 2013

6. Chowdhury FH, Haque MR, Kawsar KA, Ara S, Mohammad QD, Sarker MH, Goel AH: Endoscopic endonasal transsphenoidal exposure of circle of Willis (CW); Can it be applied in vascular neurosurgery in the near future? A cadaveric study of 26 cases. *Turk Neurosurg* 22:68-76, 2012
7. Espinoza DL, González Carranza V, Chico-Ponce de León F, Martínez AM: PsT1: A low-cost optical simulator for psychomotor skills training in neuroendoscopy. *World Neurosurg* 83: 1074-1079, 2015
8. Horowitz PM, DiNapoli V, Su SY, Raza SM: Complication avoidance in endoscopic skull base surgery. *Otolaryngol Clin North Am* 49: 227-235, 2016
9. Iacoangeli M, Rienzo AD, Colasanti R, Scarpelli M, Gladi M, Alvaro L, Nocchi N, Scerrati M: A rare case of chordoma and craniopharyngioma treated by an endoscopic endonasal, transtubercular transclival approach. *Turk Neurosurg* 24:86-89, 2014
10. Kawsar KA, Haque MR, Chowdhury FH: Avoidance and management of perioperative complications of endoscopic third ventriculostomy: The Dhaka experience. *J Neurosurg* 123:1414-1419, 2015
11. Kher Y, Yadav N, Yadav YR, Parihar V, Ratre S, Bajaj J: Endoscopic vascular decompression in trigeminal neuralgia. *Turk Neurosurg* 27(6):998-1006, 2017
12. Komatsu F, Atsumi H, Osakabe M, Matsumae M: Extended endoscopic endonasal surgery using three-dimensional endoscopy in the intra-operative MRI suite for supra-diaphragmatic ectopic pituitary adenoma. *Turk Neurosurg* 25:503-507, 2015
13. Li Y, Wang B, Lv G, Xiong G, Liu W: Video-assisted thoracoscopic surgery for migration of a Kirschner wire in the spinal canal: A case report and literature review. *Turk Neurosurg* 23:803-806, 2013
14. Liu JK, Hattar E, Eloy JA: Endoscopic endonasal approach for olfactory groove meningiomas: Operative technique and nuances. *Neurosurg Clin N Am* 26: 377-388, 2015
15. Navarro R, Gil-Parra R, Reitman AJ, Olavarria G, Grant JA, Tomita T: Endoscopic third ventriculostomy in children: Early and late complications and their avoidance. *Childs Nerv Syst* 22: 506-513, 2006
16. Ozdamar D, Etus V, Ceylan S, Solak M, Toker K: Anaesthetic considerations and perioperative features of endoscopic third ventriculostomy in infants: Analysis of 57 cases. *Turk Neurosurg* 22:148-155, 2012
17. Ratre S, Yadav YR, Parihar V, Kher Y: Micro-endoscopic removal of deep-seated brain tumors using tubular retraction system. *J Neurol Surg A Cent Eur Neurosurg* 77:312-320, 2016
18. Setty P, Volkov A, Richards B, Barrett R: Minimally invasive treatment of biventricular hydrocephalus caused by a giant basilar apex aneurysm via a staged combination of endoscopy and endovascular embolization: A case report. *Turk Neurosurg* 25:344-349, 2015
19. Sharifi G, Alavi E, Rezaee O, Jahanbakhshi A, Faramarzi F: Neuroendoscopic foraminoplasty for bilateral idiopathic occlusion of foramina of Monro. *Turk Neurosurg* 22:265-268, 2012
20. Sughrue ME, Mills SA, Young RL 2nd: Complication avoidance in minimally invasive neurosurgery. *Neurosurg Clin N Am* 21: 699-702, 2010
21. Xuejian W, Fan H, Xiaobiao Z, Yong Y, Ye G, Tao X, Junqi G: Endonasal endoscopic skull base multilayer reconstruction surgery with nasal pedicled mucosal flap to manage high flow CSF leakage. *Turk Neurosurg* 23:439-445, 2013
22. Yadav YR, Mukerji G, Shenoy R, Basoor A, Jain G, Nelson A: Endoscopic management of hypertensive intraventricular haemorrhage with obstructive hydrocephalus. *BMC Neurol* 7:1, 2007
23. Yadav YR, Nishtha Y, Vijay P, Shailendra R, Yatin K: Endoscopic endonasal transsphenoid management of craniopharyngiomas. *Asian J Neurosurg* 10:10-16, 2015
24. Yadav YR, Parihar V, Agarwal M, Sherekar S, Bhatele PR: Endoscopic vascular decompression of the trigeminal nerve. *Minim Invasive Neurosurg* 54: 110-114, 2011
25. Yadav YR, Parihar V, Janakiram N, Pande S, Bajaj J, Namdev H: Endoscopic management of cerebrospinal fluid rhinorrhea. *Asian J Neurosurg* 11:183-193, 2016
26. Yadav YR, Parihar V, Kher Y: Complication avoidance and its management in endoscopic neurosurgery. *Neurol India* 61: 217-225, 2013
27. Yadav YR, Parihar V, Namdev H, Agarwal M, Bhatele PR: Endoscopic inter laminar management of lumbar disc disease. *J Neurol Surg A Cent Eur Neurosurg* 74: 77-81, 2013
28. Yadav YR, Parihar V, Pande S, Namdev H, Agarwal M: Endoscopic third ventriculostomy. *J Neurosci Rural Pract* 3: 163-173, 2012
29. Yadav YR, Parihar V, Ratre S, Iqbal M: Microneurosurgical skills training. *J Neurol Surg A Cent Eur Neurosurg* 77:146-154, 2016
30. Yadav YR, Parihar V, Ratre S, Kher Y: Endoscopic anterior decompression in cervical disc disease. *Neurol India* 62:417-422, 2014
31. Yadav YR, Parihar V, Ratre S, Kher Y: Avoiding complications in endoscopic third ventriculostomy. *J Neurol Surg A Cent Eur Neurosurg* 76: 483-494, 2015
32. Yadav YR, Parihar V, Ratre S, Kher Y, Bhatele PR: Endoscopic decompression of cervical spondylotic myelopathy using posterior approach. *Neurol India* 62: 640-645, 2014
33. Yadav YR, Parihar Vijay, Sinha M, Jain N: Endoscopic treatment of suprasellar arachnoid cyst. *Neurol India* 58:280-282, 2010
34. Yadav YR, Sachdev S, Parihar V, Namdev H, Bhatele PR: Endoscopic endonasal trans-sphenoid surgery of pituitary adenoma. *J Neurosci Rural Pract* 3: 328-337, 2012
35. Yadav YR, Sinha M, Parihar V: Endoscopic management of brain abscesses. *Neurol India* 56: 13-16, 2008
36. Yadav YR, Yadav N, Parihar V, Kher Y, Ratre S: Endoscopic posterior decompression of lumbar canal stenosis. *Indian J Neurosurg* 2: 124-130, 2013
37. Yadav Y R, Yadav S, Sherekar S, Parihar V: A new minimally invasive tubular brain retractor system for surgery of deep brain lesions. *Neurol India* 59:74-77, 2011

38. Yadav Y R, Yadav N, Parihar V, Kher Y, Ratre S: Management of colloid cyst of third ventricle. *Turk Neurosurg* 25:362-371, 2015
39. Yildirim AE, Dursun E, Ozdol C, Divanlioglu D, Nacar OA, Koyun OK, Ilmaz AE, Belen AD: Using an autologous fibrin sealant in the preventing of cerebrospinal fluid leak with large skull base defect following endoscopic endonasal transsphenoidal surgery. *Turk Neurosurg* 23:736-741, 2013
40. Yildirim AE, Sahinoglu M, Divanlioglu D, Alagoz F, Gurcay AG, Daglioglu E, Okay HO, Belen AD: Endoscopic endonasal transsphenoidal treatment for acromegaly: 2010 consensus criteria for remission and predictors of outcomes. *Turk Neurosurg* 24:906-912, 2014
41. Zhou QJ, Liu B, Geng DJ, Fu Q, Cheng XJ, Kadeer K, Du GJ, Wang YX, Luan XP: Microsurgery with or without neuroendoscopy in petroclival meningiomas. *Turk Neurosurg* 25:231-238, 2015
42. Zhu H, Wang Z, Shi W: Keyhole endoscopic hematoma evacuation in patients. *Turk Neurosurg* 22:294-299, 2012