

Case Report

Spinal Intradural Primary Malignant Peripheral Nerve Sheath Tumor with Leptomeningeal Seeding: Case Report and Literature Review

Humain BAHARVAHDAT¹, Babak GANJEIFAR¹, Nema Mohamadian ROSHAN², Aslan BARADARAN³

¹Division of Neurological Surgery, Ghaem Hospital, Mashhad University of Medical Sciences, Iran

²Division of Pathology, Ghaem Hospital, Mashhad University of Medical Sciences, Iran

³Orthopedic Research Center, Ghaem Hospital, Mashhad University of Medical Sciences, Iran

ABSTRACT

Spinal intradural primary malignant peripheral nerve sheath tumors (MPNST) are rare in patients without neurofibromatosis. Here we represent a 3-year-old girl of primary intradural spinal malignant peripheral nerve sheath tumor. The tumor was removed partially and MPNST was diagnosed in the histopathological examination. Her condition deteriorated due to acute hydrocephalus in the following days.

In this article, we discuss the clinical presentation, imaging, treatment, and prognosis of our patient and the other 22 patients of primary intradural MPNST, found in the literature. The Kaplan–Meier method was applied for univariate analysis and Cox proportional hazards model for multivariate analysis. This analysis showed that age, was an important factor predicting short-term survival of patients with MPNST.

KEYWORDS: Malignant peripheral nerve sheath tumor, Spinal intradural tumor, Hydrocephalus

ABBREVIATIONS: **MPNST:** Malignant peripheral nerve sheath tumor, **NF-1:** Neurofibromatosis type 1, **MRI:** Magnetic resonance imaging, **T1WI:** T1-weighted image, **T2WI:** T2-weighted image, **CT:** Computed tomography, **ICU:** Intensive care unit.

INTRODUCTION

Malignant peripheral nerve sheath tumor (MPNST) is a sarcoma arising from Schwann cells and neural crest cells (20). They constitute 5% of all soft tissue sarcomas with the incidence of 0.001% (10), and a peak incidence in the seventh decade of life (11); occurring more in patients with neurofibromatosis I (NF-1) (13). MPNSTs are usually located in extremities, trunk, and head and neck regions in order of decreasing frequency (19). Primary spinal intradural MPNSTs are extremely rare (1,17,22,23), with frequent association with NF-1 (9).

Here, we presented an exceedingly rare case of MPNST diagnosed in a 3-year-old girl, with intradural extra-medullary

involvement of the cervical spinal cord and diffuse leptomeningeal metastasis. We also reviewed the literature to discuss the management strategies and prognosis of primary spinal MPNST. We performed the systematic search by two researchers independently conducting the initial identification, and abstract screening. The eligible studies were discussed and the disagreements were resolved by means of discussion. The search was conducted on March 2015 in MedLine and EMBASE databases. For primary identification of articles, we searched the phrase “[(malignant) AND (peripher*) AND (nerv*) AND (tumor)]” setting no limitations, and if the abstract was not available, full text of article was used for screening evaluation. We assessed all studies regarding “the malignant peripheral nervous sheath tumors” located or involving the spinal canal.



Corresponding author: Aslan BARADARAN

E-mail: Aslan.Baradaran@gmail.com

We included only studies with survival description of the patients. We reviewed all eligible cases for their clinical characteristics, management approaches. We excluded neurofibromatosis patients, and articles that the required data could not be extracted from the published or raw data asked from the corresponding author. Duplicate studies were discarded and only the most recent studies of each group were included. Survival curves were calculated by the Kaplan-Meier method and statistical differences were determined by the log-rank test. P values less than 0.05 are considered significant. No corrections for multiple testing are considered. Analyses have been performed using SPSS software (version 16.0).

■ CASE REPORT

A 3-year-old girl was admitted to our hospital in September 2013, complaining of being unable to walk and talking. She had a history of severe low-back pain, gait disturbance, and progressive quadriparesis for one month. She had no past medical history or family history for any neoplastic diseases or neurofibromatosis. There were no superficial stigmata of neurofibromatosis. Motor deficit was noted in upper extremities with grades 2/5 for both shoulders and elbows, and with grade 0/5 for both hands. She had spastic paraplegia.

Magnetic resonance imaging (MRI) revealed an intradural extra-intramedullary lesion in the cervical spinal canal from C1 to T1, which was isointense on T1-weighted image (T1WI), and heterogeneously hyperintense on T2-weighted image (T2WI) (Figure 1). The lesion was enhanced nonhomogeneously in MRI. Also there were multiple intradural extramedullary lesions in dorsal and lumbar parts of the spinal cord. They were mostly hypointense to cord in T2WI and isointense in T1WI (Figure 1). These lesions were enhanced homogeneously. Pathologic thickening and leptomeningeal enhancement were noted along the spinal canal. Computed tomography (CT) scans of the chest, abdomen, and pelvic showed no abnormalities. The brain MRI was performed, revealing three small enhancing lesions in brainstem and temporal lobe.

Following laminectomy from C1 to C6, a longitudinal incision was made on the center of the exposed dura mater. A dark-red large mass lesion was noted from C1 to C7 that invaded the spinal cord leading to its enlargement. The mass lesion also involved C2-C3 spinal roots. The extra-medullary part was first decompressed. Then the spinal cord was cut in posterior midline aspect for removing the intra-medullary part of tumor. Only partial excision was performed due to severe invasion of the spinal cord.

Microscopic examination showed varied cellularity with diffuse spindle cell proliferation and extensive necrosis. Proliferation of neoplastic cells with pleomorphic and hyperchromatic round to spindle cell nuclei was seen (Figures 2, 3). On immunohistological examinations: malignant cells expressed vimentin, S-100 protein and CD99, but not glial fibrillary acidic protein, epithelial membrane antigen, human melanin antigen 45, or synaptophysin. Histopathological diagnosis was compatible with malignant nerve sheath tumor.

After surgery, the patient was admitted to the neurosurgical intensive care unit (ICU) with worsening of her right hand deficit. The genomic test for NF1 mutation came as negative. The patient had an uneventful period until day 9 when she experienced loss of consciousness with both nonreactive mydriasis. Axial brain CT scan revealed severe hydrocephalus due to obstruction in the lower brain stem region (Figure 4). Despite insertion of external ventricular drainage and aggressive medical treatment she did not improve and died.

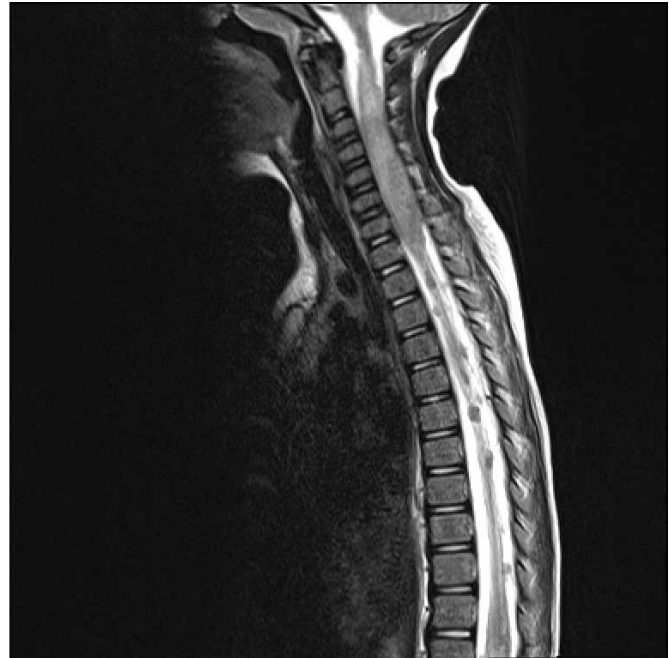

Figure 1: Magnetic resonance imaging (MRI) revealed an intradural extra-intramedullary lesion in the cervical spinal canal from C1 to T1, heterogenous on T2-weighted image (T2WI) and associated with multiple intradural extramedullary drop metastases.

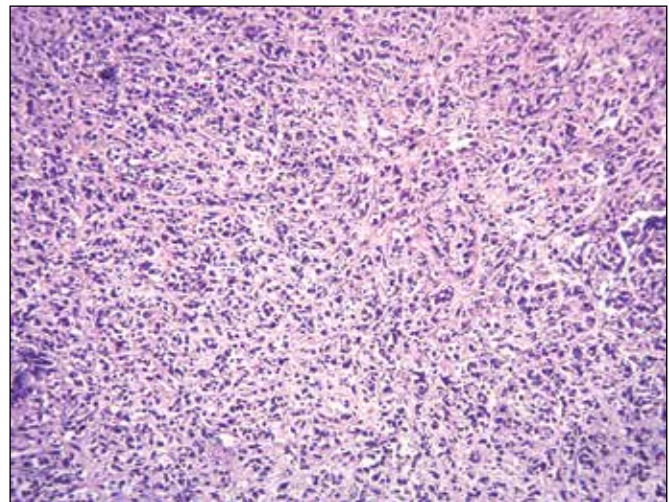


Figure 2: Proliferation of neoplastic cells with pleomorphic and hyperchromatic round to spindle cell nuclei. (H&E, x100).

DISCUSSION

Intradural spinal MPNSTs can be classified as primary or metastatic. (6). Primary spinal intradural MPNST is extremely rare. We found only 22 cases of primary spinal MPNST without neurofibromatosis in our search to this date. We summarized them in Table I. They are primarily distributed in: cervical in 7 patients (30%) (2,8,17,23), thoracic and thoracolumbar in 6 (26%) (7,15,17,23), and lumbar in 10 (44%) (1,3,7,14,17,21,22,24,25). Our patient had an intradural extramedullary cervical tumor extending from foramen magnum to lower cervical vertebrae with severely invasion of the spinal cord.

As shown in Table I, most patients of primary spinal MPNST were young with mean age of 32 ± 19 (SD) years and range of 3-70 years. There are only 5 children (22%) in the reports (8,17,24,25), mostly under 10 years old. Our patient is the

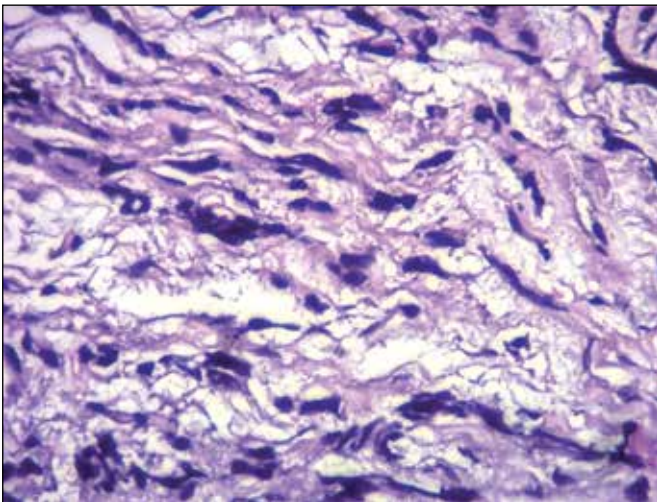


Figure 3: Wavy nuclei with hyperchromasia and pleomorphism. (H&E, x400).

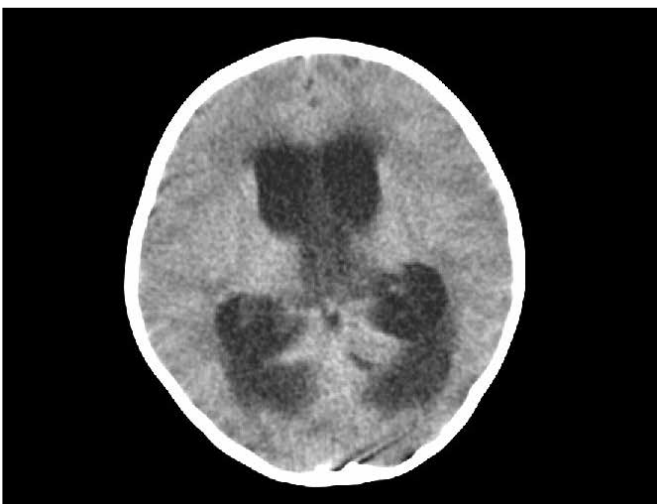

Figure 4: CT scan showed severe hydrocephalus after the patient's loss of consciousness.

youngest one. Tumors are distributed equally between men and women.

Patients usually present with pain, weakness, sensory loss, and bladder/bowel deficits. Hydrocephalus was seen in 4 patients with spinal MPNSTs (8,14,15), including 3 patients with brain metastasis and one with the cervical spinal cord involvement. Our patient developed acute hydrocephalus during hospitalization. Prompt diagnosis of acute hydrocephalus can prevent morbidity and mortality.

As found in our patient, the spinal MPNST lesions were described as non-homogenous hyperintense in T2WI and isointense in T1WI that enhanced after gadolinium injection (15,21). The hyperintense area on T2WI was reported as a central cystic lesion or necrosis (4). The leptomeningeal metastasis was hypointense in T2WI and enhanced homogeneously (14,15,21,24). The spinal seeding is defined as a "string-of-beads" pattern since they are small enhancing lesions spreading along the spinal cord (15). MRI may reveal leptomeningeal thickening and enhancement (21).

Pathological characteristics of spinal MPNST are high cellularity with spindle-shaped cells, nuclear atypia, increased mitotic activity, necrosis, extreme nuclear anaplasia, and endothelial proliferation (15,23).

Surgery is currently the mainstay of treatment for intradural spinal MPNST. It can result in significant recovery with an improved prognosis (1,10,16,23). Total removal was achieved in 64% of the patients in the previous studies (Table I). We could not achieve complete removal of the tumor, given that the lesion severely invaded the spinal cord. To the best of our knowledge, this is the only reported case with such massive tumor invasion into the spinal cord. The best adjuvant treatment for spinal MPNSTs remains poorly defined due to the rarity of the tumor and the lack of prospective trials.

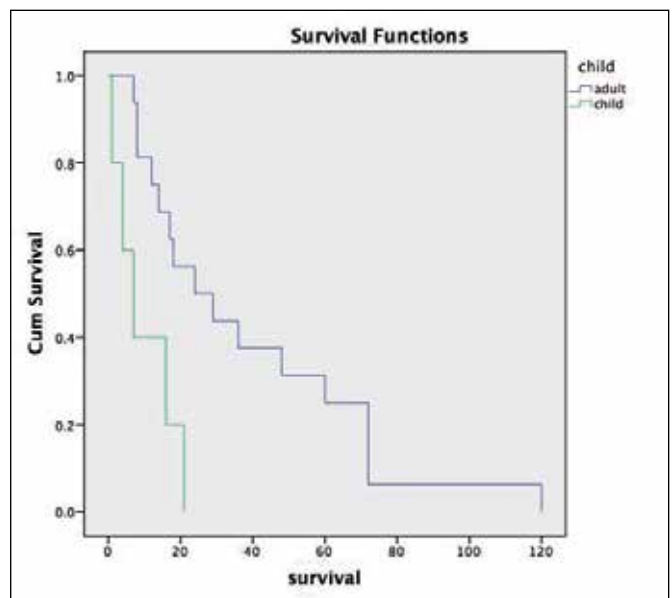


Figure 5: Kaplan-Meier test curve, comparing the survival rates between children (<16 years) and adults.

Table 1: Characteristic Findings of 23 Cases of Primary Spinal MPNST without NF1 Reported in the Literature

Authors & year of publication	Age (yrs)	Sex	Location	Presentation	Resection	Metastasis	Adjuvant Therapy	Acute Hydrocephalus	Recurrence	Survival
Thomeer et al., 1981 (22)	42	M	Cauda equina	LBP, impotency, leg weakness	Total	No	RT, Chemo	No	After 3yrs in T9-11	Alive at 3yrs
Valdueva et al., 1991 (23)	43	F	T10-12	LBP, leg weakness	Partial	No	RT	No	After 8 yrs	Alive at 10 yrs
	70	F	C4-C6	Neck pain + shoulder RD	Total	No	No	No	No	Disease free after 7 mos
	18	M	C4-5	Shoulder & arm pain	Total	No	No	No	No	Disease free after 8 mos
Seppala et al., 1993 (17)	13	M	Lumbar	Weakness & paraplegia	Total	Yes, systemic	RT	No	Yes	Died after 7 mos
	23	F	Upper thoracic	RD	Total	Yes, systemic	RT	No	Yes	Died after 8 mos
	37	F	Lower cervical	Paraparesis	Total	Yes, systemic	RT	No	After 2 yrs	Died after 6 yrs
Celli et al., 1995 (7)	52	F	T-2	Pain, weakness	Total	No	No	No	No	Disease free after 6 yrs
	68	F	L-4	Pain, weakness	Total	No	No	No	No	Disease free after 2 yrs
	43	M	L-3	Pain	Total	No	No	No	No	Disease free after 6 yrs
	36	F	T-11	Pain	Total	No	RT	No	Yes	Disease free after 4 yrs
	30	M	T-7	Pain, weakness	Total	Lung	RT	No	Yes	Died after 14 mos
Acharya et al., 2001 (1)	32	M	Cauda equina	LBP, leg weakness, Bowel & Bladder dis.	Partial	No	RT	No	No	Alive at 18 mos
Amin et al., 2004 (3)	38	M	Cauda equina	Leg weakness, LBP, Bowel & Bladder dis.	Biopsy	N/A	Chemo, palliative	-	NIM	NM
Adamson et al., 2004 (2)	37	M	C5-6	RD	partial	No	RT	No	NM	Died after 1 yr & few mos
	30	F	C5-6	RD, weakness of rt arm & wrist, rt Horner synd.	Partial	No	No	No	NM	Died after 1 yr
Yone et al., 2004 (25)	4	M	L3-5	LBP, RD, Bladder dis.	Total	Brain	RT, Chemo	No	Yes	Died after 21 mos
Chamoun et al., 2009 (8)	5	F	C4-5	Gait disturbance, vomiting, abdom. Pain	Partial	Systemic	RT, Chemo	Yes	Yes	Alive at 4 mos
Xu et al., 2012 (24)	8	M	L3-5	Pain	Total	Brain	RT	No	Yes	Died after 16 mos

Table I: Cont.

Authors & year of publication	Age (yrs)	Sex	Location	Presentation	Resection	Metastasis	Adjuvant Therapy	Acute Hydrocephalus	Recurrence	Survival
Li et al., 2014 (15)	33	F	T12-L1	LBP, RD, weakness	Partial	Brain + spinal cord	RT	Yes	Yes	Died after 2 yrs & 5 mos
Lau et al., 2014 (14)	43	M	Cauda equina	LBP, paresthesia	Total	Brain stem, spinal cord, kidney	No	Yes	After 60 mos	Died after 5 yrs
Thomas et al, 2014 (21)	49	M	Cauda equina	LBP, paraparesis, constipation	Partial	Brain, whole spinal cord	No	No	No	N/A
Present report	3	F	Foramen magnum- T1	LBP, paraplegia, Bladder & Bowel dis.	Partial	Brain, Whole spinal canal	No	Yes	-	Died shortly after surgery

Yrs: Years, **F:** Female, **M:** Male, **RT:** Radiotherapy, **mos:** Months, **LBP:** Low back pain, **Chemo:** Chemotherapy, **RD:** Radiculopathy, **N/A:** Not available, **dis:** Disorder, **MM:** Not mentioned, **rt:** Right, **syndr:** Syndrome.

Radiation therapy has been beneficial for local tumor control especially when complete resection is impossible (1,3). Yet, the effectiveness of chemotherapy has not been proven for MPNST (5).

Prognosis of patients with MPNST has always been poor with a 5-year survival rate of 16% to 52% (12). The 1-year and 5-year survival rate in our review of primary spinal MPNSTs was 68% (15/22) and 23% (5/22), respectively. Even after complete removal of the tumor and radiation therapy, metastasis rate was 45% (10/22), with recurrence of 54% (12/22). In these 23 reported spinal MPNSTs, we found age as a prognostic factor, showing children surviving less than adults ($p=0.005$, Figure 5). But the primary location of tumor (cervical, dorsal, or lumbar), sex (male or female), resection of the tumor (total or partial), occurrence of hydrocephalus, presence of metastasis, recurrence, or radiotherapy did not have any significant effect on the survival of patients ($p > 0.05$).

Craniospinal metastasis was reported in 6 cases of primary intradural spinal MPNST (14,15,18,21,24), including our patient. In 2 patients, leptomeningeal seeding was present at the time of diagnosis (21). Our patient was the only child who had metastasis along the whole spinal cord. Leptomeningeal spread is a dreadful and fatal event, usually suggesting advanced malignant disease.

■ CONCLUSION

Primary spinal MPNST have a high predisposition to leptomeningeal, craniospinal, and systemic metastasis with a rare incidence of spinal cord invasion. Despite aggressive treatment, its mortality and morbidity rates are high. Age may play a role in determining the prognosis of these patients, but one should bear in mind that this analysis was conducted on a limited number of patients reported in the literature. Lack of statistical significance for other variables could also be due to this matter.

■ REFERENCES

1. Acharya R, Bhalla S, Sehgal AD: Malignant peripheral nerve sheath tumor of the cauda equina. *Neurol Sci* 22:267-270, 2001
2. Adamson DC, Cummings TJ, Friedman AH: Malignant peripheral nerve sheath tumor of the spine after radiation therapy for Hodgkin's lymphoma. *Clin Neuropathol* 23:245-255, 2004
3. Amin A, Saifuddin A, Flanagan A, Patterson D, Lehovsky J: Radiotherapy-induced malignant peripheral nerve sheath tumor of the cauda equina. *Spine (Phila Pa 1976)* 29:E506-509, 2004
4. Aydin MD, Yildirim U, Gundogdu C, Dursun O, Uysal HH, Ozdikici M: Malignant peripheral nerve sheath tumor of the orbit: Case report and literature review. *Skull Base* 14:109-113; discussion 113-104, 2004
5. Baehring JM, Betensky RA, Batchelor TT: Malignant peripheral nerve sheath tumor: The clinical spectrum and outcome of treatment. *Neurology* 61:696-698, 2003

6. Baek WS, Pytel P, Undevia SD, Rubeiz H: Spinal cord metastasis of a non-neurofibromatosis type-1 malignant peripheral nerve sheath tumor: An unusual manifestation of a rare tumor. *J Neurooncol* 74:183-185, 2005
7. Celli P, Cervoni L, Tarantino R, Fortuna A: Primary spinal malignant schwannomas: Clinical and prognostic remarks. *Acta Neurochir (Wien)* 135:52-55, 1995
8. Chamoun RB, Whitehead WE, Dauser RC, Luerssen TG, Okcu MF, Adesina AM, Jean A: Primary disseminated intradural malignant peripheral nerve sheath tumor of the spine in a child: Case report and review of the literature. *Pediatr Neurosurg* 45:230-236, 2009
9. Dimou J, Jithoo R, Pitcher M, White G: Recurrent malignant peripheral nerve sheath tumour in a patient with neurofibromatosis Type 1: A case report. *J Clin Neurosci* 16:1221-1223, 2009
10. Gupta G, Maniker A: Malignant peripheral nerve sheath tumors. *Neurosurg Focus* 22:E12, 2007
11. Hajdu SI: Peripheral nerve sheath tumors. Histogenesis, classification, and prognosis. *Cancer* 72:3549-3552, 1993
12. Kourea HP, Bilsky MH, Leung DH, Lewis JJ, Woodruff JM: Subdiaphragmatic and intrathoracic paraspinal malignant peripheral nerve sheath tumors: A clinicopathologic study of 25 patients and 26 tumors. *Cancer* 82:2191-2203, 1998
13. Lai RS, Lin SL, Hsu SS, Wu MT: Intrathoracic paraspinal malignant peripheral nerve sheath tumor. *J Chin Med Assoc* 69:37-41, 2006
14. Lau D, Moon DH, Park P, Hervey-Jumper S, McKeever PE, Orringer DA: Radiation-induced intradural malignant peripheral nerve sheath tumor of the cauda equina with diffuse leptomeningeal metastasis. *J Neurosurg Spine* 21:719-726, 2014
15. Li Y, Fan F, Xu J, An J, Zhang W: Primary malignant peripheral nerve sheath tumor of the spine with acute hydrocephalus: A rare clinical entity. *J Neurosurg Spine* 21:367-371, 2014
16. Prieto R, Pascual JM, Garcia-Cabezas MA, Lopez-Barea F, Barrios L, Gonzalez-Llanos F: Low-grade malignant triton tumor in the lumbar spine: A rare variant of malignant peripheral nerve sheath tumor with rhabdomyoblastic differentiation. *Neuropathology* 32:180-189, 2012
17. Seppala MT, Haltia MJ: Spinal malignant nerve-sheath tumor or cellular schwannoma? A striking difference in prognosis. *J Neurosurg* 79:528-532, 1993
18. Stark AM, Mehdorn HM: Leptomeningeal metastasis of an intradural malignant peripheral nerve sheath tumor. *J Clin Neurosci* 20:1181-1183, 2013
19. Stucky CC, Johnson KN, Gray RJ, Pockaj BA, Ocal IT, Rose PS, Wasif N: Malignant peripheral nerve sheath tumors (MPNST): The Mayo Clinic experience. *Ann Surg Oncol* 19:878-885, 2012
20. Than KD, Ghori AK, Wang AC, Pandey AS: Metastatic malignant peripheral nerve sheath tumor of the cauda equina. *J Clin Neurosci* 18:844-846, 2011
21. Thomas JG, Lincoln C, Clay Goodman J, Gopinath SP: Malignant peripheral nerve sheath tumor of the cauda equina with craniospinal metastasis. *J Clin Neurosci* 21:2239-2242, 2014
22. Thomeer RT, Bots GT, van Dulken H, Luyendijk W, Helle P: Neurofibrosarcoma of the cauda equina. Case report. *J Neurosurg* 54:409-411, 1981
23. Valdueza JM, Hagel C, Westphal M, Hansel M, Herrmann HD: Primary spinal malignant schwannoma: Clinical, histological and cytogenetic findings. *Neurosurg Rev* 14:283-291, 1991
24. Xu Q, Xing B, Huang X, Wang R, Li Y, Yang Z: Primary malignant peripheral nerve sheath tumor of the cauda equina with metastasis to the brain in a child: Case report and literature review. *Spine J* 12:e7-13, 2012
25. Yone K, Ijiri K, Hayashi K, Yokouchi M, Takenouchi T, Manago K, Nerome Y, Ijichi O, Ikarimoto N, Komiya S: Primary malignant peripheral nerve sheath tumor of the cauda equina in a child case report. *Spinal Cord* 42:199-203, 2004