

*Original Investigation*

# Awake Craniotomy Procedure: Its Effects on Neurological Morbidity and Recommendations

Ali AKAY<sup>1</sup>, Sertac ISLEKEL<sup>2</sup><sup>1</sup>Ege University, Faculty of Medicine, Department of Neurosurgery, Izmir, Turkey<sup>2</sup>Kent Hospital, Department of Neurosurgery, Izmir, Turkey**ABSTRACT**

**AIM:** To present our experience with the awake craniotomy (AC) method starting from the preoperative period, to report the morbidity and the functional outcomes along with the complications in patients who underwent AC, and to make recommendations for possible problems.

**MATERIAL and METHODS:** This study involved 46 cases- 2 of which were pediatric cases with lesions localized in the functional area - who were operated with the AC method between September 2011 and January 2016 at our clinic. The age range was 12 to 81 years. The average age was 48 years. Both preoperative and postoperative (1, 3, 6 and 12 months) neurological examinations were recorded.

**RESULTS:** Of the 46 patients who had AC surgery in this series, 17 were observed to have neurological deterioration in the intraoperative period. At the month 1 follow-up, 13 of these 17 patients were observed to have full neurological recovery. Moreover, 4 patients that developed hemiplegia were able to mobilize with support at the month 6 follow-up. All patients were observed to have a return of language skills to baseline preoperative function on month 1 follow-up.

**CONCLUSION:** When the results of the AC method were examined, it was observed that persistent postoperative neurological deficit rates were very low in the follow-up period. Based on our practice presented here, it could be concluded that the precise synchrony between the surgeon, the anesthesia team and the patient is required for successful AC and the preservation of language and motor functions.

**KEYWORDS:** Awake craniotomy, Brain lesion, Morbidity, Complication

**INTRODUCTION**

Resection of brain lesions with awake craniotomy (AC) has become a method used in many centers in the past few decades. With the development of radiological techniques (functional magnetic resonance imaging (MRI), tractography) and intraoperative guidance tools (cortical stimulator, intraoperative ultrasound (USG)), the AC method is also developing. This method is preferred particularly in epilepsy and tumor surgeries, and it has become the most reliable form of resection of the lesions neighboring, or localized in, the functional areas. Additionally, the residual

tumor that would remain and the major morbidity that may develop are the most important factors affecting survival in glial tumor surgery, where the boundaries between the tumor and the normal brain tissue are lost. Therefore, AC is a reliable method to apply maximum tumor resection with minimum morbidity. Again, in patients with cardiac and respiratory risks to a degree that may not be operated with general anesthesia, the excision of brain lesions may be performed with AC.

In this article, we present the AC method that we performed on 46 patients at our clinic between September 2011 and January 2016 and the outcomes of our practice.



Corresponding author: Ali AKAY

E-mail: dr.aliakay@gmail.com

## ■ MATERIAL and METHODS

All procedures performed in studies involving human participants were in accordance with the ethical standards of the institutional and/or national research committee and with the 1964 Helsinki declaration and its later amendments or comparable ethical standards. For this type of study formal consent is not required. Informed consent was obtained from all individual participants included in the study.

A total of 46 patients that underwent awake brain tumor surgery at our clinic between September 2011 and January 2016 were included in this study. The age range of the operated patients was 12-81 years. The average age was 48 years. In this series, two pediatric patients were operated again through the AC method due to the lesions located in the functional areas (Figure 1A, B) (2,24). Patients with a minimum 12-month follow-up have been included and no complications or mortality as the natural history of the disease was observed within the 12 months in the patients. Follow-up visits were scheduled at month 1, 2, 3, 6, and 12. Only those who completed all the follow-up visits have been included in the current study.

### Preoperative Evaluations

All patients underwent diffusion, perfusion and spectroscopy analyses in addition to contrast-enhanced cranial 1.5 or 3 Tesla MRI before AC. Functional MRI (fMRI) or tractography examinations were completed preoperatively for all patients according to the characteristics of the areas neighboring the lesions or the functional area in which the lesion was localized. The postoperative MRI controls were performed within 24 hours, and the presence of residual tumor was evaluated by comparing the preoperative and postoperative MRI scans.

Furthermore, patients' baseline motor function assessment and language assessment were performed and the findings were recorded as part of preoperative evaluations. Picture naming, reading and spelling tests were utilized to see if the

patient could have any difficulty in performing any of these items preoperatively and the material to use with that patient for intraoperative language testing was modified by removing the problematic items accordingly.

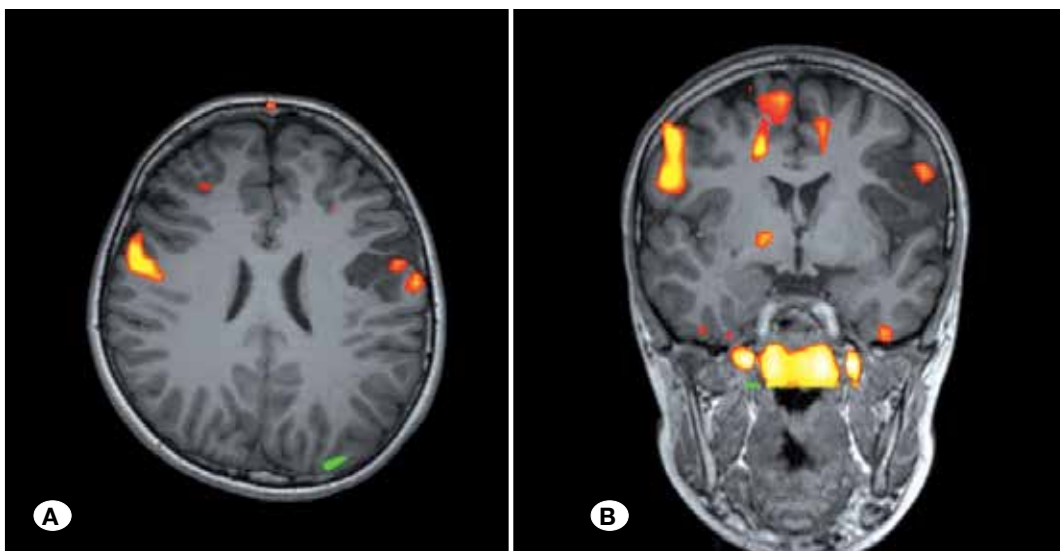
Patient education was provided with all patients. All patients were well-informed about the stages of the surgery, the possible requests of the surgical team, such as showing extremity movements and naming an object, and particularly for the need of informing the surgical team if/when they would sense any nausea or numbness and deceleration at any part of their body or similar feelings.

### Initiating the Surgery

Prior to the transportation of the patient into the operating room, intravenous (IV) midazolam was administered to help keep calm. After preoperative hair removal at the operating table, the hemodynamic, cardiac and SaO<sub>2</sub> monitorization were provided, and the procedure was passed on to the sedation part. Mayfield skull pins were inserted following local anesthesia and scalp block under sedation (Figure 2A) (12). After having provided the appropriate surgical position, an urinary catheter and nasal cannula were inserted by the anesthesia team. Once the patient's awake state was ensured, the patient's face was covered with a transparent sterile drape to enable maximum verbal and visual communication (Figure 2B). After having provided complete comfort for the patient, skin incision, craniotomy and dural incisions were performed under twilight anesthesia for less pain sensation (Figure 2C).

### Brain Mapping

Following opening of the dura, the cortical mapping step was commenced. For cortical stimulation, 50 Hz (100 Hz for the sensory cortex) 0.5 msec biphasic square waves were used [Ojemann cortical stimulator, OCS2] (Figure 2B). Starting with 1 mA and increasing with steps of 0.5 mA, up to 10 mA stimuli were given. The electrode used for this purpose was bipolar, with knob-shaped electrode ends, with 8-10 mm width



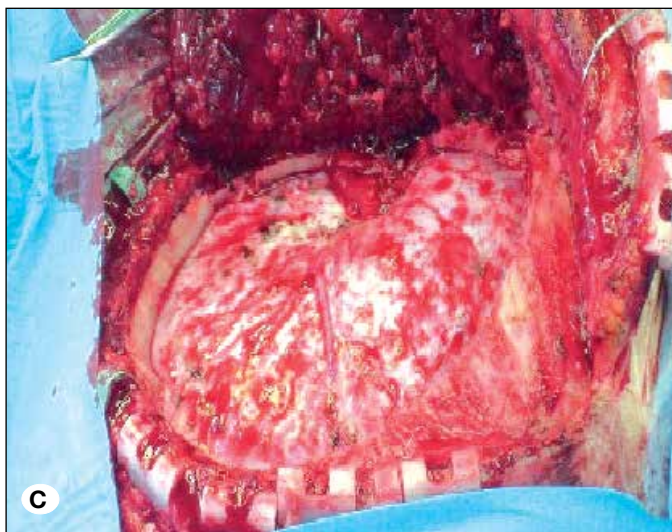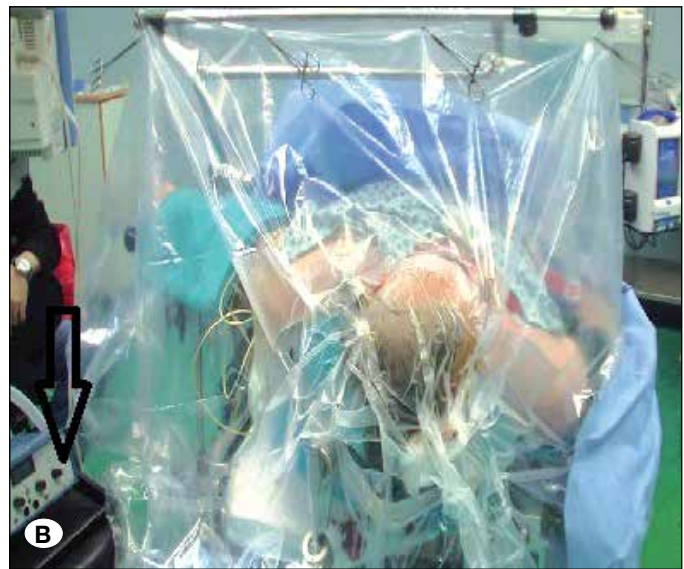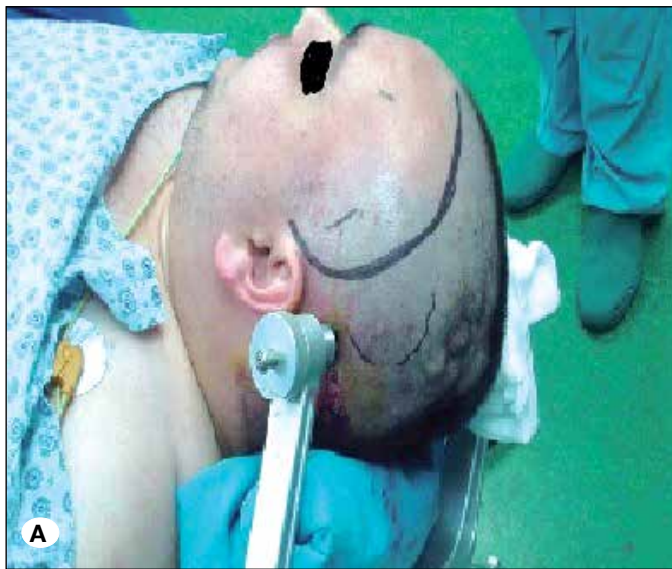**Figure 1:** During the functional MRI performed for the cerebral lesion located in Broca's area, activation in the lesion with speech activity was observed as seen in figures **A**) (axial) and **B**) (coronal). The histopathological result of the patient operated on with awake craniotomy was DNET.

between them. A potential functional area was identified from the preoperative MRI scans. Either stereotactic intervention or external landmarks was used to identify the cortex on which the incision for tumor surgery would be done and it was stimulated. When no functional response was noticed during the stimulation, the neighboring gyri were stimulated. In the motor field stimulation, findings such as contractions and tremor in the related muscles, numbness in the sensory field and tingling were observed. In the stimulation of Broca's area, findings such as pausing in speech, pausing in naming the subjects, counting numbers, reading and repeating were observed.

### Surgical Technique

When the mapping was completed, the cortex, which was identified as the closest to the lesion and identified to be non-functional, was determined for the incision. All procedures were performed using a surgical microscope. When necessary and appropriate, the sulci were used to approach the lesion,

with care taken for minimal brain tissue retraction. The retraction was made in the opposite direction in order to avoid compression of the functional cortex. Ultimate caution was ensured to protect both the veins that drain the functional areas and the arteries that were oriented to these sites, no matter what their diameters were. The functions of the patients were continuously monitored during removal of the tumor. Especially during the glial tumor excision, due to the tumor and the normal tissue being located in an intertwined manner, the tumor was stimulated so as to attempt keeping it in the safe zone. Tumor resection was continued with smaller steps and under continuous neurophysiological monitoring, particularly in the neighborhood of capsula interna or arcuate fasciculus, when it was understood that the tract was approached via stimulating the area. Tumor resection was restricted in those areas when tract invasion was detected in preoperative diffusion tensor imaging (DTI)-MRI. Intraoperative USG was used before the cortical incision and after the excision of the lesion so as not to leave residual tumor. A stereotactic frame



**Figure 2:** **A)** Mayfield skull pins were inserted following the local anesthesia under sedation and the patient was given the appropriate surgical position. **B)** After disappearance of the sedation effect, the patient was covered with transparent sterile drapes as visual and verbal communication could easily be provided. The device indicated by the arrow is the cortical stimulator that is used in brain mapping. **C)** After covering the patient, again, the skin incision and craniotomy were performed under an appropriate level of sedation-analgesia.

was used in some cases for navigation during the excision of lesions smaller than 2 cm.

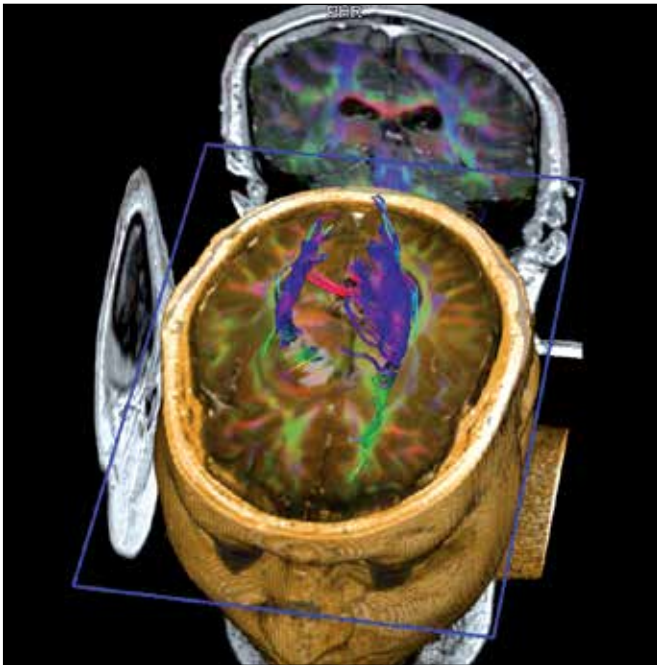
## ■ RESULTS

In the current series, no complications or mortality as the natural history of the disease was observed within the first 12 months in the patients. The histopathological results of 46 patients were 33 glial tumors, 5 metastases, 3 cavernomas,

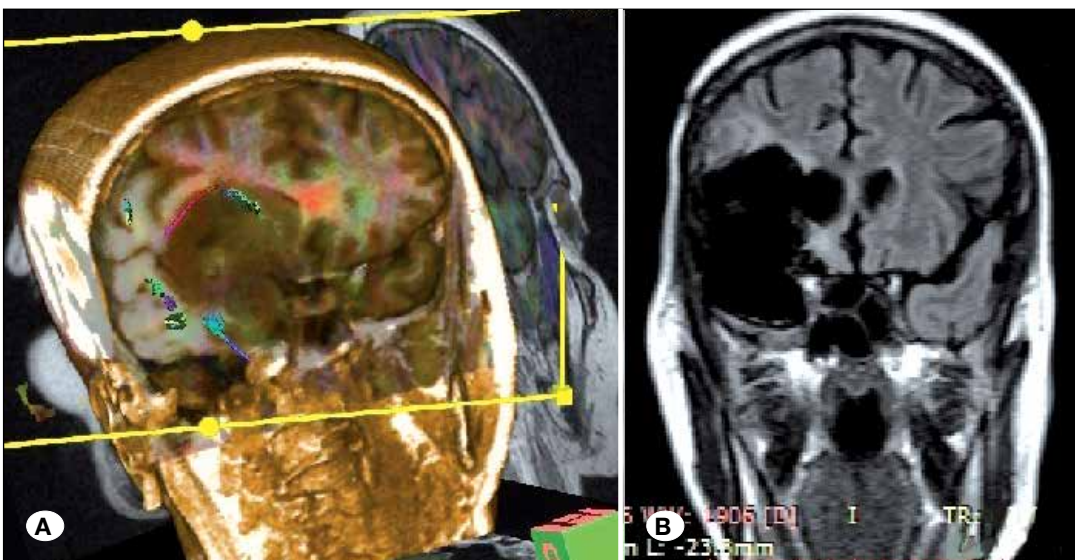
1 hemangioblastoma, 1 meningioma, 1 cortical dysplasia, 1 previous cerebritis, and 1 cortical heterotopia.

Of the 46 patients who underwent AC surgery in this series, 30 had no motor deficit preoperatively. However, during the intraoperative period, neurological deterioration was observed in 10 patients who were reported to have no previous neurological deterioration preoperatively. The characteristics of the patients with neurological deterioration were apraxia in 1 patient, dysarthria in 2 patients, hemiplegia in 2 patients, and hemiparesis in 5 patients. When the postoperative control MRI scans of the patients who had developed hemiplegia were evaluated, it was understood that in 1 patient, despite partial resection having been performed, transient hemiplegia due to motor tract manipulation developed (Figure 3), and in the other patient, permanent hemiplegia developed due to vascular injury. The hemiplegia due to tract manipulation fully recovered within 24 hours in the postoperative period. The hemiplegia which developed secondary to vascular injury was understood to have developed due to thalamic ischemia as a result of perforating artery injury, despite total resection having been observed on the postoperative control cranial MRI (Figure 4A, B). The neuromotor disorders of the other patients in this group resolved at the end of 6 months. Resections were discontinued as soon as there was deterioration in motor functions. These neurological deteriorations were related to the manipulations made with no harm to the integrity of the tract. However, the patient who developed hemiplegia due to vascular injury become mobile with support with intensive rehabilitation at the end of 1 year (lower extremity muscle strength: 3/5, upper extremity muscle strength: 1/5).

Of the 46 patients involved in this study, 16 had varying degrees of neurological deficits in the preoperative period. In the intraoperative neuro-functional monitoring of the patients in this group, 7 displayed deterioration in their motor functions, 4 showed no changes and 5 patients demonstrated improvement. Of the 7 patients who showed deterioration, 3 patients had hemiplegia, and 4 patients demonstrated



**Figure 3:** View of the thalamo-capsular lesion and the surrounding corticospinal tract. Despite partial excision of this lesion, due to the tracts being around the tumor, hemiplegia developed during the procedure. The excision was terminated due to hemiplegia. The histopathological diagnosis of this lesion was pilocytic astrocytoma.



**Figure 4:** **A)** DTI images of the insular lesion and the capsular infiltration of the lesion. **B)** Postoperative coronal T1 MRI showing total excision of the lesion. The histopathological diagnosis of this lesion was oligodendroglioma. Although total tumor excision was performed on this patient, hemiplegia developed secondary to vascular injury.

worsening in their hemiparesis. At the end of the 6<sup>th</sup> month, 3 hemiplegic patients were observed to mobilize with support. Four advanced hemiparetic patients were mobilized without support at the end of 6<sup>th</sup> month.

In brief, of 46 patients who had AC surgery in this series, 17 were observed to have worsening neurological deterioration in intraoperative period. On month 1 follow-up, 13 of these 17 patients were observed to have a full neurological recovery. Moreover, 4 patients that developed hemiplegia were able to mobilize with support on month 6 follow-up.

The complications other than vascular injury were as follows: intracerebral hematoma developed in 1 patient at the postoperative late period (2 weeks later) due to a hypertensive attack and the patient was operated. One patient was operated for cerebral abscess following discharge at the wound site postoperatively and received IV antibiotic treatment. Intraoperative epileptic seizures were observed in 3 patients. No language function deterioration was observed in any patients involved in the present study on month 1 follow-up.

#### **Possible Problems and Recommendations**

AC patients may feel pain, especially following the skin incision, during the dissection of muscle and the periosteum. In our practice, some of the patients reported feeling pain to a lower extent during craniotomy and dural incision. For this reason, sedatives that have analgesic characteristics were used at these stages. During the manipulations on blood vessels in the tumor resection, complaints of severe pain appeared in the patients. When the patient feels pain, the procedure should be halted, and the surgical team should calm the patient by talking to keep them non-agitated until the pain sensation is reduced. Surgery should be continued when the pain sensation disappears. Complaints of nausea and vomiting may appear in patients during the manipulations on vascular tissues. In particular, nausea and vomiting may occur in the excision of the masses localized in the insular region that is rich in vascular network. In this case, a break was taken, and the anesthesia team was asked to use anti-emetic agents. Patients may have seizures during the cortical stimulation procedure, which is used for cortical mapping. For our patients who had seizures during the tumor resection with AC, the seizure was brought under control with IV midazolam, applied by the anesthetists. However, during the seizure, complications of swelling of the brain and bleeding may develop. Epileptic seizures can turn the awake surgery into a nightmare. For this reason, based on our experience, we administered IV infusion of 500 mg levetiracetam to the patient before we started the surgery. Levetiracetam was continued in the postoperative period. In the literature, some authors suggested washing of the brain with cold saline during the seizures and it has been reported that the seizures stopped with this intervention (7).

Also, the level of noise in the operating room should be at a level to enable the surgical team to hear the patient's murmurs. As much as the comfort provided with the technical tools in the operating room, the comfort of the surgical position given to the patient is also important.

## **■ DISCUSSION**

The aim of neurological tumor surgery is to always achieve radical tumor excision without creating an additional neurological deficit in the patient. The amount of tumor resection is the most important determining factor on the prognosis of intra-axial brain tumors (2,21,28). The median survival time and the time to recurrence have been found to be longer in patients who have undergone gross-total tumor resection (32,33). However, such brain tumor resection in eloquent brain regions carries a high risk of morbidity. Therefore, the surgeon should respect the delicate balance between gross-total removal of the tumor and development of morbidity (30,31).

Different methods and tools are available for a safe approach and secure resection of the tumor. Methods such as intraoperative MRI, intraoperative USG, framed or frameless stereotactic navigation, and neuro-monitorization are used (5,14). Apart from the awake brain mapping to determine the motor cortex, neuromonitorization with somatosensory evoked potentials (SEP) and motor evoked potentials (MEP) are also used during the tumor excision. Each method has different advantages and disadvantages. Despite determination of the motor cortex with SEP and MEP being an important auxiliary method, it is not possible to use it in the speech area. AC seems to be an easy method with its ease of implementation and not creating additional costs (3,4,8,16,20). In the practice of neurosurgery, cranial surgeries are performed with local anesthesia such as external ventricular drainage, burr hole evacuation of hematomas and stereotactic biopsies; therefore, neurosurgeons have enough experience to carry out intracranial interventions with local anesthesia.

Radiological examinations are important for the surgical planning in tumor surgeries for functional areas and the surroundings (1,28). In some cases, tumors localized in the functional domains may be in the functional areas or may have caused displacement of the functional area (2). The most helpful examination in this field is determination of the functional cortex with fMRI (6). The resolution of the MRI device, its program, and the knowledge and the experience of the MRI technician are important in fMRI. In some cases, especially the fMRI related to speech may not provide sufficient data. In these cases, mapping becomes more important during the surgery. Tractography, which has begun to be used in recent years in preoperative MRI, has become very useful in terms of showing the areas in which care should be taken, not only in the cortical incision of the tumor, but also in the excision of the deeply localized parts. Jaaskelainen and Randell stated that many patients were afraid of the idea of awake surgery, but when sufficient explanation was provided, they trusted their physicians (16). Furthermore, in our experience, some of our patients adapted easily to the idea of reduced operative risks with awake surgery techniques, and some had concerns that they would have pain during the procedure. The patients should be well informed that they would be sedated in addition to the local anesthesia, and that they would not feel pain during the surgery. Whittle's study also showed that many patients tolerated awake surgery well (30). Sterile

transparent drapes are used to allow the surgeon to see the patient's movements during the procedure. In addition, it also permits the patient to see the outside, thus, preventing the patient from feeling bored or suffocated. In the absence of sterile transparent drapes, which have been prepared for this purpose, the microscope sheaths may be used when cut appropriately. During the procedure, the patient should be monitored and examined continuously by an anaesthetist or another neurosurgeon (25).

As Jones and Smith have defined, there are 3 different anesthesia methods for AC, as only local anesthesia, sedation, and the sleep-awake-sleep techniques (17). Local anesthesia would not be sufficient in tumor resection that requires extensive craniotomy. In some cases, the patients were sedated with propofol and fentanyl, and awakened during the mapping (9-11,13,17,18,23,26,27,29). Propofol provides short-acting sedation without affecting the cognitive functions. However, despite reducing the incidence of seizures, propofol use may cause respiratory depression during deep sedation (15). Midazolam or dexmedetomidine are more frequently recommended as alternatives to propofol (10). In the current series, adequate sedation was provided with the combination of midazolam and fentanyl to provide extensive craniotomy.

In their retrospective study of 294 patients with gliomas in the peri-rolandic region, Keles et al. have reported that the rate of patients that had a motor function deficit immediately after the surgical excision of the tumor with the aid of intraoperative monitoring was 20%, and on month 3 follow-up, persistent motor function deficit was observed in 4.8% of patients (19).

Maldaun et al. have reported that 26.2% of their cases who underwent AC surgery displayed worsening neurological functions in the postoperative period. This rate has been reported to be 2.3% on month 1 follow-up. (22)

The functional outcomes of the AC method applied in this series were as follows: at the end of the 12<sup>th</sup> month, permanent neurological deterioration secondary to the surgery was still observed in 4 of 46 patients (8.6%) who were operated with the AC method. These patients mobilized, although with support, and were not bedridden at the end of the 12<sup>th</sup> month. No evaluation of neurocognitive function outcomes was addressed to in the current study; therefore, this could be one of the limitations of the present study that calls for further research in the field.

It is also important to note that patient-dependent factors (perioperative risks related to patient, e.g. obesity, chronic smoking, psychiatric state), the type, grade, size and location of tumor in the functional area, approach toward tumor excision (gross-total or sub-total), the anesthesia method preferred, and the problems (e.g. an uncontrolled cough, vomiting, seizure), which might be encountered intraoperatively, are possible variables that determine the functional outcomes of the AC surgery procedure. Moreover, as the current literature provides various findings that make it quite difficult to compare the results related to functional area, a better documentation of the patient information, presentation of procedures and findings of further studies could be of help to improve the AC method.

## ■ CONCLUSION

AC is an essential surgical method to apply mainly in the removal of tumors located in the functional area. The role of intraoperative brain mapping, MRI and navigation use has become increasingly important for identification and preservation of functional area, i.e. language, motor and cognitive functions. Also, the results of AC interventions suggest progression-free and long-term survival, particularly in low-grade gliomas, while minimizing the volume of residual tumor. Based on our practice presented here, precise synchrony among the surgeon, anesthesia team and the patient, is required for a successful AC and for the preservation of language and motor functions.

## ■ REFERENCES

1. Akagami R, Napolitano M, Sekhar LN: Patient evaluated outcome after surgery for basal meningiomas. *Neurosurgery* 50:941-949, 2002
2. Akay A, Ruksen M, Cetin HY, Seval HO, Islekel S: Pediatric awake craniotomy for brain lesion. *Pediatr Neurosurg* 51(2):103-108, 2015
3. Ard JL Jr, Bekker AY, Doyle WK: Dexmedetomidine in awake craniotomy: A technical note. *Surg Neurol* 63(2):114-116, 2005
4. Bekar A, Korfali E, Calisir B, Tolunay S: Minimally invasive craniotomy using the Steiner-Lindquist stereotaxic guide. *Minim Invas Neurosurg* 44(1):13-16, 2001
5. Bernstein M: Outpatient craniotomy for brain tumor: A pilot feasibility study in 46 patients. *Can J Neurol Sci* 28:120-124, 2001
6. Blanshard HJ, Chung F, Manninen PH, Taylor MD, Bernstein M: Awake craniotomy for removal of intracranial tumor: Considerations for early discharge. *Anesth Analg* 92(1):89-94, 2001
7. Bohyun S, Hee-Soo K, Jin-Woo P, Hyo-Jin B, Jin-Tae K, Chong Sung K: Anesthetic management with scalp nerve block and propofol/remifentanyl infusion during awake craniotomy in an adolescent patient. *Korean J Anesthesiol* 59 Suppl : 179-182, 2010
8. Brannen JH, Badie B, Moritz CH, Quigley M, Meyerand ME, Houghton VM: Reliability of functional MR imaging with word-generation tasks for mapping Broca's area. *Am J Neuroradiol* 22(9):1711-1718, 2001
9. Cohen-Gadol AA, Britton JW, Collignon FP, Bates LM, Cascino GD, Meyer FB: Nonlesional central lobule seizures: Use of awake cortical mapping and subdural grid monitoring for resection of seizure focus. *J Neurosurg* 98(6):1255-1262, 2003
10. Conte V, Magni L, Songa V, Tomaselli P, Ghisoni L, Magnoni S, Bello L, Stocchetti N: Analysis of propofol/remifentanyl infusion protocol for tumor surgery with intraoperative brain mapping. *J Neurosurg Anesthesiol* 22(2):119-127, 2010
11. Costello TG, Cormack JR: Anaesthesia for awake craniotomy: A modern approach. *J Clin Neurosci* 11(1):16-19, 2004
12. Costello TG, Cormack JR, Mather LE, LaFerlita B, Murphy MA, Harris K: Plasma levobupivacaine concentrations following scalp block in patients undergoing awake craniotomy. *Br J Anaesth* 94(6):848-851, 2005

13. Danks RA, Rogers M, Aglio LS, Gugino LD, Black PM: Patient tolerance of craniotomy performed with the patient under local anesthesia and monitored conscious sedation. *Neurosurgery* 42: 28–36, 1998
14. Haglund MM, Berger MS, Shamseldin M, Lettich E, Ojemann GA: Cortical localization of temporal lobe language sites in patients with gliomas. *Neurosurgery* 34(4):567-576, 1994
15. Herrick IA, Craen RA, Gelb AW, Miller LA, Kubu CS, Girvin JP, Parrent AG, Eliasziw M, Kirkby J: Propofol sedation during awake craniotomy for seizures: Patient-controlled administration versus neurolept analgesia. *Anesth Analg* (84): 1285-1291, 1997
16. Jaaskelainen J, Randell T: Awake craniotomy in glioma surgery. *Acta Neurochir* 88 Suppl:31-35, 2003
17. Jones H, Smith M: Awake craniotomy. Continuing education in anaesthesia. *Critical Care & Pain* 4(6):189-192, 2004
18. Keifer JC, Dentchev D, Little K, Warner DS, Friedman AH, Borel CO: A retrospective analysis of a remifentanyl/propofol general anesthetic for craniotomy before awake functional brain mapping. *Anesth Analg* 101(2):502-508, 2005
19. Keles GE, Lundin DA, Lamborn KR, Chang EF, Ojemann G, Berger MS: Intraoperative subcortical stimulation mapping for hemispherical periorlandic gliomas located within or adjacent to the descending motor pathways: Evaluation of morbidity and assessment of functional outcome in 294 patients. *J Neurosurg* 100:369–375, 2004
20. Larkin M: Neurosurgeons wake up to awake-brain surgery. *Lancet* 353:1772, 1999
21. Mack PF, Perrine K, Kobylarz E, Schwartz TH, Lien CA: Dexmedetomidine and neurocognitive testing in awake craniotomy. *J Neurosurg Anesthesiol* 16(1):20-25, 2004
22. Maldaun MV, Khawja SN, Levine NB, Rao G, Lang FF, Weinberg JS, Tummala S, Cowles CE, Ferson D, Nguyen AT, Sawaya R, Suki D, Prabhu SS: Awake craniotomy for gliomas in a high-field intraoperative magnetic resonance imaging suite: Analysis of 42 cases. *J Neurosurg* 8:1–8, 2014
23. Manninen PH, Tan TK: Postoperative nausea and vomiting after craniotomy for tumor surgery: A comparison between awake craniotomy and general anesthesia. *J Clin Anesth* 14(4):279-283, 2002
24. McDougall RJ, Rosenfeld JV, Wrennall JA, Harvey AS: Awake craniotomy in an adolescent. *Anaesth Intensive Care*. 29(4):423-425, 2001
25. Meyer FB, Bates LM, Goerss SJ, Friedman JA, Windschitl WL, Duffy JR, Perkins WJ, O'Neill BP: Awake craniotomy for aggressive resection of primary gliomas located in eloquent brain. *Mayo Clin Proc* 76:677-687, 2001
26. Paldor I, Drummond KJ, Awad M, Sufaro YZ, Kaye AH: Is a wake-up call in order? Review of the evidence for awake craniotomy. *J Clin Neurosci* 23:1-7, 2016
27. Sarang A, Dinsmore J: Anaesthesia for awake craniotomy evolution of technique that facilitates awake neurological testing. *Brit J Anaesth* 90(2):161-165, 2003
28. Tan TC, Black P: Image-guided craniotomy for cerebral metastases: Techniques and outcomes. *Neurosurgery* 53: 82-90, 2003
29. Taylor MD, Bernstein M: Awake craniotomy with brain mapping as the routine surgical approach to treating patients with supratentorial intraaxial tumors: A prospective trial of 200 cases. *J Neurosurg* 90(1):35-41, 1999
30. Whittle IR: Surgery for gliomas. *Curr Opin Neurol* 15(6):663-669, 2002
31. Whittle IR, Borthwick S, Haq N: Brain dysfunction following 'awake' craniotomy, brain mapping and resection of glioma. *Br J Neurosurg* 17(2):130-137, 2003
32. Whittle IR, Midgley S, Georges H, Pringle AM, Taylor R: Patient perceptions of "awake" brain tumour surgery. *Acta Neurochir (Wien)* 147(3):275-277, 2005
33. Yetkin FZ, Mueller WM, Morris GL, McAuliffe TL, Ulmer JL, Cox RW, Daniels DL, Haughton VM: Functional MR activation correlated with intraoperative cortical mapping. *AJNR Am J Neuroradiol* 18(7):1311-1315, 1997