



DOI: 10.5137/1019-5149.JTN.19257-16.2

Received: 24.10.2016 / Accepted: 25.03.2017

Published Online: 02.05.2017

Original Investigation

The Effect of Intravenous L-Carnitine on the Vasospasm Process in the Experimental Subarachnoid Hemorrhage Model

Ahmet SOYER¹, Murat GOKTEN¹, Kamil OGE¹, Figen SOYLEMEZOGLU²

¹Hacettepe University, School of Medicine, Department of Neurosurgery, Ankara, Turkey

²Hacettepe University, School of Medicine, Department of Pathology, Ankara, Turkey

ABSTRACT

AIM: Cerebral vasospasm after subarachnoid hemorrhage (SAH) is an important cause of morbidity and mortality. In this study, we examined the effects of L-carnitine on the cerebral vasospasm process.

MATERIAL and METHODS: Twenty male New Zealand white rabbits were randomly divided into 4 groups. Group 1 served as control; group 2 was not subjected to SAH and received intravenous L-carnitine 3 times; group 3 was subjected to SAH and group 4 was subjected to SAH and treated with 100 mg/kg intravenous L-carnitine at 0, 24, and 48 hours after SAH. All animals were euthanized by perfusion-fixation 72 hours after SAH induction. The brains were then removed and stored in fixative +4°C overnight. The subjects' basilar arteries were sectioned from four separate zones. Basilar artery cross-sectional areas and thicknesses of vessels were measured by using the SPOT for Windows Version 4.1 computer programme. Statistical comparisons were performed by using the Kruskal-Wallis and Mann-Whitney U tests.

RESULTS: Basilar artery wall thicknesses in group 4 were significantly lower than in group 3 ($p=0.009$). Basilar artery cross-sectional areas in group 4 were higher than in group 3 and the difference was statistically significant ($p=0.008$).

CONCLUSION: L-carnitine was shown to be potentially beneficial on the resolution of cerebral vasospasm following SAH.

KEYWORDS: L-carnitine, Subarachnoid hemorrhage, Cerebral vasospasm, Basilar artery

■ INTRODUCTION

Cerebral vasospasm causes approximately 10% mortality and permanent disability after subarachnoid hemorrhage (8). It is a delayed narrowing of cerebral arteries at the base of the brain. Ecker and Riemenschneider described cerebral vasospasm in 1951 (9), and since that time the etiology and pathogenesis of cerebral vasospasm has not been revealed. Radiographic cerebral vasospasm can be seen in up to 70% and clinically apparent vasospasm in 20-30% of patients (6). In subarachnoid hemorrhage of humans, cerebral vasospasm usually begins on the third day of the hemorrhage and peaks at day seven, and if the patient survives, diminishes in the second week, with or without neurological sequelae (19). Although many approaches to prevent vasospasm have been

proposed, including hypertensive hypervolemic hemodilution therapy (triple H), calcium channel antagonists, statins, endothelin receptor antagonists, magnesium sulphate, and cisternal drainage, no standardized treatment modality has been established yet (8).

Prolonged exposure of cerebral arteries to perivascular blood (probably Oxyhaemoglobin=OxyHb) is necessary for the development of vasospasm. OxyHb causes vasoconstriction and catalyzes the formation of reactive oxygen species (ROS) (1). Antioxidants, which scavenge ROS, can slow down the vasospasm process. L-lysine and L-methionine are the precursors of L-carnitine which was synthesized in the liver and kidneys and acts as an intrinsic antioxidant compound. L-carnitine acts in the transportation of long-chained fatty



Corresponding author: Ahmet SOYER

E-mail: soyerahmet@gmail.com

acids through the inner membranes of mitochondria where they are metabolized to produce energy (11). L-carnitine is water-soluble so can be used intravenously. L-carnitine has been proposed as a treatment for many conditions such as angina pectoris (7), diabetic neuropathy (12), Alzheimer's disease (14), major depressive disorders (14), male infertility (16), erectile dysfunction (5), hyperthyroidism (3) and peripheral vascular disease (4). According to our literature survey, one research group suggests that L-carnitine has a neuroprotective effect on rats after traumatic brain injury (15). On the basis of this knowledge, we investigated the free radical scavenger effects of L-carnitine and its effect on cerebral vasospasm in an experimental subarachnoidal hemorrhage model in rabbits.

■ MATERIAL and METHODS

Animal Model

The experimental protocols used in this study were approved by the Hacettepe University Animal Research Committee (approval number of 2014/55-02). All procedures performed in this study involving animals were in accordance with the ethical standards of the institution. The sample amounts were calculated according to "resource equation" method, which is the acceptable method of Hacettepe University Animal Research Committee. The study was conducted on 4 groups each containing 5 male New Zealand White rabbits weighing 2,500-3,500 g. The animal groups were designed as follows: Group 1 was composed of 5 rabbits that served as negative controls, Group 2 was composed of 5 rabbits that received 100 mg/kg intravenous boluses of L-carnitine 3 times (0, 24, and 48 h after SAH). Group 3 was composed of 5 rabbits in which 0.1 ml of cerebrospinal fluid (CSF) was drained from the cisterna magna and 0.3 ml of autologous non-heparinized blood was administered to the cisterna magna. Group 4 was composed of 5 rabbits where 0.1 ml of CSF was drained from the cisterna magna and 0.3 ml of autologous non-heparinized blood was administered to the cisterna magna and 100 mg/kg of L-carnitine was administered intravenously at 0, 24 and 48 hours after SAH. Experiments were conducted by two researchers (A.S. and M.G.) and histopathological assessments and measurements were conducted by F.S. in a blinded fashion.

Twenty rabbits were anesthetized by intramuscular injection of ketamine (Ketalar®, 50 mg/kg) and xylazine (Rompun®, 10 mg/kg), paralyzed with pancuronium bromide 0.08 mg/kg, and intubated and then ventilated with a Harvard 683 model dual-phase ventilator (Harvard Apparatus Co.). Cisternal subarachnoidal blood was introduced by puncturing the cisterna magna with a 23 G needle. After the needle was inserted into the cisterna magna, 0.1 ml CSF was drawn and 0.3 ml of autologous non-heparinized blood was injected from the same route. The animals were then placed in Trendelenburg position to diffuse the blood into the basal cisterns and the subarachnoid space. During the procedure, arterial gas concentrations and all vital parameters of the rabbits were monitored and kept within physiological limits. After recovering from anesthesia, the rabbits were observed for possible neurological deficits and returned to the vivarium.

Sacrification, Perfusion and Fixation

All animals subjected to the experiment were anesthetized by the same method of SAH induction, mentioned above. The ear artery was cannulated for the monitoring of blood pressure and blood gas analysis. After the animal was stabilized to physiological parameters, thoracotomy was performed, the left ventricle was cannulated, the right atrium was opened and the aorta was cross-clamped. The brain was perfused by Hank's solution (Hank's balanced salt solution from Sigma Chemical Co. pH 7.4 at 37°C, 300 ml), and the fixative was administered (2% paraformaldehyde, 2.5% glutaraldehyde 0.1 M phosphate buffer, pH 7.4, at 37°C, 200 ml). Perfusion was performed at a standard height of 100 cm from the chest. The brains were then removed and stored in fixative at 4°C.

Embedding, Morphometry and Statistical Analysis

The brainstems were identified and 1/3 proximal sections of the basilar arteries were dissected for morphometric and histopathological analysis. The dissected basilar artery segments were washed with 0.1 mol phosphate-buffered solution (PBS) pH 7.4, and fixated in 1% osmium tetroxide in PBS for 1 hour at room temperature, and then rinsed with PBS. 0.5 µm cross sections were placed on microscopic glass slides and stained with Hematoxylin and Eosin (H&E). The vessel wall thickness and vessel cross-sectional area measurements were done by using computer-assisted morphometry (SPOT for Windows version 4.1). The pathologist was blinded to the groups. Four cross-section areas of each specimen were measured and arithmetical means were used for statistical analysis. Statistical comparisons were performed using the Mann-Whitney U and Kruskal-Wallis tests. Statistical significance was accepted at $p < 0.05$.

■ RESULTS

Physiological parameters of each group are summarized in Table I. No statistically significant difference was found between the physiological parameters of the groups.

Narrowing of the cross sectional area, folding and corrugation of lamina elastica, vacuolization of tunica media and inflammatory cell infiltration around the tunica adventitia comparisons of group 3 and group 4 samples are seen in Figures 1A, B.

The differences between group 1 and group 3 for both cross-sectional areas and vessel wall thicknesses were statistically significant ($p=0.008$), showing that the cisternal blood injection method worked as planned. On the other hand, vessel wall thicknesses were thinner and the vessel cross-sectional areas larger in the comparison of group 3 and group 4, and these differences were statistically significant ($p=0.009$ and $p=0.008$ respectively). Mean cross-sectional areas and vessel wall thicknesses of all groups are listed in Table II (Figures 2, 3).

■ DISCUSSION

Cerebral vasospasm after SAH is one of the most challenging situations for neurosurgeons. Despite the years of study, there is no curative treatment for this devastating entity.

Experimental models are necessary for understanding of the pathophysiology of cerebral vasospasm. Animal models should be reliable and feasible. Among them, one of the most commonly used models is the rabbit SAH model (18). Cerebral vasospasm is reported to be maximum at 48-72 hours after SAH induction in rabbits (2). Therefore, we sacrificed the animals at the 72nd hour to demonstrate significant vasospasm.

L-carnitine is an endogenous amino acid synthesized by lysine and methionine. It is synthesized in the liver and kidneys and stored in skeletal muscles, brain, heart and sperm. Meat and milk are the main resources of extrinsic carnitine. It is water soluble and can be used intravenously. It has a strong antioxidant character and is therefore used in clinical and experimental studies for angina pectoris, peripheral vascular diseases, diabetic neuropathy, Alzheimer's disease, memory dysfunctions, male infertility and erectile dysfunction.

Multiple factors contribute to cerebral vasospasm process and one of the most important is oxidative stress. After subarachnoid hemorrhage, OxyHb released from the clot in the subarachnoid space is responsible for prolonged contraction of cerebral artery wall and narrowing of the vessel's luminal area. OxyHb is involved in direct vasoconstriction, release of arachidonic acid metabolites and endothelin from the arterial wall, inhibition of endothelium-dependent vasodilatation through nitric oxide (NO) scavenging, damage to the perivascular nerves and promotion of free radical reactions through generation of reactive oxygen species (13). Antioxidants that prevent oxidative stress in the arterial wall can be used for the prevention and reversal of cerebral vasospasm.

In experimental studies, many antioxidant compounds have been used to reduce free radicals. L-carnitine is also one of the compounds affecting the same pathways. One of the

Table I: Summary of Physiological Parameters of the Groups

Group	n	Body weight (g)	Brain weight (g)	pH	pCO ₂	pO ₂	MABP (mmHg)
1	5	2,884±340.7	9.2±0.31	7.39±0.01	40.8±0.21	106.4±2.50	101±1.03
2	5	2,928±296.7	8.8±0.31	7.40±0.01	40.9±0.24	107.4±2.30	101±1.21
3	5	2,906±342.9	9.0±0.23	7.41±0.01	41.0±0.15	107.4±3.78	103±1.89
4	5	3,026±261.6	8.8±0.19	7.41±0.01	41.0±0.15	104.2±2.16	102±2.12

MABP: Mean arterial blood pressure.

Table II: Summary of Mean Cross-Sectional Areas and Vessel Wall Thicknesses of the Groups

Group	n	Mean cross sectional area (µm ²)	Mean vessel wall thickness (µm)
1	5	110,338±8,021.80	44.4±4.61
2	5	112,788.80±5,915.10	44.8±5.16
3	5	43,265.20±3,260.30	101.4±5.12
4	5	79,618.80±3,091.66	63.4±3.64

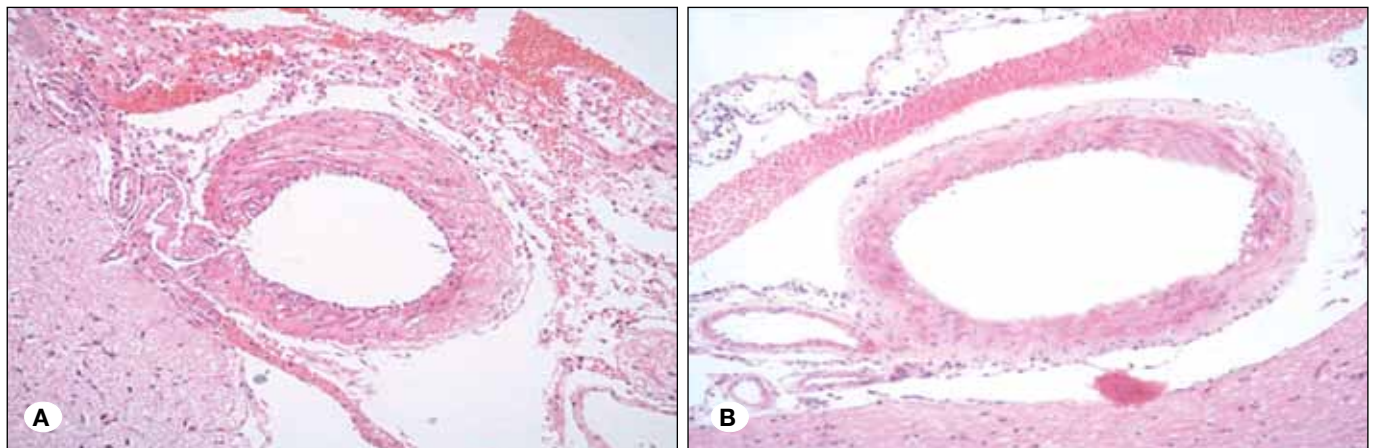


Figure 1: A) Basilar artery after SAH induction. Cross-sectional appearance of the H&E stained basilar artery under 20x magnification **B)** Basilar artery after SAH induction+L-carnitine treatment. Cross-sectional appearance of the H&E stained basilar artery under 20x magnification.

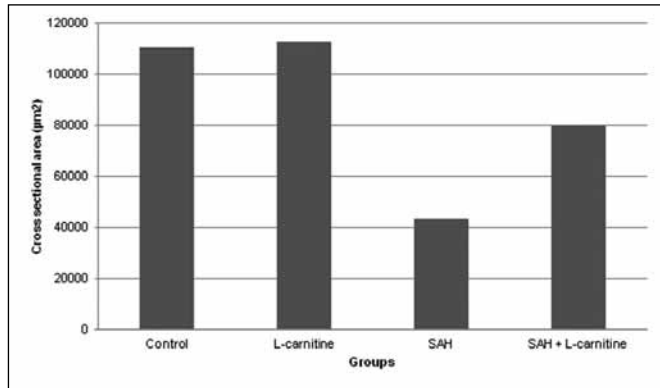


Figure 2: Mean cross sectional areas in μm^2 .

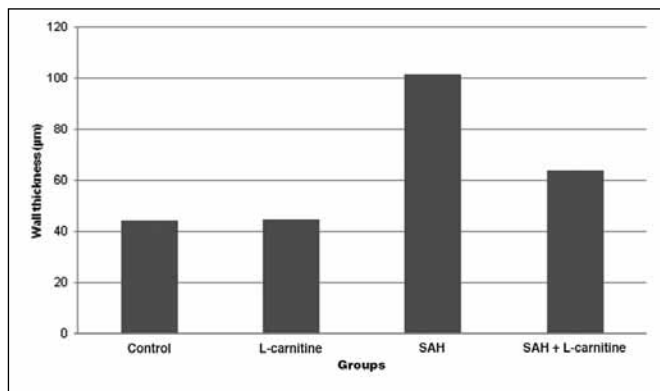


Figure 3: Mean vessel wall thicknesses in μm .

major differences of L-carnitine is its endogenous amino acid character. It has been used as a dietary supplement for many years. On the other hand, it is also used in clinical and experimental studies of systemic diseases.

In this study, we used cisternal blood injection method to induce cerebral vasospasm in the basilar artery of New Zealand white rabbits. This method is one of the most accepted cerebral vasospasm models since 1977 (17).

Two parameters, consisting of the area of the basilar artery lumen and wall thickness of the basilar artery, were chosen to show the effectiveness of the cisternal injection on vasospasm and to evaluate the results of treatment. Also the pathologist's blind assessment of the pathological sections was correlated with the parametric results.

We used potent antioxidant L-carnitine (11) in this study. We have demonstrated that SAH+L-carnitine group had a significantly greater cross-sectional area than the SAH-only group. We also showed that the SAH+L-carnitine group had a significantly thinner arterial wall thickness than the SAH-only group meaning that L-carnitine has a significant effect on early vasospasm after experimental SAH in rabbits.

Calcium channel blockers were used in experimental and clinical studies to prevent and treat vasospasm after SAH. However, the systemic hypotensive effect of calcium channel

blockers limits their usage in the perivasospasm period. Their vasodilator effect on non-affected vessels may cause blood diversion to normal brain tissue and this functional shunt-like perfusion may reduce the perfusion of the affected brain tissue distal to vasospastic vessels. Selective intraarterial application of nimodipine has also been demonstrated for the treatment of vasospasm, but it needs selective cerebral angiography, which may be a very useful method to overcome vasospasm during angiographic procedures. This seems to be difficult for clinical conditions (10).

Triple-H therapy is considered as the most effective treatment of cerebral vasospasm. Volume load causing hypertension and hemodilution forces the erythrocytes through the narrowed arterial lumen and also forces the vessel to enlarge mechanically. With the cardiac problems that may occur during the treatment, tendency to cerebral edema makes it a critical treatment modality.

CONCLUSION

It is clear that more research is necessary for defining the definite pathogenesis of cerebral vasospasm. In our study, we have demonstrated that L-carnitine is potentially beneficial on the resolution of cerebral vasospasm following SAH. Therefore, L-carnitine is a candidate for clinical trials in the treatment of cerebral vasospasm.

ACKNOWLEDGEMENT

This study was conducted as the graduation thesis of neurosurgery of the leading author (Ahmet Soyer) under the supervision of the senior author (Kamil Öge) at Hacettepe University, Medical School, Department of Neurosurgery, Microsurgery Laboratory.

REFERENCES

- Asano T: Oxyhemoglobin as the principal cause of cerebral vasospasm: A holistic view of its actions. *Crit Rev Neurosurg* 9(5): 303-318, 1999
- Atalay B, Caner H, Cekinmez M, Ozen O, Celasun B, Altinors N: Systemic administration of phosphodiesterase V inhibitor, sildenafil citrate, for attenuation of cerebral vasospasm after experimental subarachnoid hemorrhage. *Neurosurgery* 59(5): 1102-1108, 2006
- Benvenga S, Ruggeri RM, Russo A, Lapa D, Campenni A, Trimarchi F: Usefulness of L-carnitine, a naturally occurring peripheral antagonist of thyroid hormone action, in iatrogenic hyperthyroidism: A randomized, double-blind placebo-controlled clinical trial. *J Clin Endocrinol Metab* 86(8): 3579-3594, 2001
- Carrero JJ, Grimble RF: Does nutrition have a role in peripheral vascular disease? *Br J Nutr* 95(2): 217-229, 2006
- Cavallini G, Modenini F, Vitali G, Koverech A: Acetyl-L-carnitine plus propionyl-L-carnitine improve efficacy of sildenafil in treatment of erectile dysfunction after bilateral nerve-sparing radical retropubic prostatectomy. *Urology* 66(5): 1080-1085, 2005

6. Crowley RW, Medel R, Kassell NF, Dumont AS: New insights into the causes and therapy of cerebral vasospasm following subarachnoid hemorrhage. *Drug Discov Today* 13(5-6): 254-260, 2008
7. DiNicolantonio JJ, Lavie CJ, Fares H, Menezes AR, O'Keefe JH: L-carnitine in the secondary prevention of cardiovascular disease: Systematic review and meta-analysis. *Mayo Clin Proc* 88(6): 544-551, 2013
8. Dusick JR, Gonzalez NR: Management of arterial vasospasm following aneurysmal subarachnoid hemorrhage. *Semin Neurol* 33(5): 488-497, 2013
9. Ecker A, Riemenschneider PA: Arteriographic demonstration of spasm of the intracranial arteries, with special reference to saccular arterial aneurysms. *J Neurosurg* 8(6): 660-667, 1951
10. Firat MM, Gelebek V, Ozer HS, Belen D, Firat AK, Balkanci F: Selective intraarterial nimodipine treatment in an experimental subarachnoid hemorrhage model. *AJNR Am J Neuroradiol* 26(6): 1357-1362, 2005
11. Gulcin I: Antioxidant and antiradical activities of L-carnitine. *Life Sci* 78(8): 803-811, 2006
12. Head KA: Peripheral neuropathy: Pathogenic mechanisms and alternative therapies. *Altern Med Rev* 11(4): 294-329, 2006
13. Koliass AG, Sen J, Belli A: Pathogenesis of cerebral vasospasm following aneurysmal subarachnoid hemorrhage: Putative mechanism and novel approaches. *J Neurosci Res* 87(1): 1-11, 2009
14. Pettegrew JW, Levine J, McClure RJ: Acetyl-L-carnitine physical-chemical, metabolic, and therapeutic properties: Relevance for its mode of action in Alzheimer's disease and geriatric depression. *Mol Psychiatry* 5(6): 616-632, 2000
15. Scafidi S, Racz J, Hazelton J, McKenna MC, Fiskum G: Neuroprotection by acetyl-L-carnitine after traumatic injury to the immature rat brain. *Dev Neurosci* 32(5-6): 480-487, 2010
16. Sinclair S: Male infertility: Nutritional and environmental considerations. *Altern Med Rev* 5(1): 28-38, 2000
17. Svendgaard NA, Edvinsson L, Owman C, Sahlin C: Increased sensitivity of the basilar artery to norepinephrine and 5-hydroxytryptamine following experimental subarachnoid hemorrhage. *Surg Neurol* 8(3): 191-195, 1977
18. Titova E, Ostrowski RP, Zhang JH, Tang J: Experimental models of subarachnoid hemorrhage for studies of cerebral vasospasm. *Neurol Res* 31(6): 568-581, 2009
19. Weir B, Grace M, Hansen J, Rothberg C: Time course of vasospasm in man. *J Neurosurg* 48: 173-178, 1978