

MAGNETIC RESONANCE IMAGING OF FORAMINAL AND EXTRAFORAMINAL LUMBAR DISC HERNIATIONS

Tülay Keskin M.D., Tayfun Öztürk M.D., Hüsamettin Sargın M.D., Dilşat Mucuk M.D.,

BETEMAR Sağlık Tesisleri, Ankara-TÜRKİYE

Turkish Neurosurgery 2 : 135 - 138, 1992

SUMMARY

During period of 4 months, (November 1991-February 1992) lumbar magnetic resonance (MR) examinations were performed on 418 patients. 220 were found to have lumbar disc herniation, 19 (8.63 %) of which were diagnosed as having lateral disc herniation: 17 disc herniation extending into the neural foramen (7.73 %) and 2 were extraforaminal (0.9 %) surgical correlations were available for 11 Accurate diagnosis was achieved in 10 cases (90.9 %); 9 being foraminal and MR diagnosis of foraminal disc 1 extraforaminal. One case with an MR diagnosis of foraminal disc hernia was found at surgery to be a conjoined root. In 6 of the 17 foraminal disc herniations, the herniated disc was fragmente with upward migration, 2 were confirmed surgically, the other 4 were treated conservatively. In all cases, axial and sagittal T1 and sagittal fast images were obtained. Foraminal herniation diagnosed in axial was and sagittal images. Differentiation of the disc fragment from the nerve root was possible only with sagittal MR images. MR was useful in the diagnosis of the 2 extraforaminal disc herniations with the sagittal view being most helpful.

KEY WORDS

Magnetic resonance imaging, lateral lumbar disc herniation, foraminal lumbar disc herniation, spine.

INTRODUCTION

Lateral disc herniation may be purely intraforaminal, purely ekstraforaminal or mixed. These herniations cause nerve root compression beyond the termination on the root sleeves, which makes myelography ineffective in detecting such lateral compression (accuracy rate 12.5 %) (8). There are reports of accurate diagnosis of foraminal or of extraforaminal herniations with discography enhanced CT in 93.8 % of cases (8). The accuracy rates in detecting lateral disc herniations with discography and CT and/or myelography-enhanced CT are 37.5 % and 50 % respectively (8). Assessing the exact location of the herniation is an important criterion for surgeons. In this study, we evaluate MR, a non invasive technique, for imaging lateral disc herniations.

MATERIALS AND METHODS

During a period of 4 months, with MR imaging 19 patients were diagnose as lateral lumbar disc herniation. There were 11 men and 8 women, from 25 to 63 years old (mean 54 years). All patients presented with persistent radiculopathy: L3-4 radiculopathy in 7 cases (36.8 %), L4-5 in 8 cases (42.1%), and L5-S1 in 4 cases (21 %). Three of the cases were imaged for evaluation of suspected postoperative residue or recurrence.

MR was performed on a 0.5 T magnet (MR Max Plus GE) with surface coil. We used 96x224 and 224x128 matrix size for reconstruction with a 25-20 cm field-of-view and 5-7mm slice thickness. Spin-echo sequence was performed with T1-weighted (TR 500ms, TE 25ms) and fast (TR 600ms, TE 30ms, with flip angle of

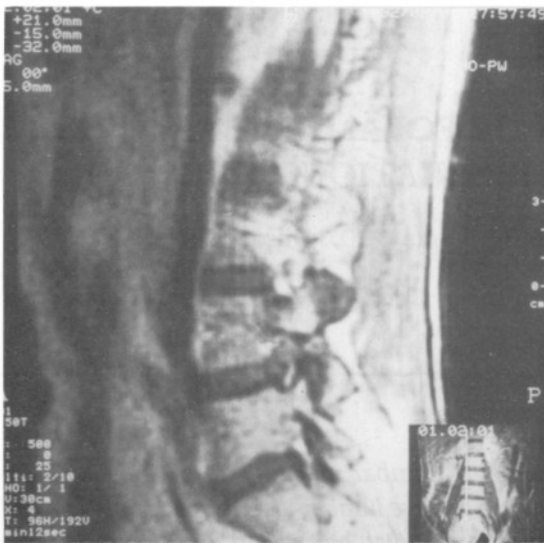

Fig. 1 : Sagittal image. The nerve root superior to the herniated disc is seen at L4-5 level.

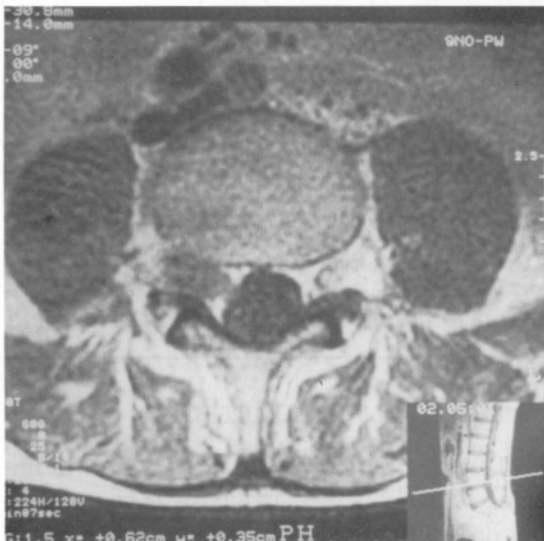

Fig. 2 : Axial image. A fragmentary disc hernia is seen on the right at L4-5 level.

30 degrees) images. In each case, T1-weighted images were obtained in the sagittal and axial planes, and fast images in the sagittal plane. The location of the herniated disc was defined in relation to the facet joints and the vertebral body on the axial images, and to the nerve root within the foramen on the sagittal images. An intravenous infusion of gadolinium diethylenetriamine pentaacetic acid (Gd-DTPA) (Schering, F.R.G.) was performed in 5 cases. 3 of which were operated for disc herniation before

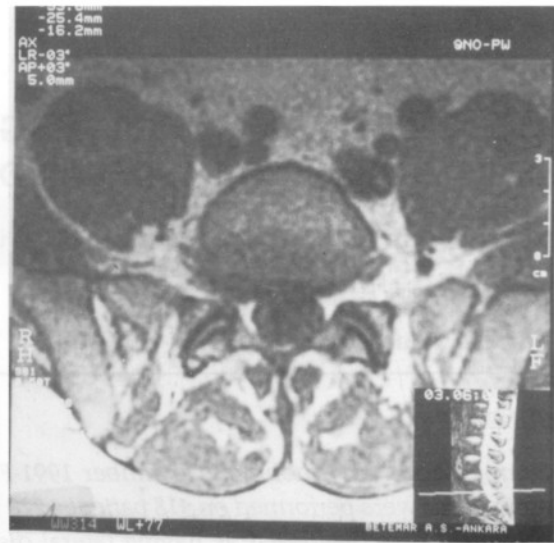


Fig. 3 : T1-weighted axial image. Foraminal disc hernia on the right at L5-S1 level.

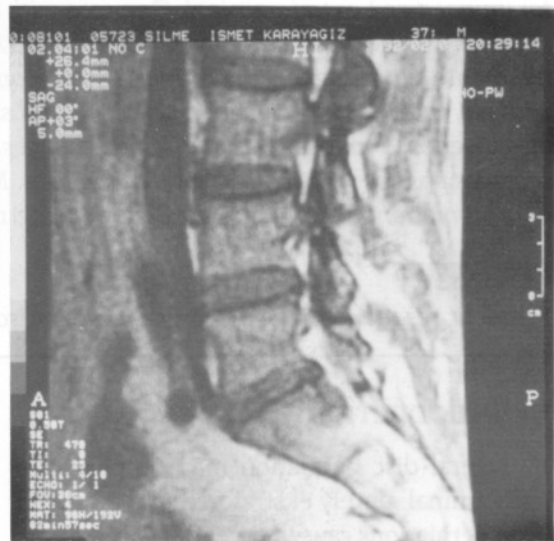

Fig. 4 : T1-weighted sagittal image. The same case as in Fig3.

MR examination (an indication for contrast use). In the other 2 patients, a contrast agent was used to exclude an enlarged nerve root or a neurinoma.

11 Patients underwent surgery and 8 patient were managed conservatively.

RESULTS

Of the 17 patients with an MR diagnosis of foraminal disc herniation, 10 were operated on

and 9 were confirmed surgically to be foraminal. The other was found to be a conjoined root. Patients were treated conservatively.

In 6 cases with a diagnosis of foraminal disc herniation, upward migration of the disc fragment was observed. Separation between the migrated disc fragment and the nerve root was best assessed on T1-weighted sagittal images. Two cases were operated and confirmed surgically. Others were treated conservatively. In two cases herniation was clearly identified with sagittal MR images, because the herniations were too far lateral. In these cases, the relationship of the herniated disc and the nerve root could be analyzed only on the axial views and were diagnosed as extraforaminal herniations. Of these, one was confirmed surgically and one was treated conservatively.

In two cases, intravenous gadolinium DTPA was used to exclude an enlarged nerve root or neurinoma, and was decided they were herniated disc as there was no contrast enhancement.

DISCUSSION

The incidence of lateral disc herniations varies from 1 to 11.7 % (1,6,10). In our study we found it to be 19 out of 220 cases (8.63 %).

CT features of lateral disc herniations are nonspecific and a differential diagnosis between neural tumours, metastatic disease, lymphoma (9), conjoined root sheath abnormality (4), arachnoid diverticula, perineural cyst, and retro peritoneal tumour (2). Is necessary.

Discography-enhanced computed tomography is found to be superior to alone by virtue of its enhancement of the foraminal disc fragment (5). However, false-negative discography-enhanced CT may occur in the presence of disc disease when no communication exists between the fragment and the disc centre (11).

MR has been found to be useful in the diagnosis of extraforaminal disc herniations with the sagittal view being most helpful especially when an intraforaminal component of the herniation is present. There are reports

that an angled coronal view is highly accurate in showing nerve root compression and in delineation of the disc fragment, especially when the herniated disc is extremely far lateral (5).

In this study we demonstrated that extraforaminal and foraminal disc herniations could be shown by obtaining axial and sagittal plane images. We also showed that in sagittal MR images a distinction could be made between the herniated disc and the nerve root, and in axial planes MR allows assessment of the exact location of the extraforaminal disc herniation in relation to the facet joints and the pedicles.

In a review of the literature indicates some articles that report the enlargement of foraminal veins as responsible for false-positive cases of foraminal disc herniations in cervical (3), thoracic (7) and lumbar regions (5). We believe that use of flow-sensitive sequences contrast enhancement may aid the diagnosis. Flow-sensitive-sequences may be added to the protocol in every MR-diagnosed extraforaminal disc herniation.

The disc fragment may be misdiagnosed as enlarged nerve root. Posterior herniations have predilection the lower lumbar levels but for lateral herniations are seen in the L3-4 level with more often higher frequency; 7 cases out of 19 (36.8 %).

In conclusion we can say:

- a) Foraminal and extraforaminal disc herniations are rare, and their diagnosis is difficult with methods other than MR imaging.
- b) MR shows the relationship between the herniated disc and the nerve root.
- c) MR is useful in to differentiation of herniated disc and neural tumours.
- d) MR shows the location of the disc herniation with high accuracy and enables surgeon to choose the site of approach.

Correspondence: Dr.Tülay Keskin
BETEMAR Sağlık Tesisleri A.Ş.
Ziya Gökalp Cad. 30/A
Kızılay Ankara, TÜRKİYE
Tel: (4) 4338230 (6 Hat) Fax: 431 71 36

REFERENCES

1. Abdullah AF, Ditto EW, Byrd EB, et al: Extreme Lateral Lumbar Disc Herniations. Clinical Syndrome and Special Problems of Diagnosis. *J Neurosurg* 41:229-234, 1974
2. Eckardt JJ, Kaplan DD, Batzdorf U, Dawson EG: Extraforaminal Disc Herniation Simulating Retroperitoneal Neoplasm. *J Bone Joint Surg (Am)* 67: 1275-7, 1985
3. Flannigan BD, Lufkin RB, Mc Glade C, et al: MR Imaging of the Cervical Spine: Neurovascular Anatomy. *AJR* 148: 785-90, 1987
4. Gado M, Patel J, Hodges FJ III: Lateral Disc Herniations into the Lumbar Intervertebral Foramen: Differential Diagnosis. *AJNR* 4: 598-600, 1983
5. Greniere N: MR Imaging and Extraforaminal Lumbar Disc Herniations. *Journal of Computer Assisted Tomography* 14(2): 243-249, 1990
6. Novetsky GJ, Berlin L, Epstein AJ et al: The Extraforaminal Herniated Disc: detection by Computed Tomography. *AJNR* 3: 363-365, 1982
7. Parizel PM, Rodesch G, Baleriaux D, et al: Gd-DTPA-enhanced MR in Thoracic Disc Herniations. *Neuroradiology* 31: 75-9, 1989
8. Roger P, Jackson MD, James J, et al: Foraminal an Extraforaminal Lumbar Disc Herniation: Diagnosis and Treatment. *Spine* 12: 577-582, 1986
9. Schbiger O, Valavanish A, Hollman J: Computed Tomograph of the Intervertebral Foramen. *Neuroradiology* 26: 439-44, 1984
10. Williams AL, Haughton VM, Daniels DL, CT Recognition of Lateral Lumbar Disc Herniation. *AJR* 139: 345-347, 1982
11. Yasuma T, Ohno R, Yamauchi Y.: False-negative Lumbar Discograms. Correlation of Discographic and Histological Findings in Postmortem and Surgical Specimens. *J Bone Joint Surg (Am)* 70: 1279-205, 1988