



DOI: 10.5137/1019-5149.JTN.12158-14.4

Received: 23.07.2014 / Accepted: 13.05.2015

Published Online: 16.02.2016

Original Investigation

Comparison of Vertebroplasty Versus Vertebral Perforation for the Treatment of Acute Vertebral Compression Fractures

Kunio YOKOYAMA¹, Masahiro KAWANISHI¹, Makoto YAMADA¹, Hidekazu TANAKA¹, Yutaka ITO¹, Shinji KAWABATA², Toshihiko KUROIWA²

¹Takeda General Hospital, Department of Neurosurgery, Kyoto, Japan

²Osaka Medical College, Department of Neurosurgery, Takatsuki, Osaka, Japan

ABSTRACT

AIM: The efficacy of vertebroplasty on acute vertebral compression fractures (VCFs) has not yet been established. This study, focusing on patients with acute VCFs, aims to compare therapeutic effects between vertebroplasty and vertebral perforation without cement injection.

MATERIAL and METHODS: Fifty-five patients with single painful VCFs were assigned to undergo vertebroplasty (Vertebroplasty group; 28 patients) or vertebral perforation (Perforation group; 27 patients). Analgesic effects before and after surgery were compared between 2 groups. Furthermore, the frequency of new VCFs during the follow-up period was compared.

RESULTS: In both groups, the visual analog scale (VAS) scores markedly decreased immediately after surgery and remained low until 90 days after surgery ($p < 0.05$). However, in the Perforation group, the analgesic effect from postoperative day 7 to 90 was significantly lower in patients with vertebral mobility before surgery than those without mobility ($p < 0.05$). New fractures after surgery occurred in 12 (42.9%) of the 28 patients in the Vertebroplasty group and 8 (29.6%) of the 27 patients in the Perforation group ($p = 0.054$).

CONCLUSION: In acute VCFs, vertebroplasty exerts a marked analgesic effect, which does not differ much from that of vertebral perforation without cement injection. Considering the risk of new postoperative fractures, the application of bone cement infusion should be carefully considered in patients with acute VCF.

KEYWORDS: Acute vertebral compression fracture, Vertebral perforation procedure, Vertebroplasty

INTRODUCTION

Percutaneous vertebroplasty for painful vertebral compression fractures (VCFs) is performed worldwide mainly for patients in the chronic phase because this procedure has effects on immediate pain relief and improvement in the patients' activities of daily living (ADL) (7,13-16,21,25). However, there is very little evidence regarding the application of vertebroplasty to acute VCFs at present, and vertebroplasty is not an established treatment procedure (6,11,12,16,20,21,23). As vertebroplasty was compared to conservative therapy in most of the previous comparative studies on the usefulness

of vertebroplasty, a possible placebo effect of vertebroplasty could not be ruled out (6,11,16,20,21). Firanescu et al. are conducting a randomized controlled trial targeting patients with acute VCFs to compare vertebroplasty and a sham procedure without cement injection, and their trial has not yet reached a conclusion (12).

Vertebral perforation for VCFs is a procedure in which an affected vertebral body is perforated but not injected with bone cement (26,27). This procedure is contrived based on a hypothesis that fracture pain is caused by hyper-intraosseous pressure, and the aim of the procedure is to relieve pain by



Corresponding author: Kunio YOKOYAMA

E-mail: neu100@poh.osaka-med.ac.jp

perforation of the bone marrow by decreasing intraosseous pressure. The difference between vertebroplasty and vertebral perforation is the existence of cement injection alone. This enables not only comparative assessment of the utility of vertebral perforation, but also evaluation of the validity of the application of bone cement infusion. We have investigated the therapeutic efficacy in both treatments focusing on chronic VCF patients mainly. However, there may be different pathologic conditions between acute and chronic VCF patients. Some researchers proposed that movement-evoked pain due to acute VCFs may be associated with increased intraosseous pressures (2,3,10). We hypothesized that vertebral perforation will exert a remarkable analgesic effect for patients with acute painful VCF. This study, focusing on patients with painful acute VCFs, aims to compare therapeutic effects between vertebroplasty and vertebral perforation.

■ MATERIAL and METHODS

Our institutional review board and ethics committee approved the study protocol. Before surgery, we obtained informed consents from all patients after a full explanation of the surgical procedure.

Subjects

We assessed 55 patients with single painful acute VCF who had not responded to conservative medical treatment in an orthopedic clinic. All fractures were osteoporotic and not due to high energy traumas.

From 2007 to 2010, these patients were treated with either percutaneous vertebroplasty or vertebral perforation procedure at our institution. The first 28 patients were treated with percutaneous vertebroplasty (Vertebroplasty group); the last 27, with vertebral perforation procedure (Perforation group). We reviewed clinical and imaging data from these patients retrospectively.

The Perforation group included 23 women and 4 men. The mean age was 77 years (range 61-100 years). The Vertebroplasty group included 26 women and 2 men. The mean age was 79 years (range 69-89 years). Patients were evaluated before surgery on the basis of a complete history, physical examination, and neuroimaging evaluations (X-ray, Computed tomography (CT), and Magnetic resonance imaging (MRI)).

The presence of vertebral instability of the affected vertebra before surgery was assessed with dynamic radiography. We measured Vertebral body height (VBH) to assess vertebral mobility. We determined the vertebral mobility was present if there was a little difference in vertebral body height between lateral flexion and extension (Figure 1) (27).

Inclusion and Exclusion Criteria

Inclusion criteria: 1) VCF with 0%–90% loss of VBH on x-ray of the spine; 2) severe back pain refractory to medication for 2~6 weeks; 3) Visual analog scale (VAS) score of 5 or higher, tapping pain at the spinal process of the fractured vertebral body; and 4) on MRI, the affected vertebral body showed a high intensity on STIR imaging and low signal intensity on T1W imaging.

Exclusion criteria: 1) back pain for more than 6 weeks, 2) back pain associated with more than 2 VCFs, 3) infection, 4) secondary osteoporosis, 5) inability to give informed consent, 6) cardiopulmonary dysfunction, 7) painless VCF, 8) metastatic spinal tumor, and 9) neurologic symptoms.

Surgical Procedures

Vertebral perforation

We reported the surgical procedure of percutaneous vertebral body perforation previously (26,27). All patients were operated on by a single surgeon, who previously performed more than

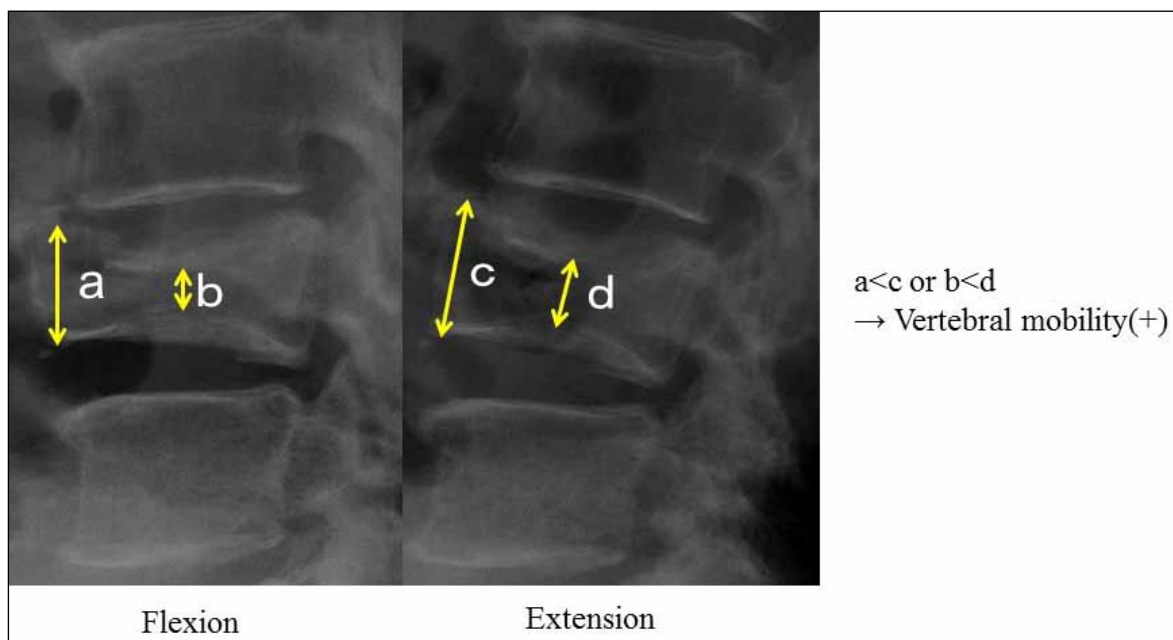


Figure 1: Preoperative lateral radiographs of a patient with VCF with vertebral instability. The collapsed vertebral body shows dynamic mobility. The vertebral height increased with extension stress.

700 vertebroplasties. Surgery was performed in the prone position under local anesthesia. 13G biopsy needles were inserted via bilateral transpedicular routes into the anterior third of the vertebral body under C-arm guidance. The effusion in the vertebral body was aspirated. Next, contrast medium was injected, and the position of the each needle, its communication with vertebral veins, and the efflux pattern of the contrast medium were then confirmed. Finally saline was irrigated via each needle. Surgery was completed by withdrawing needles (Figure 2B).

Vertebroplasty

Surgery was performed in the prone position under local anesthesia. A 13G biopsy needle was inserted via a unilateral transpedicular route. Contrast medium was injected through the needle and A polymethylmethacrylate (PMMA) mixture was injected into the vertebral body. Surgery was completed by withdrawing the needle. During cement injection, fluoroscopic monitoring was used in biplanes (Figure 2A).

Outcome Evaluation

Pain (VAS score) was evaluated before and at 2 days (next day), 7 days, and 90 days after surgery. ADL were evaluated before the surgery and 90 days after surgery 5-point scale (grade 0=complete independence; grade 1=light assistance and being able to walk with a stick; grade 2=moderate assistance and needing a wheelchair for locomotion; grade 3=major assistance and mostly staying in bed; and grade 4=a bed-

ridden state and needing total assistance) (27). We compared postoperative changes in VAS and ADL scores between the vertebroplasty and perforation groups. Furthermore, in the perforation group, we compared scores between patients with and without vertebral instability. Then, the frequency of new fractures after surgery was compared between the 2 groups. The presence of new fractures was determined by the signal change on STIR imaging and T1 weighted imaging in other vertebral bodies.

Statistical Analysis

Statistical analyses were performed by Stat View 5.0 software. For comparison of factors between 2 groups, we applied the Mann-Whitney U test or the Fisher exact test. All data are presented as mean ± standard deviation, and differences were considered statistically significant at a p <0.05.

RESULTS

The mean follow up periods were 28.2 months in vertebroplasty group and 19.6 months in perforation group, respectively. The preoperative demographic data for both groups are shown in Table I. There were no significant differences in baseline characteristics between the 2 groups (p<0 .05). Preoperative dynamic radiography revealed mobility of vertebral bodies in 6 vertebroplasty group (21%) and 9 perforation group (33%) patients. Figure 3A and Table II shows VAS score changes during follow-up in both groups. No significant difference

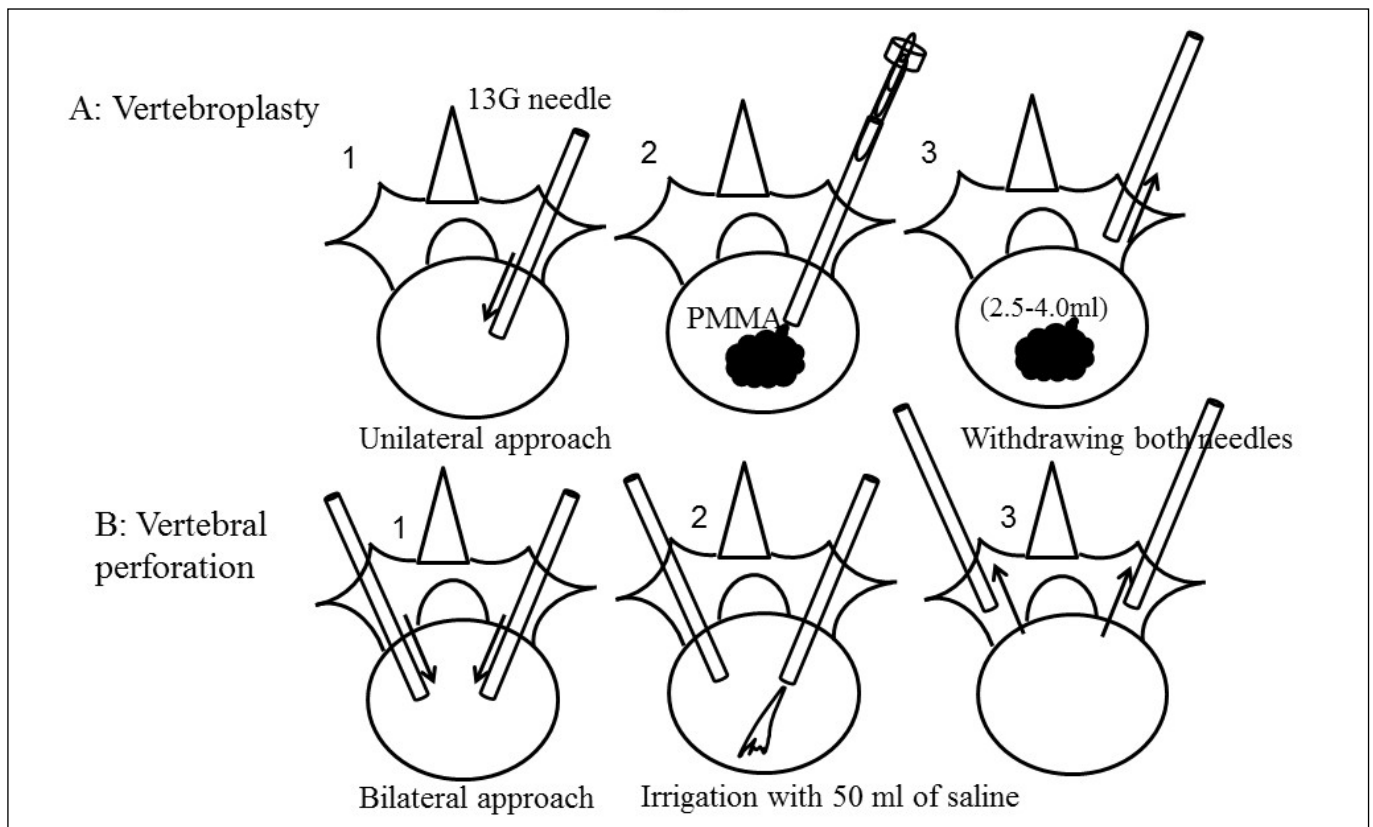


Figure 2: Illustrated procedures of Vertebroplasty and vertebral perforation. (A: Vertebroplasty, B: Vertebral perforation).

in postoperative VAS scores was observed between the 2 groups during 90 days after surgery ($p>0.05$). In both groups, VAS scores were markedly decreased on the day after surgery. In the perforation group, the analgesic effect on

postoperative day 7 and onward was lower in patients with vertebral mobility than those without ($p<0.05$) (Figure 3B, Table II). The postoperative ADL scores significantly improved on postoperative day 90 in the perforation group as compared

Table I: Baseline Characteristics of Patients Treated for VCF

	Vertebroplasty group	Perforation group	p-value
No. of patients	28	27	
Mean age (years)	79±6.5	77±7.3	0.16
No. of women (%)	26 (93%)	23(85%)	0.21
Preoperative VAS	7.64±1.3	7.14±1.7	0.27
Mean interval (days)	22.5±6.9	25.8±9.5	0.16
Treated level (T11-L2)	16/28(57%)	20/27(74%)	0.13
Percent compression (%)	30.9±25	34.1±23	0.69
Preop. mobility of fracture	6/28 (21%)	9/27(33%)	0.18

Table II: Comparison of VAS and ADL score between Vertebroplasty group and Perforation group

		Vertebroplasty group	perforation group	p-value	Perforation group		p-value
					mobility (+)	mobility (-)	
VAS	preop.	7.64±1.3	7.14±1.7	0.27	6.88±2.3	7.25±1.5	0.92
	Day 2	1.89±2.2	2.58±2.5	0.30	4.57±3.3	1.89±1.8	0.11
	Day 7	1.65±1.9	2.90±2.7	0.10	5.50±3.0	1.79±1.6	0.015
	Day 90	1.96±2.1	2.94±3.1	0.38	4.75±3.5	1.80±2.1	0.041
ADL score	preop.	2.00±0.86	1.83±0.78	0.54	1.50±1.05	1.94±0.66	0.344
	Day 90	1.44±0.84	0.73±0.70	0.008	0.63±0.82	0.78±0.62	0.290
New VCFs (median follow)		12/28 (42.9%) (28.2 mon.)	8/27 (29.6%) (19.6 mon.)	0.054	2/9 (22.2%) (18.2 mon.)	6/18 (33.3%) (20.3 mon.)	0.338

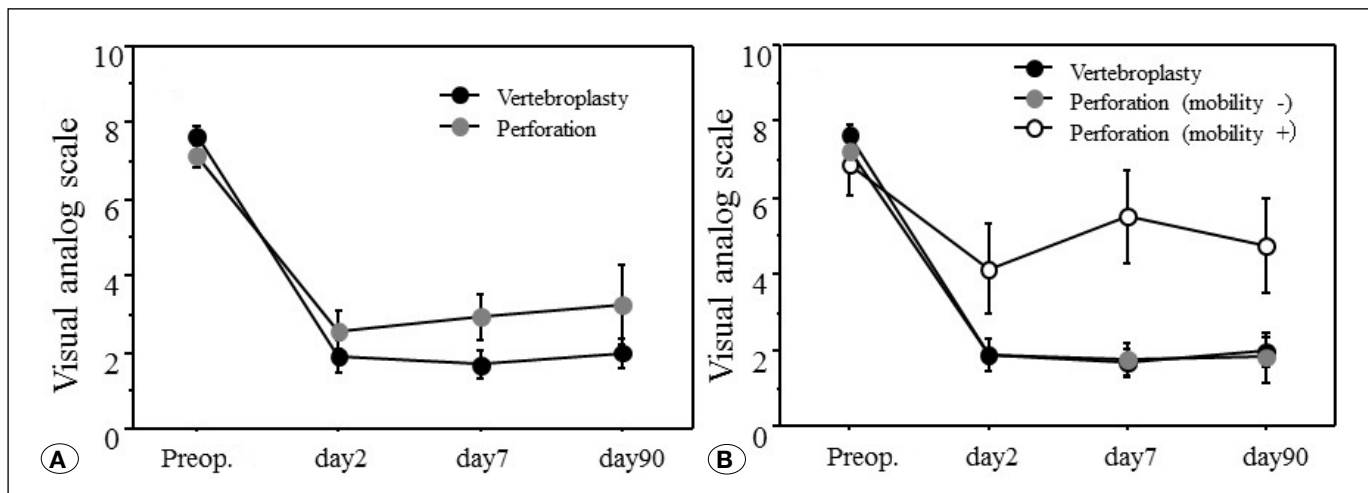


Figure 3: Comparison of changes in postoperative VAS scores of acute VCF patients during follow-up between the vertebral perforation and vertebroplasty groups.

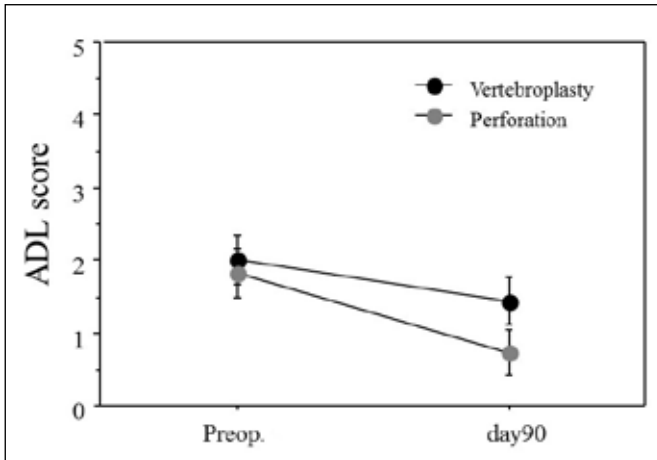


Figure 4: Comparison of changes in ADL scores of acute VCF patients during follow-up between the vertebral perforation and vertebroplasty groups.

with those in the vertebroplasty group (Figure 4, Table II, $p=0.008$). In the perforation group, there was no significant difference in the ADL scores on postoperative day 90 between patients with and without vertebral mobility ($p=0.29$). New fractures after surgery occurred in 12 (42.9%) of the 28 patients in the vertebroplasty group and 8 (29.6%) of the 27 patients in the perforation group. Although the incidence rate tended to be higher in the vertebroplasty group, no significant difference was observed between the 2 groups ($p=0.054$).

DISCUSSION

Some clinicians claim that the analgesic effect achieved by vertebroplasty for VCFs to be a placebo effect. As most previous studies compared the therapeutic effect of vertebroplasty with conservative therapy (6,11,16,20,21), these studies could not rule out the placebo effect of vertebroplasty. On the other hand, there are already many reports on complications associated with the use of bone cement in vertebroplasty (8,9,24). Thus, unless its true analgesic effect is demonstrated, the procedure cannot be considered as useful. In order to prove the benefits of vertebroplasty and to exclude the placebo effect, comparison to a control therapy from which patients to be treated expect pain relief is essential. Buchbinder et al. (7) and Kallmes et al. (13) conducted the first randomized studies comparing vertebroplasty and a sham procedure without cement injection in patients with chronic VCFs (7,13). However, both studies concluded that there was no difference in analgesic effects between vertebroplasty and the sham procedure, and the usefulness of vertebroplasty was not demonstrated. In patients with acute VCFs, Firanescu et al. are currently conducting a randomized study comparing the analgesic effects between vertebroplasty and a sham procedure (VERTOS IV), and the results are awaited (12). Unlike chronic VCFs, there are always patients with acute VCFs whose pain is spontaneously relieved by conservative therapy. Thus, it seems extremely difficult to demonstrate the analgesic effect of vertebroplasty in patients with acute VCFs. Vertebral perforation, which we

used as the control therapy for vertebroplasty, is a treatment procedure that has conventionally been performed for pain relief in patients with long bone fractures, etc., based on the hypothesis that fracture pain is associated with intraosseous edema (1-5,10,17,18,22). We applied this procedure to VCFs in this study. The major difference between vertebral perforation and the sham procedures performed by Buchbinder et al. (7), Kallmes et al. (13), and Firanescu et al. (12), is that a vertebral body was perforated through the inside in vertebral perforation. Perforation to the inside of a vertebral body is considered to have effects on not only reduction of intraosseous pressure but also improvement of microcirculation, elimination of pain substances, etc (19). As all patients receive treatment with the expectation of obtaining pain relief, we consider that there is little difference in treatment-related placebo effects between the 2 procedures. In a study conducted in patients with chronic VCFs, we already demonstrated that the analgesic effect of vertebroplasty is significantly superior to that of vertebral perforation (26,27). While the analgesic effect of vertebroplasty was significantly superior to that of vertebral perforation especially in patients with vertebral mobility, we revealed that there was little difference between the procedures in patients without vertebral mobility despite a marked analgesic effect achieved by vertebroplasty (27). In other words, vertebroplasty exerted a marked analgesic effect in patients in the chronic phase regardless of the presence or absence of vertebral mobility, whereas the analgesic effect of vertebral perforation was lower in patients with vertebral mobility. In the present study focusing on acute VCFs, the analgesic effect of VP was also apparently lower in patients with instability in the perforation group, as shown in Figure 3B. However, no significant difference in analgesic effects was observed between vertebroplasty and vertebral perforation during 90 days after surgery. It seemed that the absence of difference between the 2 procedures was attributable to the smaller number of patients with vertebral mobility in the acute VCF cases compared to the chronic cases in terms of frequency. In fact, patients with vertebral mobility accounted for 55 (42.0%) of 131 subjects in the previous study that focused on those in the chronic phase mainly (27), whereas such patients accounted for 15 (27.3%) of 55 patients in the present study. The number of patients with vertebral mobility was apparently decreased in this study on acute VCFs. Occurrence of vertebral mobility associated with pseudarthrosis is a chronic change derived from vertebral osteonecrosis. There may be a problem with seeking patients with these conditions in those in the acute phase. While the inclusion criteria for patients with acute VCFs were set as those within 6 weeks after the occurrence in this study, results may greatly differ depending on the definition of the acute phase of VCF. Based on the above, although vertebroplasty exerts a substantial analgesic effect in acute VCFs, there is little difference between vertebroplasty and vertebral perforation without cement injection. Given the large number of reports on complications associated with cement injection, etc. (8,9,24), vertebroplasty is a procedure that should not be recommended without careful consideration. On the other hand, vertebral perforation exerts approximately the same analgesic effect as vertebroplasty and can also avoid complications associated with cement injection.

Thus, vertebral perforation can be an option for the treatment only for acute VCFs. However, because the analgesic effect of vertebral perforation is low in patients with vertebral mobility even among patients in the acute phase, the application of vertebral perforation should be carefully considered.

This study has some limitations. First, the sample size is small. Furthermore, the study is not randomized. The results may differ with a larger sample size. In our study, subjects were limited to patients treated for a single vertebral body in order to more accurately assess analgesic effects on treated vertebral bodies. If patients treated for multiple vertebral bodies are included as the study subjects, several vertebral bodies fractured at different times may exist in a single patient. We consider that this impairs the credibility of assessment in this study focusing on acute VCFs. Although this study was neither blinded nor randomized, vertebroplasty was performed for all patients in the first half of the study period, and vertebral perforation was performed for all patients in the second half. Because both procedures were performed for patients who were determined to be indicated for vertebroplasty in a conventional manner, the assignment to the treatment procedures was not biased. Finally, it is suggested that vertebral perforation may relieve intraosseous edema as described above. Because vertebral perforation may exert an analgesic effect through a mechanism different from that of vertebroplasty, it is not certain whether vertebral perforation can be compared with vertebroplasty on an equal footing.

■ CONCLUSION

In acute VCFs, vertebroplasty exerts a marked analgesic effect, which does not differ much from that of vertebral perforation without cement injection. Considering the risk of new postoperative fractures, the application of bone cement infusion should be carefully considered in patients with acute VCF.

■ REFERENCES

1. Arnoldi CC: Intraosseous hypertension and pain in the knee. *J Bone Joint Surg* 57:360–363, 1975
2. Arnoldi CC: Intraosseous hypertension a possible cause of low back pain. *Clin Orthop Relat Res* 115:30–34, 1976
3. Arnoldi CC: Intravertebral pressures in patients with lumbar pain. *Acta Orthop Scand* 43:109–117, 1972
4. Arnoldi CC: Venous engorgement and intraosseous hypertension in osteoarthritis of the hip. *J Bone Joint Surg* 54:409–421, 1972
5. Azuma H: Intraosseous pressure as a measure of hemodynamic changes in bone marrow. *Angiology* 15:396–406, 1964
6. Boonen S, Van Meirhaeghe J, Bastian L, Cummings SR, Ranstam J, Tillman JB, Eastell R, Talmadge K, Wardlaw D: Balloon kyphoplasty for the treatment of acute vertebral compression fractures: 2-year results from a randomized trial. *J Bone Miner Res* 26(7):1627–1637, 2011
7. Buchbinder R, Osborne RH, Ebeling PR, Wark JD, Mitchell P, Wriedt C, Graves S, Staples MP, Murphy B: A randomized trial of vertebroplasty for painful osteoporotic vertebral fractures. *N Engl J Med* 361:557–568, 2009
8. Chen YJ, Tan TS, Chen WH, Chen CC, Lee TS: Intradural cement leakage: A devastatingly rare complication of vertebroplasty. *Spine* 31:379–382, 2006
9. Cosar M, Sasani M, Oktenoglu T, Kaner T, Ercelen O, Kose KC, Ozer AF: The major complications of transpedicular vertebroplasty. *J Neurosurg Spine* 11:607–613, 2009
10. Esses SI, Moro JK: Intraosseous vertebral pressures. *Spine* 17:S155–159, 1992
11. Farrokhi MR, Alibai E, Maghami Z: Randomized controlled trial of percutaneous vertebroplasty versus optimal medical management for the relief of pain and disability in acute osteoporotic vertebral compression fractures. *J Neurosurg Spine* 14(5):561–569, 2011
12. Firanescu C, Lohle PN, de Vries J, Klazen CA, Juttman JR, Clark W, van Rooij WJ; VERTOS IV Study Group: A randomised sham controlled trial of vertebroplasty for painful acute osteoporotic vertebral fractures (VERTOS IV). *Trials* 12:93, 2011
13. Kallmes DF, Comstock BA, Heagerty PJ, Turner JA, Wilson DJ, Diamond TH, Edwards R, Gray LA, Stout L, Owen S, Hollingworth W, Ghdoke B, Annesley-Williams DJ, Ralston SH, Jarvik JG: A randomized trial of vertebroplasty for osteoporotic spinal fractures. *N Engl J Med* 361:569–579, 2009
14. Kallmes DF, Comstock BA, Gray LA, Heagerty PJ, Hollingworth W, Turner JA, Stout L, Jarvik JG: Baseline pain and disability in the Investigational Vertebroplasty Efficacy and Safety Trial. *AJNR Am J Neuroradiol* 30:1203–1205, 2009
15. Kawanishi M: Vertebroplasty for vertebral compression fracture: Indications, technique, clinical application. *Brain Nerve* 61:663–666, 2009
16. Klazen CA, Lohle PN, de Vries J, Jansen FH, Tielbeek AV, Blonk MC, Venmans A, van Rooij WJ, Schoemaker MC, Juttman JR, Lo TH, Verhaar HJ, van der Graaf Y, van Everdingen KJ, Muller AF, Elgersma OE, Halkema DR, Fransen H, Janssens X, Buskens E, Mali WP: Vertebroplasty versus conservative treatment in acute osteoporotic vertebral compression fractures (VERTOS II): An open-label randomised trial. *Lancet* 376:1085–1092, 2010
17. Lemperg RK: The significance of intraosseous pressure in normal and disease states with special reference to the intraosseous pain engorgement syndrome. *Clin Orthop Relat Res* 136:143–156, 1978
18. Ochia RS, Ching RP: Internal pressure measurements during burst fracture formation in human lumbar vertebrae. *Spine (Phila Pa 1976)* 27:1160–1167, 2002
19. Ogihara M: Core decompression of vertebral body for osteoporotic vertebral compression fracture. *Pain Clinic* 27:898–903, 2006
20. Rousing R, Andersen MO, Jespersen SM, Thomsen K, Lauritsen J: Percutaneous vertebroplasty compared to conservative treatment in patients with painful acute or subacute osteoporotic vertebral fractures: Three-months follow-up in a clinical randomized study. *Spine (Phila Pa 1976)* 34(13):1349–1354, 2009

21. Rousing R, Hansen KL, Andersen MO, Jespersen SM, Thomsen K, Lauritsen JM: Twelve-months' follow-up in forty-nine patients with acute/semiacute osteoporotic vertebral fractures treated conservatively or with percutaneous vertebroplasty: A clinical randomized study. *Spine* 35: 478–482, 2010
22. Spencer DL, Ray RD, Spigos DG, Kanakis C Jr: Intraosseous pressure in the lumbar spine. *Spine* 6:159–161, 1981
23. Staples MP, Kallmes DF, Comstock BA, Jarvik JG, Osborne RH, Heagerty PJ, Buchbinder R: Effectiveness of vertebroplasty using individual patient data from two randomised placebo controlled trials: Meta-analysis. *BMJ* 343:d3952,2011
24. Trout AT, Kallmes DF: Does vertebroplasty cause incident vertebral fractures? A review of available data. *AJNR Am J Neuroradiol* 27:1397–1403, 2006
25. Voormolen MH, Mali WP, Lohle PN, Franssen H, Lampmann LE, van der Graaf Y, Juttmann JR, Janssens X, Verhaar HJ: Percutaneous vertebroplasty compared with optimal pain medication treatment: Short-term clinical outcome of patients with subacute or chronic painful osteoporotic vertebral compression fractures—the VERTOS study. *AJNR Am J Neuroradiol* 28:555–560, 2007
26. Yokoyama K, Kawanishi M, Yamada M, Tanaka H, Ito Y, Hirano M, Kuroiwa T: Comparative study of percutaneous vertebral body perforation and vertebroplasty for the treatment of painful vertebral compression fractures. *AJNR Am J Neuroradiol* 33(4):685–689, 2012
27. Yokoyama K, Kawanishi M, Yamada M, Tanaka H, Ito Y, Hirano M, Kuroiwa T: Validity of intervertebral bone cement infusion for painful vertebral compression fractures based on the presence of vertebral mobility. *AJNR Am J Neuroradiol* 34(1):228–232, 2013