



Fragmentation to Epidural Space: First Documented Complication of Gelstix™

Epidural Mesafeye Fragmantasyon: Gelstix™'in Dökümanite Edilen İlk Komplikasyonu

Emre DURDAG¹, Omer AYDEN¹, Serdal ALBAYRAK¹, Ibrahim Burak ATCI¹, Ercan ARMAGAN²

¹Elazığ Education and Research Hospital, Department of Neurosurgery, Elazığ

²Private Medical Park Hospital, Department of Neurosurgery, Elazığ

Presented in: 27th Annual Congress of Turkish Neurosurgical Society, poster presentation, 12-16 April 2013, Antalya, Turkey.

Corresponding Author: Emre DURDAG / E-mail: emredurdag@yahoo.com

ABSTRACT

The knowledge of minimal invasive spinal surgery has increased greatly in recent years. A current issue is the hydrogel implant inserted through nucleus pulposus. In this paper we present a case in which the hydrogel implant was found to be fragmented into the spinal canal at follow up. The patient was a 40-year-old female. She was examined at another clinic because of low back pain about four months ago, and a hydrogel implant was inserted at the L5-S1 level. She was admitted to our clinic due to severe radicular pain. Magnetic resonance imaging (MRI) showed a posterolateral annular tear only and she was explored microneurosurgically as she did not benefit from a foraminal injection. A fragmented hydrogel implant that compressed the spinal root was seen peroperatively and it was excised. Postoperatively the radicular complaints of the patient disappeared and she was discharged with total recovery. Although rare, complications causing compression of neural structures can be seen after placing implants into the disc. In this case, the assessment of the patient according to the clinical presentation and microsurgical exploration if necessary are important.

KEYWORDS: Gelstix™, Epidural space, Fragmentation

ÖZ

Son yıllarda minimal invaziv spinal cerrahide büyük bilgi birikimi kazanılmıştır. Güncel bir konu da nükleus içine yerleştirilen hidrojel implantlarıdır. Bu çalışmada daha önce başka bir klinikte hidrojel implantı konulan ancak takibinde implantı spinal kanala fragmente olan bir olgumuzu sunmak istedik. Kırk yaşında kadın hasta yaklaşık dört ay önce başka bir klinikte bel ağrısı nedeniyle tetkik edilmiş ve L5-S1 seviyesine hidrojel implantı konulmuş. Hastanın şiddetli radiküler ağrısı olması üzerine kliniğimize başvurdu. Sol bacağında yaklaşık 10 derecede Laseque testi müspetliği saptanan hasta tetkik edildi. Manyetik rezonans incelemesinde sadece sol L5-S1 posterolateral annuler yırtık saptanan ve foraminal enjeksiyondan rahatlamayan hasta mikroşürüjikal teknikle eksplore edildi. Peroperatif izlemde spinal kanala bası yapan fragmente hidrojel implantı görüldü ve eksize edildi. Post-operatif radiküler yakınması geçen hasta şifa ile taburcu edildi. Disk içi implant yerleştirilmesi sonrasında nadir de olsa nöral yapıları basılabilecek komplikasyonlar görülebilmektedir. Bu durumda hastanın klinik durumuna göre değerlendirilmesi ve gerekiyorsa mikroşürüjikal olarak eksploasyonu önemlidir.

ANAHTAR SÖZCÜKLER: Gelstix™, Epidural aralık, Fragmantasyon

INTRODUCTION

Low back pain is the second most frequent cause of work loss, and its global prevalence in the 20-50 years age group is 60% to 80% (3, 4). This pain usually ceases but can become chronic. The most common cause of chronic low back pain is degenerative disc disease (DDD), and environmental and genetic factors are accused. There are many studies related to DDD. In the degeneration process of the disc, it is proven that decline of pH in the disc and deterioration of disc perfusion together with impairment of type-2 collagen formation occurs and leads to diminished water content in the nucleus. This is followed by increased formation of type-1 collagen. The disc content becomes harder and inflexible, and neovascularization and reinnervation occurs in the annulus (1).

Treatment options include conservative and surgical approaches. Increased knowledge on DDD pathophysiology has accelerated the development of some minimally invasive percutaneous procedures that can affect degenerative process positively. Application of hydrogel implants to increase the amount of water in the disc space has become popular (3,4,5). In this article, we would like to present the first known complication of a hydrogel implant.

CASE REPORT

A 40-year-old female patient was examined after low back pain and severe radicular pain in her left leg. Her medical history was unremarkable except insertion of a hydrogel implant with the discography technique at the L5-S1 level at another hospital four months ago (Figure 1). She claimed that

she did not benefit from the procedure and was experiencing low back pain after surgery. Her neurological examination revealed a positive Laseque test in her left leg. There was significant weakness in plantar extension of the foot and diminished Achilles reflex. Magnetic resonance imaging (MRI) was normal except for a left paracentral hyperintense zone at the L5-S1 level. A trial of foraminal steroids provided no benefit. Surgical exploration was decided on due to the severe nature of the pain and absence of a significant radiological evidence that would explain it, and the patient was underwent microsurgery. Peroperatively, a hydrogel implant protruding from the annular tear was observed. The left S1 root was significantly compressed by the implant. The implant was excised in two fragments. Pain ceased immediately postoperatively and the patient was discharged without any problems (Figure 2A-D).

DISCUSSION

DDD affects 10-15 % of adults (10). Surgical treatment plays an important role in the management of this disease for which a wide range of treatment approaches are present. Although the main goal in the evolution of surgical treatment is to decrease neurological compression, surgery including stabilization and fusion of the mobile segment is applied afterwards. In order to protect the moving segment, total intervertebral discectomy and subsequent application of disc prosthesis or interbody cages, and addition of dynamic instrumentation techniques have been used. Despite the fast development of minimally invasive percutaneous lumbar instrumentation techniques, the need for general anesthesia in most of the approaches and unsatisfactory patient satisfaction have led to a search for new treatment techniques with less invasive percutaneous approaches (5).

Considering the pathophysiology of DDD, it can be hypothesized that increasing the amount of water in the nucleus could increase disc elasticity and decrease the complaints. Using implants in minimally invasive spinal surgery has therefore considered, as they were formerly used in plastic surgery, orthopedic surgery and gynecologic surgery.

Hydrogel is highly compatible with the surrounding tissue. Its application volume is low, it causes little inflammation, and it can absorb ten times more water than its own volume (4). Many studies have been performed before spinal application and the molecule has been developed. Many in vivo and in vitro studies by spinal applications of improved hydrogel implants are present, and it is concluded that hydrogel implants affect DDD prognosis positively, increase the amount of water in the disc, increase pH, increase lumbar ROM angles and are safe to insert (1,2,4,5,6,8,10). Subsequent to these studies, the developed hydrogels have been used in clinical practice and the presented trademark is Gelstix™.

Gelstix™ is indicated for patients who have adequate disc height (>3 mm) and black disc feature at MRI, and whose main complaint is axial discogenic pain when there is no

annular tear (10). It is inserted into the nucleus pulposus with the discography technique. After placement, it can absorb water 10-fold its weight in about 15 minutes (10). Although little is known about the implant, results of the studies so far show that the patient benefit is favorable (10). (10).

In the evaluation of the patient, it was found that Gelstix was placed in another clinic four months ago, but there was no improvement in axial low back pain. Due to severe radicular pain at follow up, the patient was explored microsurgically although there was no significant problem on MRI except the hiperintense zone on T2-weighted MRI scans. During the surgery with a classic posterior approach, it was seen that Gelstix™ had fragmented into the epidural space. This might have happened in two ways:

- 1: An implant which is placed correctly may come into the epidural space through a new annular tear. A correctly placed implant takes a high volume of water in a short time, and can hardly become fragmented in its former location.
- 2: An implant that is placed in the fibers of the annulus fibrosus (false location) may be due to a new or former annular tear by mobilisation as time passes.

We could not obtain the scopy images of the percutaneous intervention. Although MRI scans before the insertion of Gelstix™ did not exactly show a black disc on the level of L5-S1, there was loss of T2 signal at the disc space. Our preoperative MRI inspection did not show hyperintensity in the disc at the L5-S1 level that should be seen at the T2 sequence as a proof of increased hydration (10). Consequently, it is considered that the implant was incorrectly placed into the annulus fibers.

A few complications related to hydrogel usage as dura adhesive in neurosurgery have been reported (7,9). However, no complication related to Gelstix™ application has been

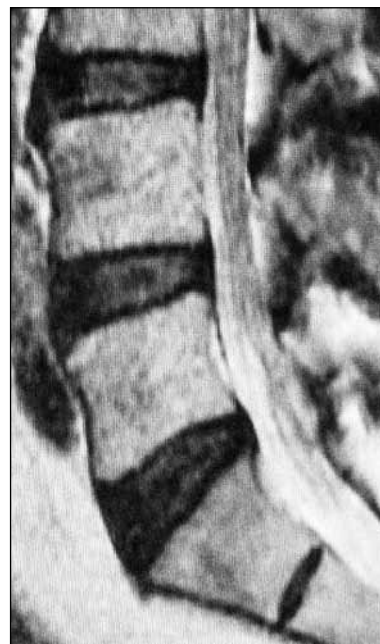

Figure 1: Sagittal T2 weighted MRI imaging of the patient before insertion of Gelstix™

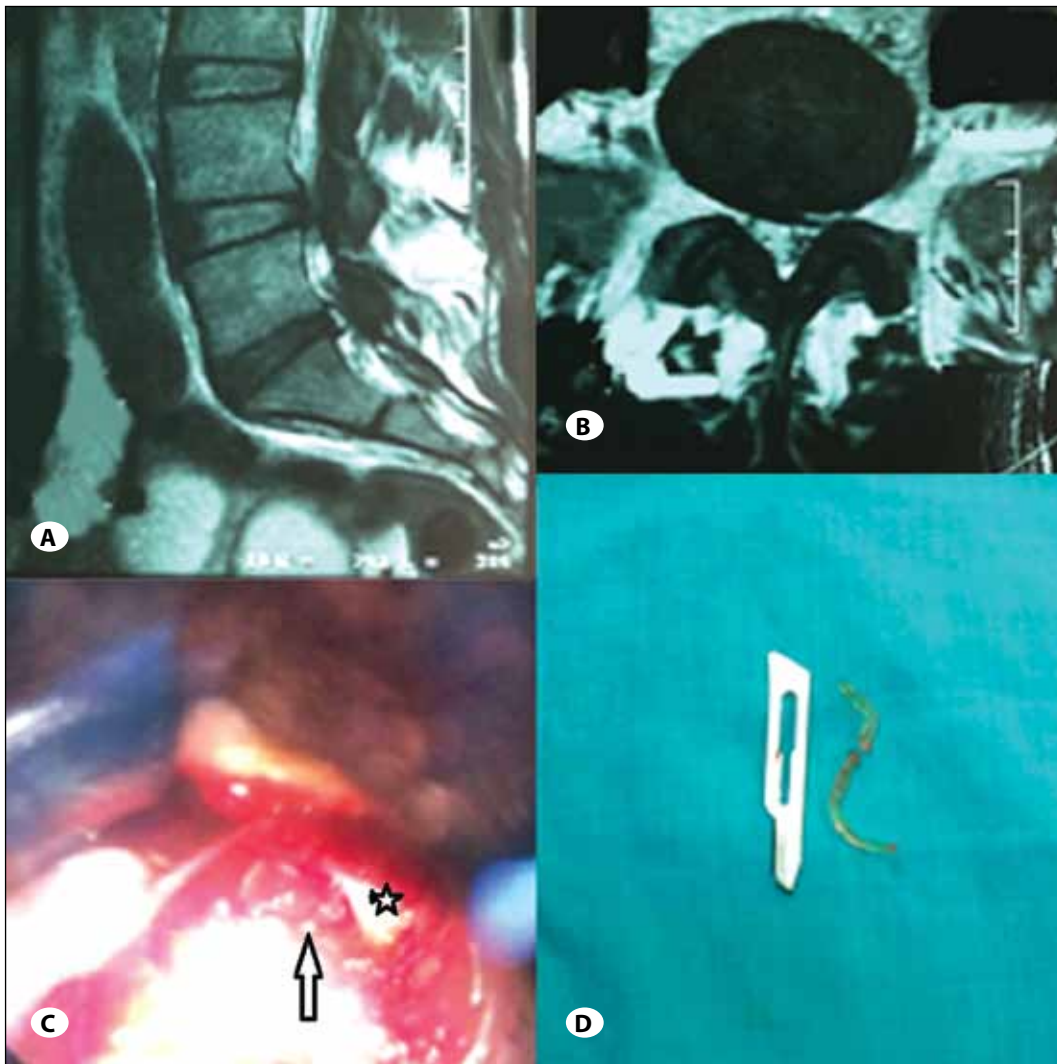


Figure 2: A) Pre-operative sagittal T2 weighted MRI imaging of the patient. B) Pre-operative axial T2 weighted MRI imaging of the patient. C) Operative image from microscope: White star: neural root, white arrow: fragmented Gelstix™. D) Excised fragment of Gelstix™.

reported until now. Our case is therefore important as it describes the first complication related to the issue.

CONCLUSION

Difficulty during placement during the application of minimally invasive hydrogel implant in the disc can cause unfavourable results proceeding to surgery. Hyperintensity of annulus fibrosus on T2-weighted MRI scans of patients with hydrogel-based implants may indicate fragmentation of the implant. The technique of placement is important in order not to turn minimally invasive surgery into a complication surgery.

REFERENCES

1. Benz K, Stippich C, Fischer L, Möhl K, Weber K, Lang J, Steffen F, Beininger B, Gaissmaier C, Mollenhauer JA: Intervertebral disc cell- and hydrogel-supported and spontaneous intervertebral disc repair in nucleotomized sheep. *Eur Spine* J21:1758-1768, 2012
2. Benz K, Stippich C, Osswald C, Gaissmaier C, Lembert N, Badke A, Steck E, Aicher WK, Mollenhauer JA: Rheological and biological properties of a hydrogel support for cells intended for intervertebral disc repair. *BMC Musculoskeletal Disorders* 13:54, 2012
3. Collin EC, Grad S, Zeugolis DI, Vinatier CS, Clouet JR, Guicheux JJ, Weiss P, Alini M, Pandit AS: An injectable vehicle for nucleus pulposus cell-based therapy. *Biomaterials* 32:2862-2870, 2011
4. Gorapalli D, Seth A, Vournakis J, Whyne C, Akens M, Zhang A, Demcheva M, Qamirani E, Yee A: Evaluation of a novel poly N-acetyl glucosamine (pGlcNAc) hydrogel for treatment of the degenerating intervertebral disc. *Life Sci* 17:1328-1335, 2012
5. Kranenburg HJ, Meij BP, Onis D, van der Veen AJ, Saralidze K, Smolders LA, Huizinga JG, Knetsch ML, Luijten PR, Visser F, Voorhout G, Dhert WJ, Hazewinkel HA, Koole LH: Design, synthesis, imaging, and biomechanics of a softness-gradient hydrogel nucleus pulposus prosthesis in a canine lumbar spine model. *J Biomed Mater Res B Appl Biomater* 100: 2148-2155, 2012

6. Malhotra NR, Han WM, Beckstein J, Cloyd J, Chen W, Elliott DM: An injectable nucleus pulposus implant restores compressive range of motion in the bovine disc. *Spine* 37(18):1099-1105, 2012
7. Mulder M, Crosier J, Dunn R: Cauda equina compression by hydrogel dural sealant after a laminotomy and discectomy. *Spine* 34:E144-148, 2009
8. Nakashima S, Matsuyama Y, Takahashi K, Satoh T, Koie H, Kanayama K, Tsuji T, Maruyama K, Imagama S, Sakai Y, Ishiguro N: Regeneration of intervertebral disc by the intradiscal application of cross-linked hyaluronate hydrogel and cross-linked chondroitin sulfate hydrogel in a rabbit model of intervertebral disc injury. *Bio-Medical Materials and Engineering* 19:421-429, 2009
9. Thavarajah D, De Lacy P, Hussain R, Redfern RM: Postoperative cervical cord compression induced by hydrogel (DuraSeal). *Spine* 35:25-26,2010
10. Yue JJ, Morgenstern R, Morgenstern C, Lauryssen C: Shape memory hydrogels – A novel material for treating age-related degenerative conditions of the spine. *European Musculoskeletal Review* 6:184-188, 2011