



Spinal Intradural Malignant Peripheral Nerve Sheath Tumor in a Child with Neurofibromatosis Type 2: The First Reported Case and Literature Review

Nörofibromatosis Tip 2 Olan Bir Çocukta Spinal İntradural Malign Periferik Sinir Kılıfı Tümörü: İlk Bildirilen Olgu ve Literatürün Gözden Geçirilmesi

Liang WU, Xiaofeng DENG, Chenlong YANG, Yulun XU

Beijing Tiantan Hospital, Capital Medical University, Department of Neurosurgery, Beijing, China

Corresponding Author: Yulun XU / E-mail: xuhuxi@sina.cn

ABSTRACT

Spinal intradural malignant peripheral nerve sheath tumors (MPNSTs) in children are extremely rare, with only five reported cases in the literature. A 9-year-old female with neurofibromatosis type 2 (NF-2) presented with right hip pain and severe weakness of bilateral legs for 3 months. Magnetic resonance (MR) imaging revealed multiple intradural masses at the T11-L2, L4, and L5-S5 level respectively, and bilateral vestibular schwannomas in the cerebellopontine angle. Partial tumor excision with T11-L2 laminectomy was undertaken and the tumors in the spinal cord were consistent with the diagnosis of epithelioid MPNSTs. No adjuvant therapy was performed after surgery. No metastasis of the tumor was found in the 6-month follow-up MR imaging. She died of brain metastasis at 9 months after surgery. MPNSTs should be added to the differential diagnosis of intradural tumors of the pediatric spine, even in children with NF-2. Multidisciplinary treatment consisting of total surgical removal and adjuvant radiotherapy should be considered due to poor prognosis of this abnormality. To our knowledge, this is the first case of spinal MPNSTs in a child with NF-2 to be published in English literature.

KEYWORDS: Child, Malignant peripheral nerve sheath tumor, Neurofibromatosis type 2, Spinal cord tumor

ÖZ

Spinal intradural malign periferik sinir kılıfı tümörleri (MPSKT) çocuklarda çok nadirdir ve literatürde sadece bildirilen beş olgu vardır. Nörofibromatosis tip 2 (NF-2) hastası olan 9 yaşında bir kız çocuğu, 3 aylık sağ kalça ağrısı ve her iki bacakta şiddetli güçsüzlük ile geldi. Manyetik rezonans (MR) görüntülemesi T11-L2, L4 ve L5-S5 seviyelerinde çok sayıda intradural kitle ve serebellopontin açıda bilateral vestibüler schwannom gösterdi. T11-L2 laminektomisiyle kısmi tümör eksizyonu yapıldı ve omurilikteki tümörler epiteliyoid MPSKT tanısıyla uyumluydu. Cerrahiden sonra adjuvan tedavi verilmedi. 6 aylık takip MR görüntülemesinde tümör metastazı saptanmadı. Cerrahiden 9 ay sonra beyin metastazları sebebi ile öldü. MPSKT'ler NF-2 hastası olan çocuklarda bile pediatrik omurga intradural tümörlerinin ayırıcı tanısına eklenmelidir. Total cerrahi çıkarma ve adjuvan radyoterapiden oluşan multidisipliner tedavi bu anormalliğin kötü prognozu nedeniyle düşünülmelidir. Bildiğimiz kadarıyla bu İngilizce literatürde yayınlanan NF-2'li bir çocukta ilk spinal MPSKT olgusudur.

ANAHTAR SÖZCÜKLER: Çocuk, Malign periferik sinir kılıfı tümörü, Nörofibromatosis tip 2, Omurilik tümörü

INTRODUCTION

Malignant peripheral nerve sheath tumors (MPNSTs) are rare soft tissue neoplasms constituting 3–10% of all soft tissue sarcomas (10). They tend to occur in the subcutaneous soft tissues and muscles in the extremities and trunk. Spinal intradural MPNSTs are extremely rare and are frequently associated with neurofibromatosis type 1 (NF-1). Very few cases of spinal MPNSTs in neurofibromatosis type 2 (NF-2) have been reported and no such case has been noted in a child with NF-2. Here, we report a case of spinal intradural MPNSTs in a 9-year-old female with NF-2 and discuss the clinical features and treatment strategies of the disease.

CASE REPORT

A 9-year-old female complaining of right hip pain and severe progressive weakness in the bilateral legs for 3 months was referred to our hospital. She was diagnosed as NF-2 by molecular confirmation 1 year ago. Molecular testing results are not available. The patient was unable to stand unaided for 1 month before admitting to our department. She denied any cranial nerve or sphincter symptoms. The neurological examination revealed muscle tone was decreased and muscle power was grade 1/5 (classified by the Medical Research Council grading system) in the lower extremities. Deep and superficial sensation of her bilateral legs was reduced. Deep

tendon reflexes had no hypo- or hyper-excitability and bilateral Babinski signs were negative.

Magnetic resonance (MR) imaging of the brain demonstrated bilateral vestibular schwannomas in the cerebellopontine angle (Figure 1A). The criteria for a diagnosis of NF-2 (the National Institutes of Health consensus statement criteria (6)) were satisfied by imaging manifestation combined with her medical history. Preoperative MR imaging of the lumbar spine demonstrated multiple intradural masses at the level of T11-L2, L4, and L5-S5 respectively. The tumors showed isointensity on the T1-weighted image (WI), mild hyperintensity on the T2WI, and homogeneously marked enhancement after gadolinium administration. The spinal cord was severely compressed and displaced to the left (Figure 1B-D). The tumors were initially suspected to be neurofibromas.

A T11-L2 laminectomy was performed through the posterior approach. The dura was highly tense and a longitudinal incision was made on the center of it. The intraoperative findings showed that the tumor had incomplete capsule and was grayish, soft but not well circumscribed. The lesion had high vascularity and appeared densely adherent to the cauda roots. *En bloc* resection is difficult to be achieved. Following transection of the filum terminale, the tumor was resected piece by piece and partial removal was achieved using microsurgical techniques.

Histopathologically, the tumor was composed of a large number of oval and epithelioid-shaped cells and a small number of spindled-shaped cells with a focal nested architecture (Figure 2A,B). Immunohistochemical staining revealed diffuse strong immunoreactivity for S-100, Vimentin, myelin basic protein (MBP), and neuron-specific enolase (NSE) but negative for human melanoma black-45 (HMB-45) and epithelial membrane antigen (EMA), confirming that the tumor was epithelioid MPNST (Figure 3A-D).

After surgery, the patient's right hip pain relieved apparently and the postoperative course was uneventful. Because the nature of the spinal tumors was malignant, further treatment was strongly recommended. However, the patient and her parents refused to perform adjuvant radiochemotherapy for the residual spinal tumors. She left our hospital 2 weeks after the operation. On postoperative MR imaging performed until 6 months, the residual tumors showed a mild enlargement and no metastasis of the tumor was found. However, the patient died of brain metastasis at 9 months after surgery.

DISCUSSION

MPNSTs are uncommon malignant tumors of peripheral nerve sheath cell origin. Up to 50% of these tumors occur in association with NF-1, and they also can be found in NF-2 cases, although very infrequently (3). MPNSTs involvements

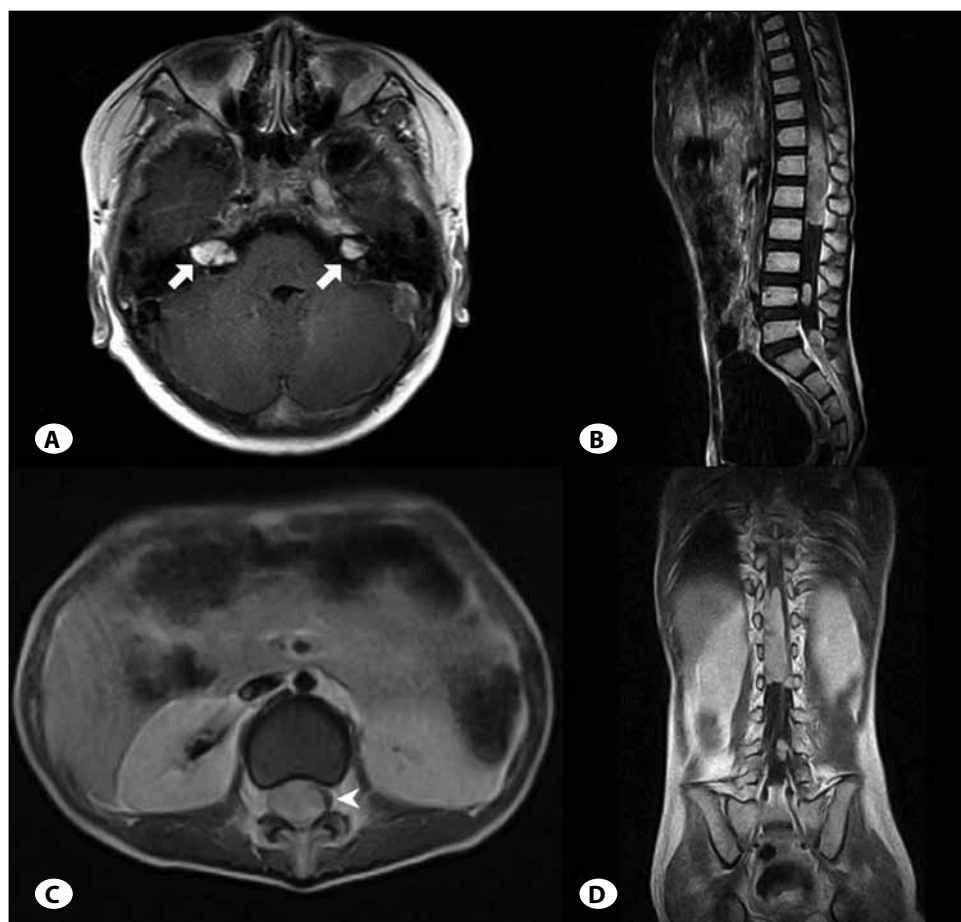


Figure 1: Axial (A) T1-weighted contrast-enhanced magnetic resonance (MR) imaging of the brain demonstrating bilateral vestibular schwannomas in the cerebellopontine area (arrow). Sagittal (B), axial (C) and coronal (D) T1-weighted contrast-enhanced MR imaging of the lumbar spine showing multiple intradural masses, causing the spinal cord was severely compressed and displaced to the left (arrowhead).

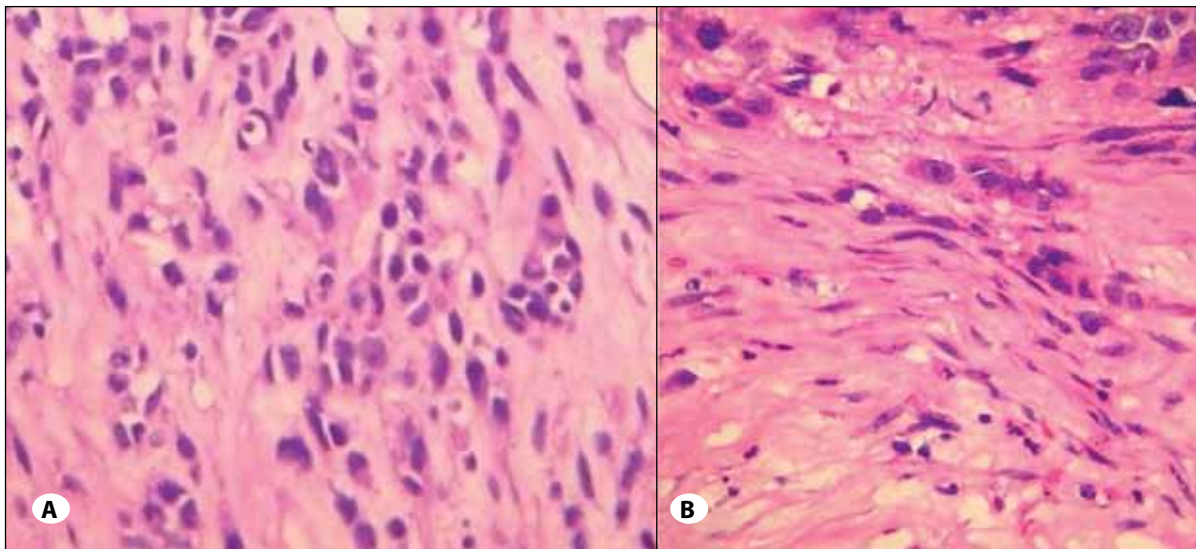


Figure 2: Histology sections showing the tumor composed of epithelioid-shaped cells and a small number of spindled-shaped cells with a focal nested architecture (hematoxylin and eosin stain; original magnification: **A** $\times 200$, **B** $\times 400$).

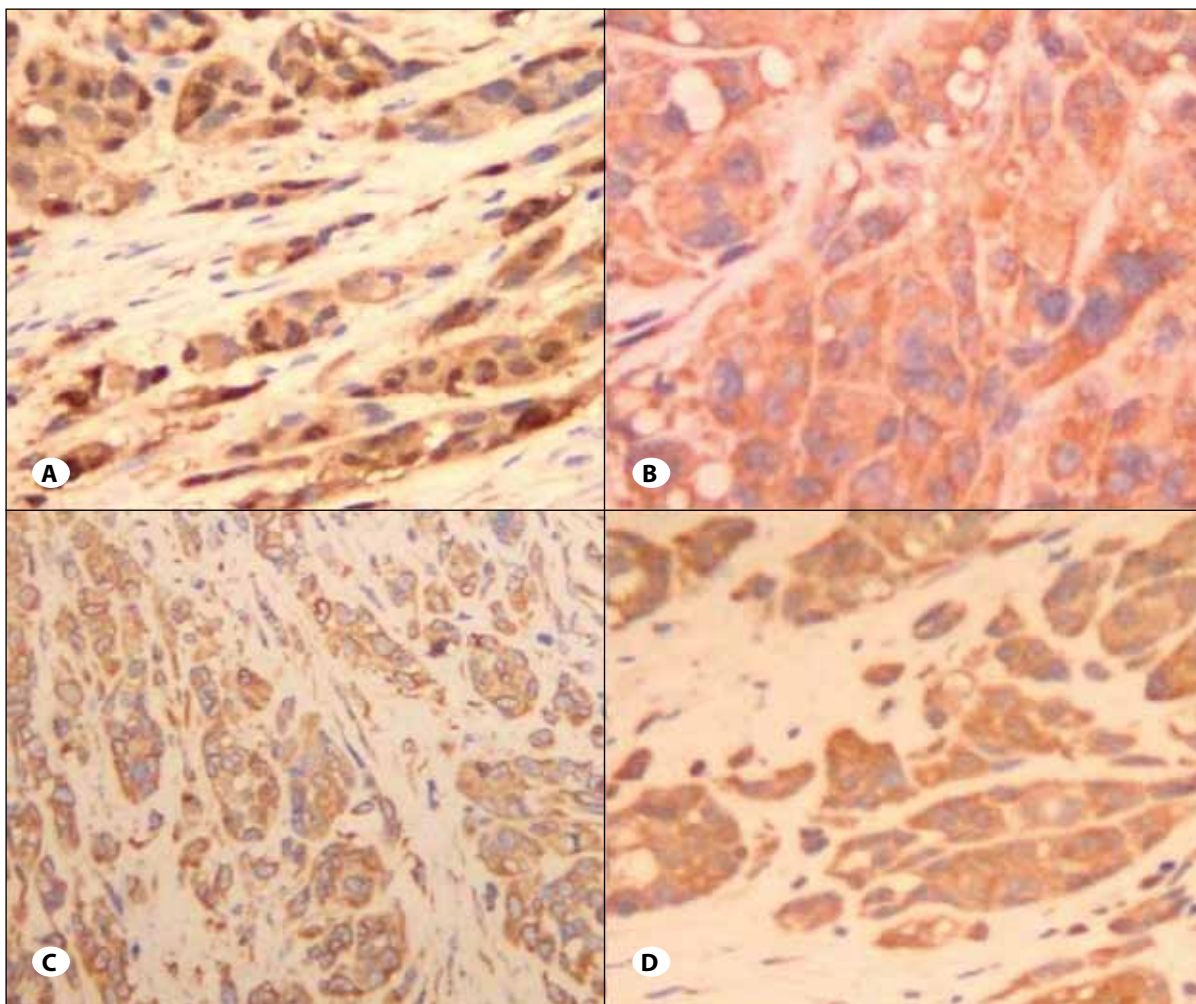


Figure 3: Immunohistochemical staining showing the tumor cells positive for S-100 (**A**), Vimentin (**B**), myelin basic protein (**C**), and neuron-specific enolase (**D**) (original magnification $\times 200$).

of the spinal cord are extremely rare, especially in pediatric patients. There are only five case reports in the literature describing this condition in children (Table I) (2, 7, 8, 9). In this report, we present the first case of spinal intradural MPNSTs in a child with NF-2.

Some series show that MPNSTs have a female preponderance (1). However, in children with spinal MPNSTs, four of the six patients were males and two were females. Regarding tumor site, one was cervical, five were located in the lumbar and sacrum, and cauda equina was often involved. The condition of all the patients rapidly progressed and the duration of illness was usually only several weeks. Two cases occurred in patients with neurofibromatosis. Somatic pain and weakness of lower extremity are the most frequent symptoms caused by intradural MPNSTs. The patients with progressing paraparesis were usually unable to walk at the time of operation. Radiologically, intradural MPNSTs have no specific imaging features and may resemble schwannomas, neurofibromas, or paragangliomas.

Histologically, schwannomas should be considered in the differential diagnosis of MPNSTs. Schwannomas are the most common type of spinal nerve sheath tumor occurring in association with NF-2 (5). They are commonly benign lesions. However, schwannomas may be difficult to distinguish from MPNSTs when the tumor tissues have increased cellularity and proliferation of atypical spindle cell. Especially, spontaneous malignant transformation of these tumors to MPNSTs does occur, although very infrequently (4). Due to the existence of an inactivated germ-line NF-2 allele in NF-2 patients, somatic mutation may contribute to this malignant transformation, but

the prevalence and risk factors of it in NF-2 are still unknown. Though the background rate of 0.5% for CNS malignancy in NF-2 is very much less than for NF-1 (5), it is recommended that all children with NF-2, regardless of symptoms, should undergo serial follow-up radiological screening by spinal MR imaging to detect occult spinal lesions, especially malignant tumors.

Clinical outcomes for patients with spinal intradural MPNSTs are very poor despite total removal and adjuvant radiochemotherapy. Compared with adult patients with MPNSTs, the pediatric patients seemed to have a worse prognosis (8). Although no optimal therapeutic strategy has been established yet, total resection is the primary goal for the treatment of spinal intradural MPNSTs. However, it is usually difficult to achieve complete removal of the mass with tumor-free margins without damage to the function of adjacent nerves. The main goals of surgery included preservation of neurological function, relief of pain, and maintenance of spinal stability. Incomplete removal of this highly malignant tumor may cause recurrence and metastases.

In the reported pediatric cases, all three patients only performed surgery died within 9 months of diagnosis. Two patients performed radiotherapy had longer survival time (21 and 16 months). For local control in the event of incomplete removal or tumor recurrence, postoperative adjuvant radiotherapy in children is recommended though the outcomes of it in adult patients are poor (2). Due to the small number of cases reported, it is difficult to comment on the role of chemotherapy. The most common sites for metastatic spread after the removal of intradural MPNSTs are

Table I: Summary of Previously Reported Spinal Intradural MPNSTs in Children

Author/Year	Age/ Sex	Location of tumor	Associated NF	Surgical removal	Adjuvant therapy	Metastasis	Prognosis
Seppala /1993 ⁷	13/M	L	NF-1	Partial	Nd	Brain and systemic	Dead at 2 months
	13/M	L	No	Total	Nd	Systemic	Dead at 7 months
Yone/2004 ⁹	4/M	L3-5	No	Total	RTX+CTX	Brain and spine	Dead at 21 months
Chamoun/2009 ²	5/F	C4-5 with dissemination to the thoracic spine, cauda equina and leptomeninges	No	Partial	RTX+CTX	leptomeningeal carcinomatosis	Alive at 4 months
Xu/2012 ⁸	8/M	L3-5	No	Total	RTX	Brain, lumbar and sacral spine	Dead at 16 months
Present case	9/F	T11-L2, L4, L5-S5	NF-2	Partial	No	Brain	Dead at 9 months

C: cervical, **CTX:** chemotherapy, **L:** lumbar, **Nd:** not determined, **RTX:** radiotherapy, **T:** thoracic.

the lungs and liver in adult patients (7). However, among the six pediatric patients reviewed in this article, five had brain metastasis after surgery. Thus, brain is the most frequent site of metastasis via dissemination of cerebrospinal fluid in children with spinal MPNSTs, and the efficacy of adjuvant radiochemotherapy for controlling brain metastasis is still limited.

In conclusion, MPNSTs should be considered to the differential diagnosis of intradural tumors of the pediatric spine, even in children with NF-2. Histopathological diagnosis should distinguish from schwannomas. Surgical removal combined with adjuvant radiotherapy is recommended although overall prognosis is unfavorable.

ACKNOWLEDGMENT

We thank all the patients who trusted us and all the physicians and staff who help this study.

REFERENCES

1. Cashen DV, Parisien RC, Raskin K, Hornicek FJ, Gebhardt MC, Mankin HJ: Survival data for patients with malignant schwannoma. *Clin Orthop Relat Res* 426:69-73, 2004
2. Chamoun RB, Whitehead WE, Dauser RC, Luerssen TG, Okcu MF, Adesina AM, et al: Primary disseminated intradural malignant peripheral nerve sheath tumor of the spine in a child: Case report and review of the literature. *Pediatr Neurosurg* 45:230-236, 2009
3. Dimou J, Jithoo R, Pitcher M, White G: Recurrent malignant peripheral nerve sheath tumor in a patient with neurofibromatosis Type 1: A case report. *J Clin Neurosci* 16:1221-1223, 2009
4. Evans DG, Sainio M, Baser ME: Neurofibromatosis type 2. *J Med Genet* 37:897-904, 2000
5. Holland K, Kaye AH: Spinal tumors in neurofibromatosis-2: Management considerations-a review. *J Clin Neurosci* 16: 169-177, 2009
6. National Institutes of Health Consensus Development Conference Statement on Neurofibromatosis. *Arch Neurol* 45:575-579, 1987
7. Seppala MT, Haltia MJ: Spinal malignant nerve-sheath tumor or cellular schwannoma? A striking difference in prognosis. *J Neurosurg* 79:528-532, 1997
8. Xu Q, Xing B, Huang X, Wang R, Li Y, Yang Z: Primary malignant peripheral nerve sheath tumor of the cauda equina with metastasis to the brain in a child: Case report and literature review. *Spine J* 12:7-13, 2012
9. Yone K, Ijiri K, Hayashi K, Yokouchi M, Takenouchi T, Manago K, et al: Primary malignant peripheral nerve sheath tumor of the cauda equina in a child case report. *Spinal Cord* 42:199-203, 2004
10. Zhu B, Liu X, Liu Z, Yang S, Liao HI, Jiang L, et al: Malignant peripheral nerve sheath tumours of the spine: Clinical manifestations, classification, treatment, and prognostic factors. *Eur Spine J* 21:897-904, 2012