



Solitary Juvenile Xanthogranuloma in Cervical Spine: Case Report and Review of the Literature

Servikal Omurganın Soliter Jüvenil Ksantogranüloму: Olgu Sunumu ve Literatürün Gözden Geçirilmesi

Subhas KONAR¹, Paritosh PANDEY², Yasha T.C³

¹NIMHANS, Department of Neurosurgery, Bangalore, Karnataka, India

²NIMHANS, Department of Neurosurgery, Bangalore, Karnataka, India

³NIMHANS, Department of Neuropathology, Bangalore, Karnataka, India

Corresponding Author: Paritosh PANDEY / E-mail: paritosh2000@gmail.com

ABSTRACT

Solitary juvenile xanthogranuloma (JXG) in the spinal column is extremely rare. Here, we report and characterize the case of xanthogranuloma of the upper cervical spine. A 18-year-old male presented with neck pain for 3 months, along with progressive quadriparesis and sensory loss of 2 months duration with urinary retention. Motor examination revealed spastic quadriparesis with power of 2/5 in all the 4 limbs. Magnetic Resonance Imaging (MRI) spine with contrast showed a dorsally placed intradural extramedullary lesion at the level of C2-C4 vertebral body. The lesion, measuring 2.9x1.7x1.4 cm, was isointense on T1WI, hypointense on T2WI, and enhanced homogeneously on contrast. He underwent an emergency C2-C4 laminectomy and complete excision of the lesion. At 3-month follow-up, he was asymptomatic except for mild neck pain. MRI scan of the cervical spine done at follow-up, revealed complete excision of tumor without any residual lesion. Histopathological examination of the mass revealed a polymorphous population of sheets of bloated pale foamy histiocytes (xanthoma cells), numerous admixed mature lymphocytes and several Touton giant cells. The cells were positive for CD68, a histiocytic marker, and negative for CD1a (excludes LCH) and S-100 (excludes RDD).

KEYWORDS: Juvenile xanthogranuloma, Cervical spine, MRI, Complete resection

ÖZ

Omurgada soliter jüvenil ksantogranüloму çok nadirdir. Burada üst servikal omurgada bir ksantogranüloму olgusunu bildiriyoruz. 18 yaşında bir erkek 3 aydır boyun ağrısı, 2 aydır progresif kuadriparezi ve duyu kaybı ile üriner retansiyonla geldi. Motor inceleme 4 uzuvda 2/5 güçle spastik kuadriparezi gösterdi. Omurganın kontrastlı Manyetik Rezonans Görüntülemesi (MRG) C2-C4 vertebral cisim seviyesinde dorsal yerleşimli bir intradural ekstramedüller lezyon ortaya koydu. 2,9x1,7x1,4 cm boyutlarında olan lezyon T1WI ile izointens, T2WI ile hipointens ve kontrast ile homojen tutulum göstermekteydi. Acil C2-C4 laminektomi ve lezyonun tam eksizyonu yapıldı. 3 aylık takipte hafif boyun ağrısı dışında semptom yoktu. Takipte yapılan servikal omurga MRG taraması herhangi bir rezidüel lezyon olmadan tümörün tam eksizyonunu gösterdi. Kitlenin histopatolojik incelemesi şiş ve soluk köpüklü histiosit tabakalarının (ksantoma hücreleri) polimorfik bir popülasyonunu, araya karışmış çok sayıda matür lenfosit ve birkaç Touton dev hücrelerini gösterdi. Hücreler bir histiositik belirteç olan CD68 için pozitif ve CD1a (LCH ekarte eder) ve S-100 (RDD ekarte eder) için negatifti.

ANAHTAR SÖZCÜKLER: Jüvenil ksantogranüloму, Servikal omurga, MRG, Komplet rezeksiyon

INTRODUCTION

Juvenile xanthogranuloma (JXG) is a self-limiting dermatologic disorder usually occurring in the first two decades of life. Pathologically, it is a proliferative disorder of dendritic cell, non-Langerhans histiocytes, and is on a spectrum of histiocytic disorders that includes benign cephalic histiocytosis, generalized eruptive histiocytosis, adult xanthogranuloma, and progressive nodular histiocytosis (7). JXG is rarely associated with systemic manifestations, and isolated involvement of the sub-axial cervical spine is extremely rare (3,8,18,19). Only 11 previous cases have been described of isolated involvement of spine with JXG. We report a case of solitary cervical intradural extramedullary juvenile xanthogranuloma, and review the pertinent literature.

CASE REPORT

An 18-year-old male presented to our institution with neck pain for 3 months, along with progressive quadriparesis and sensory loss of 2 months duration. He was bed-ridden for a week before admission, and for two days prior to admission, he had urinary retention. There was no history of trauma or fever. On clinical examination, he was conscious and oriented, and did not have any cranial nerve deficits. There were no neurocutaneous markers. Motor examination revealed spastic quadriparesis with power of 2/5 in all the 4 limbs. He had hyper-reflexia in all 4 limbs, and bilateral plantars were extensor. Sensory examination showed 80% decrease in sensation below C4 dermatome.

Magnetic Resonance Imaging (MRI) spine with contrast (Figure 1A-E) showed a dorsally placed intradural extramedullary lesion at the level of C2-C4 vertebral body. The lesion, measuring 2.9x1.7x1.4 cms, was isointense on T1WI, hypointense on T2WI, and enhanced homogeneously on contrast. The spinal cord was displaced anteriorly by the tumor, and there was a 'meniscus sign' at the superior and inferior borders of the tumor. There was no evidence of extension of the tumor into the neural foramina, or bony destruction by the tumor.

He underwent an emergency C2-C4 laminectomy and complete excision of the lesion. The laminae and bone looked normal. On opening the dura, there was a dorsally placed, intradural extramedullary tumour. There were some adhesions between the tumor and dura, which was easily separated. The tumor was well defined, yellowish, firm and lobulated. There was no attachment of the tumor to any of the nerve rootlets. There was no extension of the tumor to the neural foramina. Complete excision of the tumor was performed. Postoperatively, the patient improved remarkably, and his power improved to 4/5 in all groups on postoperative day

1. He was discharged on postoperative day 4, by which time he was walking without support, and was fully continent. At 3-month follow-up, he was asymptomatic except for mild neck pain. MRI scan of the cervical spine done at follow-up revealed complete excision of tumor without any residual lesion. A screening MRI of spine and brain did not reveal any other tumor.

Histopathological examination of the mass revealed a polymorphous population of sheets of bloated pale foamy histiocytes (xanthoma cells), numerous admixed mature lymphocytes and several Touton giant cells. The latter are multinucleate lipid laden giant cells with a circle of nuclei around a central area of eosinophilic cytoplasm and vacuolated cytoplasm between the nuclei and cell membrane. The cells were positive for CD68, a histiocytic marker, and negative for CD1a (excludes LCH) and S-100 (excludes RDD) (Figure 2A-D).

DISCUSSION

Juvenile xanthoranoloma (JXG) is classified into one of the histiocytic disorders, which are grouped as (1) dendritic-cell

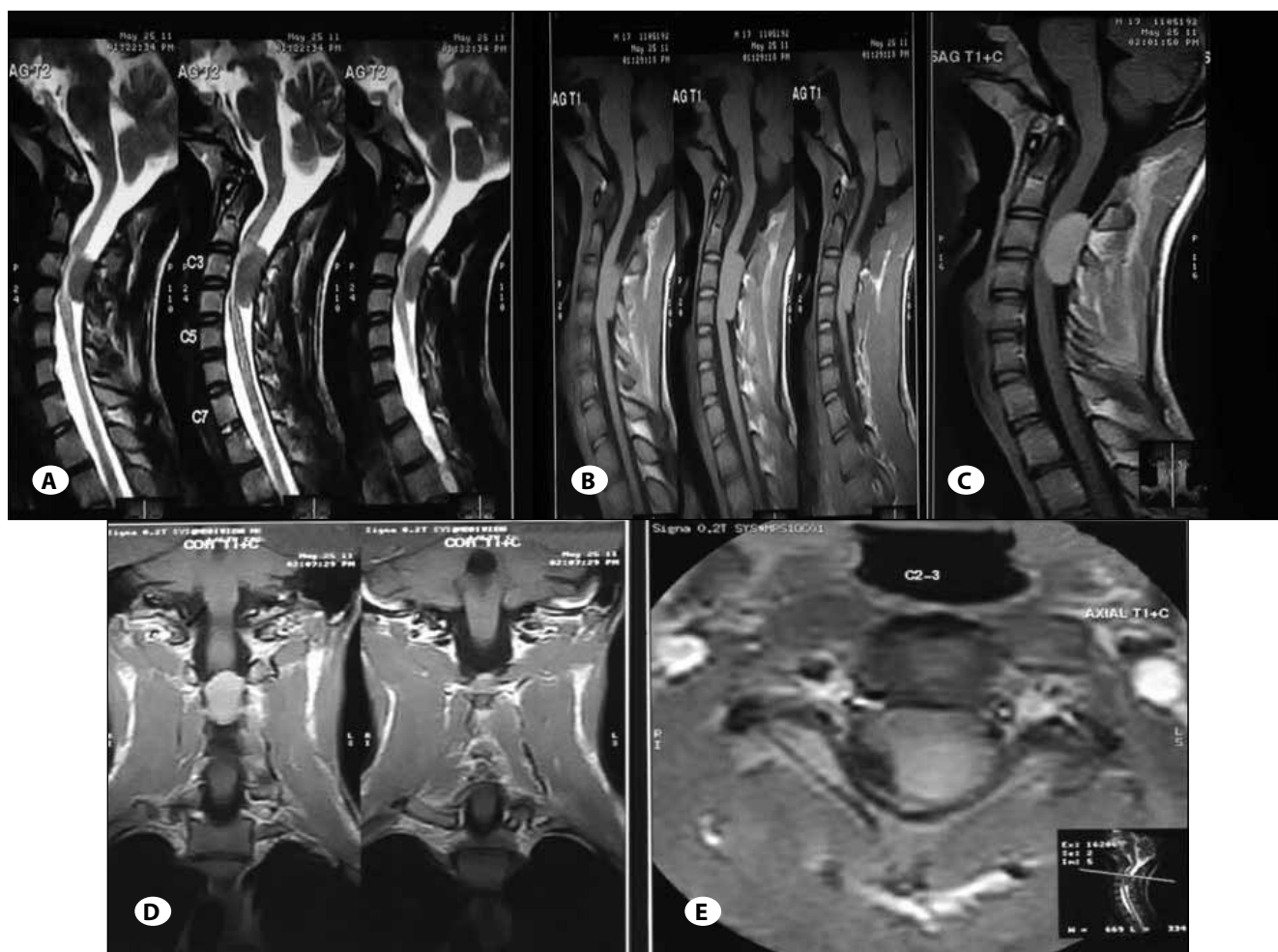


Figure 1: Magnetic Resonance Imaging (MRI) of Cervical Spine: **A)** SAG: T2W: Hypointense, ventrally located. **B)** MRI: SAG: T1W-isointense. **C)** MRI-Contrast-SAG-enhancing mass. **D)** MRI: Contrast: CORONAL: Centrally located. **E)** MRI: Contrast: AXIAL: Enhancing mass pushing cord anteriorly.

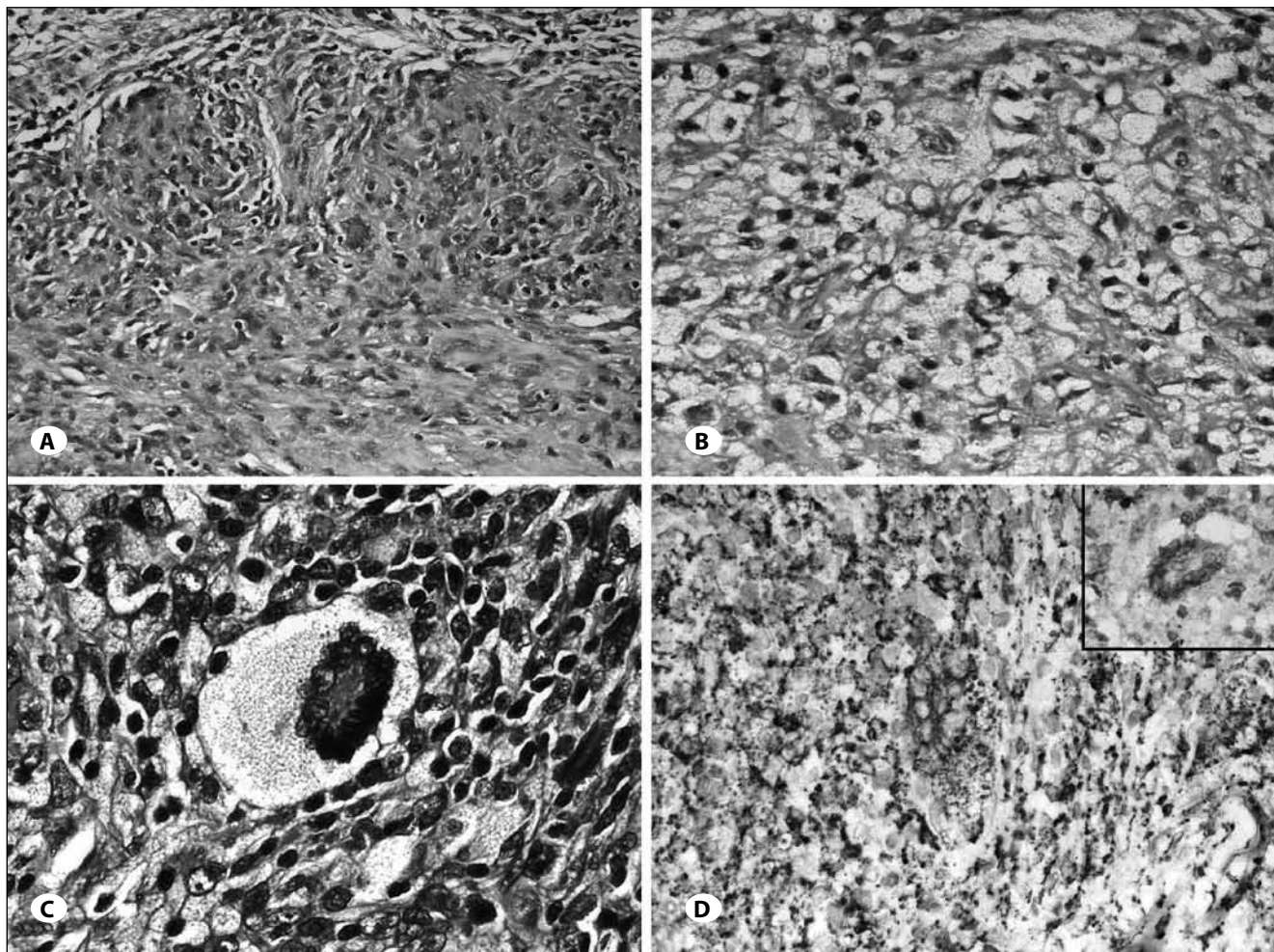


Figure 2: Spinal Juvenile Xanthogranuloma. **A)** Nodular aggregates of histiocytes, lymphocytes and giant cells forming granulomas in a collagenous stroma. (HE stain; original magnification x200) **B)** Sheets of foamy histiocytes - 'xanthoma' cells. (HE stain; original magnification x400) **C)** A 'Touton' multinucleate giant cell on a background of lymphocytes and histiocytes. (HE stain; original magnification x400) **D)** Histiocytes and Touton cells are positive for CD 68 marker. Inset: Negative for CD 1a. (Immunohistochemistry for CD 68 and CD1a; Original magnification x400).

related, (2) macrophage-related or (3) malignant histiocytic disorders. JXG is an example of a dendritic cell disorder, another being Langerhans cell histiocytosis (LCH). Macrophage related disorders comprise while Rosai- Dorfmann disease (RDD), and hemophagocytic lymphohistiocytosis and Erdheim Chester disease (6,9).

These disorders are believed to be the result of altered macrophage response to a non-specific injury, resulting in granulomatous reaction. JXG was thought to be a reactive process, however its clonal nature has recently been demonstrated, leading to credence its neoplastic origin (10).

JXGs are benign, usually asymptomatic, self-limiting skin disorder. JXG usually occurs in infancy and childhood, and typically regresses over the years (9). The commonest sites of involvement is on the skin and head, but it can occur in other sites as well. Extracutaneous involvement occurs in a minority

of patients, and common sites include the uveal tract, oropharynx, heart, lung, liver and other organs (9). However, central nervous system (CNS) involvement is extremely rare. JXG has been reported in various intracranial and skull base locations (2,4,11). Orbital and skull base involvement is common, though xanthogranuloma in a colloid cyst has been described before (13). Isolated spinal involvement is extremely rare, and to the best of our knowledge, there are only 11 reported cases in the English literature, and third in the subaxial cervical spine (1,3,5,6,8, 14,15, 18-20).

Spinal JXG usually affects children and young adults, and 7 of the 11 previously reported cases have been pediatric patients (<18 years). The location of the tumor in the previous 11 reported cases have been in upper cervical spine (2), sub-axial cervical spine (2), thoracic spine (3), cauda equina (1) and lumbar spine (3). Thus there is a small predilection of these tumors to occur in thoracic and lumbar spine,

Table I: Published Cases of Solitary Juvenile Xanthogranuloma

Author	Age/sex	Location	Presentation	Radiology	Surgery	Resection	Follow up
Present case	17/M	C3-C5 IDEM	Quadripareisis, bladder involvement	Hypo on T1, Hyper on T2, uniform enhancement on contrast	C3-C5 laminectomy, excision of lesion	Complete resection	Normal at 3 month follow-up
Inoue, 2011 ³	38/M	C7-T1 IDEM	T1 radiculopathy	Isointense on T1 and T2, enhancing on contrast	C7 Hemilaminectomy, excision of lesion	Complete resection	Normal at follow-up
Jain, 2010 ¹⁸	22/F	T2 body, extradural	Back pain	Hypo on T1 and T2, enhancing	Laminectomy, complete excision, fusion	Complete resection	Normal at follow-up
Castro-Gabo, 2009 ¹³	14/M	Cauda equine	Paraparesis	String of beads like appearance, nodular enhancement in spinal canal	Laminectomy, partial resection	Partial resection	Prednisolone, vinblastine. Well at 12 months
Cao, 2008 ²	18/F	C2 nerve root	Neck pain	Hypo on T1, Hyper on T2, enhancing on contrast	C1-C2 laminectomy, excision of lesion, C1-2 fusion	Complete excision	Normal at follow-up
Dehmer, 2003 ⁶	14/F	L3 body lesion	Back pain	Vertebral body collapse	NA	NA	NA
Ramipini 2001 ⁵	34m/F	C5-C7 IDEM	Spastic quadripareisis	Isointense on T1 and T2, enhancing on contrast	C5-T1 laminectomy, excision	Complete resection	Recovered in 4 months
Agabigi, 2001 ¹⁴	47/F	L2 body, soft tissue extension	Back pain, bowel/bladder involvement	NA	T12-L3 laminectomy, partial resection	Partial resection	Radiotherapy
Oyama, 1997 ⁴	18/F	C1 IDEM	Left hemiparesis, Left hypoesthesia	NA	Suboccipital craniectomy, C1 Hemilaminectomy, excision	Complete resection	Normal at follow-up
Kim, 1996 ¹⁵	16m/M	T1-2 IDEM	Spastic paraparesis	Isointense on T1, Hyperintense on T2, Uniformly enhancing on contrast	C&T3 laminectomy, excision	Complete resection	Recovered in 3 months
Kitchen, 1995 ¹⁶	15/F	S1 nerve root	Low back pain /sciatica	Isointense on T1, Hyperintense on T2	L5 laminectomy, excision	Complete resection	Asymptomatic at follow-up
Shimosawa, 1993 ¹⁷	13m/F	T6-T9, IDEM	Spastic paraparesis	IDEM, Hypo on T1, Hyper on T2, non-enhancing	T6-T9 laminectomy, excision	Complete resection	Improved at 6m follow-up

IDEM: Intradural Extramedullary.

though it can occur anywhere in the spinal canal. Spinal JXG presents clinically as an intradural extramedullary (IDEM) tumor, as an osteolytic lesion in vertebral body, with spinal nerve root involvement, or a combination of these 3 features depending on the location of the tumor. Among the previous 11 patients, 6 presented as IDEM tumor, 2 presented with nerve root involvement, and 3 presented with vertebral body lesions with or without neurological deficits. Radiologically, they appear as well-defined lesions, iso- to- hypointense on T1WI, hyperintense on T2WI, and enhancing homogeneously on contrast. Castro-Gago described a patient with diffuse irregular thickening of the nerve roots, with string of beads appearance, and multiple nodular lesions in posterior spinal canal at L2-3 level (5). There is variable involvement of the bony structures. Cao et al. described a patient who had JXG in the upper cervical spine, along with bony destruction, necessitating bony fusion following excision of the tumor (3). Jain et al. reported a patient with D7 bony lesion with paraspinal and anterior epidural components, mimicking an aneurysmal bone cyst (12). Intraoperatively, these tumors mimic IDEM tumors like schwannoma or meningiomas, or bony tumors like aneurysmal bone cysts, depending on their radiological appearance. In case of presentation as IDEM tumors, resection of the tumor appears to be curative (14,19,20). However, fusion may be required following radical excision for lesions having extensive bony involvement (3,12).

Histologically, JXG are composed of mononuclear cells, multinucleated giant cells with or without Touton features, and spindle cells. At high magnification, lesions contain dense polyhedral histiocytes with large amounts of cytoplasm that often contain vacuoles (9). Touton giant cells are present in 85% of cases; in a background of mononuclear cells. Large osteolytic lesions with well-demarcated margins can be found along with osteoclast like giant cells, Touton giant cells and mononuclear cells in JXG with extensive bony involvement. Immunohistochemistry shows the lesions to be positive for factor XIIIa, CD68, CD163, fascin, and CD14 but are negative for S100 and CD1a (12,16,17). It is important to distinguish these tumors from LCH, as these lesions are more aggressive, and require aggressive treatment. Langerhans cells are distinguished by positivity of for CD-1a on IHC and by the presence of Birbeck granules on electron microscopy (6). In the present case the cells were negative for CD1a and for S-100 excluding LCH and RDD respectively.

Surgery is the first line of treatment, and total removal of tumor is curative. If a total resection has been achieved, there isn't any need for adjuvant therapy (14,15,19). In cases where there has been partial removal, authors have reported use of prednisone and vinblastine (19). However, the role of radiotherapy and chemotherapy in these tumors is unclear. In the present case, we could achieve complete tumor excision, and MRI done 3 months after surgery did not reveal any residual tumor. In cutaneous lesions disease can be self-limited and self-regressive. However, regression has not been reported in spinal JXA in the literature. Complete resection is

usually associated with a favourable outcome, with relief of symptoms and no recurrence.

CONCLUSION

To conclude, we report a very rare case of spinal JXG presenting as IDEM, for which curative resection was performed. This is the 12th case report of this tumor in English literature, and 3rd in sub-axial cervical spine (Table I). Total excision of the tumor is the treatment of choice, and should be aimed for whenever possible. It is important to distinguish these tumors from other histiocytic disorders pathologically, as the other disorders may require more aggressive treatment in contrast to the benign nature of JXG.

REFERENCES

1. Agabegi SS, Iorio TE, Wilson JD, Fischgrund JS: Juvenile xanthogranuloma in an adult lumbar spine: A case report. *Spine* 36:E 69-73, 2011
2. Boström J, Janssen G, Messing-Jünger M, Felsberg JU, Neuen-Jacob E, Engelbrecht V, HG Lenard, WJ Bock, G Reifenberger: Multiple intracranial juvenile xanthogranulomas. Case report. *J Neurosurgery* 93:335-341, 2000
3. Cao D, Ma J, Yang X, Xiao J: Solitary juvenile xanthogranuloma in the upper cervical spine: Case report and review of the literatures. *Eur Spine J* 17 Suppl 2:S318-323, 2008
4. Chidambaram B, Santosh V: Giant orbital and intracranial xanthogranuloma--a short report. *Neurol India* 49:208-210, 2001
5. Castro-Gago M, Gómez-Lado C, Alvez F, Alonso A, Vieites B: Juvenile xanthogranuloma of the cauda equina. *Pediatr Neurol* 40:123-125, 2009
6. Dehner LP: Juvenile xanthogranulomas in the first two decades of life: A clinicopathologic study of 174 cases with cutaneous and extracutaneous manifestations. *Am J Surg Pathol* 27:579-593, 2003
7. Favara BE, Feller AC, Pauli M, Jaffe ES, Weiss LM, Arico M, Bucsky P, Egeler RM, Elinder G, Gardner H, Gresik M, Henter JI, Imashuku S, Janka-Schaub G, Jaffe R, Ladisch S, Nezelof C, Pritchard: Contemporary classification of histiocytic disorders. The WHO Committee On Histiocytic/Reticulum Cell Proliferations. Reclassification Working Group of the Histiocyte Society *Med Pediatr Oncol* 29:157-166, 1997
8. Inoue H, Seichi A, Yamamuro K, Kojima M, Kimura A, Hoshino Y: Dumbbell-type juvenile xanthogranuloma in the cervical spine of an adult. *Eur Spine J* 20 Suppl 2:S343-347, 2011
9. Janssen D, Harms D: Juvenile xanthogranuloma in childhood and adolescence: A clinicopathologic study of 129 patients from the kiel pediatric tumor registry. *Am J Surg Pathol* 29: 21-28, 2005
10. Janssen D, Fölster-Holst R, Harms D, Klapper W: Clonality in juvenile xanthogranuloma. *Am J Surg Pathol* 31:812-813, 2007
11. Johnson TE, Alabiad C, Wei L, Davis JA: Extensive juvenile xanthogranuloma involving the orbit, sinuses, brain, and subtemporal fossa in a newborn. *Ophthal Plast Reconstr Surg* 26:133-134, 2010

12. Jain A, Mathur K, Khatri S, Kasana S, Jain SK: Rare presentation of juvenile xanthogranuloma in the thoracic spine of an adult patient: Case report and literature review. *Acta Neurochir (Wien)* 153:1813-1818, 2011
13. Kudesia S, Das S, Shankar SK, Santosh V, Reddy AK: Colloid cyst xanthogranuloma of the third ventricle--a case report. *Indian J Pathol Microbiol* 39:221-223, 1996
14. Kim DS, Kim TS, Choi JU: Intradural extramedullary xanthoma of the spine: A rare lesion arising from the dura mater of the spine: Case report. *Neurosurgery* 39:182-185, 1996
15. Kitchen ND, Davies MS, Taylor W: Juvenile xanthogranuloma of nerve root origin. *Br J Neurosurg* 9:233-237, 1995
16. Nascimento AG: A clinicopathologic and immunohistochemical comparative study of cutaneous and intramuscular forms of juvenile xanthogranuloma. *Am J Surg Pathol* 21:645-652, 1997
17. Newman CC, Raimer SS, Sánchez RL: Nonlipidized juvenile xanthogranuloma: A histologic and immunohistochemical study. *Pediatr Dermatol* 14:98-102, 1997
18. Oyama H, Ikeda K, Inoue S, Katsumata T, Murakami S, Doi A: A case of intradural xanthogranuloma in the upper cervical spine]. *No Shinkei Geka* 25:745-748, 1997
19. Rampini PM, Alimehmeti RH, Egidi MG, Zavanone ML, Bauer D, Fossali E, Villani RM: Isolated cervical juvenile xanthogranuloma in childhood. *Spine* 26:1392-1395, 2001
20. Shimosawa S, Tohyama K, Shibayama M, Takeuchi H, Hirota T: Spinal xanthogranuloma in a child: Case report. *Surg Neurol* 39:138-142, 1993