

Use of Scalp Flaps as a Salvage Procedure in Reconstruction of the Large Defects of Head and Neck Region

Baş Boyun Bölgesindeki Geniş Defektlerin Onarımında Kurtarıcı Bir Prosedür Olarak Skalp Fleplerinin Kullanımı

Onur EGEMEN¹, Derya BINGOL¹, Ozay OZKAYA¹, Tolga AKSAN¹, Suat Erol CELIK², Mithat AKAN¹

¹Okmeydanı Research and Training Hospital, Department of Plastic, Reconstructive and Aesthetic Surgery, Istanbul, Turkey

²Okmeydanı Research and Training Hospital, Department of Neurosurgery, Istanbul, Turkey

Presented in: 1. Oral and Maxillofacial Surgery Society, 1st International Congress, 29.04.2011-01.05.2011, Adile Sultan Sarayı, Istanbul
2. Plastic Surgery Special Joint Meeting - Mayo Clinic-Selcuk University, 20-22.05.2011, Konya

Correspondence address: Onur EGEMEN / E-mail: onuregemen@hotmail.com

ABSTRACT

AIM: Large defects of the scalp, head and neck region are often encountered by plastic surgeons. The repair of such defects is dependent upon their location, size and depth. This study describes the use of large scalp flaps as a salvage procedure in the reconstruction of large scalp, head and neck region defects in elderly patients with poor general condition or advanced malignancy.

MATERIAL and METHODS: The presented study includes 22 patients operated between 2007 and 2011 for the reconstruction of large defects of the hair-bearing skin and head/neck region with large scalp flaps. A defect exceeding 25 cm² area was classified as "large" as defined in the previous studies. The patients' medical records were analyzed.

RESULTS: Scalp flaps provided a satisfactory and durable reconstruction in the late follow-up term. All flaps were completely survived except in one case in which a partial necrosis in the distal margin occurred. Major complications were recorded in 4.5% of patients while minor complications were recorded in 13.5% of them.

CONCLUSION: In conclusion, large scalp flaps should be considered as a salvage procedure for reconstruction of large scalp, head and neck defects especially for palliative situations in elderly patients with significant comorbidities and advanced malignancies.

KEYWORDS: Scalp defect, Large scalp flap, Head and neck defect, Scalp reconstruction, Head and neck reconstruction, Hair-bearing skin defect

ÖZ

AMAÇ: Saçlı deri ve baş boyun bölgesinin geniş defektleri plastik cerrahlar tarafından sıkça karşılaşılan durumlardır. Bu defektlerin onarımı defektin yerleşim yeri, boyutu ve derinliği ile ilişkilidir. Bu çalışmada; genel durumu bozuk veya ilerlemiş kanser durumlarında, yaşlı hastalardaki saçlı deri ve baş boyun bölgesi geniş defektlerinin onarımında, kurtarıcı bir prosedür olarak geniş skalp fleplerinin kullanımı sunulmaktadır.

YÖNTEM ve GEREÇLER: Çalışmada, 2007-2011 yılları arasında, saçlı deri ve baş boyun bölgesinin geniş defektleri nedeniyle, geniş skalp flepleri ile rekonstrükte edilen 22 hasta değerlendirildi. Çalışmada, daha önceki çalışmalarda tanımlandığı şekilde, 25 cm²'den büyük defektler, 'geniş' defekt olarak sınıflandırıldı. Hastaların tıbbi kayıtları üzerinden değerlendirme yapıldı.

BULGULAR: Uzun dönem takiplerinde, skalp flepleri tatmin edici ve dayanıklı bir rekonstrüksiyon sunmaktadır. Çalışmada, bir flebin distal marjinde gelişen parsiyel nekroz dışında tüm flepler tamamen yaşadı. Hastaların %4,5'inde majör, %13,5'inde ise minör komplikasyonlar kaydedildi.

SONUÇ: Sonuç olarak, geniş skalp flepleri, ciddi komorbiditesi olan veya ileri kanser olgularında, yaşlı hastalarda özellikle palyatif durumlarda, geniş skalp ve baş boyun bölgesi defektlerinin rekonstrüksiyonunda, kurtarıcı bir prosedür olarak dikkate alınmalıdır.

ANAHTAR SÖZCÜKLER: Skalp defekti, Geniş skalp flebi, Baş ve boyun defekti, Skalp rekonstrüksiyonu, Baş ve boyun rekonstrüksiyonu, Saçlı deri defekti

INTRODUCTION

Large defects of the scalp following traumatic losses, removal of malignant tumors, radiotherapy-induced necrosis, burns, infections, and congenital disorders are often encountered by plastic surgeons (9). The repair of such defects is dependent upon their location, size and depth (3).

Repair of the large defects may be problematic in the hair-bearing skin site due to its tight and resistant structure. The correct design of such flaps includes incorporation of large vascular pedicles and wound closure without excessive tension (9,12,13,16).

Knowledge of scalp anatomy is essential for preparing scalp flaps (16). The skin layers of the scalp are easy to remember: SCALP (S: skin; C: subcutaneous tissue; A: aponeurotic layer; L: loose areolar tissue; P: pericranium). The skin of the scalp is the thickest in the body and the subcutaneous tissue contains the blood vessels, nerves and hair follicles (9,13). The only exception of this is the superficial temporal artery lying in the temporoparietal fascia. The main arteries of the scalp are the superficial temporal artery, with its frontal and parietal branches, the posterior auricular artery and the occipital artery, all of which are branches of the external carotid artery. Supraorbital and trochlear branches of the internal carotid artery are the other sources of arterial inflow(9,17).

Considering the large scalp, head and neck defects, although all steps of the reconstruction ladder is valid here, tissue expansion and free flaps stand out as the most appropriate options for satisfactory aesthetic and functional results (9). However, elderly patients with poor general condition and comorbid disorders or the patients with advanced malignancies are poor candidates for complicated, long lasting and staged surgical procedures. These patients require safe, reliable and durable defect covering a quick manner.

This study describes the use of large scalp flaps as a salvage procedure in the reconstruction of large scalp, head and neck defects in elderly patients with poor general condition or advanced malignancy.

MATERIAL and METHODS

The presented study includes 22 patients operated between 2007 and 2011 for the reconstruction of large defects of the hair-bearing skin and head/neck region with large scalp flaps. A defect exceeding 25 cm² area was classified as "large" as defined in the previous studies (9). The patients' medical records were analyzed. Their demographic data, past medical and surgical history including comorbidity, pathologic findings, location and the extension of scalp and head and neck defects, the method of reconstruction, postoperative complications, follow-up duration, and outcomes were evaluated. Major complications includes death, events requiring surgical revision, or postoperative disorders requiring an intensive care medical intervention; whereas minor complications were defined as wound related issues managed successfully applying conservative therapy.

Surgical procedure: In terms of malignancies, first the tumor was totally excised with safe surgical margins based on the histological diagnosis. The neurosurgeon was involved primarily in cases of skin tumors infiltrating the internal tabula or duramater and primary brain tumors infiltrating the skull or scalp tissue. In patients with tumor infiltration of the calvarial bone or duramater, the resection of these tissues was combined with the immediate reconstruction of the scalp tissues with a large scalp flaps. The bony defects were not reconstructed.

For the defects caused by traumatic losses or infectious situations, first all necrotic tissues were debrided. After reaching the healthy bleeding tissues the excision or debridement process was ended and the reconstructive step was performed immediately with the use of a large scalp flap.

The scalp flap was designed to include at least one major feeding vessel of the scalp. The flap was elevated at the subgaleal plane and transposed to cover the defect. A hemovac drain was placed under the flap, and the closure was performed in two layers with the use of 3/0 polyglactin sutures for the subcutaneous layer and 4/0 polypropylene suture and staples for the skin closure. The flap donor sites were reconstructed with split thickness skin grafts harvested from the anterior thigh region.

RESULTS

Twelve of the patients were male and ten of them were female. The mean age of the patients was 56 years (ranging between 45-81 years). Etiologic factors were tumor ablation in 16 cases (72.7%), trauma in 4 cases (18.2%) and infection in 2 cases (9.1 %). Considering the tumor cases, 13 (81.3%) of them were caused by the skin malignancies, while 2 (12.5%) of them had primary intracranial origin. In one case (6.2%), the surgical procedure and the scalp flap was performed palliatively for the brain and calvarial metastases of the primary lung cancer. Considering the skin malignancies, 11 of them were squamous cell cancer, 1 of them was basal cell cancer and 1 of them was basosquamous cell cancer.

The defect sizes ranged from 5x5cm to 18x14cm. 18 flaps were transposed and 4 flaps were rotated to the defect (Table I). Each flap included at least one major artery of the scalp. Flaps were used to cover a periorbital defect in 1 case, a periauricular defect in one case and scalp defects in the remaining 20 cases (Figure 1-4). Cranial bones were infiltrated in 6 cases and the duramater was infiltrated in 3 of them while the brain parenchyma was involved only in 2 cases.

Twenty patients (90.9%) had concomitant disorders including hypertension, diabetes mellitus, chronic obstructive lung diseases or other malignancies.

All flaps were completely survived except in one case in which a partial necrosis in the distal 2 cm margin occurred. In that case the flap was revised by reelevating and retransposing to cover the defect after debridement of the necrotic part. This case was accepted as a major complication with the ratio of

Table I: Patient Details

Patient no	Sex	Age	Defect size	Etiology of defect	Flap type	Complication
1	Male	57	6x10	Trauma	Transposition flap	None
2	Male	81	13x10	Squamous cell carcinoma	Transposition flap	Delayed healing of donor site
3	Male	55	16x12	Squamous cell carcinoma	Transposition flap	None
4	Male	45	5x9	Trauma	Transposition flap	None
5	Female	53	5x5	Infection	Rotation flap	None
6	Male	10	5x5	Squamous cell carcinoma	Rotation flap	Wound dehiscence
7	Male	60	6x5	Squamous cell carcinoma	Transposition flap	None
8	Female	47	15x10	Adenoid cystic carcinoma	Transposition flap	None
9	Male	45	8X6	Trauma	Transposition flap	None
10	Female	55	5x6	Trauma	Transposition flap	None
11	Female	61	14x18	Squamous cell carcinoma	Transposition flap	None
12	Male	52	5x5	Squamous cell carcinoma	Rotation flap	None
13	Female	59	5x5	Infection	Transposition flap	Partial necrosis
14	Male	52	5x6	Squamous cell carcinoma	Transposition flap	None
15	Male	58	5x5	Squamous cell carcinoma	Rotation flap	None
16	Female	56	6x6	Atypical meningioma	Transposition flap	None
17	Female	69	5x7	Primary lung cancer metastases	Transposition flap	None
18	Male	78	12X9	Squamous cell carcinoma	Transposition flap	Wound dehiscence
19	Female	69	11X9	Basosquamous cell carcinoma	Transposition flap	None
20	Male	46	5x5	Basal cell carcinoma	Transposition flap	None
21	Female	55	6x5	Squamous cell carcinoma	Transposition flap	None
22	Female	65	13X13	Squamous cell carcinoma	Transposition flap	None

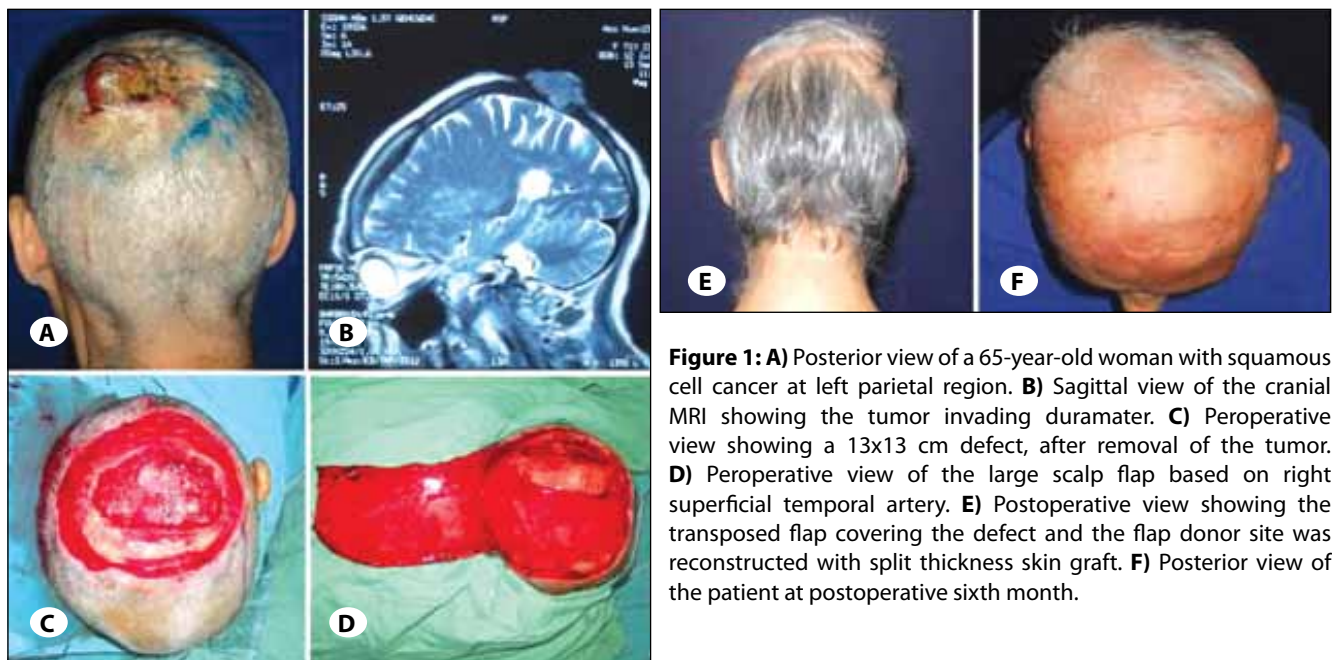


Figure 1: **A)** Posterior view of a 65-year-old woman with squamous cell cancer at left parietal region. **B)** Sagittal view of the cranial MRI showing the tumor invading duramater. **C)** Peroperative view showing a 13x13 cm defect, after removal of the tumor. **D)** Peroperative view of the large scalp flap based on right superficial temporal artery. **E)** Postoperative view showing the transposed flap covering the defect and the flap donor site was reconstructed with split thickness skin graft. **F)** Posterior view of the patient at postoperative sixth month.

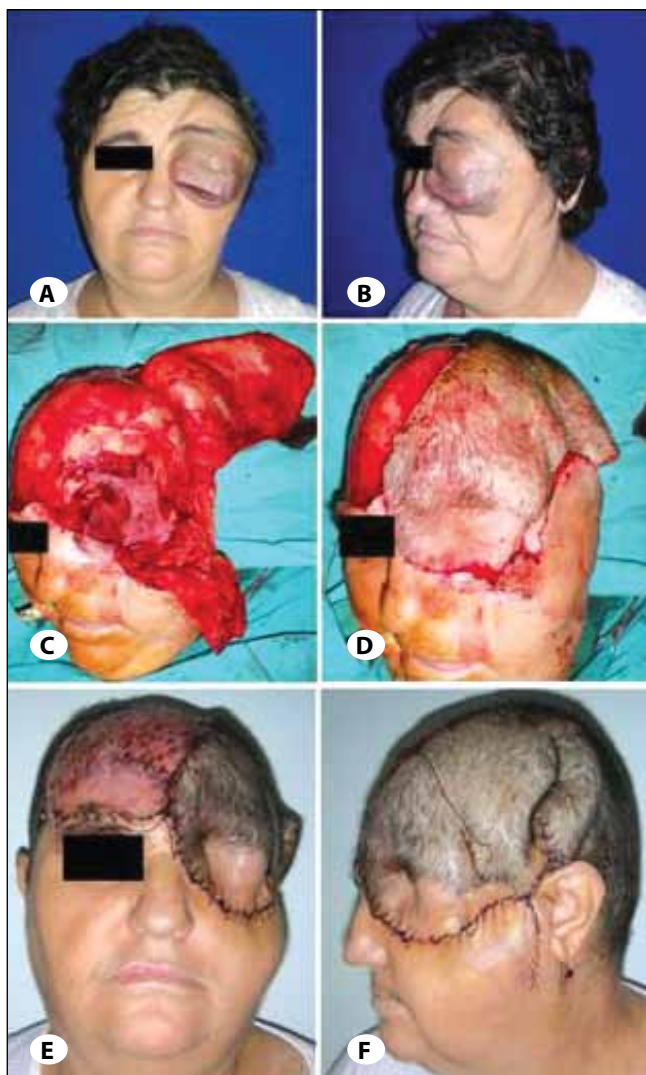

Figure 2: **A)** Anterior view of a 47-year-old woman with adenoid cystic carcinoma of left orbital region. **B)** Left oblique view of the same patient. **C)** Peroperative photo showing the soft tissue defect, the tumor was excised and the periorbital bones were reconstructed with porous polyethylene. **D)** Peroperative photo showing the large scalp flap measuring 15x10 cm based on right occipital region, transposed to cover the defect. **E)** Anterior view of the patient on postoperative tenth day showing reconstruction of left periorbital region with the large scalp flap. **F)** View of left side of the same patient on tenth day postoperatively.

4.5%. No other major complications were recorded. Minor complications were recorded in 3 cases (13,5%). 2 of them were wound dehiscence at the flap margin and one of them was delayed wound healing of the graft donor site. These patients healed with medical treatment without the need of surgical intervention.

Flaps provided a satisfactory and durable reconstruction in the late follow-up term. The average follow-up period was 14 months, ranging between 2 and 36 months. During the follow-up period, we observed 3 recurrent tumor cases. One

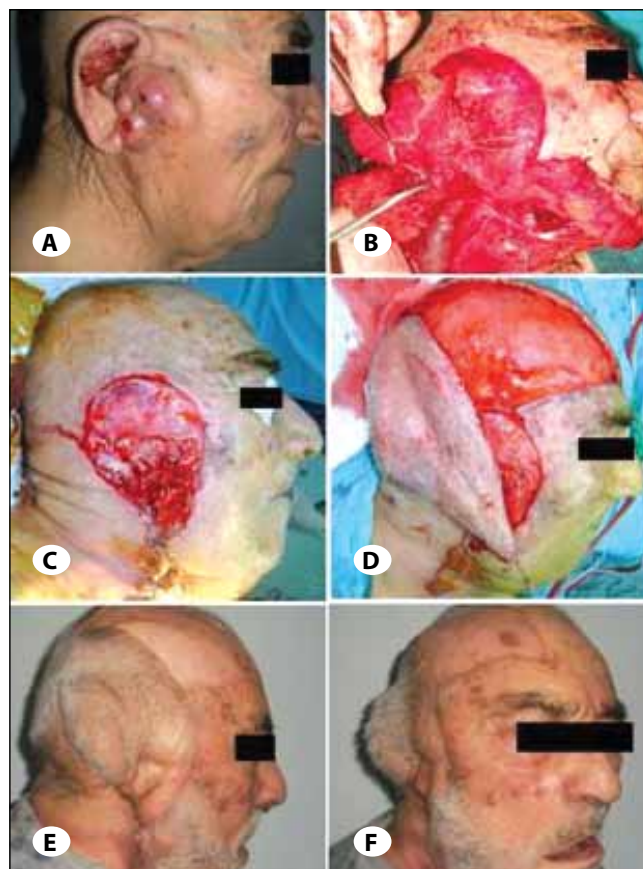


Figure 3: **A)** Lateral view of an 81-year-old man with squamous cell cancer at right periauricular region. **B)** Peroperative view (right ear amputation, total parotidectomy, excision of the facial nerve and occipitally extended neck dissection). **C)** Peroperative view showing 13x10 cm right periauricular defect. **D)** Right occipital artery based scalp flap transposed to cover the defect. **E)** Postoperative lateral view of the patient on third month, the donor site of the flap was covered with a split thickness skin graft harvested from right anterior thigh region. **F)** Postoperative anterior oblique view of the patient on third month.

of them was due to the adenoid cystic carcinoma infiltrating the left periorbital region. The other two cases were squamous cell carcinoma of the skin. The patient who was operated palliatively for the metastasis of the primary lung cancer was lost because of respiratory failure during the follow-up period.

All patients complained of the dog ears at the base of the flap in the early postoperative period. However, none of the patients requested a secondary surgical procedure for the improvement of the aesthetic results as they were all in advanced age group or had advanced malignancy.

DISCUSSION

The scalp defects are caused by acute trauma, infection, tumor extirpation, radiation necrosis (9). The history of scalp reconstruction parallels developments in plastic surgery techniques. Augustin Belloste, in 1696 advocated early perforation of bare cranium to allow granulation tissue

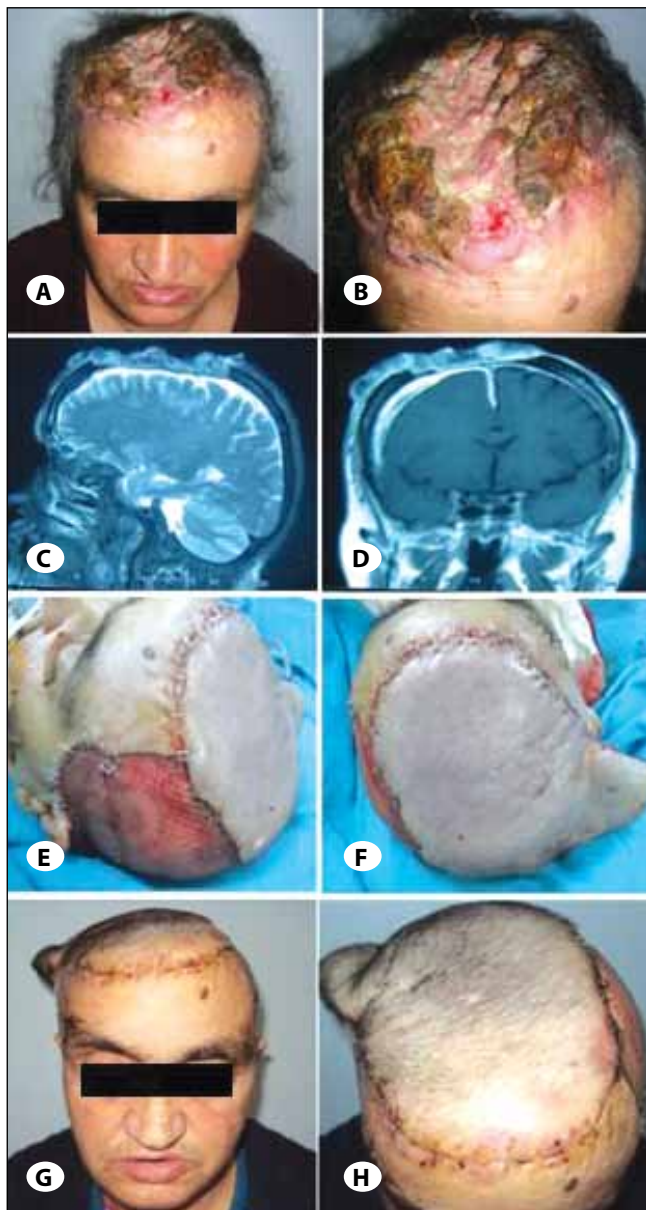


Figure 4: **A)** 61 years old woman with invasive Squamous cell cancer. **B)** Vertex view of the patient showing widely tumor invasion of the scalp. **C)** Sagittal view of cranial MRI showing the tumor invading duramater. **D)** Coronal view of cranial MRI. **E,F)** Peroperative view of the patient showing the transposed flap (18X14cm) based on right postauricular region and donor site closure with split skin graft. **G,H)** Postoperative third week view of the patient.

and secondary epithelialization (4). This was practiced until Netolitzky, in 1871, used skin grafting of the calvaria after the presence of granulation tissue (4). In 1908, Robinson demonstrated the success of skin grafting on intact periosteum in the absence of granulation tissue (4). Thereafter many authors demonstrated successful reconstruction with local flaps (2,6,8,11,18). Neumann reported the first clinical use of tissue expansion in 1957, when he used the expanded scalp tissue for ear reconstruction (15). With the advances

in microsurgery, Miller et al. successfully replanted a totally avulsed scalp with return of normal hair growth and frontalis function in 1976 (14). Multiple authors have since presented series of patients who have had near total scalp defects reconstructed with free tissue transfer (9).

Scalp defects smaller than 2 cm² can usually be closed with direct primary suturing (9). The medium sized defects between 2 cm² and 25 cm² or in another terms the defects between 3-4 cm and 6-8 cm diameter, cannot be closed primarily and requires skin grafts, local rotation or advancement flaps or staged procedures by means of tissue expanders. In order to close the larger defects as in our study, serial tissue expansions, regional flaps especially for occipital defects and free flaps can be used (7,9).

The use of skin grafts for reconstruction requires an intact pericranium. Furthermore, skin grafts usually result in unstable, depressed, and unsightly scars, which have to be rated as poor from both functional and aesthetic standpoints. Moreover skin grafts are not strong enough to withstand the negative effects of the radiotherapy procedure. Closure of the defect with vascular and healthy tissues is mandatory in cases requiring radiotherapy in the postoperative period. In the absence of a pericranium and when grafting is the only repair option, perforations in the external cortical layer of the skull allow the formation of granulation tissue that would improve the prognosis of the second-step free skin graft (5,16).

Tissue expansion eliminates donor site grafting and facilitates direct defect closure. It also supplies hair-bearing scalp tissue with good aesthetic results. However, reconstruction with expansion is a staged procedure and has its own potentially associated complications which vary from 6% to 25% (1,10).

Regional nonadjacent tissue transfer techniques are limited to very specific indications and specific locations (7).

Once the defect size surpasses a diameter of 6 to 8 cm within the hair-bearing scalp and 4 to 5 cm at the hairline, free tissue transfer is suggested (7). Free tissue transfer is also the best option if well-vascularized tissue is needed to cover neurocranial structures, exposed alloplastic material and areas with substantial infection. Although the functional outcome is good, the aesthetic results are only moderate due to the lack of hair on the transferred tissue. Greater consideration should be given to free tissue transfer instead of local flaps for reconstruction in the cases who were previously subjected to radiation therapy or will be irradiated postoperatively (7,19).

Although all steps of the reconstruction ladder are valid here tissue expansion and free flaps stand out as the most appropriate options for satisfactory aesthetic and functional results (9). However, the extent of malignancy in oncological cases with its direct impact on patient survival is the highest imperative, second to which are functional and aesthetic considerations. Existing general algorithms for scalp reconstruction are of limited value here, as the aforementioned considerations are not sufficiently addressed (7).

Elderly patients with comorbid conditions or patients with advanced malignancies are not good candidates for complicated, long and staged surgical procedures. In the presented study, cases were in advanced age group and majority of them had poor general health status due to comorbid situations or advanced malignancies. Most of them were in high risk group for general anaesthesia. Therefore we performed a single stage, uncomplicated, low-risky and a short-term procedure.

Formation of dog ears at the base of the flaps is the most common drawback of large scalp transfer. This excess tissue can be excised under local anesthesia in a secondary procedure in the late term. However the presented cases were all in advanced age group or had advanced malignancies in which the flaps were performed as a salvage procedure. All patients learned to camouflage the dog ears in the late term obviating the need of revision.

CONCLUSION

In conclusion, large scalp flaps should be considered as a salvage procedure for reconstruction of large scalp, head and neck defects especially for palliative situations in elderly patients with significant comorbidities and advanced malignancies.

REFERENCES

1. Azzoloni A, Riberti C, and Cavalca D: Skin expansion in head and neck reconstructive surgery. *Plast Reconstr Surg* 90: 799-807, 1992
2. Coleman CC Jr: Scalp flap reconstruction in head and neck cancer patients. *Plast Reconstr Surg Transplant Bull* 24: 45-54, 1959
3. Demir Z, Velidedeoğlu H, Celebioğlu S: V-Y-S plasty for scalp defects. *Plast Reconstr Surg* 112:1054-1058, 2003
4. Ducic Y: Total avulsion of the scalp. *Facial Plast Surg Clin North Am* 17: 177-187, 2009
5. Frodel JL Jr, Ahlstrom K: Reconstruction of complex scalp defects: The "Banana Peel" revisited. *Arch Facial Plast Surg* 6:54-60, 2004
6. Gaisford JC, Hanna DC, Susen AF: Major resection of scalp and skull for cancer with immediate complete reconstruction; fourteen cases. *Plast Reconstr Surg Transplant Bull* 2:335-344, 1958
7. Iblher N, Ziegler MC, Penna V, Eisenhardt SU, Stark GB, Bannasch H: An algorithm for oncologic Scalp Reconstruction. *Plast Reconstr Surg* 126:450-459, 2010
8. Kazanjian VH: Repair of partial losses of the scalp. *Plast Reconstr Surg* 12:325-334, 1953
9. Leedy JE, Janis JE, Rohrich RJ: Reconstruction of acquired scalp defects: An Algorithmic Approach. *Plast Reconstr Surg* 116:54e-72e, 2005
10. Manders ER, Schenden MJ, Furrey JA, Hetzler PT, Davis TS, Graham WP 3rd: Soft-tissue expansion: Concepts and complications. *Plast Reconstr Surg* 74: 493-507, 1984
11. Marcks KM, Trevaskis A, Nauss TJ: Scalp defects and their repair. *Plast Reconstr Surg* 7:237-243, 1951
12. Mehrotra S, Nanda V, Shar RK: The islanded scalp flap: A better regional alternative to traditional flaps. *Plast Reconstr Surg* 116:2039-2040, 2005
13. Michaelidis IG, Stefanopoulos PK, Papadimitriou GA: The triple rotation scalp flap revisited: A case of reconstruction of cicatricial pressure alopecia. *Int J Oral Maxillofac Surg* 35:1153-1155, 2006
14. Miller GD H, Anstee EJ, Snell JA: Successful replantation of an avulsed scalp by microvascular anastomoses. *Plast Reconstr Surg* 58:133-136, 1976
15. Neumann CG: The expansion of an area of skin by progressive distension of a subcutaneous balloon. *Plast Reconstr Surg* 19:124-130, 1957
16. Newman MI, Hanasono MM, Disa JJ, Cordeiro PG, Mehrara BJ: Scalp reconstruction: A 15-year experience. *Ann Plast Surg* 52:501-506, 2004
17. Onishi K, Maruyama Y, Hayashi A, Inami K: Repair of scalp defect using a superficial temporal fascia pedicle VY advancement scalp flap. *Br J Plast Surg* 58:676-680, 2005
18. Straith CL, Beers MD: Scalp avulsions: Report of early homo and zoo-grafting and recent split scalp grafting. *Plast Reconstr Surg* 6:319-326, 1950
19. Yuen JC, Hochberg J: Free flap coverage of scalp defects following radiation. *J Ark Med Soc* 100:194-195, 2003