

# Spinal Hemangioblastoma Located in the Conus Medullaris: Case Report

## ABSTRACT

Although hemangioblastomas may be seen in various locations of the central nervous system (CNS), intradural-extramedullary spinal hemangioblastomas are extremely rare. Hemangioblastomas are histologically benign lesions. They may cause important neurological deficits and may bleed during the operation. In our case, the tumour was located extramedullary at the conus medullaris level. In this report, we discuss spinal hemangioblastomas with this special localization.

**KEY WORDS:** Conus medullaris, Hemangioblastoma, Intradural-extramedullary

## INTRODUCTION

Hemangioblastomas may originate from anywhere in the central nervous system (CNS) sporadically or related to the von Hippel-Lindau (VHL) syndrome. Although they are histologically benign, they may cause important neurological problems depending on their localization and size. In our case the tumour was located egzophytically at the level of the conus medullaris. Although spinal hemangioblastomas have been reported several times, we could find only one case located at the conus medullaris other than our case.

## CASE REPORT

A 33-year-old female presented with back pain and right leg pain. The back pain had been present for two years and had become worse and spread to the right leg in the last two months. Neurological examination was normal except slight paresis on right foot dorsiflexion. Lumbar magnetic resonance imaging (MRI) revealed an extramedullary mass that was arising from the conus medullaris at the T12-L1 level with a size of 30x6x19 mm. (Figure 1, 2). The cauda equina fibers were separated by the lesion and morphologically it resembled an ependymoma according to the MRI report. The patient was operated on using T12-L1-L2 laminoplasty. The bone and extradural tissues were normal. The dura and arachnoid were opened in the midline followed by microsurgical exploration. The tumour was observed in the conus medullaris covered with pia. (Figure 3). The tumour was removed totally with microsurgery after coagulation and cutting of the feeding artery. There was no additional neurological deficit after the surgery. The histopathology report revealed a hemangioblastoma (Figure 4). No retinal angioma was observed during the ophthalmological examination. There was no other mass lesion noticed in superior and inferior abdominal ultrasonography (USG). The cranial and the rest of the spinal MRI were also normal. As the only mass lesion observed was in the cauda equina, the patient was accepted to have sporadic spinal hemangioblastoma. There was no residual tumour in the postoperative MRI.

Cem DİNÇ<sup>1</sup>  
A. Celal İPLİKÇİOĞLU<sup>2</sup>  
Deniz ÖZCAN<sup>3</sup>  
Mustafa ERDAL<sup>4</sup>  
Kerem BIKMAZ<sup>5</sup>  
Erdinç ÖZEK<sup>6</sup>

<sup>1,2,4,5,6</sup> Department of Neurosurgery,  
Ministry of Health Okmeydanı  
Education and Research Hospital,  
Istanbul, Turkey  
<sup>3</sup> Department of Pathology,  
Ministry of Health Okmeydanı  
Education and Research Hospital,  
Istanbul, Turkey

Received : 08.03.2006

Accepted : 21.09.2006

Correspondence address

**Erdinç ÖZEK**

19 Mayıs Mahallesi, Yeni İlhan Sokak,

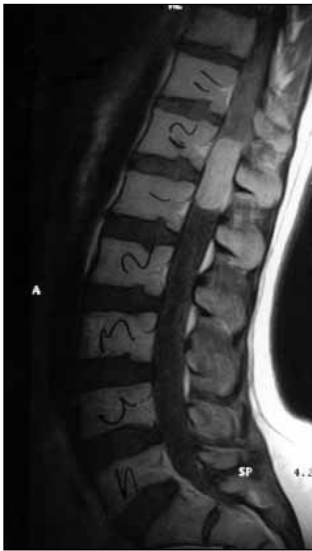No:32 Daire:20

Şişli, Istanbul, Turkey

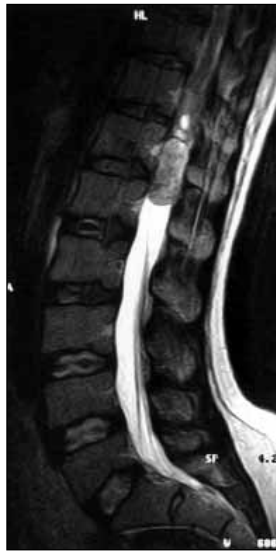Phone : +90 212 2217777/1280

Fax : +90 212 2217800

E-mail : erdincozek@gmail.com



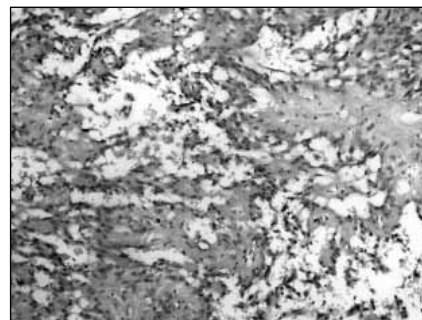
**Figure 1:** Sagittal T1-weighted magnetic resonance image with contrast revealing the lesion at conus medullaris level.



**Figure 2:** Sagittal T2-weighted magnetic resonance image revealing the cauda equina fibers separated by the lesion.



**Figure 3:** Intraoperative view of the tumour after dura was opened.



**Figure 4:** The tumour is characterized by an anastomosing network of delicate vessels that separate groups of large polygonal cells (HE, X200).

### DISCUSSION

Hemangioblastomas are extremely vascular tumours and 67-75% are seen sporadically while 25-33% are accompanied by the VHL syndrome (2, 19, 20). They can be cystic, solid or mixed and their size varies (25). Hemangioblastomas are mostly seen in the cerebellum (44-72%) and spinal cord (13-50%), spinal and especially extramedullary localizations are extremely rare (1, 5, 8, 9, 11, 13, 6, 17). Although they can be observed at all levels of the spinal canal, cervical and thoracic lesions are frequently seen (19, 4). Spinal hemangioblastomas constitute 1.6-2.1% of all spinal canal tumours, 21-28% of them are intradural-extramedullary and 30% are related to the VHL syndrome (11, 4).

Only four extramedullary-located filum terminale hemangioblastomas have been previously reported and all were diagnosed postoperatively by the histopathology as in our case (23). There are at least 20 reports of lesions arising from the proximal root, cauda equina or peripheral nerves (7).

Ismail et al (12) reported a case with VHL syndrome where they observed several asymptomatic microscopic hemangioblastomas in the posterior nerve roots at the cervical, thoracic and lumbar levels at the autopsy.

VHL is an autosomal dominant related syndrome (10). It is a familial syndrome that occurs as a result of a mutation and deletion of the VHL gene on the 3p25 chromosome (14). Although a genetic analysis was not performed, we did not find retinal angioma in the ophthalmological examination or a renal or pancreas mass during the abdominal USG.

Hemangioblastomas are mostly seen in the 3rd and 4th decades and are much likely to occur in males than females (2, 19, 21, 24). Radicular pain, back pain, paraparesia and sphincter dysfunction are the possible symptoms and signs of spinal hemangioblastomas (3). Numbness was the most common presenting symptom in the Lonser et al review (12). Our patient first presented with back and right leg pain.

Recent studies have shown that vascular endothelial growth factor secreted from stromal cells is the most important factor in endothelial cell proliferation (18). These tumours are histologically benign and neurological dysfunction is related to tumour size and location (15).

The aim of surgery should be total removal, as recurrence rates are high following subtotal removal even if postoperative radiotherapy is administered (4,26). The tumour nodule may be small, similar to cerebellar hemangioblastomas (4). In our case, the

tumour was solid and total removal was achieved without any massive bleeding. Resection is recommended for hemangioblastomas arising from the lumbosacral region when they become symptomatic (15).

Ependymoma, schwannoma, neurofibroma, meningioma, metastasis and spinal vascular malformations should be kept in mind in the differential diagnosis. Selective spinal angiography is an additional tool for the preoperative evaluation of a hemangioblastoma, either to confirm the diagnosis or to perform preoperative embolisation to decrease bleeding during surgery (23).

The postoperative prognosis is excellent in sporadic intradural hemangioblastomas with a single lesion. Total removal of the lesion results in cure (6, 22).

#### REFERENCES

- Baker KB, Moran CJ, Wippold FJ 2nd, Smirniotopoulos JG, Rodriguez FJ, Meyers SP, Siegal TL. MR imaging of spinal hemangioblastoma. *Am J Roentgenol* 174: 377-82, 2000
- Baumgartner JE, Wilson CB. Removal of posterior fossa and spinal hemangioblastomas, in Wilson CB (ed). *Neurosurgical Procedures: Personal Approaches to Classic Operations*. Baltimore: Williams&Wilkins, 1992, 188-199pp
- Brisman JL, Borges LF, Ogilvy CS. Extradural hemangioblastoma of the conus medullaris, case report. *Acta Neurochir* 142: 1059-1062, 2000
- Browne TR, Adams RD, Roberson GH. Hemangioblastoma of the spinal cord. *Arch Neurol* 33: 435-441, 1976
- Chu b, Terae S, Hida K, Furukawa M, Abe S, Miyasaka K. MR findings in spinal hemangioblastoma: correlation with symptoms and with angiographic and surgical findings. *Am J Neuroradiol* 22: 206-17, 2001
- Emery E, Hurth M, Lacroix-Jousselin C, David P, Richard S. Intraspinial hemangioblastoma. Apropos of a recent series of 20 cases. *Neurochirurgie* 40: 165-173, 1994
- Escott EJ, Kleinschmidt-DeMasters BK, Brega K, Lillehei KO. Proximal nerve root spinal hemangioblastomas: presentation of three cases, MR appearance, and literature review. *Surg Neurol* 61: 262-73, 2004
- Friedrich CA. von Hippel-Lindau syndrome. A pleomorphic condition. *Cancer* 86: S2478-S2482, 1999
- Giannini C, Scheithauer BW, Hellbusch LC, Rasmussen AG, Fox MW, McCormick SR, Davis DH. Peripheral nerve hemangioblastoma. *Mod Pathol* 11: 999-1004, 1998
- Glenn GM, Linehan WM, Hosoe S, Latif F, Yao M, Choyke P, Gorin MB, Chew E, Oldfield E, Manolatos C. Screening for von Hippel-Lindau disease by DNA polymorphism analysis. *JAMA* 267: 1226-1231, 1992
- Hurth M. Intraspinial hemangioblastomas. *Neurochirurgie* 21: 1-136, 1975
- İsmail S, Cole G. von Hippel-Lindau syndrome with microscopic hemangioblastomas of the spinal nerve roots. *J Neurosurg* 60: 1279-81, 1984
- Lamiell JM, Salazar FG, Hsia YE. von Hippel-Lindau disease affecting 43 members of a single kindred. *Medicine (Balt)* 68: 1-29, 1989
- Latif F, Tory K, Gnarr J, Yao M, Duh FM, Orcutt ML, Stackhouse T, Kuzmin I, Modi W, Geil L. Identification of the von Hippel-Lindau disease tumor suppressor gene. *Science* 260: 1317-1320, 1993
- Lonser RR, Wait SD, Butman JA, Vortmeyer AO, Walther MM, Governale LS, Oldfield EH. Surgical management of lumbosacral nerve root hemangioblastomas in von Hippel-Lindau syndrome. *J Neurosurg* 99: 64-69, 2003
- Lonser RR, Weil RJ, Wanebo JE, DeVroom HL, Oldfield EH. Surgical management of spinal cord hemangioblastomas in patients with von Hippel-Lindau disease. *J Neurosurg* 98: 106-116, 2003
- Maddock IR, Moran A, Maher ER, Teare MD, Norman A, Payne SJ, Whitehouse R, Dodd C, Lavin M, Hartley N, Super M, Evans DG. A genetic register for von Hippel-Lindau disease. *J Med Genet* 33: 120-127, 1996
- Morii K, Tawaka R, Washiyama K, Kumanishi T, Kuwano R. Expression of VEGF in capillary hemangioblastoma. *Biochem Biophys Res Commun* 194: 749-755, 1993
- Murota T, Symon L. Surgical management of hemangioblastoma of the spinal cord: a report of 18 cases. *Neurosurgery* 25: 699-708, 1989
- Neumann HP, Eggert HR, Weigel K, Friedburg H, Wiestler OD, Schollmeyer P. Hemangioblastomas of the central nervous system. A 10-year study with special reference to von Hippel-Lindau syndrome. *J Neurosurg* 70: 24-30, 1989
- Solomon RA, Stein BM. Unusual spinal cord enlargement related to intramedullary hemangioblastoma. *J Neurosurg* 68: 550-553, 1988
- Spetzger U, Bertalanffy H, Huffmann B, Mayfrank L, Reul J, Gilsbach JM. Hemangioblastomas of the spinal cord and brainstem: diagnostic and therapeutic features. *Neurosurg Rev* 19: 147-151, 1996
- Tibbs RE, Harkey HL, Raila FA. Hemangioblastoma of the Filum Terminale: case report. *Neurosurgery* 44: 221-3, 1999
- ory K, Brauch H, Linehan M, Barba D, Oldfield E, Filling-Katz M, Seizinger B, Nakamura Y, White R, Marshall FF. Specific genetic change in tumors associated with von Hippel-Lindau disease. *J Natl Cancer Inst* 81: 1097-1101, 1989
- Vortmeyer AO, Gnarr JR, Emmert-Buck MR, Katz D, Linehan WM, Oldfield EH, Zhuang Z. von Hippel-Lindau gene deletion detected in the stromal cell component of a cerebellar hemangioblastoma associated with von Hippel-Lindau disease. *Hum Pathol* 28: 540-543, 1997
- Yasargil MG, Antice I, Laciga R, de Preux I, Fideler RW, Boone SC. The microsurgical removal of intramedullary spinal hemangioblastomas: Report of twelve cases and review of the literature. *Surg Neurol* 6: 141-148, 1976