

Successful Transarterial Embolization of a Posttraumatic Fistula Between a Posterior Communicating Artery Aneurysm and the Cavernous Sinus: A Case Report

Posterior Komünikan Arter Anevrizması ile Kavernöz Sinüs Arasında Posttravmatik Fistülün Başarılı Transarteriyel Embolizasyonu: Bir Olgu Sunumu

Yin JINBO, Liu JUN, Mou KEJIE, Zhou ZHENG

Xinqiao Hospital, Third Military Medical University, Department of Neurosurgery, Chongqing, China

Corresponding Author: Zhou ZHENG / E-mail: zhengzhou727@gmail.com

ABSTRACT

Posterior communicating artery (PCoA) aneurysm-cavernous sinus fistulae are an extremely rare complication of head injury. The treatment of PCoA aneurysm-cavernous sinus fistulae has not been well described. A 27-year-old man was admitted with a retroocular bruit and blurred vision of the left eye seven months after a severe head injury. We report the angiographic appearance of a posterior communicating artery (PCoA) aneurysm with a fistula to the cavernous sinus. This injury had been previously misinterpreted to be a PCoA aneurysm by computerized tomographic angiography (CTA). The patient was successfully treated with coils and Onyx of a fistula between the PCoA aneurysm and cavernous sinus.

KEYWORDS: Carotid-cavernous sinus fistula, Aneurysm, Endovascular therapy, Posterior communicating artery

ÖZ

Posterior komünikan arter (PCoA) anevrizması-kavernöz sinüs fistülü kafa travmasının çok nadir bir komplikasyonudur. PCoA anevrizması-kavernöz sinüs fistülünün tedavisi iyi tanımlanmamıştır. 27 yaşında bir erkek şiddetli bir kafa travmasından yedi ay sonra retrooküler bruit ve sol gözde bulanık görmeyle başvurdu. Kavernöz sinüse fistülle birlikte posterior komünikan arter (PCoA) anevrizmasının anjiyografik görünümünü bildiriyoruz. Bu yaralanma daha önce bilgisayarlı tomografik anjiyografide (BTA) yanlışlıkla PCoA anevrizması olarak yorumlanmıştı. Hastada PCoA anevrizmasıyla kavernöz sinüs arasındaki fistül Onyx ve sarmallarla başarıyla tedavi edildi.

ANAHTAR SÖZCÜKLER: Karotid-kavernöz sinüs fistülü, Anevrizma, Endovasküler tedavi, Posterior komünikan arter

INTRODUCTION

Direct carotid-cavernous fistulae are communications between the intracavernous carotid artery and the cavernous sinus. They most often result from head trauma associated with basal skull fracture. Posterior communicating artery (PCoA) aneurysm-cavernous sinus fistulae are an extremely rare complication of head injury (1, 4, 6, 7). The treatment of PCoA aneurysm-cavernous sinus fistulae has not been well described. In the literature, two cases of this kind of fistula that were treated with either surgical treatment or endovascular embolization were reported (1, 6). One case was treated by performing clip ligation of the anterior origin of the PCoA; however, this procedure failed to exclude the fistula because of residual flow from the posterior aspect of the PCoA (6). The other case was successfully treated with endosaccular coil embolization via the transarterial route (1). Here, we describe

a case of a traumatic fistula between the PCoA aneurysm and the cavernous sinus that was successfully treated with transarterial embolization.

CASE REPORT

A 27-year-old man suffered a head injury with subsequent loss of consciousness in April 2008, seven months before admission. In October 2008, six months after the injury, cranioplasty was performed at another hospital. Five days before admission to our hospital, a left retroocular bruit that was synchronous with the patient's pulse and blurred vision gradually developed. He was admitted to our department with a suspected PCoA aneurysm according to CTA performed at the previous hospital. Right internal carotid and right vertebral angiograms revealed that the cavernous sinus fistula was supplied by a large dome-shaped ruptured aneurysm with

dimensions of 15 mm 21 mm arising from the PCoA (Figure 1A-D). A vertebral artery injection opacified the aneurysm, cavernous sinus, and the supraclinoid internal carotid artery. Thus, the patient was diagnosed with a posttraumatic PCoA aneurysm-cavernous sinus fistula. Using the transfemoral route, we attempted to place an Excelsior SL-10 microcatheter into the aneurysm through the proximal and distal PCoA, but we failed. We then placed the microcatheter in the distal PCoA through a guiding catheter positioned in the ipsilateral vertebral artery, and one Guglielmi detachable coil (GDC)-10 (2 mm 3 cm; Boston Scientific, Massachusetts, USA) was deposited into the artery. An additional GDC-10 coil (2 mm 2 cm) was also deposited. Immediately after the procedure, angiography demonstrated complete occlusion of the artery. The Excelsior SL-10 catheter was subsequently advanced through the right internal carotid artery and to the proximal PCoA. Three GDC-10s (2 mm 4 cm; 2 mm 3 cm; 2 mm 3 cm) were deposited. Angiography demonstrated that the proximal PCoA continued to decompress through the fistula. After 0.2 ml of Onyx-18 was injected into the proximal PCoA, angiography demonstrated complete occlusion of the aneurysm and fistula, with sacrifice of the PCoA and without any drainage into the superior ophthalmic vein and inferior petrosal sinus. Three months after treatment, the patient's blurred vi-

sion had completely resolved. Subsequent angiography was scheduled for the patient's six-month follow-up examination, but the patient declined further examination.

DISCUSSION

Direct carotid-cavernous fistulae are usually single connections between the cavernous carotid artery and the cavernous sinus. They most often result from posttraumatic tears of the internal carotid artery (ICA) trunk. A supraclinoid carotid-cavernous sinus fistula caused by head trauma is rare. These types of fistulae include traumatic aneurysms of the supraclinoid ICA in association with a carotid-cavernous fistula, trigeminal cavernous fistulae, and carotid-cavernous fistulae produced by ruptured aneurysms of the meningohypophyseal branch.

The treatment of PCoA aneurysm-cavernous sinus fistulae has not been well described. To date, there are only two other cases reports in which fistulae developed between the PCoA aneurysm and the cavernous sinus after head injury (1, 6), and in another two case reports, fistulae developed between the PCoA and the cavernous sinus (4, 7). Tytle et al. (6) described a presumed posttraumatic direct fistula between a PCoA aneurysm and the cavernous sinus that was treated by performing proximal anterior clip ligation of the PCoA. This

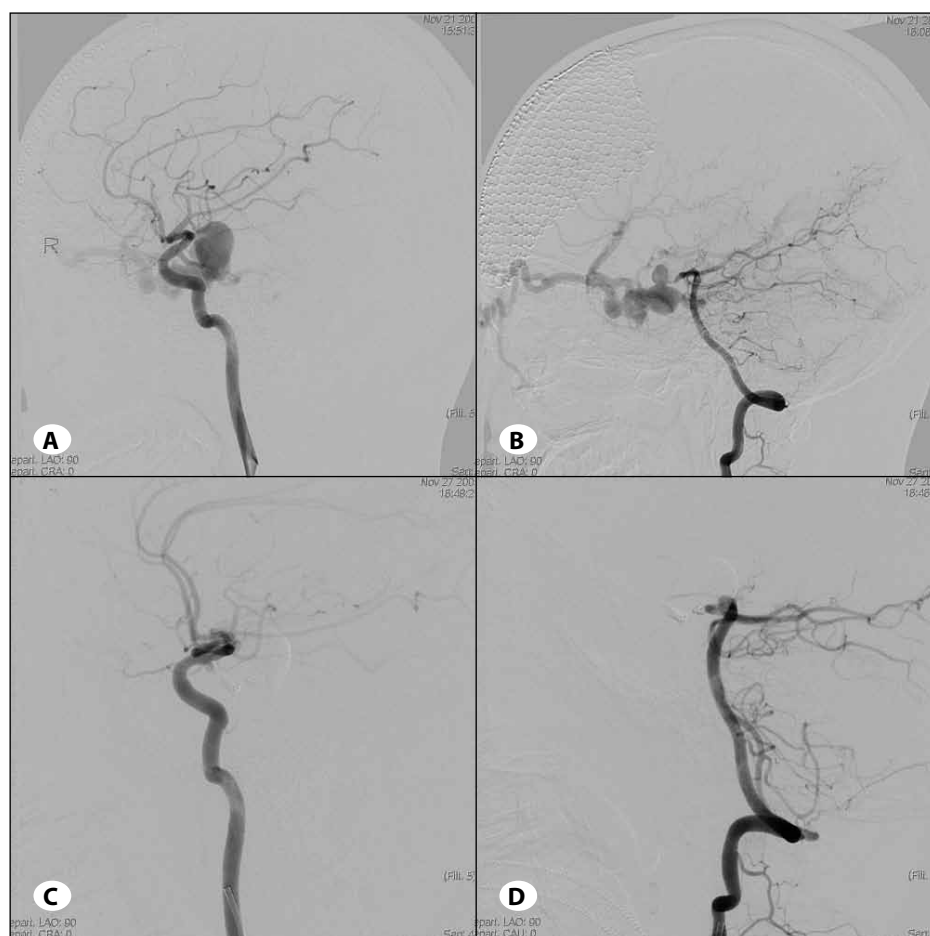


Figure 1: A) Lateral right internal carotid angiogram shows rapid opacification of the cavernous sinus supplied by the ruptured PCoA aneurysm and the engorged ophthalmic vein. **B)** Lateral right vertebral angiogram shows the cavernous sinus fistula supplied by the ruptured PCoA aneurysm. **C)** Lateral right internal carotid artery angiogram immediately after the procedure demonstrates complete occlusion of the aneurysm and fistula with preservation of the internal carotid artery. **D)** Lateral vertebral angiogram demonstrates complete occlusion of the aneurysm and fistula with sacrifice of the PCoA.

procedure failed to exclude the fistula because there was residual flow from the posterior aspect of the PCoA. Kinugasa et al. (4) reported a successful transvenous embolization of a posttraumatic PCoA-cavernous sinus fistula. In that case, the cavernous sinus was accessed through the transfemoral venous inferior petrosal sinus route and ultimately was packed with platinum coils. Weaver et al. (7) reported the successful transarterial coil embolization of a posttraumatic PCoA-cavernous sinus fistula through the PCoA. Chen et al. (1) reported a case of a posttraumatic PCoA aneurysm-cavernous sinus fistula that was successfully treated with endosaccular coil embolization via the transarterial route.

Pedroza et al. (5) determined that dural branches to the cavernous sinus do not originate from the PCoA; therefore, a fistula of the PCoA-cavernous sinus would not occur spontaneously. Our patient had previously been healthy and had no symptoms consistent with a pre-existing PCoA aneurysm. We believe that a posttraumatic pseudoaneurysm between the PCoA and the cavernous sinus might have developed after the head injury. The fistula resulted from the ruptured pseudoaneurysm.

The treatment of a carotid-cavernous fistula depends on the speed of flow through the fistula, its arterial supply, and the routes of venous drainage. The detachable balloon technique is considered by most neurosurgeons to be the best initial therapy for type A carotid-cavernous fistulae (3). Although most direct fistulae of the carotid-cavernous sinus can be obliterated through transarterial embolization (2), the transarterial pathway through the PCoA is too small and dangerous for balloon navigation. The pseudoaneurysm between the PCoA and the cavernous sinus made this route hazardous or impossible. A transvenous approach through the inferior petrosal sinus was also impossible because the pseudoaneurysm could not be obliterated. This approach may obliterate fistulae, but it leaves the fistulous communication and aneurysm in the subarachnoid space after obliterating the shunting to the cavernous sinus (7). This approach will result in the risk of aneurysmal growth and subarachnoid hemorrhage. In addition, we did not consider surgical ligation of the ICA and endovascular therapeutic carotid occlusion because such a procedure not only would have failed to obliterate the fistula, but it also could have greatly complicated future treatment. Hence, we choose a transarterial approach to trap the PCoA through the ICA and vertebral artery (VA).

The flow of the middle segment branches of the PCoA were decreased due to the long-term "blood steal." Because there is a lower resistance for blood going to the fistula than in the normal surrounding branches of the PCoA, the volume of blood directed to the fistula will increase. Over time, the fistula will begin to draw blood away from the normal branches of the PCoA, which were deprived of flow, and the blood cannot

sufficiently perfuse the surrounding parenchyma. Thus, the patient did not show any neurologic deficit after the PCoA was trapped.

To our knowledge, this report describes the first case of successful transarterial embolization with coils and Onyx of a fistula between the PCoA aneurysm and cavernous sinus. PCoA aneurysm-cavernous sinus fistulae may carry a higher risk than intracavernous carotid-cavernous fistulae, because the fistula is located in the subarachnoid space. We considered that simply eliminating the shunt to the cavernous sinus through the transvenous approach would have been insufficient therapy because the fistula remnant within the subarachnoid space might provide a substrate for long-term aneurysmal growth. Thus, instead of occluding the fistula through the transvenous route, we performed transarterial embolization with coils and Onyx. The origin of the fistula in the middle segment of the PCoA was trapped in the proximal and distal segment of the PCoA with dense coils and Onyx packing. Complete occlusion of the fistula was achieved after the middle segment of the PCoA was trapped. This treatment method successfully obliterated the fistula and the aneurysm, avoiding the risk of PCoA aneurysmal growth and subarachnoid hemorrhage. Although the middle segment of the PCoA was sacrificed, the patient did not show any deterioration in presentation.

REFERENCES

1. Chen Y, Jiang DY, Tan HQ, Wang LH, Chen XY, Sun JH: Successful transarterial Guglielmi detachable coil embolization of post-traumatic fistula between a posterior communicating artery aneurysm and the cavernous sinus. A Case Report. *Interv Neuroradiol* 15: 435-441, 2009
2. Debrun GM, Lacour P, Vinuela FV, Fox AJ, Drake CG, Caron JP: Treatment of 54 traumatic carotid-cavernous fistulas. *J Neurosurg* 55: 678-692, 1981
3. Debrun GM, Vinuela F, Fox AJ, Davis KR, Ahn HS: Indications for treatment and classification of 132 carotid-cavernous fistulas. *Neurosurgery* 22: 285-289, 1988
4. Kinugasa K, Higashi H, Ohmoto T: Fistula of the posterior communicating artery and cavernous sinus. *Am J Neuroradiol* 16: 1626-1628, 1995
5. Pedroza A, Dujovny M, Artero JC, Umansky F, Berman SK, Diaz FG, Ausman JI, Mirchandani HG: Microanatomy of the posterior communicating artery. *Neurosurgery* 20: 228-235, 1987
6. Tittle TL, Loeffler CL, Steinberg TA: Fistula between a posterior communicating artery aneurysm and the cavernous sinus. *Am J Neuroradiol* 16: 1808-1810, 1995
7. Weaver KD, Ewend MG, Solander S: Successful transarterial Guglielmi detachable coil embolization of posttraumatic posterior communicating artery-cavernous sinus fistula: Technical note. *Neurosurgery* 52: 458-460, 2003