

# 3-Dimensional Neurosurgical Planning Using Multilevel CT-MRI Image Registration and Fusion

Nandish SIDDESHAPPA<sup>1,\*</sup>, Malaaika Mihir CHHAYA<sup>2</sup>, Gopalakrishna K PRABHU<sup>2</sup>, Rajagopal V KADAVIGERE<sup>3</sup>

<sup>1</sup>Manipal Academy of Higher Education, Manipal School of Information Sciences, Manipal, Karnataka, India

<sup>2</sup>Manipal Academy of Higher Education, Manipal Institute of Technology, Department of Biomedical Engineering, Manipal, Karnataka, India

<sup>3</sup>Manipal University, School of Engineering, Department of Electronics and Communication, Jaipur, India

<sup>4</sup>Manipal Academy of Higher Education, Kasturba Medical College, Department of Radiodiagnosis and Imaging, Manipal, India

**Corresponding author:** Nandish SIDDESHAPPA ✉ nandnama@gmail.com

## ABSTRACT

**AIM:** To provide a tool to plan neurosurgery which demonstrate multimodal brain images together in two and three dimensions respectively.

**MATERIAL and METHODS:** On the brain CT-MRI image sequences, a unique multilevel registration technique is used in place of the traditional image registration strategy, which has drawbacks. The multi-resolution registration technique is used for level one registration, and the B-spline Deformable Registration Technique is used for level-2 registration. The results of the multilevel registration procedure are then used to execute feature-based fusion. This is followed by 3-D volume rendering on the fused sequence of CT and registered MRI sequence.

**RESULTS:** The results of fusion are evaluated between the resultants of both level-1 and level-2 registration. The Q4 index and the correlation coefficient (CC) are two potential measures for estimating fusion results. Both level-1 and 2 registration approaches yield fusion results. For level-1 and 2 fusions, the average CC measured across all image pairs is 0.71 and 0.85, respectively, while Q4 measured 0.21 and 0.46 for level-1 and 2, respectively. At level-2 registration, both CC and Q4 exhibit an improvement in fusion. Using VTK angle and distance widgets for measuring distances and angles on the 3-D model improves path planning capabilities.

**CONCLUSION:** The proposed research creates a computer-aided platform for better neurosurgical planning. The multilevel registration method produced promising fusion results and laid the groundwork for enhanced 3-D viewing of fused CT-MRI sequences using depth peeling. Distance and angle measurements improve surgical planning capability.

**KEYWORDS:** Fusion, Registration, Multilevel, Multimodal, Multiresolution, Volume rendering

**ABBREVIATIONS:** CT: Computed tomography, MRI: Magnetic resonance imaging, VTK: Visualization tool kit

## INTRODUCTION

Illness is a state of being sick and recovery necessitates medical attention. Modern healthcare technology trends and advancements give better patient care in terms of diagnosis, treatment, and disease cure plans. It is critical to discuss the patterns that are prevalent in developed and emerging countries to provide healthcare. When comparing industrialized and emerging countries, there is a significant gap

in terms of education, economy, infrastructure, population, and resources. The latest technological developments may not reach those living in poverty. However, when compared to an urban neighbourhood with significant blunt trauma, the rural region has a lower volume of trauma (11). The most significant shift in global health policy has underlined the importance of necessary and emergency surgery as a key priority. More deaths result from a lack of access to surgical care (16); most patients in underdeveloped nations are unable

to obtain primary surgical care due to a lack of availability and high costs.

Specialty treatment, such as neurosurgery, in low- and middle-income nations usually progresses from distance to complete absenteeism. This is due to a variety of reasons: A lack of suitable hospital infrastructure, a dearth of resources and training programs, isolated rural locations, and the high expense associated with pathologies that require neurosurgery. Telemedicine, remote surgery, and education are examples of advanced technology that should be deployed in partnership with tier-1 healthcare facilities and teaching hospitals. Local neurosurgeons can be quickly trained to provide viable answers to neurosurgical problems (25). Regions in the developing nation have a median ratio of about one neurosurgeon for every 1,00,000 people (1); the US ratio is 1:63,000 (7); low-income countries' ratio is 1:3,000,000. Africa has a 1:4,000,000 ratio and northeastern India has 1:2,500,000 ratio of neurosurgeons (5). In India, there are 59 medical colleges with a neurosurgery specialty, with a total of 1,800 neurosurgeons. Every year, 1.2 billion people are served by 190 new graduates. Because the vast majority of India's 1,800 neurosurgeons live in urban locations such as Delhi, Mumbai, Bangalore, Chennai, etc. An estimated 800 million Indians reside in suburban/rural areas and have limited access to general neurosurgery (25).

In the case of neurological problems, a thorough examination of medical imaging is required. In most circumstances, studying brain pathology, biopsy, and other extractions on brain tissue is impossible. Medical imaging is used to understand morphological irregularities in the brain structure and muscles caused by disease disorders. As a result, in neurosurgical cases, a thorough examination of medical imaging is essential. Various imaging modalities exist, such as CT, MRI, and so on, and each of these modalities gives the clinician complimentary information. The difficulty in neurosurgery is determining the region of interest and the location of the incision. Exploration of multimodal images that provide complementary information is critical to addressing this difficulty. In neurosurgery, planning is crucial. Planning necessitates the mapping of a brain abnormality onto the anatomy of the brain. This aids in the planning of scalp incisions multimodal imaging, such as X-ray, CT, and MRI is recommended to map functional information on the anatomy. The fusion of multimodal medical images can aid in improved neurosurgical planning. On 3-D visualization of the data and doing depth peeling, the incision site on the skull and the locations of the lesions may be better identified. Finding better image registration techniques to perform multimodal brain image fusion and 3-D surgical planning is part of the proposed research.

## MATERIAL and METHODS

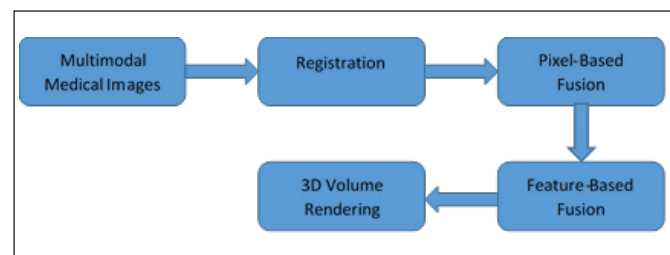
Training in neurosurgery is multidimensional. The trainee should become a skilled neurosurgeon within a short period. Many aspects will influence their practice, such as surgical and non-surgical treatments for diseases, and prevalent and relevant aspects of the brain and peripheral nerve system, respectively. Advancement in healthcare technology has

minimized human contact in surgery. In academic institutions, to build the competency level of budding surgeons, it is necessary to adopt a supplementary mode of learning. The author (6) states that practical solutions to individual training on supplements in the areas of weakness, with the aid of new technologies of pre-operative try-outs, can decrease errors in real surgeries. Simulators and computer-aided doctor education tools allow pre-operative practice as a rehearsal. The work proposed involves the design of a preoperative neurosurgical planning tool using multimodal clinical images. Neyaz Z et al. introduced a surgical planning tool for intracranial lesions, where localization of landmarks on the brain surface is significant along with identifying vascular structures (14). Neyaz Z et al. state that 3-D visualization of different anatomical structures is performed using MRI sequence simultaneously but additional integration into single fully automated software is required to make better pre-surgical planning tools.

According to the literature review, 3-D volume rendering of brain imaging plays an important role in pre-surgical planning. The traditional method of planning neurosurgery results in an enlarged craniotomy and a high error rate. A small bony area near the lateral skull base houses critical neurovascular systems. As a result, less invasive procedures are becoming important, and greater surgical training and preparation are required. Many situations exist when brain regions are encased in small and bony gaps. CT images better characterize facial bones and small bony areas at the base of the skull as compared to MRI images. MRI sequences are used to visualize several anatomical structures simultaneously, but further integration into single, completely automated software is needed to create better pre-surgical planning tools. A fusion of CT and MRI of the brain sequence can enhance the visualization of lesions, soft tissues, and bony structures during 3-D imaging and depth peeling to meet the concerns described. The proposed methodology is shown in Figure 1.

### Multimodal Medical Images

Under the guidance and approval of the Institutional Ethical Committee, Kasturba Hospital, 20 CT and MRIs have been archived and anonymized data sets have been collected and the same has been used in the proposed methodology. Both, CT and MRI scans collected are of the same patients. Among 20 scans of normal and defected patients, three datasets have CT and MRI sequences with more than 100 slices with a voxel size of 0.46x0.46x1 mm and 220 MRI images with a voxel size of 1x1x1 mm. The remaining scans have CT images (34 ~ 39 images in each case) and MRI images (23 ~ 25 images in



**Figure 1:** Proposed methodology.

each case) with varying voxel sizes between 0.45x0.45x4.95 ~ 0.49x0.49x6.31 mm. All the images collected from the archive mentioned above are converted into Analyze format (with the extension `hdr` and `img`) for processing. CT sequences without contrast axial sections and MRI T2 Flair sequences are used in the proposed methodology.

### Registration

In the proposed methodology, medical image registration is performed at multilevel. Multilevel-based medical image registration and the analysis of results have been performed and published earlier (20). Multiresolution registration technique is performed at level-1 and BSpline Deformable registration is performed at level-2. Performing image registration for CT and MRI sequences at the first level using a multi-resolution approach is widely used to improve the speed, accuracy, and robustness of the registration technique. Multiresolution image registration of CT-MRI brain images has been performed earlier and published (13). In the proposed article, the fusion of registration results at both levels is performed using feature-based and pixel-based techniques. Results of both levels, one and two, are validated by radiologists, and quantitative analysis of the results is performed using Mutual Information (MI) metric (20).

### Fusion and Segmentation

After successful CT-MRI registration, the multilevel image registration technique is evidenced to be a novel method to register brain CT and MRI sequence with enhanced mutual information metric (20). The fusion of CT and registered MRI image sequence is performed on the results of both registration techniques. Image fusion is used in medicine in many applications such as radiodiagnosis, oncology, neurology, neuro-surgery, cardiology, etc. (3,8–10,12,17,18). Even though many researchers published articles on medical image registration and fusion for many decades, there exist open-ended technological and scientific challenges. In the case of multimodal medical image fusion, there are many types of registration and fusion rules, which produce different outputs on a different input dataset. To develop and tender explicit applications, methods, and components for the respective dataset, it is thought-provoking to explore more potential to deliver an improved outcome.

Two fusion methods are used in the proposed research; one is pixel-based fusion, and another is feature-based fusion. Pixel-based fusion is performed on corresponding pixels from both images by taking mean values and feature-based fusion is performed if lesions are present in the brain MRI sequence. Feature-based fusion is performed to address the limitations of the multilevel registration technique since the multilevel registration of MRI images is smoothened, resulting in reduced contrast of the lesion. Hence, the lesion is segmented from the registered MRI and fused with the resultant pixel-based fusion method. Feature-based in proposed research considers lesions as a region of interest. The lesion is extracted from registered MRI brain images and then fused with the CT-MRI fused sequence. Pixel-based fusion represents each pixel in the fused sequence acquiring a combination of input image

pixels. Pixel-based fusion is the basic fusion technique performed. Two input sources are fused globally based on the corresponding pixels. Following are the steps to follow during fusion,

- Read input source images 1 and 2 in Analyze 7.5 format.
- Images 1 and 2 are CT and registered MRI sequences respectively.
- Check dimensions of input source images 1 and 2.
- If the dimensions of both the images are the same, then continue fusion, else abort fusion.
- Fusion of images 1 and 2.
  - Output pixel = Output pixel type (Input image 1 pixel + input image 2 pixel)
- Repeat for every slice in the sequence.

There are numerous methods for performing image fusion; however, because the input data sources are CT and registered MRI sequences, the suggested technique is conducted at a spatial level by adding the relevant pixel. The multiresolution registration technique includes smoothing and subsampling. Extracting lesions from registered MRI images and fusing extracted features with CT and registered MRI sequences is advised for enhanced visibility of lesions along with bone and soft tissues. To extract lesions from registered MRI images, the Otsu threshold-based segmentation algorithm is used. The Otsu approach is combined with multiple threshold techniques to automatically determine a threshold. Global thresholding and local thresholding are two types of automatic thresholding systems. Global thresholding chooses a single threshold value from the entire image's histogram. Local thresholding chooses multiple threshold values based on localized grey-level information, each of which is optimized for a small portion of the image (15). Thresholds calculated by the two methods are equivalent under certain conditions. For an image with a significant difference between within-class variances of the object and background, the property of the Otsu threshold provides a theoretical basis to limit the search range of the optimal threshold (26). Otsu multiple threshold technique calculates five threshold values and generates five results respectively for each value. Otsu multiple threshold technique resulted with threshold values for four bins, threshold value 1 = 17.9, threshold value 2 = 51.8, threshold value 3 = 79.6, threshold value 4 = 113.5, and threshold value 5 = 165.3 respectively.

### 3-D Volume Rendering

VTK 3-D visualization takes the fused CT-MRI sequence as input. To establish image data dimensions, the datasets' origin and spacing must be provided. The height, breadth, and length of the voxels are all evenly spaced. Filters create an internal data object that meets its output requirements and returns it when the `GetOutput()` method is called. Type checking may be imposed at compile time depending on which language is used to generate a VTK application (for example, when using C++). The visualization pipeline's execution should be closely monitored after it has been built. Filters should re-execute

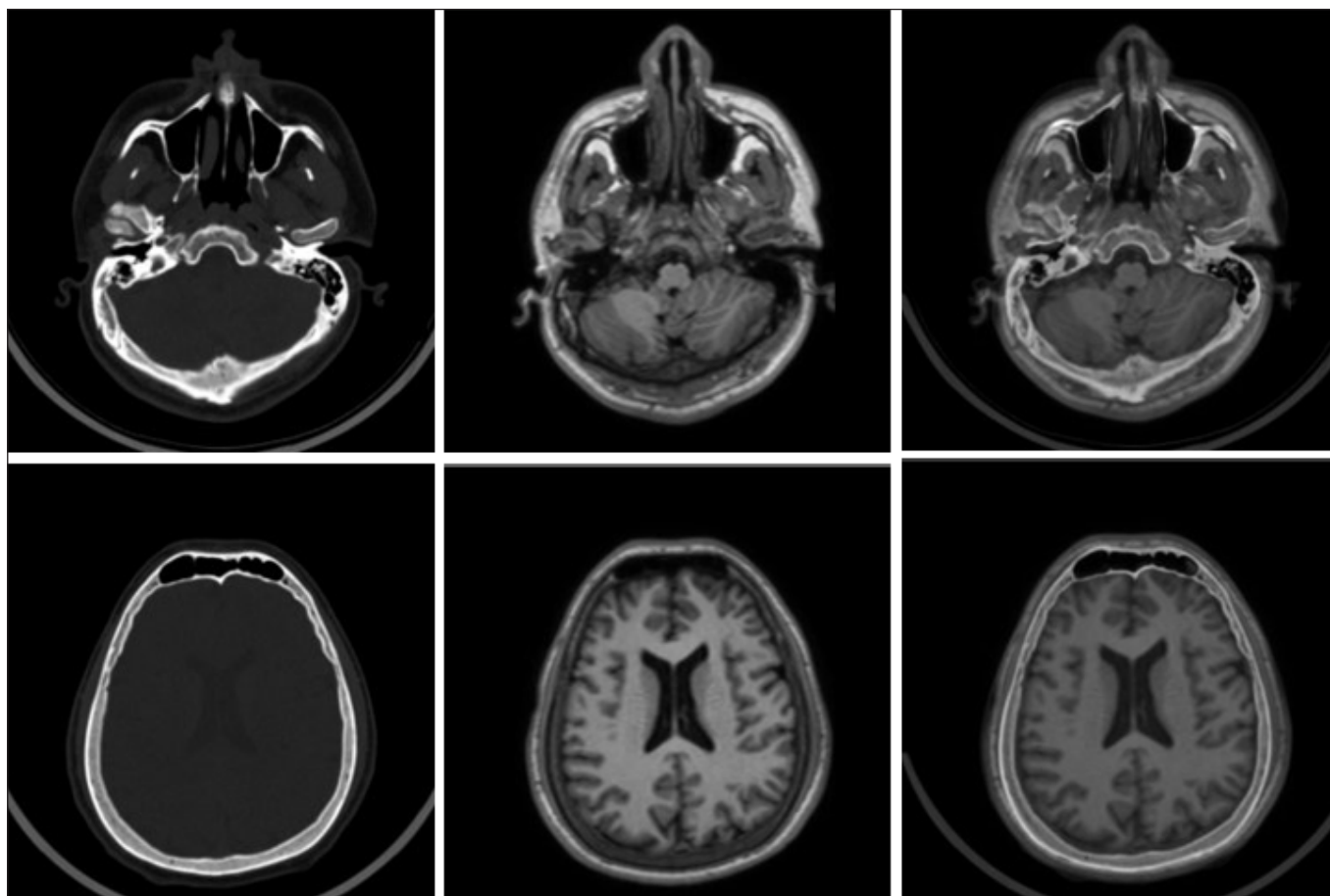
when the input to the filter changes, or when the internal state changes (19).

Mappers end the visualization pipeline by writing data to the file or by generating graphical primitives by interfacing with other devices or software. In the proposed methodology, a fixed point volume ray cast mapper is used; it maps a volume to an image using 15-bit fixed-point precision for the calculation, of volumes up to 4-component scalars. Volume ray cast mapper performs volume rendering; it supports three subclasses, to render iso-surface, generate maximum intensity projections, and render volume with alpha compositing technique (2). The image viewer is convenient to display the images; the VTK actor is used to view an image in a 3-D render window. On most platforms, this enables users to rotate, pan, and zoom with bilinear interpolation. VTK image actor object is a composite class that encapsulates both an actor and mapper into one class. VTK render window provides a connection between the operating system and the rendering engine of VTK (2). VTK distance measurement and angle measurement widgets are used to perform the path planning for the surgery on the 3-D volume.

## ■ RESULTS

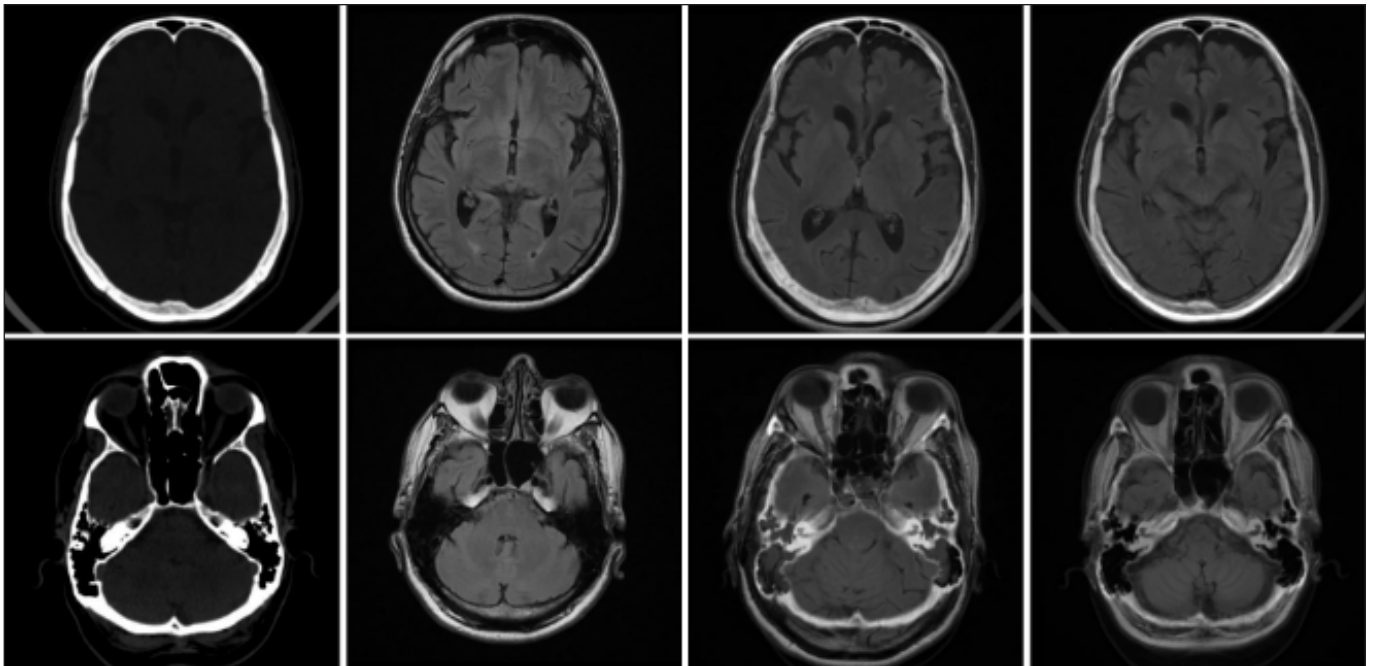
The resulting fused image sequence is a combination of a registered MRI image sequence and a brain CT bone window. The input images and the result of pixel-based fusion are shown in Figure 2. Figure 3 depicts pixel-based fusion using level-1 and 2 registration algorithms, during multilevel image registration. The output provided by the Otsu multiple thresholds approaches with threshold value 4 during feature-based fusion delivers promising results by segmenting lesions as illustrated in Figure 4. It also shows the outcome of the proposed fusion technique exhibiting the lesion, soft tissues, and bony structures, and the same is produced as input to perform 3-D volume rendering, depth peeling, distance, and angle measurement.

VTK 3-D visualization uses the fused CT-MRI sequence as input, which aids in better planning of surgery and treatment plans tailored to the patient's lesion localization and incision site on the skull and/or cranium. To establish image data dimensions, the datasets' origin and spacing must be provided. The height, breadth, and length of the voxels are all evenly spaced. The image viewer is used to view images in a 3-D render window; the VTK actor is used to view images in a 2-D render window. Users can rotate, pan, and zoom with

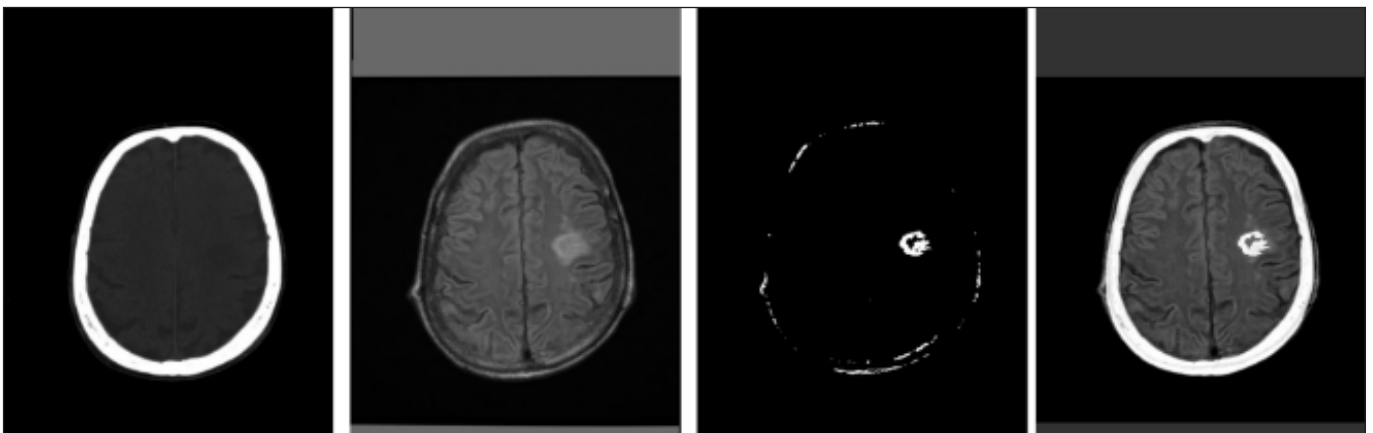


**Figure 2:** The first row shows the CT slice (left), registered MRI slice (Middle), and fused CT with registered MRI (Right) for slice number 61. And the second row shows the same for slice number 129. The total number of slices, in this case, is 206.





**Figure 3:** Fusion of CT and Registered MRI sequence. Column 1 shows CT slice numbers 8 and 13, column 2 shows corresponding MRI slices, column 3 shows the fusion of CT slice 8 with level-1 registered MRI slice and column 4 shows the fusion of CT slice 13 with level-2 registered MRI slice. Fusion at level-2 registered images shows the best match and overlay compared to fusion at the level-1 result.

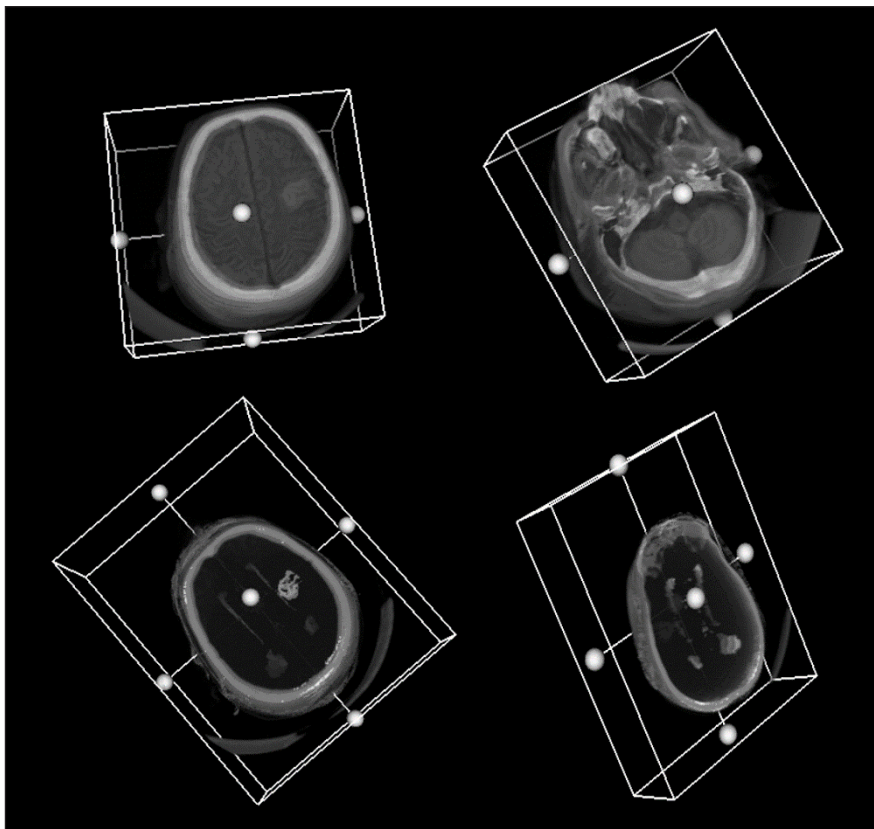


**Figure 4:** Resultant of feature-based fusion shown at rightmost image demonstrating CT bone window, soft tissue from registered MRI and lesion extracted from Otsu multiple thresholding technique. From left is the CT, registered MRI, and resultant of Otsu multiple thresholding technique respectively.

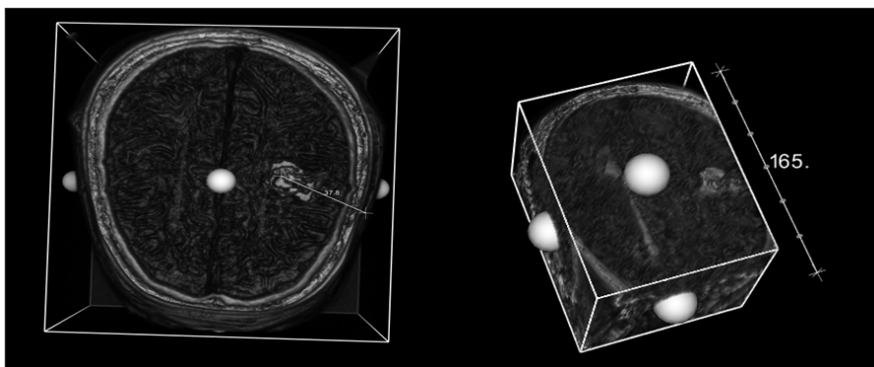
bilinear interpolation on most platforms. The VTK image actor object is a composite class that contains both an actor and a mapper (2). Figure 5 shows the volume rendering of the CT-registered MRI fused sequence. Fused CT-MRI volume is then used for surgical planning by providing widgets like distance measurement and angle measurements using VTK. Hence, neurosurgeons can perform distance and angle measurements which leads to planning the surgical path to reach the lesions through the cranium or facial bones. Figures 6 and 7 show the usage of the distance and angle measurement widget on the 3-D volume.

## DISCUSSION

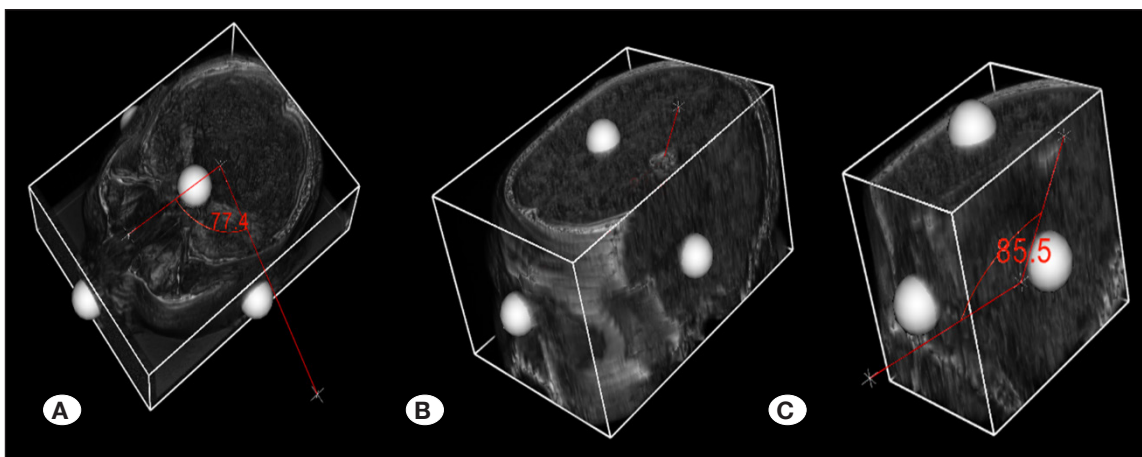
Image registration of multimodal brain imaging can also be verified and validated by combining images from multimodal medical images. Mismatches in the overlapping images can be determined in the case of misregistration and the quality of image fusion can be estimated using commonly used fusion quality assessment methods. The correlation among the pixels in the input images will be used to test multimodal medical image fusion. As a result, image fusion assessment is done on the CT and registered MRI fusion results at both levels of registration techniques, as shown in Table I.



**Figure 5:** Volume rendering and depth peeling of fused CT and registered MRI showing lesion (top) and fused CT and lesion extracted registered MRI.



**Figure 6:** Measuring distance on fused CT-MRI 3-D volume.



**Figure 7:** Performing angle measurement on the fused CT-MRI 3-D Volume. Selecting the appropriate points near the nasal cavity (A) and on the lesion (B) and measuring the angle for the path planning (C).

There are a few frequently used methods to analyze the fusion of two images, they are, Relative Dimensionless Global Error (ERGAS), Quality index (Q4), Correlation Coefficients (CC), Mean Square Error (MSE), Root Mean Square Error (RMSE), and Hausdorff distance (Hd), etc. (27,28). In this methodology CC, Q4, MSE, and RMSE are used to assess the fusion quality. ERGAS, Q4 calculates the mean square between input image pairs. Since it is a multimodal image, the mean square between input images is not favourable in the methodology used. Hd is sensitive to changes in intensities, in this methodology multimodal images are used and Hd is not favoured for assessing the registration results.

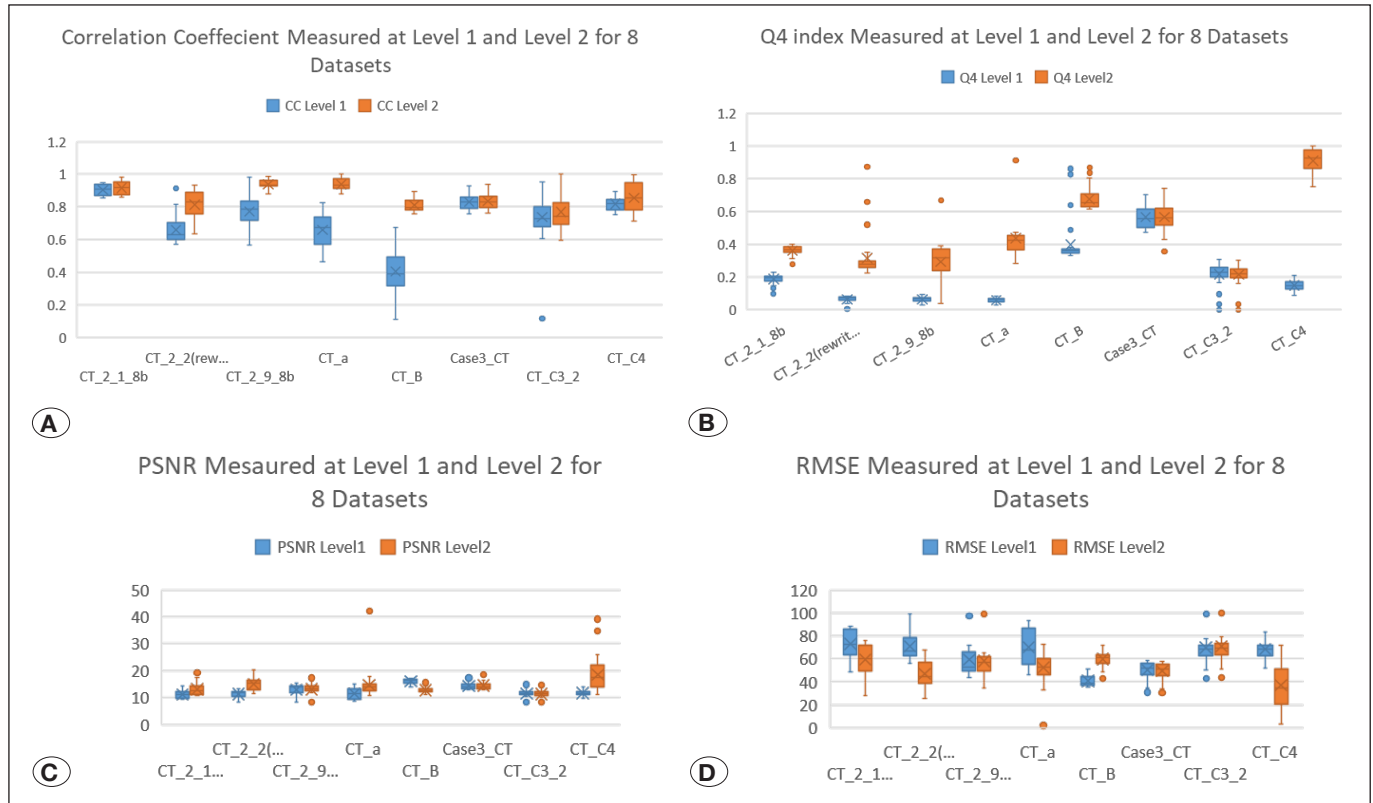
Average metrics measured to assess the fusion of CT and MRI datasets at both levels of registration techniques are shown in Table 1. Metrics measured at level-2 show the enhancement in the quality of the slices. Figure 8 shows the box plot drawn for the metrics measured such as CC, Q4, PSNR, and RMSE for

eight datasets, which illustrates enhancement in results of the level-2 registration technique. Since in the proposed research, multimodal images are used, it is observed from Table I that CC and Q4 provide a better assessment of fusion compared to PSNR, MSE, and RMSE based on standard deviation and variance measured across all the CT-MRI image pairs.

Fusion on CT and MRI (T2 Flair) image pair is performed using Daubechies complex wavelet transform (DCWT) (21,22), Singh R et al. achieves higher values of fusion factor (FF) and low value of fusion symmetry (FS) compared to other methods based on wavelet and spatial techniques. A higher FF and lower FS indicate fusion results are more promising. Table II shows the results compared with the DCWT method and other methods (4,23,24). Our proposed multilevel registration-based fusion outperforms all previous strategies based on PCA and transform-based methods, as shown in Table 2. The correlation coefficient and Q4 index were found to be useful

**Table I:** Fusion Assessment Metrics. Average Values Calculated Across all the Slices

	CC	Q4	PSNR	MSE	RMSE
Average	<b>0.8581</b>	<b>0.4610</b>	13.9	1771.7	55.03
Standard Deviation	<b>0.09099</b>	<b>0.1124</b>	3.79	954.5	15.98
Variance	<b>0.00828</b>	<b>0.0507</b>	14.3	911191	255.6



**Figure 8:** Box plot of various metrics measured to assess the results of fusion. Blue represents the results of level-1 and brown represents level-2. Boxplot is drawn for CC (A), Q4 index (B), PSNR (C), and RMSE (D). Each metric shows the enhancement in the fusion result performed on level-2 registration.

**Table II:** Results Compared with Fusion Based on DCWT

Method	FF	FS
DCWT	1.8	0.35
Pixel-Average	5.05	0.015
Fuzzy Inference System (FIS)	6.49	0.08
Neuro-Fuzzy Inference System (NFIS)	5.3	0.03
Wavelet Transform + Principal Component Analysis	3.6	0.01
Complex Wavelet Transform + Principal Component Analysis	3.1	0.03
Wavelet Transform +Activity	3.2	0.16
DWT	2.08	0.02
DCT Variance	3.2	0.13
SWT	2.3	0.082
<b>Proposed Multilevel Registration Based Fusion</b>	2.03	0.081

metrics for assessing the quality of multimodal medical image fusion in the proposed article.

Volume rendering is accomplished using an optical technique known as volume ray casting. The surface was rendered from volume data using the ray cast mapper. Because it handles all the multi-component data and uses fixed pointed computations and space hopping for high speed, the fixed point volume ray cast mapper is utilized instead of the volume ray cast. The data contains several components, such as colour, opacity, and shading style. The fixed point volume ray cast mapper can handle all scalar types from unsigned char to double, and it can handle up to four independent components, each with its transfer function and shading parameters.

The proposed study facilitates the identification of the cranial incision site and the locations of the lesions, which is useful in most essential skull-based neurosurgeries. The integration of CT and MRI image sequences, as well as 3-D volume representation of fused series with depth peeling, distance measurement, and angle measurement, provides a more robust platform for neurosurgery planning. The findings of this study will also help with computer-assisted surgical training for aspiring neurosurgeons, better neurosurgery pre-planning, and better treatment planning for neurological diseases.

## ■ CONCLUSION

In multimodal and mono-modal medical image fusion for analysis, prediction, and 3-D visualization to aid clinicians in better diagnosis and planning, image registration is critical. Multimodal medical images provide additional information. This study examines image registration algorithms for performing medical image fusion and 3-D visualization. The image registration approach is used on multimodal medical images such as brain CT and MRI. The most difficult aspect of registration is getting the best match between the CT and MRI slices. The archived dataset had a sequence of CT and

MRI slices with varied numbers of slices in each. Various registration techniques have been used on archival datasets in the past, but they have failed to produce the best mapping between the respective slices, resulting in noisy image sequences due to misregistration. The suggested research yields a novel multilevel registration technique for the fusion of multimodal brain images.

The fusion of registered images with the target image is a methodology for evaluating the registration process's quality. CC and Q4 index appear to be adequate metrics to measure the quality of fusion when done on multimodal brain images such as CT and MRI, as determined by computing standard deviation and variance across all five metrics generated for CT and fused data. PSNR, MSE, and RMSE indicate a lot of variation among all image pairings collected, and values are scattered over slices from different datasets. The average CC recorded is 0.85, while the Q4 recorded is 0.46. As a result, both CC and Q4 show an improvement in the quality of the registration consequent. The suggested method also outperforms the other techniques listed in Table II, with the multilevel registration methodology emerging as a novel method for combining multimodal brain images.

A novel multilevel image registration technique allows for the fusion and 3-D visualization of multimodal medical images. The 3-D visualization tool allows for simultaneous planning of three sequences: CT, registered MRI and fused CT-registered MRI. Furthermore, 3-D visualization of fused series reveals the properties of both CT and MRI series in the same 3-D space. This, coupled with distance and angle measurement widgets allows doctors to better plan due to improved localizing lesions and anatomical locations. Future work will focus on better path planning and measurements, which will aid surgeons in preparing for surgery and developing a graphical user interface to do fusion, 3-D rendering, path planning, and measurements.



## AUTHORSHIP CONTRIBUTION

**Study conception and design:** NS, GKP, RVK

**Data collection:** NS, RVK

**Analysis and interpretation of results:** NS, MMC, RVK

**Draft manuscript preparation:** NS, MMC

**Critical revision of the article:** GKP, RVK

**Other (study supervision, fundings, materials, etc...):** GKP, RVK

All authors (NS, MMC, GKP, RVK) reviewed the results and approved the final version of the manuscript.

## REFERENCES

- Attebery JE, Mayegga E, Louis RG, Chard R, Kinasha A, Elle-gala DB: Initial audit of a basic and emergency neurosurgical training program in rural Tanzania. *World Neurosurg* 73:290-295, 2010
- Avila LS, Ayachit U, Barré S, Baumes J, Bertel F, Blue R, Cole D, DeMarle D, Geveci B, Hoffman WA, King B, Krishnan K, Law CC, Martin KM, McLendon W, Pebay P, Russell N, Schroeder WJ, Shead T, Shepherd J, Wilson A, Wylie B: The VTK User's Guide [Internet, 2001 Available from: [www.vtk.org](http://www.vtk.org)
- Delbeke D, Schöder H, Martin WH, Wahl RL: Hybrid Imaging (SPECT/CT and PET/CT): Improving therapeutic decisions. *Semin Nucl Med* 39:308-340, 2009
- Galande A, Patil R: The Art of Medical Image Fusion: A Survey. 2013 International Conference on Advances in Computing, Communications and Informatics (ICACCI), 2013. Available from: [https://www.researchgate.net/profile/Ashwini-Galande/publication/261235754\\_The\\_art\\_of\\_medical\\_image\\_fusion\\_A\\_survey/links/5afaa0bba6fdccacab16cef3/The-art-of-medical-image-fusion-A-survey.pdf](https://www.researchgate.net/profile/Ashwini-Galande/publication/261235754_The_art_of_medical_image_fusion_A_survey/links/5afaa0bba6fdccacab16cef3/The-art-of-medical-image-fusion-A-survey.pdf)
- Ganapathy K: Neurosurgery in India: An overview. *World Neurosurg* 79:621-628, 2013
- Gasco J: Present and future of neurosurgery training and education. *Malaysian J Med Sci* 21:1-3, 2014
- Griswold D, Benet A, Tabani H, Lawton MT, Meybodi AT: "To Operate" versus "Not to Operate" in low-resource settings: example of aneurysm surgery in rural Iran and impact of mastery of neurosurgical anatomy. *World Neurosurg* 100:628-631, 2017
- Hernández AI, Carrault G, Mora F, Thoraval L, Passariello G, Schleich JM: Multisensor fusion for atrial and ventricular activity detection in coronary care monitoring. *IEEE Trans Biomed Eng* 46:1186-1190, 1999
- Kannathal N, Acharya UR, Ng EYK, Min LC, Suri JS, Spaan JAE: Data fusion of multimodal cardiovascular signals. In: Acharya UR, Suri JS, Spaan JAE, Krishnan SM (eds), *Advances in Cardiac Signal Processing*. Springer, Berlin: Heidelberg, 2007:167-168
- Lindseth F, Ommedal S, Bang J, Unsgård G, Nagelhus Hernes TA: Image fusion of ultrasound and MRI as an aid for assessing anatomical shifts and improving overview and interpretation in ultrasound-guided neurosurgery. *Int Congr Ser* 1230:254-260, 2001
- Lipsky AM, Karsteadt LL, Gausche-Hill M, Hartmans S, Bongard FS, Cryer HG, Ekhardt PB, Loffredo AJ, Farmer PD, Whitney SC, Lewis RJ: A comparison of rural versus urban trauma care. *J Emerg Trauma Shock* 7(1):41-46, 2014
- Nakamoto Y, Tamai K, Saga T, Higashi T, Hara T, Suga T, Koyama T, Togashi K: Clinical value of image fusion from MR and PET in patients with head and neck cancer. *Mol Imaging Biol* 11:46-53, 2009
- Nandish S, Prabhu G, Rajagopal KV: Multiresolution image registration for multimodal brain images and fusion for better neurosurgical planning. *Biomed J* 40:329-338, 2017
- Neyaz Z, Phadke RV, Singh V, Godbole C: Three-dimensional visualization of intracranial tumors with cortical surface and vasculature from routine MR sequences. *Neurol India* 65:333-340, 2017
- Ng HF: Automatic thresholding for defect detection. *Pattern Recognit Lett* 27:1644-1649, 2006
- Park KB, Johnson WD, Dempsey RJ: Global neurosurgery: The unmet need. *World Neurosurg* 88:32-35, 2016
- Pattichis CS, Pattichis MS, Micheli-Tzanakou E: Medical imaging fusion applications: An overview. *Conf Rec Asilomar Conf Signals Syst Comput* 2:1263-1267, 2001
- Rojas GM, Raff U, Quintana JC, Huete I, Hutchinson M: Image fusion in neuroradiology: Three clinical examples including MRI of Parkinson disease. *Comput Med Imaging Graph* 31: 17-27, 2007
- Schroeder WJ, Avila LS, Hoffman W: Visualizing with VTK: A tutorial. *IEEE Comput Graph Appl* 20:20-27, 2000
- Siddeshappa N, Gopalakrishna PK, Kadavigere RV: Multimodal medical image registration: A multilevel approach and validation using mutual information analysis. *Int J Adv Sci Technol* 29:4944-4953, 2020
- Singh R, Khare A: Fusion of multimodal medical images using Daubechies complex wavelet transform - A multiresolution approach. *Inf Fusion* 19:49-60, 2014
- Singh R, Srivastava R, Prakash O, Khare A: Mixed scheme based multimodal medical image fusion using Daubechies complex wavelet transform; in 2012 International Conference on Informatics, Electronics and Vision, ICIEV 2012, 2012
- So RWK, Chung ACS: Multi-level non-rigid image registration using graph-cuts; in ICASSP, IEEE International Conference on Acoustics, Speech and Signal Processing - Proceedings, 2009
- Srinivasa Rao D, Ramesh Babu C, Nagendra Kumar YJ, Rajasekhar N, Ravi T: Medical image fusion using transform based fusion techniques. *Int J Recent Technol Eng* 8:309-317, 2019
- Upadhyayula PS, Yue JK, Yang J, Birk HS, Ciacci JD: The current state of rural neurosurgical practice: An international perspective. *J Neurosci Rural Pract* 9:123-131, 2018
- Xu X, Xu S, Jin L, Song E: Characteristic analysis of Otsu threshold and its applications. *Pattern Recognit Lett* 32:956-961, 2011
- Zhang Q, Cao Z, Hu Z, Jia Y, Wu X: Joint image registration and fusion for panchromatic and multispectral images. *IEEE Geosci Remote Sens Lett* 12:467-471, 2015
- Zhang Y: Methods for image fusion quality assessment-a review, comparison and analysis. *Int Arch Photogramm Remote Sens Spat Inf Sci* 37:1101-1109, 2008