

Variations in the Foramen Transversarium of Cervical Spine and Their Surgical Importance: An Osteological Study in Dried Cervical Vertebrae of North Indian Origin

Apurba PATRA¹, Priti CHAUDHARY¹, Harsimarjit KAUR²

¹All India Institute of Medical Sciences, Department of Anatomy, Bathinda, India

²Government Medical College, Department of Anatomy, Patiala, India

Corresponding author: Apurba PATRA ✉ apurba.cnmc03@gmail.com

ABSTRACT

AIM: To examine the variations in number, size, and shape of foramina transversaria (FTs) of cervical vertebrae, and to discuss their clinical importance.

MATERIAL and METHODS: The FTs of 200 dry cervical vertebrae (C3–C7) from 40 spines were studied for the presence of variations in their number (single, double, or triple), size, and shape. The foramina were classified according to their shape depending upon the direction of their main diameter.

RESULTS: Accessory foramina were found in 40 cervical vertebrae. Bilateral accessory foramina were slightly more common than a unilateral accessory foramen. Accessory foramina occurred in a particular pattern, with incidence increasing with descending order of cervical vertebrae, and were most commonly found in C7. The mean values of the anteroposterior and transverse FT diameters on the right side were 4.96 ± 1.08 and 5.68 ± 1.20 mm, respectively, and on the left side were 5.07 ± 1.12 and 5.76 ± 1.29 mm, respectively. The difference was not statistically significant. FTs with very small diameter (<3.5 mm) were found mostly in C7 followed by C5 and C6. Five types of shape were noted. Type 1 was predominant on the right side, whereas type 4 was predominant on the left side.

CONCLUSION: Differences in number (duplication), size, and shape of the FTs are not uncommon phenomena. Anatomical knowledge of FT variations is surgically pertinent, as in such conditions the vertebral artery may become twisted or deformed and result in vertebrobasilar insufficiency. Morphometric measurements from this study may be useful in interpreting radiographic images of the cervical spine obtained using computed tomography or cervical angiograms.

KEYWORDS: Anatomical variation, Cervical vertebra, Foramen transversarium, Transverse process, Vertebral artery

ABBREVIATIONS: FT: Foramen transversarium, AFT: Accessory foramen transversarium, APD: Anteroposterior diameter, TD: Transverse diameter, CT: Computed tomography

INTRODUCTION

A cervical vertebra can be distinguished from other vertebrae by the presence of a foramen transversarium (FT) in the transverse processes (20). Foramina transversaria (FTs) are formed as the result of fusion of the true transverse process with the costal element of the vertebra.

The main function of the FT is to allow passage of the vertebral vessels (artery and veins) accompanied by cervical sympathetic nerves from the inferior cervical ganglion (5). Variations in the number (absence, double, and triple), size, and shape of the FT may affect these vital structures, with serious consequences such as vertebrobasilar insufficiency and ischemia should the route of the vertebral artery become

obstructed (13). Neurosurgeons require precise knowledge about the surgical anatomy of the FT and the structures passing through it. Preserving the integrity of these components, especially the vertebral artery, is the prime concern during a surgical approach to the cervical spine (18), as even minor injury to the artery may lead to severe blood loss or even loss of life. Knowledge regarding any variations in shape, size, and number of FTs within a specific surgical patient is of immense help for the operating surgeons to determine a more patient-specific approach to remove osteophytes or spurs compressing the vertebral arteries and in other cervical interventions (4). Previous studies have made observations of the presence or absence of accessory FT (AFT) and variability in the shape and size of FTs in the spinal column (9,23,26). However, the exact basis of such differences in the number, shape, and size of the FT is still unknown. It has been proposed that embryological fusion of the transverse process with the costal process of the cervical vertebrae and other structural and functional circumstances take part in the formation of FTs. AFTs are more frequently found in the lower cervical vertebrae (C5–C7) than in the upper vertebrae (C1–C2) and are smaller in size than the primary foramen. There have been a sizable number of investigations studying FT shrinking or distortion or determining the presence of osteophytes and their impingement on the structures traversing the FT, but there have been limited studies on the shape and diameter of the FT (22,26). Thus, in the present study, we focus on the variations in shape and dimensions of the FT to provide data for accurate interpretation of cervical radiographs and computed tomography (CT) angiograms of the vertebrobasilar system.

MATERIAL and METHODS

The present study was conducted on 200 dried cervical vertebrae (40 spines) collected from the bone-keeping room. The vertebrae were procured from South-Central Asian cadavers, mostly males, aged approximately between 45 and 65 years. Of the 200 cervical vertebrae, 160 were typical cervical vertebrae C3, C4, C5, and C6, and 40 were atypical cervical vertebra C7. Vertebrae were macroscopically inspected for the presence or absence of FT, incomplete FT, accessory foramina (AFT), and osteophytes. The side of each FT feature was also recorded. The shapes of the FTs were noted and classified into five categories following the criteria previously described by Taitz et al. (26), where foramen type is dependent upon the shape and direction of the main diameter as indicated below. (FTs were inspected as seen from above in an anteroposterior direction, with the body of the vertebra facing the examiner; where an AFT was present, the shape of the primary FT was considered.)

The five categories were type 1, round; type 2, elliptical with main diameter disposed anteroposteriorly (length); type 3, elliptical with main diameter disposed transversely (breadth); type 4, elliptical with main diameter disposed obliquely, from right to left; and type 5, elliptical with main diameter disposed obliquely, from left to right (26).

The widest anteroposterior and transverse diameters (APD and TD, respectively) of each FT were measured on their inner aspect using a digital vernier caliper, accurate to 0.01 mm, placed within each FT. In cases where the vertebra contained an AFT, the APD and TD of the main FT was measured and recorded. The size of the FT was not measured in cases where the FT was too small to properly place the caliper.

Statistical analysis: The data are presented as mean \pm standard deviation (SD). Subsequent statistical analysis was performed using paired, two-tailed Student's *t* test (Microsoft Office Excel software version 16.0 for Windows 10).

RESULTS

Accessory foramina (AFT): Out of 200 cervical vertebrae, 40 (20%) contained an AFT. Among them, a unilateral AFT was found in 12 typical cervical vertebrae (Figure 1) and in 6 C7 atypical vertebrae (Figure 2). Bilateral AFTs were found in 14 typical cervical vertebrae (Figure 3) and in 8 C7 atypical vertebrae (Figure 4). Thus, bilateral AFTs were slightly more frequent than a unilateral AFT. The AFTs were smaller in size than, and located posterior to, the primary foramen in all cases except one. Further, the incidence of accessory foramina increases with descending order of the cervical vertebrae, with AFTs most commonly found in C7. Each vertebra had at least one FT on either side (Table I).

Osteophytic encroachments: We found that 23 vertebrae (11.5%) showed osteophytes originating from either the uncinata process or articular processes; in 12 vertebrae (6%), the osteophytes were causing impingement into the main FT (Figure 5).

Shapes of the FTs: We classified the shape of FTs into five types according to the criteria defined by Taitz et al. (26). We observed type 1 to be the most commonly occurring type (23.85%) and type 5 to be the least commonly occurring type (14.46%). When taking the side of the vertebrae into




Figure 1: Arrow showing unilateral accessory foramen transversarium on right side of C5 vertebra (superior view).

consideration, type 1 was predominant (27.13%) on the right, whereas type 4 was predominant (27.63%) on the left. No significant differences between the sides of the vertebrae were found at any level (Table II).

Size of the main FT: On the right side, the mean APD and TD were 4.96 ± 1.08 and 5.68 ± 1.20 mm, respectively; on the left side, they were 5.07 ± 1.12 and 5.76 ± 1.29 mm, respectively.

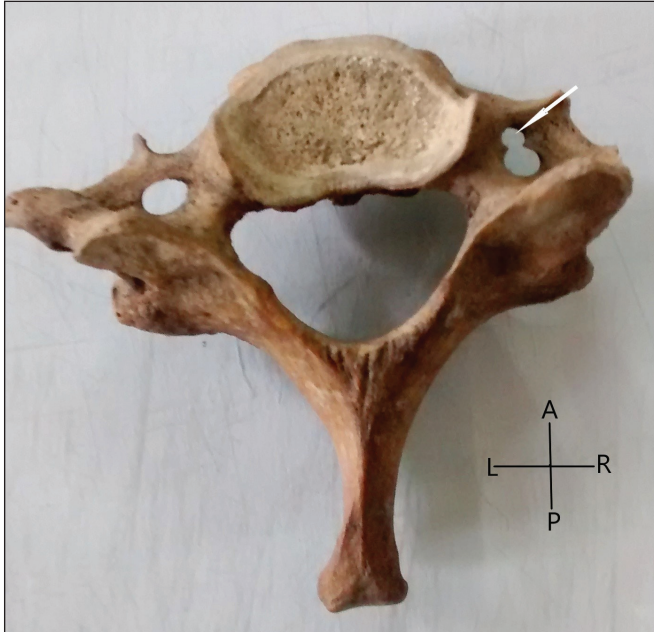

Figure 2: Arrow showing unilateral accessory foramen transversarium on right side of C7 vertebra. AFT is smaller than the main FT and located anterior to the main FT (superior view).

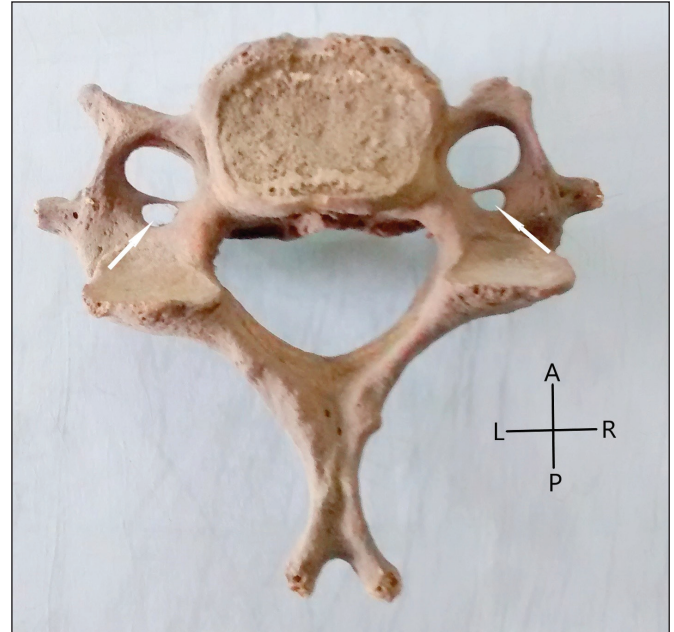


Figure 3: Arrows showing Accessory foramen transversarium on both sides of C5 vertebra (superior view).

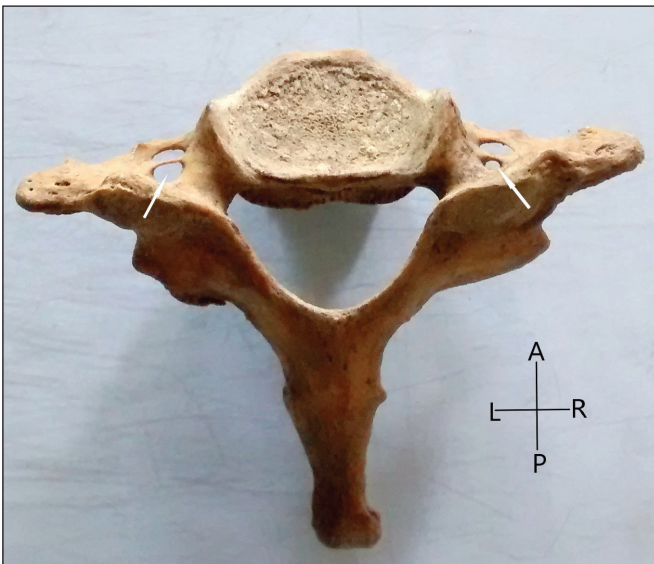


Figure 4: Arrows showing bilateral occurrence of accessory foramen transversarium in (AFT) C7 vertebra. On the right side AFT is smaller than the main FT, whereas on the left side both the aft and main FT are of equal size (superior view).

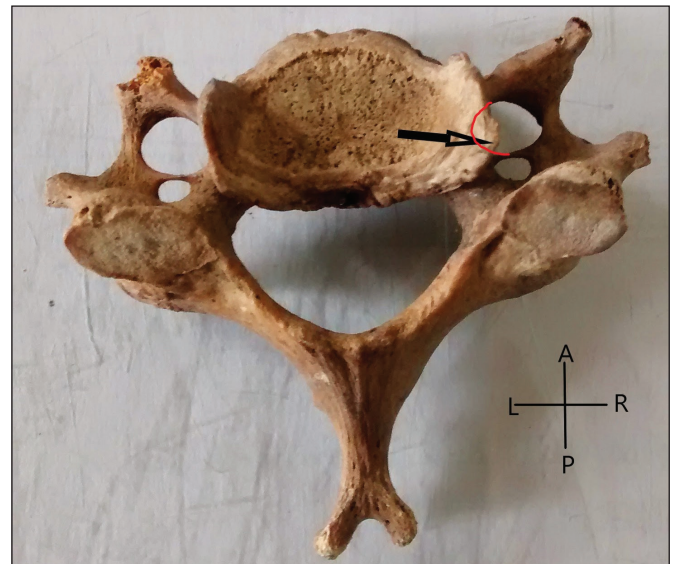


Figure 5: Arrow showing osteophytes arising from uncinate process of C5 vertebra. On the right side of the vertebra, the osteophyte was encroaching into the main FT. Red coloured curved line with medial convexity showing the actual medial boundary of the main FT (superior view).

diameter FTs in C3, C4, and C5 cervical vertebrae were <1 SD below the mean. In a few cases (C6 and C7 cervical vertebrae), the FT diameter was >1 SD below the mean. FTs with a diameter 2 SDs narrower than the mean were only

reported in the C7 vertebrae. FTs with a very small diameter (<3.5 mm) were found mostly in C7 followed by C5 and C6 (Table III).

Table I: The Incidence of Accessory Foramen Transversarium (FT) in Cervical Vertebrae

Type of vertebrae	No. of vertebra examined	Unilateral accessory FT	Bilateral accessory FT	Total	Incidence (%)
C3	40	2	1	3	7.5
C4	40	3	2	5	12.5
C5	40	3	4	7	17.5
C6	40	4	7	11	27.5
C7	40	6	8	14	35
Total	200	18	22	40	20

Table II: The Different Categories of Shape of Foramen Transversarium and Their Incidence

Shape and direction of axes	Type of vertebrae												Total	Incidence (%)
	C3		C4		C5		C6		C7		C3-C7			
	R	L	R	L	R	L	R	L	R	L	R	L		
Type 1	7	7	12	7	10	5	13	9	12	10	54	38	92	23.35
Type 2	5	8	7	6	7	8	7	8	9	9	35	39	74	18.78
Type 3	11	7	9	8	8	7	6	7	7	7	41	36	77	19.54
Type 4	12	12	8	11	7	11	7	11	5	10	39	55	94	23.85
Type 5	5	6	4	8	8	9	7	5	7	4	31	32	63	15.75
Total FT examined	40	40	40	40	40	40	40	40	40	40	200	200	400	100

Table III: The Mean Diameters of Foramen Transversaria (FTs) on Either Side of the Cervical Vertebrae

Type of Vertebrae examined	No of Foramina examined	Right				Left			
		Diameter (mm)	Mean	Range	SD	Diameter	Mean	Range	SD
C3	80	APD	5.14	4.02-6.31	0.63	AP	5.23	4.10-6.32	0.53
		TD	5.88	4.10-6.98	0.73	TD	5.93	4.11-6.87	0.54
C4	80	APD	5.10	3.46-7.02	.83	AP	5.17	4.12-6.76	0.60
		TD	5.86	4.12-7.60	0.88	TD	5.92	4.20-7.06	0.80
C5	77*	APD	5.11	0-6.6.8	0.88	AP	5.23	3.50-6.80	0.90
		TD	6.02	0-7.02	0.90	TD	6.12	3.70-7.20	1.10
C6	79*	APD	4.97	3.78-6.8	1.12	AP	5.10	0-6.86	1.70
		TD	5.55	4.10-7.6	1.23	TD	5.60	0-7.32	1.93
C7	76*	APD	4.5	0-6.88	1.91	AP	4.63	0-7.02	1.90
		TD	5.10	0-7.89	2.30	TD	5.24	0-7.92	2.10

APD: Antero-posterior diameter, **TD:** Transverse diameter. *The discrepancy in foraminal numbers was due to the presence of foramina too small to be measured. In cases with double FT the diameter of the largest was used.

■ DISCUSSION

Previous studies have examined the differences in number, shape, and size of the FT; however, most of these studies were conducted on random collections of cervical vertebrae. We have performed this study on cervical vertebrae from intact spines, so our findings can be compared directly among the vertebrae of different levels. This key aspect of our study helps us to comment on whether these variations follow a particular pattern.

Accessory FTs (AFTs): According to Guera et al. (8) and Sangari et al. (23), the incidence of AFT is more common in the C3–C6 segment or in the vertebrae of the lower cervical spine (C5–C7). Considering these previous studies, we have studied FTs in detail in the C3–C7 segment of the cervical spine.

Taitz et al. studied 480 cervical vertebrae and found several variations in FTs. Double foramina were found in 34 cases. Among them, six vertebrae had double foramina of equal size, whereas others were of small dimensions. The absence of FT was observed in four vertebrae, and one case exhibited triple foramina (26).

Murlimanju et al. studied 363 cervical vertebrae and found 6 cases (1.6%) of AFTs, 4 cases of absent FT, and 1 C6 vertebra containing triple foramina. AFTs were smaller than the main FT and occurred more commonly on the left side than on the right side (15).

Sangari et al. studied 71 typical vertebrae (C3–C6) and reported 17 (24%) of vertebrae contained an AFT. The AFT was always smaller than and located posterior to the main FT (23).

Patra et al. studied 150 cervical vertebrae (C3–C7) and observed an AFT in 33 (22.00%) vertebrae, including unilateral AFT in 16 (10.67%) vertebrae and bilateral AFTs in 17 (11.33%) vertebrae (17).

Sharma et al. examined 200 typical cervical vertebrae and found an AFT in 16 vertebrae, either unilaterally or bilaterally (24).

Wysocki et al. examined 100 spines and found an AFT in 167 cases, most predominantly at the level of C6 (45.6%) and least commonly at the level of C3 (2.8%). The AFTs were always smaller in size than the main FT. Wysocki et al. also mentioned one C7 vertebra with triple foramina (28).

In the current study, 20% of C3–C7 cervical vertebrae showed the presence of an AFT. Among them, unilateral AFT was found in 12 typical cervical vertebrae (C3–C6) and in 6 C7 vertebrae. Bilateral AFT was found in 14 typical cervical vertebrae and in 8 C7 vertebrae. Thus, bilateral AFT was slightly more common than unilateral AFT. AFTs were smaller than and located posterior to the primary FT in all but one case. We found that the incidence of AFT increases with descending order of the vertebra, with AFTs most commonly found in C7.

According to Aydinoglu et al. (1), the occurrence of AFT is a low-frequency anatomical variation commonly associated with duplication of vertebral artery. Therefore, the presence of an AFT may indicate an alteration in the course and pattern of

the vertebral artery and vein and cervical sympathetic nerves within the FT.

In a CT angiographic study, Sanchis-Gimeno et al. correlated the occurrence of AFT in C5–C6 vertebrae with the presence of clinical symptoms such as acute headache, vertigo, and vomiting after whiplash injuries. Sanchis-Gimeno hypothesized that the most pronounced bending during whiplash occurs at the level of C5–C6 vertebrae and causes such symptoms (21).

Osteophytic encroachments: It is well recognized that osteophytes from the uncinat and articular processes can impinge on the FT and cause clinically important sequelae such as vertebral artery compression or irritation of the sympathetic plexus surrounding the artery (14,25–27). Osteophytes most frequently affect the FTs of C5 and C6, where they also tend to have the largest area of encroachment (16). As the vertebral and basilar arteries contribute to the blood supply of both the brain and the inner ear, vertebral artery compression or spasm due to irritation of the surrounding sympathetic plexuses may present clinically as neurological symptoms or labyrinthine or hearing disturbances (19,26). The present study showed osteophytes in 21.3% of vertebrae studied, encroaching upon the FT in approximately half these vertebrae. C5 and C6 were the most commonly affected vertebrae, a result in accordance with the findings of Nathan (16). The intrusion of the osteophytes into the foramen may cause traumatic injury to the artery or twisting of the vertebral artery around them, resulting in external compression and arterial narrowing (3,23).

Shape of the main FT: Very few authors have studied the shape of the main FT. Taitz et al. classified the main FT into five types based on the direction of the main diameter of the FT. Taitz et al. found that the type 3 shape was most predominant in vertebrae of the lower cervical spine segment (C3–C7), whereas types 4 and 1 were most prominent in the C1 and C2 upper segments, respectively (26). In our present study, we used the classification method of Taitz et al. and found type 1 to be the most common (23.85%) and type 5 to be the least common (15.75%). Type 1 was predominant (27.13%) on the right side of the vertebrae, whereas type 4 was predominant (27.63%) on the left side, although no significant differences between sides were detected at any cervical level.

In contrast to the present work, Karau and Odula found that the right side showed a predominance of type 4 FTs (40.2%), whereas the left side showed predominance of types 2 and 5 FTs (39.2% each) (12). The variations in the shape of the FT might be due to differences in the orientation of the structures traversing the foramen, and vice versa. According to Xu et al., the vertebral artery occupies approximately two-thirds of the smallest diameter of the foramen and more than half of the largest diameter of the foramen (29). Additionally, the predominance of osteophytes on the medial or lateral margins of the FT has been suggested to narrow its mediolateral (transverse) diameter, leading to vertebral artery compression and dissection (7). Hence, type 2 FTs, with their main diameter arranged anteroposteriorly, can be assumed to be associated with maximal risk of vertebral artery compression syndrome. In contrast, type 3 FTs with their main diameter arranged transversely confer the lowest risk of compression injury to the neurovascular bundle (2).

Size of the main FT: According to the available literature, the right and left vertebral arteries are of unequal size in approximately 75% of individuals. In 10% of individuals, the artery on the right side is much narrower than the artery on the left side (8).

In the present study, we measured both APD and TD of FTs in cervical vertebrae from C3 to C7. Both diameters were larger in FTs on the left side than in FTs on the right side, but the difference was not significant.

Sangari et al. measured the diameters of FTs from C3 to C6. The mean FT diameter was 5.55 mm on the right side and 5.48 mm on the left side; although this difference was not significant, a considerable variation remained (23).

Gupta and Agarwal computed the APD and TD of FTs in cervical vertebrae from C1 to C7. They observed a statistically significant difference between the right and left mean TD and APD of FT in C1, C3–C5, and C7 vertebrae. In contrast, C2 and C6 showed no significant differences between sides. This finding indicates that the shapes of FTs vary at different levels of the cervical spine (9).

Studies conducted by Epstein (7) and Kaya et al. (13) also found the left FT to be larger than the right FT, but these studies did not perform statistical analyses.

Reviewing the previous literature indicates that the mean diameter of FTs varies at different levels of the cervical spine and follows a particular pattern.

In the present study, we found that the FT diameters in C3, C4, and C5 were within 1 SD of the mean. In C6 and C7, the diameter of the FT was >1 SD away from the mean. The TD of C7 vertebral FTs was 2 SDs narrower than the mean. In a similar study, Sangari et al. (23) measured the dimensions of the FT of typical cervical vertebrae (C3–C6). They also categorized narrow FTs according to their deviation from the mean and found that most of the FTs were within ± 1 SD of the mean. In 20 vertebrae, the dimension of FT was ≤ 1 SD away from mean, and among these, the difference was ≤ 3 SD from the mean in 5 vertebrae.

Taitz et al. reported the largest mean FT diameter in C1 vertebrae and the smallest mean diameter in C7 vertebrae. The mean diameters of left-side FTs were higher than those of right-side FTs at every vertebral level from C3 to C7, and the coefficient of variation of the FT increased cranio-caudally from C4 to C7 (26).

Gupta and Agarwal also reported that the mean width of FTs was highest in C1 vertebrae and lowest in C7 vertebrae. In the present study, we also found the mean FT width to be lowest in C7 vertebrae (9).

According to Ebraheim et al., FT width increased from C3 to C5 and then decreased at C6. This finding is in accordance with the observations in our present study (6).

Zibis et al. proposed that variations in FT as discovered in CT scans of the cervical spine may be considered a good indicator of vertebral artery variations, and vice versa (30). Therefore, these incidental findings should be thoroughly investigated in the preparation stage of spinal surgery.

The FT chiefly contains the vertebral artery. Thus, variations in the structure of the developing embryonic vertebral artery will manifest in variations in the size and number of FTs, and the reverse will also hold true (26). Embryologically, the vertebral artery originates from the fusion of the longitudinal anastomosis that joins the second to sixth cervical intersegmentary arteries, which arise from the primitive dorsal aorta (8,11). Almost all the intersegmental arteries degenerate, with the exception being the seventh cervical intersegmental artery, which gives rise to the first part of vertebral artery (10). Any developmental changes, such as failure of intersegmental arteries and primitive dorsal aorta to degenerate completely, may result in vertebral artery duplication or other variations usually observed. According to Taitz et al. (26), mechanical stress and erect posture are responsible for remodeling in the bony architecture of the cervical region. Such alterations in the cervical spine can either compress or potentially change the natural course of the vertebral artery within the FT and give rise to neurological symptoms. Understanding variations in the FT is crucial for neurosurgeons operating on the cervical spine and for radiologists interpreting radiological images (CT and magnetic resonance imaging) of the cervical region. Our study provides more information about the morphological characteristics of the FT and their variations.

CONCLUSION

The study has revealed existence of many variations in the FT in cervical vertebrae of North Indian origin. Differences in the number (duplication), size, and shape of FTs were not uncommon in the study population. Anatomical knowledge of such variations is surgically pertinent, as in such conditions the vertebral artery may become twisted or deformed, resulting in vertebrobasilar insufficiency. Morphometric measurements furnished in this study may be useful in determining precise surgical approaches for the removal of osteophytes or spurs compressing the vertebral arteries, and in interpretation of radiographic images of the cervical spine obtained through CT or cervical angiograms.

REFERENCES

1. Aydinoglu A, Kavakli A, Yesilyurt H: Foramen transversarium bipartite. *Van Tıp Dergisi* 8(4):110-112, 2001
2. Aziz J, Morgan M: Morphological study of the foramen transversarium of the atlas vertebra among Egyptian population and its clinical significance. *Anatomy Physiol Biochem Int J* 4(4):1-5, 2018
3. Cagnie B, Barbaix E, Vinck E, D'Herde K, Cambier D: Extrinsic risk factors for compromised blood flow in the vertebral artery: Anatomical observations of the transverse foramina from C3 to C7. *Surg Radiol Anat* 27(4):312-316, 2005
4. Cloward RB: The anterior approach for removal of ruptured cervical disks. *J Neurosurg* 15(6):602-617, 1958
5. Das S, Suri R, Kapur V: Double foramen transversaria. An osteological study with clinical implications. *Int Med J* 12:311-313, 2005

6. Ebraheim NA, Reader D, Xu R, Yeasting RA: Location of the vertebral artery foramen on the anterior aspect of the lower cervical spine by computed tomography. *J Spinal Disord* 10(4):304-307, 1997
7. Epstein BS: The spine: A radiological text and atlas. Philadelphia: Lea and Febiger, 1969:24-25
8. Guerra MM, Fuentes PR, Roa I, Molinet G, Robles F, Roa I: Anatomical variations of the foramen transversarium in cervical vertebrae. *Int J Morphol* 35(2):719-722, 2017
9. Gupta M, Agarwal S: Morphometric study of foramina transversari and the incidence of accessory foramina in cervical spine of Indian population. *J Clin Diag Res* 13(3):AC07-AC11, 2019
10. Hamilton WJ, Mossman HW: Hamilton, Boyd & Mossman's Human Embryology. Cambridge: Heffer, 1972:261-271
11. Ionete C, Omojola MF: MR angiographic demonstration of bilateral duplication of the extracranial vertebral artery: Unusual course and review of the literature. *AJNR Am J Neuroradiol* 27(6):1304-1306, 2006
12. Karau PB, Odula P: Some anatomical and morphometric observations in the foramina of the atlas among Kenyans. *Anat J of Africa* 2(1):61-66, 2013
13. Kaya S, Yilmaz ND, Pusat S, Kural C, Kirik A, Izci Y: Double foramen transversarium variation in ancient Byzantine cervical vertebrae: Preliminary report of an anthropological study. *Turk Neurosurg* 21(4):534-538, 2011
14. Kovacs A: Subluxation and deformation of the cervical apophyseal joints; a contribution to the aetiology of headache. *Acta Radiol* 43(1):1-16, 1955
15. Murlimanju BV, Prabhu LV, Shilpa K, Rai R, Dhananjaya KV, Jiji PJ: Accessory transverse foramina in the cervical spine: Incidence, embryological basis, morphology and surgical importance. *Turk Neurosurg* 21(3):384-387, 2011
16. Nathan H: Compression of the sympathetic trunk by osteophytes of the vertebral column in the abdomen: An anatomical study with pathological and clinical considerations. *Surgery* 63(4):609-625, 1968
17. Patra A, Kaur H, Chhabra U, Kaushal S, Kumar U: Double foramen transversarium in dried cervical vertebra: An osteological study with its clinical implications. *Indian J Oral Sci* 6:7-9, 2015
18. Riew K: Microscope-assisted anterior cervical decompression and plating techniques for multilevel cervical spondylosis. *Operative Techniques in Orthopaedics* 8:22-33, 1988
19. Romanov VA, Miller LG, Gaevyĭ MD: The effect of the vertebral nerve on circulation in the inner ear (cochlea). *Biull Eksp Biol Med* 75(6):10-12, 1973
20. Rosse C, Gaddum Rosse P: The vertebral column. Hollinshead's Text Book of Anatomy. Philadelphia: Lippincott-Raven, 1997
21. Sanchis-Gimeno JA, Blanco-Perez E, Llido S, Perez-Bermejo M, Nalla S, Mata-Escolano F: Can the transverse foramen/vertebral artery ratio of double transverse foramen subjects be a risk for vertebrobasilar transient ischemic attacks? *J Anat* 233(3):341-346, 2018
22. Sandikcioglu M, Skov S, Solow B: Atlas morphology in relation to craniofacial morphology and head posture. *Eur J Orthod* 16(2):96-103, 1994
23. Sangari SK, Dossous PM, Heineman T, Mtui EP: Dimensions and anatomical variants of the foramen transversarium of typical cervical vertebrae. *Anat Res Int* 2015:391823, 2015
24. Sharma A, Singh K, Gupta V, Srivastava S: Double foramen transversarium in cervical vertebra an osteological study. *J Anat Soc India* 59:229-231, 2010
25. Sheehan S, Bauer RB, Meyer JS: Vertebral artery compression in cervical spondylosis: Arteriographic demonstration during life of vertebral artery insufficiency due to rotation and extension of the neck. *Neuroradiology* 10:968-986, 1960
26. Taitz C, Nathan H, Arensburg B: Anatomical observations of the foramina transversaria. *J Neurol Neurosurg Psychiatry* 41(2):170-176, 1978
27. Tissington Tatlow WF, Bammer HG: Syndrome of vertebral artery compression. *Neurology* 7(5):331-340, 1957
28. Wysocki J, Bubrowski M, Reymond J, Kwiatkowski J: Anatomical variants of the cervical vertebrae and the first thoracic vertebra in man. *Folia Morphol (Warsz)* 62(4):357-363, 2003
29. Xu R, Nadaud MC, Ebraheim NA, Yeasting RA: Morphology of the second cervical vertebra and the posterior projection of the C2 pedicle axis. *Spine (Phila Pa 1976)* 20(3):259-263, 1995
30. Zibis A, Mitrousias V, Galanakis N, Chalampalaki N, Arvanitis D, Karantanis A: Variations of transverse foramina in cervical vertebrae: What happens to the vertebral artery? *Eur Spine J* 27(6):1278-1285, 2018