

# Using of the Synthetic Dural Graft as Described in Bogota Bag Technique to Decrease the Adhesions in Decompressive Craniectomy

Ulas YUKSEL<sup>1</sup>, Bulent BAKAR<sup>1</sup>, Alemiddin OZDEMIR<sup>1</sup>, Mehmet ZENGİN<sup>2</sup>, Serhat COMERT<sup>3</sup>, Mustafa OGDEN<sup>1</sup>

<sup>1</sup>Kirikkale University, Faculty of Medicine, Department of Neurosurgery, Kirikkale, Turkey

<sup>2</sup>Kirikkale University, Faculty of Medicine, Department of Pathology, Kirikkale, Turkey

<sup>3</sup>Yenimahalle Training and Research Hospital, Neurosurgery Clinic, Ankara, Turkey

**Corresponding author:** Ulas YUKSEL ✉ ulasyksl@hotmail.com

## ABSTRACT

**AIM:** To create an alternative synthetic dural graft using a parenteral solution bag made of polyvinyl chloride/polypropylene (PVC/PP).

**MATERIAL and METHODS:** Twenty-two albino rats were divided into the Sham, DC and BAG groups. Except for the Sham group animals, the right parietal bone of the rats was totally drilled in a diameter of 1.0 x 0.5 mm. Then, the PVC/PP BAG was layered over the craniectomized bone of the BAG group animals. Thirty days later, all animals were sacrificed, and inflammatory processes consisting of polymorphonuclear cell infiltration, inflammation, edema, hyperemia, lymphocytosis, histiocytosis, vascular proliferation, and fibrosis were graded at the craniectomy site.

**RESULTS:** The grade values of inflammation, edema, histiocytosis, and fibrosis were found different among the groups ( $p<0.017$ ). It was observed that placing a synthetic graft to the surgical site undergoing craniectomy could prevent fibrotic adhesions that might occur between the brain tissue and scalp in the chronic period. Furthermore, it was considered that this synthetic material did not increase inflammatory processes secondary to surgery at the surgical site and did not produce a foreign body reaction, toxicity, or infection.

**CONCLUSION:** As a result of this study, it was argued that the synthetic material used in this study could be compatible with dermal and neural tissues and reduce adhesions at the craniectomy field. Therefore, it was considered that this material could be used as an alternative synthetic dural graft in decompressive craniectomy in human subjects after detailed toxicity studies.

**KEYWORDS:** Bogota bag, Decompressive craniectomy, Fibrosis, Dural graft, Synthetic

## INTRODUCTION

Decompressive hemicraniectomy (DC) and duroplasty represents a surgical procedure that is still commonly used to reduce the mortality rate in subjects with malignant hemispheric infarction, traumatic brain injury (TBI), subarachnoid hemorrhage (SAH), intracerebral hemorrhage, cerebral venous and sinus thrombosis, or infections (34). However, it is known that adhesions can usually develop

between the brain cortex, scalp and temporal muscle after decompressive craniotomy and may increase the duration of reconstruction surgery and complications during and after surgery (14,36). It has been previously suggested in the literature that autografts, allografts, xenografts and synthetic dural grafts placed during the first craniectomy can reduce these adhesions, provide a structural and protective barrier for the cortex during cranioplasty and provide a dissection plane, decrease the risk of venous thromboembolism, reduce

Ulas YUKSEL  : 0000-0002-6398-4110  
Bulent BAKAR  : 0000-0002-6236-7647  
Alemiddin OZDEMIR  : 0000-0002-5431-7287

Mehmet ZENGİN  : 0000-0001-2345-6789  
Serhat COMERT  : 0000-0001-8810-5787  
Mustafa OGDEN  : 0000-0002-7129-0936

surgery time, blood loss, and the duration of anesthesia (4,14,16,26,27,29,33). However, there is still no consensus on the “best dural graft” to be used to improve surgical outcomes. Moreover, in decompressive craniotomy surgeries performed under emergency conditions, time is restricted for allograft duraplasty, as well as other graft options, which may be very costly and not often available in the operating room (25,27).

In surgical clinics, due to their good handling properties such as strength, elasticity, formability and resistance to absorption (2), synthetic materials obtained from plastic (polyvinyl chloride, polypropylene) bags of sterilized parenteral solutions, as has been previously described in the Bogota bag or Borraez bag technique, are still using to prevent adhesion between the viscera and parietal peritoneum and reduce the risk of lesions and provide the irrigation of the cavity (20,32). Moreover, studies have demonstrated that polypropylene can reduce the inflammatory response, is relatively more resistant to infections, and is compatible with patients. Furthermore, it has been determined to be extremely resistant to biological degradation and tissue enzymes (25).

To reduce the complications of the cranioplasty surgery, the aim of this preliminary study was to create a synthetic dural graft alternative, which is sterile, does not adhere to tissues, is inexpensive, easily available and applicable with various sizes and easily shaped using a parenteral solution bag made of polyvinyl chloride/polypropylene.

## ■ MATERIAL and METHODS

### Materials

This experimental study was performed in accordance with the guidelines for the use of laboratory animal subjects in research set by the Local Ethics Committee.

Twenty-two albino rats weighing between 250-350 mg were utilized by being randomly divided into three main groups used for chronic stage investigation (30 days after the application). The groups were as follows:

- Sham group (neither craniectomy nor bag was applied; n=5);
- DC group (craniectomy was applied, but no bag was layered on the brain surface; n=5+3);
- BAG group (craniectomy was applied, and the bag was layered on the brain surface; n=6+3).

A parenteral solution bag (Polifleks, Polifarma, Turkey), which is produced using polyvinyl chloride/polypropylene (PVC/PP), was used as a synthetic dural graft in this study.

Sedation anesthesia was applied with the intraperitoneal administration of ketamine HCl (Ketalar®; Pfizer Inc, USA) and xylazine HCl (Rompun® 2%; Bayer HealthCare AG, Germany).

### Surgical Procedure

All animals were sedated with the intraperitoneal administration of ketamine HCl 40 mg/kg and xylazine HCl 6 mg/kg during spontaneous respiration at room temperature. Under an

operating microscope, the head skin was vertically incised from the nose to the craniocervical junction in the midline route. Except for the Sham group animals, the right parietal bone of the rats was drilled in a diameter of approximately 1.0 x 0.5 mm, and the cranium piece was removed by simple microdissector. Then, a dural incision was made for dural opening, and the PVC/PP bag, which was cut in a diameter of approximately 1.5 x 1.0 cm (i.e., its size was wider than the craniectomy diameter) was layered on the craniectomized bone of the BAG group animals without dural closure (Figure 1A-D). Following the mentioned procedure, all rats were removed from sedation anesthesia spontaneously under the blanket. Afterward, they were kept at normal room temperature and examined by a neurosurgeon twice a day for the development of any neurological deficit. During the experiment period, no antibiotic or anti-inflammatory agent that could suppress the development of inflammatory reactions was used. After thirty days, all animals were re-sedated with the intraperitoneal administration of ketamine HCl 40 mg/kg and xylazine HCl 6 mg/kg for sacrifice. All rats were sacrificed using the cervical dislocation technique and then they were decapitated. Afterward, three rats from the DC group and three rats from the BAG group were used for demo purposes to evaluate adhesions and anatomical distortions during the surgical dissection. The remaining rat heads were stored in 10% buffered formaldehyde solution at room temperature for a future histopathological examination.

### Histopathological Analysis

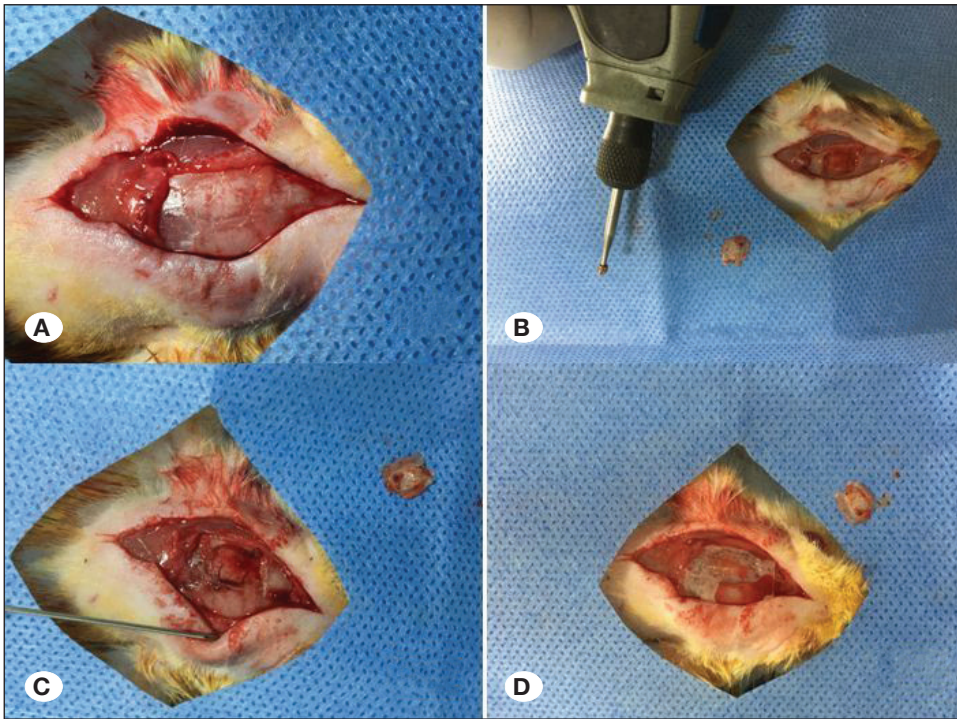
Briefly, the specimens collected for histopathological analysis were fixed in 4% paraformaldehyde in phosphate-buffered saline at a pH value of 7.4 for a period of 48 hours. They were immersed into 10% EDTA for decalcification and washed with tap water overnight. The tissues were prepared in a routine way by dehydration through a graded alcohol and xylene series, following which they were embedded in paraffin blocks. Paraffin serial sections were cut at a thickness of 4–5 µm, placed onto poly-L-lysine-coated glass slides and mounted on glass slides. Hematoxylin-eosin (H&E) staining was carried out, and the sections were analyzed histopathologically under a light microscope (Nikon Eclipse E600, Nikon AG Instruments, Switzerland).

The inflammatory processes consisted of *polymorphonuclear cell infiltration, inflammation, edema, hyperemia, lymphocytosis, histiocytosis, vascular proliferation, and fibrosis*, which were graded in accordance with the histopathological scoring table mentioned below. For the purpose of avoiding the observer's bias, a blinded pathologist quantified all sections.

- Grade 0: Normal
- Grade 1: Mild
- Grade 2: Moderate
- Grade 3: Severe

### Statistical Analysis

The histopathological grade values were analyzed statistically by the *Kruskal-Wallis* test. *p* values below 0.05 were regarded



**Figure 1:** The rat head skin was vertically incised from the nose to the craniocervical junction in mid-line route (A); right parietal bone was totally drilled approximately in diameter of 1.0 X 0.5 mm (B, C); and then synthetic graft which was cut approximately in diameter of 1.5 x 1 cm was layered on the craniectomized bone of the BAG group animals (D).

to be significant. To reveal statistical differences (post hoc evaluation) between the groups, the *Mann-Whitney U* test and the *Bonferroni correction* test were conducted, and *p* values below 0.017 were considered to be significant.

## RESULTS

### Demo Results

At the end of the experiment, it was observed during the dissection performed in the demo animals of the BAG group that both the scalp and brain tissue were more easily separated from the synthetic graft, and there was no apparent adhesion between them. However, in the demo animals of the DC group, adhesions were observed between the brain tissue and galea tissue at the craniectomy site that was closed without applying the synthetic graft. These subjective findings also supported the results of the experiment.

### Light Microscopy

According to the normal brain parenchyma, a similar inflammatory density was observed in the subjects in the DC and BAG groups. It was also observed that the inflammatory response increased at the craniotomy site and around the synthetic graft. However, no inflammatory response was observed in the brain parenchyma for any of the groups (Figure 2).

### Histopathological Analysis

The histopathological grade values of inflammation ( $X^2=11.737$ ,  $p=0.003$ ), edema ( $X^2=11.286$ ,  $p=0.004$ ), hyperemia ( $X^2=11.340$ ,  $p=0.003$ ), lymphocytosis ( $X^2=8.142$ ,  $p=0.017$ ), histiocytosis ( $X^2=11.776$ ,  $p=0.003$ ), vascular proliferation

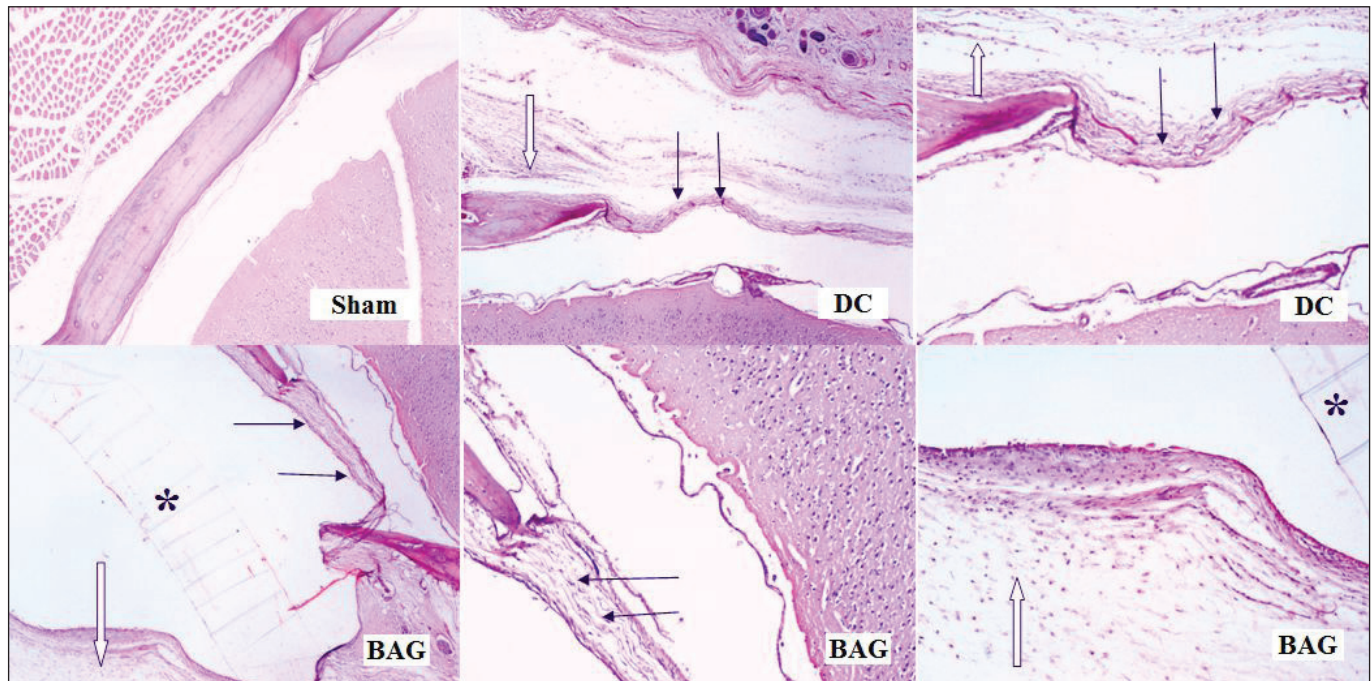
( $X^2=11.082$ ,  $p=0.004$ ), and fibrosis ( $X^2=12.949$ ,  $p=0.002$ ) were found different among the groups (Table I).

The *post hoc* test results revealed that the inflammation grade values differed between the Sham and DC ( $Z=-2.449$ ,  $p=0.014$ ) groups and between the Sham and BAG ( $Z=-2.894$ ,  $p=0.004$ ) groups. The edema grade values differed between the Sham and DC ( $Z=-2.909$ ,  $p=0.014$ ) groups and between the Sham and BAG ( $Z=-2.894$ ,  $p=0.004$ ) groups. The hyperemia grade values differed between the Sham and BAG ( $Z=-2.909$ ,  $p=0.004$ ) groups. The histiocytosis grade values were found different between the Sham and DC ( $Z=-2.449$ ,  $p=0.014$ ) groups and between the Sham and BAG ( $Z=-2.909$ ,  $p=0.004$ ) groups. The vascular proliferation grade values were determined to be different between the Sham and BAG ( $Z=-2.932$ ,  $p=0.003$ ) groups. Finally, the fibrosis grade values were revealed to be different between the Sham and DC ( $Z=-2.835$ ,  $p=0.005$ ) groups and between the Sham and BAG ( $Z=-2.932$ ,  $p=0.003$ ) groups (Table II, Figure 3).

## DISCUSSION

Adhesions that develop between the cortex, scalp, and temporal muscle after decompressive craniotomy can increase the duration of reconstruction surgery and complications during and after surgery (14,36). Due to these adhesions, the cerebral cortex and / or cerebral vessels may be damaged while they are dissected from the scalp or temporal muscle. Furthermore, if the temporal muscle is left under the bone flap, a part of the muscle may cause a mass effect on the brain parenchyma and seizures and/or headache due to dural irritation. Moreover, the temporal muscle may remain under the bone flap after the wrong temporal muscle dissection, and it





**Figure 2:** According to the normal brain parenchyma, similar inflammatory density was observed in subjects in the DC group and BAG group. It was also observed that the inflammatory response increased in the craniotomy field (white arrow) and around the synthetic graft (black arrow). However, no inflammatory response was observed in the brain parenchyma for either group. (\*) refers to the synthetic graft.

**Table 1:** Table Describes the Histopathological Analyses Results

	Sham	DC	BAG		
Variable	Median (min-max)	Median (min-max)	Median (min-max)	$\chi^2$	p
Polymorphonuclear cell infiltration	1 (1-1)	1 (1-2)	2.50 (1-4)	5.527	0.063
Inflammation	1 (1-1)	2 (1-2)	3 (2-4)	11.737	<b>0.003</b>
Edema	1 (1-1)	2 (1-2)	2.50 (2-4)	11.286	<b>0.004</b>
Hyperemia	1 (1-1)	2 (1-2)	3 (2-4)	11.340	<b>0.003</b>
Lymphocytosis	1 (1-1)	1 (1-1)	2.50 (1-4)	8.142	0.017
Histiocytosis	1 (1-1)	2 (1-2)	3.50 (2-4)	11.776	<b>0.003</b>
Vascular proliferation	1 (1-1)	1 (1-2)	2.50 (2-3)	11.082	<b>0.004</b>
Fibrosis	1 (1-1)	2 (2-3)	3.50 (3-4)	12.949	<b>0.002</b>

The Kruskal-Wallis test, ( $p < 0.05$ ). (**Min:** Minimum, **Max:** Maximum,  $\chi^2$ : Chi-square).

may cause worse cosmetic results since there is not sufficient muscle to cover the bone flap (8,18,19). In this regard, it has been recommended to use dural grafts during decompressive craniectomy (27).

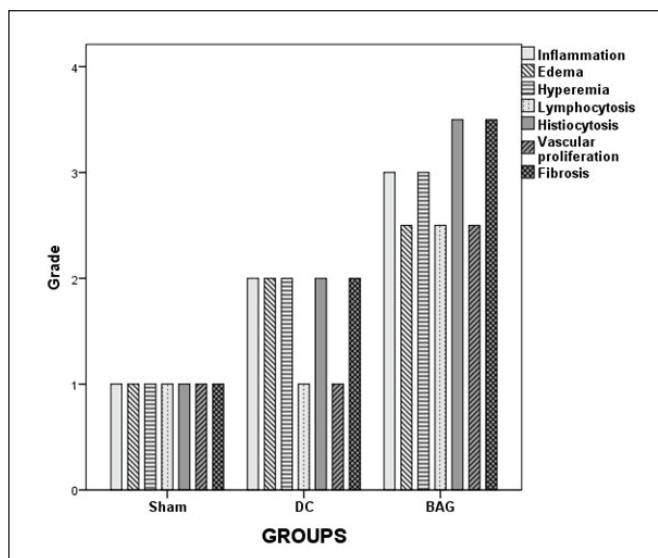
Dural autografts (such as galea-pericranium or fascia lata) are often preferred due to their cost-effectiveness and almost the complete absence of the risk of tissue rejection or infection (unlike allografts) (15,28,35,39). On the other hand, the size of the existing autograft may not be enough to close a large dural defect that occurs during DC, and the duration of the graft

removal may cause adverse results, such as the unnecessary prolongation of the operation time and additional morbidities that may occur when the graft is obtained from the fascia lata muscle. Moreover, these vital grafts may densely adhere to the adjacent tissues, such as the scalp, and cause difficulty in surgical dissection. As a result, it is thought that it is not practical to use autologous tissues because of these negative aspects, and it can increase surgical morbidity (9,25,27,29,39). Nowadays, due to the mentioned disadvantages of autografts, the trend toward various biological (such as allografts and xenografts) and synthetic grafts is, therefore, increasing (27).

**Table II:** Table Demonstrates the Post Hoc Test Results of the Histopathological Findings

Variable	Group (I-J)	Z	p
Inflammation	Sham/ DC	-2.449	<b>0.014</b>
	Sham/ BAG	-2.894	<b>0.004</b>
	DC / BAG	-2.202	0.028
Edema	Sham/ DC	-2.449	<b>0.014</b>
	Sham/ BAG	-2.909	<b>0.003</b>
	DC / BAG	-1.909	0.056
Hyperemia	Sham/ DC	-1.964	0.050
	Sham/ BAG	-2.909	<b>0.004</b>
	DC / BAG	-2.327	0.020
Lymphocytosis	Sham/ DC	0.000	1.000
	Sham/ BAG	-2.121	0.034
	DC / BAG	-2.121	0.034
Histiocytosis	Sham/ DC	-2.449	<b>0.014</b>
	Sham/ BAG	-2.909	<b>0.004</b>
	DC / BAG	-2.214	0.027
Vascular proliferation	Sham/ DC	-1.500	0.134
	Sham/ BAG	-2.932	<b>0.003</b>
	DC / BAG	-2.345	0.019
Fibrosis	Sham/ DC	-2.835	<b>0.005</b>
	Sham/ BAG	-2.932	<b>0.003</b>
	DC / BAG	-2.345	0.019

Mann-Whitney U test and Bonferroni Correction test,  $p < 0.017$ . (Z: Z score).



**Figure 3:** Bars represent inflammatory processes consisted of inflammation, hyperemia, edema, lymphocytosis, histiocytosis, vascular proliferation and fibrosis va.

Theoretically, xenografts (such as the pericardium, intestinal submucosa or peritoneum obtained from bovine, porcine, equine, or ovine donors) (1,3,5,10,23,24,37) or synthetic grafts (such as silicon, polytetrafluoroethylene (PTFE), expanded PTFE, polyethylene polyester urethane, polylactic acid sheets, polyglactin 910-polydioxanone, polysiloxane-carbonate film, biosynthetic cellulose) do not generally trigger the inflammatory response (6,11,22,25,30,33,38). Xenografts are preferred in many clinics because they are abundant in use, have dura-like mechanical properties and have relatively lower costs. Nevertheless, xenografts may have a risk of immunological reactions, in addition to zoonotic diseases. Furthermore, it is not possible to effectively neutralize prion proteins on the graft by neutralizing agents (13,21,31).

Due to all the above-mentioned disadvantages of autologous grafts and xenografts, studies have focused on synthetic and semi-synthetic dural grafts (23,24,25). Synthetic materials have begun to be a suitable alternative, with good handling properties such as easy accessibility, strength, elasticity, and formability. However, synthetics are not exposed to vascular and epithelial fusion with natural dura as biological grafts, which can complicate radiography and cause inflammatory reactions or friction injury (2). Polypropylene has been determined to reduce the inflammatory response, be relatively more resistant to infections and compatible with tissues. Furthermore, it has been reported to be extremely resistant to biological degradation and tissue enzymes (25). In the current study, the main purpose was to find an alternative dura graft that could be cheap, easily available, compatible with neural and other tissues, and easily shaped. For this purpose, we chose to use the PVC/PP dural graft which can be obtained from a parenteral solution bag, which has already been used in abdominal surgeries and is proven to be effective, cheap and easily available and has a width that could close the surgical site and is easily shaped.

At the end of this study, it was observed that the inflammation, edema, hyperemia, histiocytosis, vascular proliferation, and fibrosis grade values differed among the groups. However, polymorphonuclear cell infiltration grade values were not found to be different among the groups. Considering these findings, it was thought that this synthetic material applied did not cause the acute inflammatory reaction related to infection in the late period in subjects. The pairwise comparisons revealed that the inflammation, edema, histiocytosis, and fibrosis grade values significantly increased in the animals in the DC and BAG groups. However, these parameters were not different between the DC and bag groups. Therefore, it was considered that the PVC/PP graft did not aggravate the inflammation, edema, hyperemia, lymphocytosis, histiocytosis, vascular proliferation, and fibrosis grade values at the craniectomy site. Moreover, no inflammation was observed in the adjacent cerebral cortex where the PVC/PP graft contacted directly, although the marked chronic inflammation characterized by histiocytosis and fibrosis was observed at the craniectomy site. Briefly, with and without draped synthetic grafts over the brain surface, no statistically significant difference was found in the level of inflammation formation, edema development, hyperemia, lymphocytosis, histiocytosis, and

fibrosis development. Therefore, it was considered that the application of a synthetic graft to the craniectomy site did not cause a significant increase in inflammatory processes secondary to craniectomy and did not cause a significant foreign body reaction, toxicity, or infection in neural or other tissues. Moreover, at the end of the experiment, it was observed during the dissection performed in the demo animals of the BAG group that both the scalp and brain tissue were more easily separated from the synthetic graft, and there was no apparent adhesion between them. However, in the demo animals of the DC group, adhesions were observed between the brain tissue and galea tissue at the craniectomy site that was closed without applying the synthetic graft. These subjective findings also supported the results of the experiment.

As a result, it was thought in the light of histopathological results that placing a synthetic graft obtained from a PVC/PP bag to the surgical site undergoing craniectomy could prevent fibrotic adhesions that might occur between the brain tissue and scalp in the chronic period. Furthermore, it was thought that this synthetic material did not increase inflammatory processes secondary to surgery at the surgical site and did not produce a foreign body reaction, toxicity, or infection. Therefore, it was considered that this synthetic material could be compatible with dermal and neural tissues. However, it was argued that detailed toxicity studies in animal models should be conducted before applying this material to humans.

### Study Limitations

The current preliminary research has a number of limitations. *Firstly*, the present study did not include the results of more specific biochemical and histopathological analyses for other cytotoxic pathways because of technical and/or financial restrictions. Moreover, it is necessary to support this research with electron microscopic findings, which can demonstrate the presence of any ultrastructural findings of an inflammatory response and/or neuronal toxicity. However, according to the study results, it can be said that this synthetic material is, most likely, biocompatible and nontoxic to the neural tissue in rats and can be used as a dural graft material after detailed investigations. *Secondly*, by evaluating the effect of the synthetic dural graft on preventing adhesions developing at the surgical site, it could be thought that this graft should remain at the surgical site for longer than one month. However, in the recent literature, it has been reported that the risk of developing complications (such as infection, seizure, hydrocephalus, autologous bone flap resorption, neurological deterioration due to the sinking skin flap) may be high in patients undergoing late cranioplasty. Moreover, it has been recommended that the application time of cranioplasty should be between 30-45 days after decompressive craniectomy (7,12,17). Therefore, according to the recommendations made in the literature, it was considered appropriate to evaluate the graft effectiveness at the end of 30 days in this study. *Thirdly*, the present research is far from the investigation of any toxic impacts of PVC/PP in the long term due to the selected time period. *Finally*, in this preliminary study, the toxicity profile of PVC/PP was not compared with other materials (such as PTFE, bovine or cadaveric pericardial graft, etc.). Therefore,

this study results demonstrated with the above-mentioned limitations that this study might guide future studies on this issue.

### CONCLUSION

In conclusion, it has been considered that to prevent adhesions and provide the protection of neural and dermal tissues the PVC/PP bag used to drape the craniectomy site could be an alternative synthetic dural graft, which is cheap, easily available, has a low allergic activity.

### REFERENCES

1. Anson JA, Marchand EP: Bovine pericardium for dural grafts: Clinical results in 35 patients. *Neurosurgery* 39(4):764-768, 1996.
2. Azzam D, Romiyo P, Nguyen T, Sheppard JP, Alkhalid Y, Lagman C, Prashant GN, Yang I: Dural repair in cranial surgery is associated with moderate rates of complications with both autologous and nonautologous dural substitutes. *World Neurosurg* 113:244-248, 2018
3. Bejjani GK, Zabramski J, Duras Study Group: Safety and efficacy of the porcine small intestinal submucosa dural substitute: Results of a prospective multicenter study and literature review. *J Neurosurg* 84(3):508-513, 1996
4. Bulters D, Belli A: Placement of silicone sheeting at decompressive craniectomy to prevent adhesions at cranioplasty. *Br J Neurosurg* 24:75-76, 2010
5. Centonze R, Agostini E, Massacesi S, Toninelli S, Morabito L: A novel equine-derived pericardium membrane for dural repair: A preliminary, short-term investigation. *Asian J Neurosurg* 11: 201-205, 2016
6. Cetin B, Sengul G, Tuzun Y, Gundogdu C, Kadioglu HH, Aydin IH: Suitability of collagen matrix as a dural graft in the repair of experimental posterior fossa dura mater defects. *Turk Neurosurg* 16(1):9-13, 2006
7. Demir O, Deniz FA: A clinical experience with decompressive craniectomy. *Turk Neurosurg* 2019 (Online ahead of print)
8. Di Rienzo A, Iacoangeli M, Alvaro L, Colasanti R, Nocchi N, Di Somma LG, Scerrati M: Autologous vascularized dural wrapping for temporalis muscle preservation and reconstruction after decompressive craniectomy: Report of twenty-five cases. *Neurol Med Chir (Tokyo)* 53:590-595, 2013
9. Dufrane D, Marchal C, Cornu O, Raftopoulos C, Delloye C: Clinical application of a physically and chemically processed human substitute for dura mater. *J Neurosurg* 98:1198-1202, 2003
10. Filippi R, Schwarz M, Voth D, Reisch R, Grunert P, Perneczky A: Bovine pericardium for duraplasty: Clinical results in 32 patients. *Neurosurg Rev* 24(2-3):103-107, 2001
11. Hamzaoglu V, Ozalp H, Karkucak A, Cokluk C: Comparison of the efficiency, side effects and complications of the synthetic dural grafts: Beriplast and Tissudura. *J Exp Clin Med* 32(2): 77-82, 2015
12. Iaccarino C, Kolas AG, Roumy LG, Fountas K, Adeleye AO: Cranioplasty following decompressive craniectomy. *Front Neurol* 10:1357, 2020



13. Ishida C, Okino S, Kitamoto T, Yamada M: Involvement of the peripheral nervous system in human prion diseases including dural graft associated Creutzfeldt-Jakob disease. *J Neurol Neurosurg Psychiatry* 76:325-329, 2005
14. Kawaguchi T, Hosoda K, Shibata Y, Koyama J: Expanded polytetrafluoroethylene membrane for prevention of adhesions in patients undergoing external decompression and subsequent cranioplasty. *Neurol Med Chir (Tokyo)* 43:320-324, 2003
15. Lam FC, Kasper E: Augmented autologous pericranium duraplasty in 100 posterior fossa surgeries-a retrospective case series. *Neurosurgery* 71 Suppl Operative 2:302-307, 2012
16. Lee CH, Cho DS, Jin SC, Kim SH, Park DB: Usefulness of silicone elastomer sheet as another option of adhesion preventive material during craniectomies. *Clin Neurol Neurosurg* 109:667-671, 2007
17. Malcolm JG, Rindler RS, Chu JK, Chokshi F, Grossberg JA, Pradilla G, Ahmad UF: Early cranioplasty is associated with greater neurological improvement: A systematic review and meta-analysis. *Neurosurgery* 82(3):278-288, 2018
18. Missori P, Paolini S, Ciappetta P, Seferi A, Domenicucci M: Preservation of the temporal muscle during the frontotemporo-parietal approach for decompressive craniectomy: Technical note. *Acta Neurochir (Wien)* 155:1335-1339, 2013
19. Missori P, Polli FM, Peschillo S, D'Avella E, Paolini S, Miscusi M: Double dural patch in decompressive craniectomy to preserve the temporal muscle: Technical note. *Surg Neurol* 70:437-439, 2008
20. Muhammad Y, Gondal KM, Khan UA: Use of the "bogota bag" for closure of open abdomen wound after exploratory laparotomy – our experience at Mayo Hospital Lahore. *J Park Med Assoc* 66:980-983, 2016
21. Ostendorf AP, Connolly AM: Medical management of eosinophilic meningitis following bovine graft duraplasty for Chiari malformation Type I repair: Case report. *J Neurosurg Pediatr* 12:357-359, 2013
22. Ozdol C, Alagoz F, Yildirim AE, Korkmaz M, Daglioglu E, Atilla P, Muftuoglu S, Belen AD: Use of spongostan™ for prevention of cranial subdural adhesions following craniotomy in an experimental rabbit model. *Turk Neurosurg* 25(5):707-711, 2015
23. Parížek J, Husek Z, Měrická P, Téra J, Němecek S, Spacek J, Němecekova J, Suba P: Ovine pericardium: A new material for duraplasty. *J Neurosurg* 106:1028-1033, 2007
24. Parížek J, Měrická P, Husek Z, Suba P, Spacek J, Němecek S, Němecekova J, Sercl M, Elias P: Detailed evaluation of 2959 allogeneic and xenogeneic dense connective tissue grafts (fascia lata, pericardium, and dura mater) used in the course of 20 years for duraplasty in neurosurgery. *Acta Neurochir (Wien)* 139(9):827-838, 1997
25. Pathrose Kamalabai R, Nagar M, Mohammed Haneefa Suharanbeevi S, Bhanu Prabhakar R, Peethambaran A, Mallika Dhanapalan S, Jain S, Sharma S: Rationale behind the use of double-layer polypropylene patch (G-patch) dural substitute during decompressive craniectomy as an adhesion preventive material for subsequent cranioplasty with special reference to flap elevation time. *World Neurosurg* 111:105-112, 2018
26. Pierson M, Birinyi PV, Bhimireddy S, Coppens JR: Analysis of decompressive craniectomies with subsequent cranioplasties in the presence of collagen matrix dural substitute and polytetrafluoroethylene as an adhesion preventative material. *World Neurosurg* 86:153-160, 2016
27. Raghavan A, Wright JM, Huang Wright C, Sajatovic M, Miller J: Effect of dural substitute and technique on cranioplasty operative metrics: A systematic literature review. *World Neurosurg* 119:282-289, 2018
28. Sabatino G, Della Pepa GM, Bianchi F, Capone G, Rigante L, Albanese A, Maira G, Marchese E: Autologous dural substitutes: a prospective study. *Clin Neurol Neurosurg* 116: 20-23, 2014
29. Sekhar LN, Mai JC: Dural repair after craniotomy and the use of dural substitutes and dural sealants. *World Neurosurg* 79(3-4): 440-442, 2013
30. Shimada Y, Hongo M, Miyakoshi N, Sugawara T, Kasukawa Y, Ando S, Ishikawa Y, Itoi E: Dural substitute with polyglycolic acid mesh and fibrin glue for dural repair: Technical note and preliminary results. *J Orthop Sci* 11:454-458, 2006
31. Tanaka S, Fukushima M: Size of Creutzfeldt-Jakob disease epidemic associated with cadaveric dura transplantation. *Neuroepidemiology* 34:232-237, 2010
32. Torres NJR, Barreto AP, Prudente ACL, Santos AM, Santiago RR: Uso da peritoneostomia na sepse abdominal. *Rev Bras Coloproctol* 27:278-283, 2007
33. Vakis A, Koutentakis D, Karabetsos D, Kalostos G: Use of polytetrafluoroethylene dural substitute as adhesion preventive material during craniectomies. *Clin Neurol Neurosurg* 108:798-802, 2006
34. Wachter D, Reineke K, Behm T, Rohde V: Cranioplasty after decompressive hemicraniectomy: Underestimated surgery-associated complications? *Clin Neurol Neurosurg* 115:1293-1297, 2013
35. Wang F, Xue Y, Zhao SS, Yang TJ, Song HQ, Liu H: Suturing-free artificial dura with dacron heart patch in decompressive craniectomy and cranioplasty. *Indian J Surg* 77 Suppl 3: 1008-1011, 2015
36. Yamagata S, Goto K, Oda Y, Kikuchi H: Clinical experience with expanded polytetrafluoroethylene sheet used as an artificial dura mater. *Neurol Med Chir (Tokyo)* 33(8):582-585, 1993
37. Yu F, Wu F, Zhou R, Guo L, Zhang J, Tao D: Current developments in dural repair: A focused review on new methods and materials. *Front Biosci (Landmark Ed)* 18:1335-1343, 2013
38. Zerris VA, James KS, Roberts JB, Bell E, Heilman CB: Repair of the dura mater with processed collagen devices. *J Biomed Mater Res B Appl Biomater* 83:580-508, 2007
39. Zhang GL, Yang WZ, Jiang YW, Zeng T: Extensive duraplasty with autologous graft in decompressive craniectomy and subsequent early cranioplasty for severe head trauma. *Chin J Traumatol* 13:259-264, 2010