

The Relationship Between Transpedicular Stabilization with Spinal Canal Type

Ismail KAYA¹, Huseyin BOZKURT²

¹Republic of Turkey, Ministry of Health, Sirnak State Hospital, Department of Neurosurgery, Sirnak, Turkey

²Republic of Turkey, Ministry of Health, University of Health Sciences, Keçioren Training and Research Hospital, Department of Neurosurgery Ankara, Turkey

Corresponding author: Ismail KAYA ✉ hekimikaya@gmail.com

ABSTRACT

AIM: To analyze the spinal canal type and spinal structure of patients, to determine appropriate preoperative preparation and surgical procedures to prevent material malposition, which is the most common complication of thoracolumbar posterior transpedicular stabilization (TPTS) and is a determiner of its clinical outcomes.

MATERIAL and METHODS: A total of 214 cases were examined. TPTS procedures carried out on each thoracolumbar vertebra were evaluated. Twenty parameters were documented and retrospectively examined in each patient.

RESULTS: Laminectomy is not helpful for healing unless there is spinal compression and ligamentotaxis is beneficial for healing. The correlation between the structure of the spinal canal and defective screw delivery found ($p < 0.05$).

CONCLUSION: The spinal structure formed around the canal should be the first form to evaluate while TPTS applications to protect the spinal cord, which is the focal point of the spinal structure.

KEYWORDS: Spinal canal type, Spinal structure, Thoracolumbar posterior transpedicular stabilization, Material malposition, Long-term results

ABBREVIATIONS: CT: Computed tomography, EMG: Electromyography, Et. al: and others, JOA: Japanese Orthopedic Association, MR: Magnetic resonance, PACS: Picture archiving and communication systems, TLICS: Thoraco-lumbar injury classification and severity, TPTS: Thoracolumbar posterior transpedicular stabilization.

INTRODUCTION

Spinal stabilization has been widely used over the last 50 years to treat multiple pathologies in neurosurgery. Thoracolumbar posterior transpedicular fixation (TPTF) surgery can be performed for many different reasons including mechanical instability, trauma, spinal stenosis, degenerative spondylolisthesis, lumbar disc surgery, scoliosis, facet joint syndrome, and degenerative disc disease.

The purpose of surgery is to:

- 1) correct spinal deformities
- 2) increase spinal fusion rates

3) provide nerve tissue decompression

4) facilitate improvement after surgery

The spinal canal can be examined in three ways:

- 1) Round
- 2) Oval
- 3) Trefoil shaped (7,14,21)

Each channel shape is associated with its spinal shape and configuration (Figure 1A-C). When we examined the spinal canal structures, the spinal canal was narrowed in the trefoil-shaped canal. The lateral recesses were narrowed, and

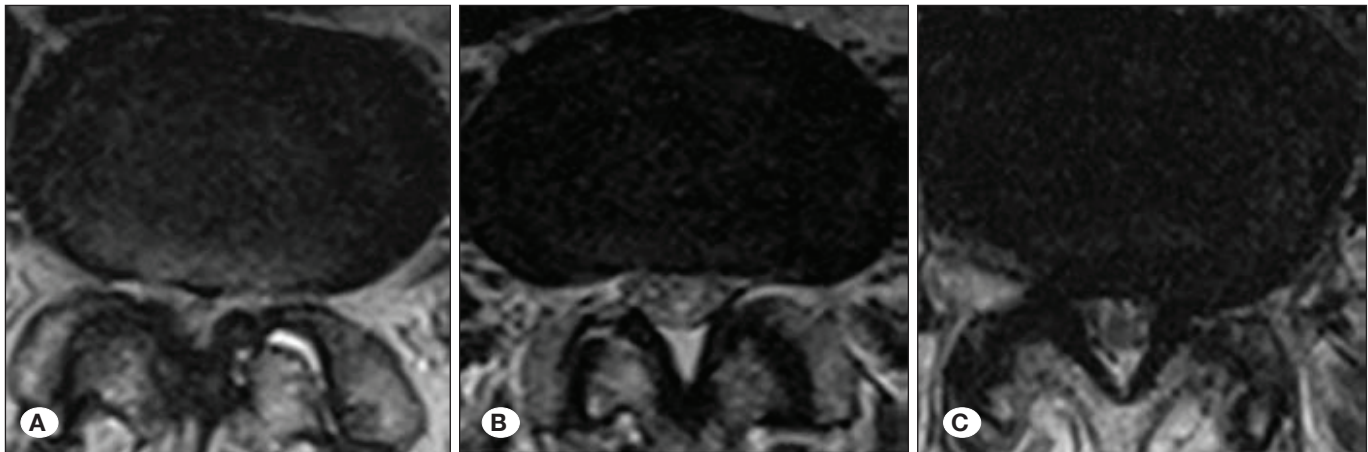


Figure 1: T2 Magnetic resonance images of oval (A), round (B), and trefoil (C) shaped spinal canal shapes and spine structure.

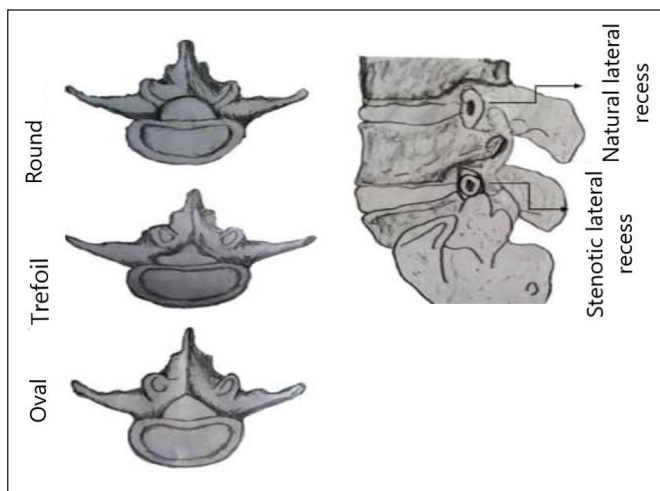


Figure 2: Spine canal shape and spine structure.

the facet was enlarged. In this type of spine, the pedicle is angled from a medial to a lateral position. Since the pedicle is larger, it is difficult to differentiate anatomically from other elements. Trefoil-shaped canal is more commonly seen in the lumbar spine. Although with age the shape becomes more prominent in the moving and degenerated segments, it is also familiarly widespread. In the round-shaped canal, the opposite is seen, and the pedicle is steeper and thinner. The spinal canal shape has more space in the spinal cord and is more common in the thoracic spine. Lateral recesses are more spacious in the thoracic spine. In the oval-shaped canal, there are a certain number of characteristics that resemble both ends of the spine, while it is mostly found in the transitional regions. Similarly, trefoil-shaped canals vertebrae bodies are more irregularly shaped when compared with round-shaped canals vertebrae bodies, although spinal body shapes are not separated by precise lines as canal shape (Figure 2) (19).

The purpose of this study was to carry out pre-operative preparation and operative technique proposals by analyzing and examining all the TPTF cases we performed in terms of spinal canal shape and spine structure what we think the

most important variables regarding screw misplacement and protection from the consequences of screw misplacement in TPTF surgery.

■ MATERIAL and METHODS

Transpedicular fixation procedures at each thoracolumbar distance were evaluated. In the patient selection process, age, sex, and surgical reason were not considered, but their effects were also mentioned. Since the area under investigation was the operation area, the distribution of the spinal canal shape in each operation area was examined, rather than each thoracolumbar spinal canal shape. The first sacral vertebrae were evaluated between the lumbar spine, not the sacral area. The second sacral vertebrae were not present in the cases. The ribs were used to distinguish between the thoracic and lumbar spine.

Each patient's age, sex, the reason for surgery, pre-operative and post-operative examination findings, Japanese Orthopedic Association (JOA) score, thoracolumbar injury classification and severity (TLICS) score (Figure 3), accident type, ligamentotaxis presence, dural damage owing to accidental or intraoperative causes, laminectomy, spinal canal shape and spine structure, wrong screw direction level, presence of post-operative infection, presence and cause of repeat-surgery, other rare side effects, screw failure in long-term follow up (a minimum of six months), and similar long-term follow up of 20 variables, including the cause of screw failure, were reported retrospectively and examined as described later.

All surgeries were performed by the same surgeons and surgical assistants.

A modified JOA score was used for scoring (Figure 4). The wellbeing of each patient was compared before and after surgery (6,15,16).

Magnetic resonance imaging (MRI) and computed tomography (CT) were carried out and measurements were made using the Sisoft picture archiving and communication systems (PACS) at our hospital.

Injury Category	Point Value
Injury morphology	
Compression	1
Burst	2
Translation or rotation	3
Distraction	4
PLC status	
Intact	0
Injury suspected or indeterminate	2
Injured	3
Neurologic status	
Intact	0
Nerve root involvement	2
Spinal cord or conus medullaris injury	
Incomplete	3
Complete	2
Cauda equina syndrome	3

Figure 3: TLICS scoring system evaluation.

I Motor dysfunction(upper extremities)	
0	Unable to feed oneself
1	Unable to handle chopsticks, able to eat with a spoon
2	Handle chopsticks with much difficulty
3	Handle chopsticks with slight difficulty
4	None
II Motor dysfunction(lower extremities)	
0	Unable to walk
1	Walk with walking aid
2	Able to go up and/or down stairs with handrail for support
3	Lack of stability and smooth gait
4	None
III Sensory deficit	
A Upper extremities	
0	Severe sensory loss or pain
1	Mild sensory loss
2	None
B Lower extremities same as A	
C Trunk same as A	
IV Sphinter dysfunction	
0	Unable to void
1	Marked difficulty in micturition(retention, stranguary)
2	Difficulty in micturition(pollakisuria, hesitation)
3	None

Figure 4: Modified JOA scoring.

Informed consent to undergo TPTF was obtained from patients in accordance with the preoperative Turkish Neurosurgical Society consent form. The form clearly stated that the data could be used under ethical rules.

The data obtained in the present study were analyzed using SPSS (ver:22.0). If the data provided parametric test assumptions for evaluation (data obtained by interval, ratio scale, normal distribution), a t-test for two groups (independent, conjugate) when not fulfilled (Kolmogorov–Smirnov); a Mann–Whitney U test, a chi-squared test used. Chi-squared exact test was used to determine the chi-squared value of Fisher's exact test Monte Carlo model. A p-value of <0.05 was considered statistically significant.

GraphPad Prism 7 was used to graph the data and Photoshop CS3 was used to edit pictures.

The study was approved by institutional non-interventional clinical research ethics committee (2018-06/24).

RESULTS

In total, 106 patients (49.53%) were female and 108 patients (51.47%) were male. The gender distribution is shown in Figure 5.

The minimum age of the patients was 14 years and the maximum age was 88 years (median age 53.5 years and the average was 52.3). The age distribution is shown in Figure 6.

An overall evaluation of post-operative data was carried out. Dural damage was observed in 30 patients (16.30%) owing to surgery or insult. Infection was observed in 17 patients (7.94%). Screw failure was observed in 9 patients (4.20%) at a follow-up of more than 6 months (Figure 7). A total of 27 patients (12.61%) were required to undergo a repeat procedure.

Almost all patients underwent repeat surgery, except for one deceased, an increase in the JOA score was observed (Figure 8).

The reasons for surgery were listhesis in 42 patients, scoliosis in 1 patient, collapse fracture in 10 patients, burst fracture in 111 patients, chance fracture in 1 patient, dislocation in

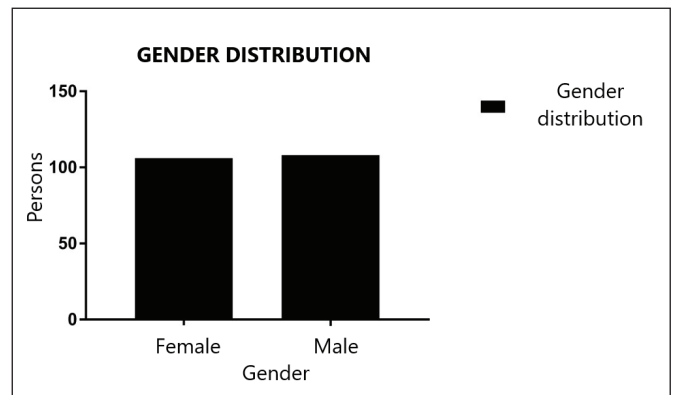


Figure 5: Gender distribution graph.

8 patients, spinal stenosis in 14 patients, multiple recurrent discs in 13 patients, adjacent segment disease in 1 patient, spinal mass in 2 patients, pathological fracture in 8 patients, osteoporotic fracture in 1 patient, and decompressive surgery in 2 patients. A total of 136 patients (63.55%) underwent

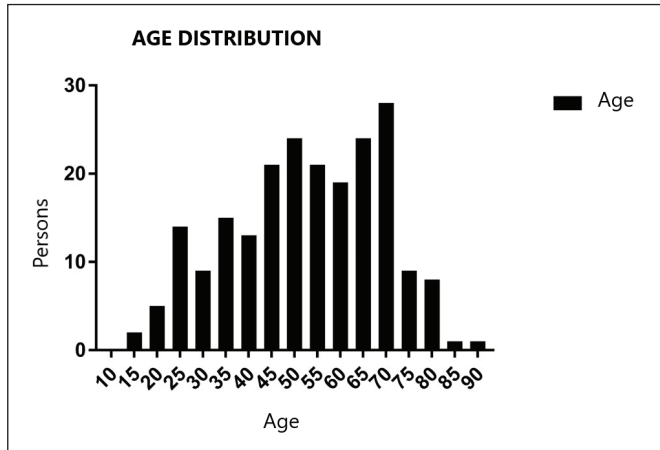


Figure 6: Age distribution graph.

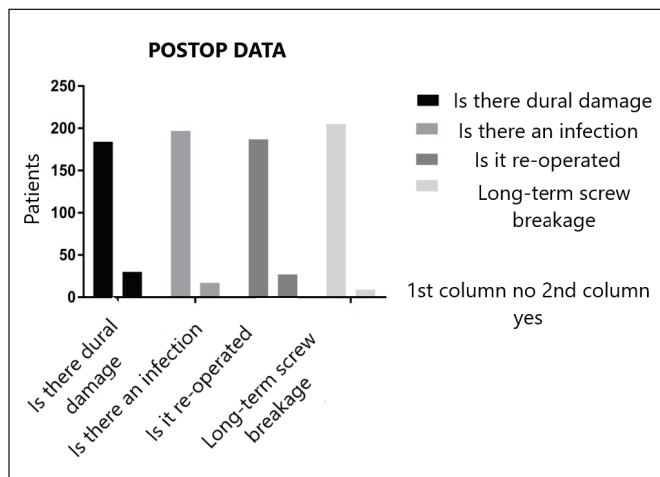


Figure 7: Postoperative data.

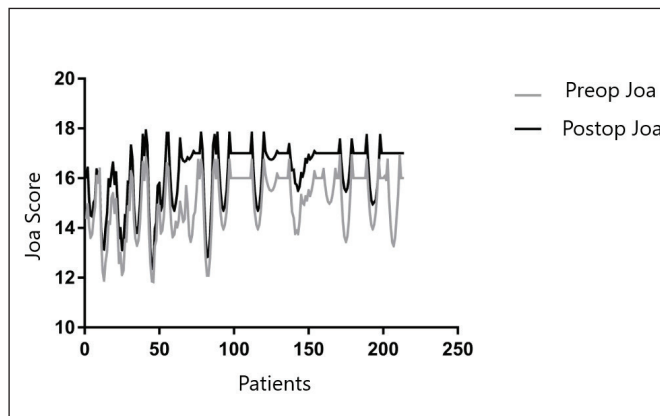


Figure 8: Preoperative and postoperative JOA scoring together.

surgery owing to accidents, among others; the highest rate of listhesis was observed in 42 patients (19.62%) and the remaining cases occurred in a minority of <10% (Figure 9).

Ligamentotaxis, which is the principle of our department, was applied to the patients as much as disease and biomechanical anatomy allowed. The frequency of administration according to recovery and disease will be discussed in the statistical evaluation (Figure 10).

A total of 46 patients presented with incorrect screw applications. We didn't repeat surgery without nerve damage, persistent pain, or thinking that incorrect screw would interfere with healing. Considering all these factors, when infection (7.94%) and screw fracture (4.20%) were eliminated, the number of patients that underwent repeat surgery was small (2 patients).

A total of 1334 screws were inserted into 214 patients; 77 of them (5.77%) were defective. When the total area of the spine was examined, 220 thoracic and 454 lumbar spines were attempted. Among thoracic spine 157 (71.36%) round, 36 (16.36%) oval, 27 (12.27%) trefoil canal structure observed. Also, in the lumbar spine 106 (23.34%) round, 39 (8.59%) oval 309 (68.06%) trefoil canal structure was observed. A total of 263 (39.02%) round-shaped canal, 75 (11.12%) oval-shaped canal, and 336 (49.85%) trefoil-shaped canal was studied. In this case, the round-shaped canal was very common in the thoracic spine, while the trefoil-shaped canal was common in the lumbar spine. The total number of incorrectly inserted screws was 77. Among these 37 were round, 34 were trefoil, and 6 were oval. A total of 35 incorrectly screw inserted vertebrae were thoracic and 42 were lumbar. There was a total of 9 triangular vertebrae bodies; 7 were thoracic and 2 were lumbar. Four of the triangular vertebrae bodies were the cause of the error. Among those screw inserted vertebrae bodies; 1 screw was long 3 screws were sent laterally and 1 screw was sent medially (1 screw was both long and send laterally). Triangular vertebrae body samples were not significant, but 44.45% misplacement will be discussed in the discussion. A total of 33 screws that were sent incorrectly were delivered medially, while 24 were delivered laterally. Fifteen of the screws were long, 4 were short, and 1 was delivered to occupy the foramen.

A total of 30 patients had dural damage. Comparing the reasons for surgery, the relationship between dural damage and explosion fracture is important. Four out of the 18 cases were due to the surgeon and 14 were due to insult. None of these 18 cases underwent repeat surgery for this reason. Patients did not undergo lumbar drainage, and all were recovered during postoperative follow-up. In the remaining 12 patients with dural damage, owing to the small number of cases, there was a weak relationship between dislocation, spinal stenosis, and the incidence of multiple recurrent discs.

There was no relationship between the cause of surgery and the incidence of post-operative infection. Likewise, there was no difference between the cause of surgery and repeat surgery, screw fracture or screw fracture reason. However, there was more accumulation in the burst fracture.

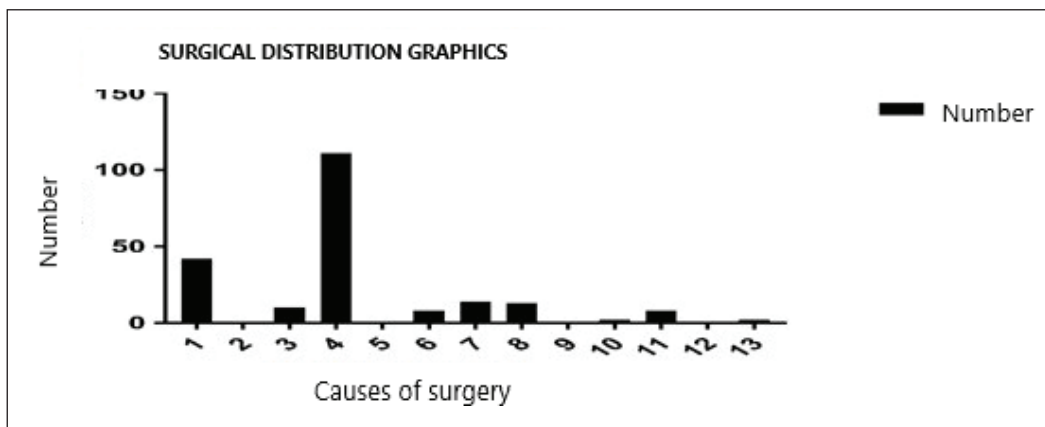


Figure 9: Operation cause distribution graph. listhesis 1, scoliosis 2, collapse fracture 3, burst fracture 4, chance fracture 5, dislocation 6, narrow canal 7, multiple relapsed disc 8, adjacent segment disease 9, spinal mass 10, pathological fracture 11, osteoporotic fracture 12 and cause of decompressive surgery numbered with 13.

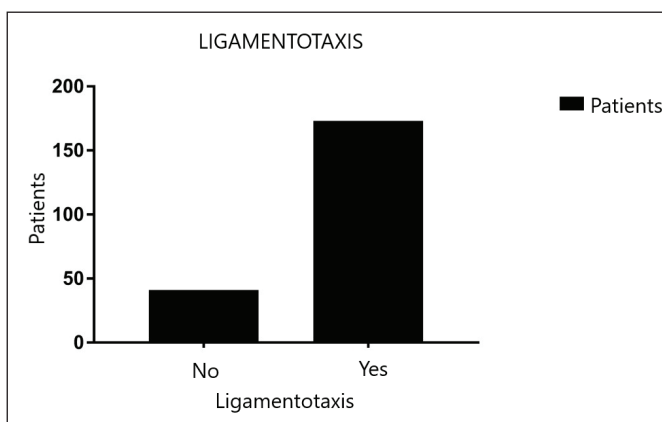


Figure 10: Frequency of ligamentotaxis application.

When the patients who underwent ligamentotaxis were compared with the reason for surgery, there was a strong correlation between listhesis, collapse fracture, burst fracture, spinal stenosis, and multiple recurrent discs. Although the number of cases was small, there was a weak association with osteoporotic fractures, decompression surgery, pathological fractures, dislocation, chance fractures, and scoliosis. Ligamentotaxis was applied more frequently in patients as time passed.

The difference between the causes of surgery among patients that underwent laminectomy was significant. A strong relationship between listhesis, burst fracture, spinal stenosis, and multiple relapsed disc was observed. Decompressive surgery, pathological fracture, spinal mass, and dislocation showed a weak relationship because the number of observed cases was low.

There was no significant difference between patients who underwent laminectomy and others regarding the presence of dural damage and post-operative recovery rate. When we examine the laminectomy, the number of applications decreased over time. No significant difference was observed between ligamentotaxis and screw fracture. Similarly, the rate of repeat procedure with laminectomy was non-significant. Also, an improvement was observed when ligamentotaxis and healing rates were compared.

The difference between the spinal canal shape and the level of the misplaced screw was significant. In the thoracic vertebrae, round-shaped canal and the lumbar vertebrae trefoil-shaped canal were strongly associated also in the lumbar vertebrae round-shaped canal poorly associated. The oval-shaped and trefoil-shaped canals in the thoracic area were rare; four cases of each were observed. Although there were two oval-shaped canals in the lumbar spine, the round-shaped canal relative to the trefoil-shaped canal was observed in a ratio of 1:3.

When the canal shapes of misplaced screws were compared with the screw direction a significant relationship was observed. Screws were sent in the form of a round-shaped canal (in 20 patients, 54.1%) mostly medially and at a close rate laterally (in 16 patients, 43.2%). Since the number of oval-shaped canals was small, there was a weak relationship and inadequate for opinion. In the trefoil-shaped canal, screws were positioned medially (in 10 patients, 29.4%) but it was also significant with lateral delivery (in 5 patients, 14.7%). In addition, more significantly long screw delivery was observed in the trefoil-shaped canal (14 patients, 41.2%).

When we compare the reasons for surgery with the incorrect screw applied spinal canal shape annular-shaped canal was misplaced in 30 patients with burst fractures. Although the patients with oval-shaped canal were small the results are similar (5 burst fractures observed out of 6 patients). In the spine with a trefoil-shaped canal, the most frequent misplacement was observed in patients with listhesis (18 patients) also there were similar results in patients with burst fractures (10 patients).

The mean TLICS score of 136 patients with trauma was 5.42.

When the causes of screw failure were examined, the inclination of the rod was incorrect in four patients (1.9%). Also, four patients (1.9%) had a patient-induced accident and one patient (0.5%) presented with sustained osteoporotic collapse.

Other side effects were observed, including one patient with late infection; two patients underwent stent implantation due to aorta wall reinforcement after aortic wall contact; one patient with late gastrointestinal hemorrhage resulting in death, which was due to steroid treatment; and one patient developed global infarction and death after surgery.

■ DISCUSSION

Despite the necessity and widespread use of spinal fixation, side effects are possible. Among the side effects of TPTF, screw misplacement is most common (1,8-12,25,27,29).

Considering the data obtained in this study, when patients are required to undergo TPTF, we should first question our decision and evaluate the suitability of the decided procedure. We can see the evidence from screw failure reasons and other side effects. My dissertation, which was the source of the present article, discusses in detail when each disease requires a suitable stabilization procedure (17). According to our data, one of the important points at this stage is to benefit from the intervention made to patients who are fully paralyzed in the early period. Masked intact tissue could be parting. Intervention should be considered.

In practice, no evaluation is made except for pedicle diameter and angle. According to the data evaluated in this paper, the structure of the canal is important. As we understand from facts and basic medical knowledge, each structure takes shape around the spinal cord with the genetic and the environmental conditions of its surrounding tissues. We believe that an understanding of the shape of the spinal canal in which the nerve tissue is located will provide a more holistic approach to avoid nerve damage and improve nerve tissue which is the main goal in surgical procedures. Our data clearly supports this. The round-shaped canal, which is common in the thoracic spine, is frequently encountered in medial screw delivery, as well as possibly entering from the laterally to avoid the spinal cord causes screw out. The spinal cord is closer to the pedicles in the round-shaped canal. Again, with this type of canal, patients have weaker pedicles and pedicle violation occurs more frequently. This was thought to be the reason for the close rates of medial and lateral delivery. Therefore, the calculation should be made in the middle area where the pedicle is the thinnest. Again, to avoid the thoracic aorta, the structure of the spine body is also important. Although there were no statistically significant differences owing to the small number of cases of triangular vertebrae body shape were associated with a high misplacement. Due to the shape, especially in the thorax, the screw is likely to come out from the front face of the vertebral body and cause major vessel damage. For the same reason, since the pedicle angle is more inclined from lateral to medial in patients with such a spinal body, the lateral protrusion is common. In the lumbar spine, misplacement was more common in the trefoil-shaped canal, which results in medial delivery. The reason for this is that the pedicle entry points of the spine are lateral with this canal structure. This was thought to be due to the medial placement of the entrance site, especially at the lower levels within the contribution of the iliac wing and low-angle delivery. It is thought that lateral delivery, although it is a small one because of its shape, it couldn't be adjusted and that it could not be sufficiently angulated due to the presence of neighboring structures. According to the data long screw delivery situation also encountered here. The reason being there is a difference in length caused by shape could not be detected correctly pre-operatively and the fluoroscopy method used in the

cases could not give three dimensions. After all these and calculating the screw length with the appropriate entry point, the angle of the spinal body and pedicle in the natural position was in accordance with the canal shape. Reliable markings that can be used to insert thoracic pedicle screws are not present in most spines. Unfortunately, there is a significant variation in the location, size, and angle of the pedicles between individuals as well as different levels in the same individual (26). Pedicle cortex violation is relatively high at blind referencing. In a series, the pedicle violation rate was 47% (4). Special targeting devices have been produced but have not undergone significant scrutiny. Fluoroscopy is very helpful. Fluoroscopy should be used to show the site of entry, although there are limitations due to the presence of surrounding tissues. The use of frameless stereotactic techniques has improved screw placement in various series (3,18,23,28). Another technique directly observed the pedicle for thoracic placement by small laminotomy, which has been suggested to improve pedicle screw placement. Nerve conduction studies, especially freelance work and evoked electromyography (EMG), have been widely advocated for accurate and safe placement of pedicle screws. However, the evidence did not have better results than patients who underwent ordinary nerve conduction studies (24). The use of stereotaxic systems may increase accuracy, but results have not improved (22). The surgeon must choose the most compatible technique and master this technique accordingly. The holes are made to the desired size using expanders. Pedicle walls should be checked with a probe after each expansion to verify the integrity of the cortical bone. Screws known to penetrate the medial wall of the pedicle should be repositioned immediately. It is known that screws that are misplaced by up to 4 mm medial to the lumbar pedicle cortex can continue their life without causing nerve damage since this is considered as the "safe zone" (13). Nevzati et al. reported pedicle fracture in 20% of 1236 pedicle screws implanted with fluoroscopy; 10,9% were small (<2 mm), 5.3% were moderate (2.1-4 mm), and 3.8% were severe (>4 mm) (20). This safe zone may not be present in the thorax (26). In patients with fractures in the medial cortex, damage may occur if the bone fragment is broken by the screw or if the misplaced screw itself occupies the foramen or canal, in turn causing nerve compression. If possible, the screws should be placed at the lateral-medial angle, which is beneficial to increase the effects of triangulation and parallelogram on screw stripping (5). The length of the screw should be chosen such that it should reach the front third of the spinal body. A significant benefit is not achieved with an excessively long screw. With all thoracolumbar fixation systems, the involvement of the anterior cortex can encounter the related level of vascular, nerve or organ damage. Amaral et al. showed that 25% of the 2229 pedicle screws carry a risk for organs and 0.6% reported a compressed aortic wall in the scoliotic spine (2). Although the risk of damage to organs by the screw was not investigated in our study articular wall compression was observed in 0.14% of cases. Screw delivery must be done at once. The screws must be confirmed in the operation room by any means. The screw that is positioned incorrectly must be corrected. Laminectomy should be performed only in cases where canal compression

cannot be corrected without laminectomy and the pedicle cannot be found, such as in cases of tumor or burst fracture. In the case of laminectomy, the dura should be kept closed and protected. In the present study, laminectomy had no effect on healing. Besides, more serious side effects are seen in patients who received laminectomy after infection. Also, dural rupture can be seen. In the case of dural rupture, it should be sutured; and if not, the tissue should be supported using adhesives. Ligamentotaxis was found to be beneficial if the posterior longitudinal ligament was intact and biomechanical stability could be provided. The connection should be completed with the least formed rod that is suitable for the anatomical position at the appropriate torque values and strengthened with cross-links in suitable diseases.

Management of complications is also of utmost importance. If there is no possibility to check the screw locations in the operating room, it may not be necessary to replace the misplaced screws, especially in patients without neurological deficit or material-related pain after surgery. The situation should be evaluated between patient and surgeon, and a joint decision should be made. When there is evidence of insufficiency (e.g., broken rods or screws), legal considerations may cause the surgeons' guide to remove the device. After thoracic or lumbar fixation, the decision to remove the equipment in patients with permanent back pain should be made on an individual basis.

■ CONCLUSION

The present study shows that laminectomy is not beneficial for except for selected patients, and if biomechanical anatomy is allowing and applied correctly, ligamentotaxis is beneficial for healing. A connection was deduced between the canal structure and incorrect screw delivery. In patients with round-shaped canal screws sent frequently medially and with a close-ratio sent laterally. Patients with a trefoil-shaped canal, screws are most frequently long with a close-ratio sent laterally with half of it sent medially. Since the number of oval canal structures was low, no connection was found.

Considering the findings of the present study, it was concluded that the spinal structure formed around the canal should be taken as the basis to evaluate the appropriate position of screw placement in TPTF applications to protect the spinal cord.

■ ACKNOWLEDGMENTS

Preparation for publication of this article is partly supported by the Turkish Neurosurgical Society.

Special thanks for my bellowed wife Damla KAYA unquestionable support. Also, I am grateful to Prof. Dr. Özen Karadağ for precious pieces of advice about dissertation and life.

■ REFERENCES

1. An HS, Lynch K, Toth J: Prospective comparison of autograft vs allograft for adult posterolateral lumbar spine fusion: Differences among freeze-dried, frozen and mixed grafts. *J Spinal Disorders* 8:131-135, 1995
2. Amaral TD, Wollowick AL, Kulkarni PM, Thornhill B, Sugarman E, Horn JJ, Sarwahi V: How commonly are pedicle screws adjacent to the great vessels or viscera? A study of 2,295 pedicle screws. Presented at the 46th Annual Meeting of the Scoliosis Research Society, 2011
3. Amiot LP, Lang K, Putzier M, Zippel H, Labelle H: Comparative results between conventional and computer-assisted pedicle screw installation in the thoracic, lumbar, and sacral spine. *Spine (Phila Pa 1976)* 25:606-614, 2000
4. Belmont PJ Jr, Klemme WR, Dhawan A, Polly DW Jr: In vivo accuracy of thoracic pedicle screws. *Spine (Phila Pa 1976)* 26:2340-2346, 2001
5. Benzel EC: Biomechanics of spine stabilization: Principles and clinical practice. New York: McGraw-Hill, 1995:156,157
6. Benzel EC, Lancon J, Kesterson L, Hadden T: Cervical laminectomy and dentate ligament section for cervical spondylotic myelopathy. *J Spinal Disord* 4:286-295, 1991
7. Bozkurt H, Kaya İ, Oztoprak B: The role of triangular vertebral canal shape in surgical management of patients with lumbar spinal stenosis: A cross-sectional study. *Turk Neurosurg*, 2017 (Online ahead of print)
8. Chozick BS, Toselli R: Complications of spinal instrumentation. In: Benzel EC, (ed). *Neurosurgical topics: Spinal instrumentation*. Park Ridge, IL: American Association of Neurological Surgeons, 1994:257-274
9. Davne SH, Myers DL: Complications of lumbar spinal fusion with transpedicular instrumentation. *Spine (Phila Pa 1976)* 17:S184-S189, 1992
10. Esses SI, Sachs BL, Dreyzin V: Complications associated with the technique of pedicle screw fixation: A selected survey of ABS members. *Spine* 18:2231-2238, 1993
11. Farber GL, Place HM, Mazur RA, Jones DE, Damiano TR: Accuracy of pedicle screw placement in lumbar fusions by plain radiographs and computed tomography. *Spine (Phila Pa 1976)* 20:1494-1499, 1995
12. Frazier DD, Lipson SJ, Fossel AH, Katz JN: Associations between spinal deformity and outcomes after decompression for spinal stenosis. *Spine* 22:2025-2029, 1997
13. Gertzbein SD, Robbins SE: Accuracy of pedicle screw placement in vivo. *Spine (Phila Pa 1976)* 15:11-14, 1990
14. Hilibrand AS, Rand N: Degenerative lumbar stenosis: Diagnosis and management. *J Am Acta Orthop Surg* 7:239-249, 1999
15. Hirabayashi K, Miyakawa J, Satomi K, Maruyama T, Wakano K: Operative results and postoperative progression of ossification among patients with ossification of cervical posterior longitudinal ligament. *Spine* 6:354-364, 1981
16. Jamjoom A, Williams C, Cummins B: The treatment of spondylotic cervical myelopathy by multiple subtotal vertebrectomy and fusion. *Br J Neurosurg* 5:249-255, 1991

17. Kaya İ: The relationship between transpedicular stabilization with spinal canal type. Published doctoral dissertation, Cumhuriyet University Medical Faculty, Turkey, 2019
18. Kim KD, Johnson PJ, Bloch BS, Masciopinto JE: Computer assisted thoracic pedicle screw placement: An in vitro feasibility study. *Spine (Phila Pa 1976)* 26:360-364, 2001
19. Melancia JL, Francisco AF, Antunes JL: Spinal stenosis. *Handb Clin Neurol* 119:541-549, 2014
20. Nevzati E, Marbacher S, Soleman J, Perrig WN, Diepers M, Khamis A, Fandino J: Accuracy of pedicle screw placement in the thoracic and lumbosacral spine using a conventional intraoperative fluoroscopy guided technique: A national neurosurgical education and training center analysis of 1236 consecutive screws. *World Neurosurg* 82:866-871, 2014
21. Patel CK, Truumees E: Spinal stenosis: Pathophysiology, clinical diagnosis, and differential diagnosis. In: Garfin SR, Eismont FJ, Bell GR, Fischgrund JS, Bono CM (eds), Rothman-Simeone and Herkowitz's *The Spine* seventh edition. Philadelphia, Pa: Elsevier Saunders, 2018:1019-1032
22. Puvanesarajah V, Liauw JA, Lo SF, Lina IA, Witham TF: Techniques and accuracy of thoracolumbar pedicle screw placement. *World J Orthop* 5:112-123, 2014
23. Resnick DK: Comparison between virtual fluoroscopy and fluoroscopy for the placement of lumbar pedicle screws. *J Spinal Disord* 16:254-260, 2003
24. Resnick DK: Updated guidelines for the management of acute cervical spine and spinal cord injury. *Neurosurgery*, 72 Suppl 2:1, 2013
25. Roy-Camille R, Saillant G, Mazel C: Internal fixation of the lumbar spine with pedicle screw plating. *Clin Orthop Relat Res* 203:7-17, 1986
26. Ugur HC, Attar A, Uz A, Tekdemir I, Egemen N, Genç Y: Thoracic pedicle: Surgical anatomic evaluation and relations. *J Spinal Disord* 14:39-45, 2001
27. Vaccaro AR, Garfin SR: Degenerative lumbar spondylolisthesis with spinal stenosis: A prospective study comparing decompression and decompression with intertransverse processes arthrodesis. *A Critical Analysis Spine* 22:368-369, 1997.
28. Youkilis AS, Quint DJ, McGillicuddy JE, Papadopoulos SM: Stereotactic navigation for placement of pedicle screws in the thoracic spine. *Neurosurgery* 48:771-778, 2001
29. Zdeblick TA, Hanley EN Jr, Sonntag VK, Andersson GB, Boden SD, Fraser RD, Garfin SR, Goel VK, Katz JN, Pope MH: Indications for lumbar spinal fusion. Introduction. Focus issue meeting on fusion. *Spine* 20:124-125, 1995