

Original Investigation

The Vasorelaxant and Neuroprotective Effects of Mildronate in A Rabbit Subarachnoid Hemorrhage Model

Muhammed Taha ESER¹, Pinar KURU BEKTASOGLU^{2,3}, Bora GURER², Huseyin BOZKURT⁴, Mehmet SORAR¹, Ozden Caglar OZTURK², Ata Turker ARIKOK⁵, Hayri KERTMEN¹

¹Turkish Ministry of Health, University of Health Sciences, Diskapi Education and Research Hospital, Department of Neurosurgery, Ankara, Turkey

²Turkish Ministry of Health, University of Health Sciences, Fatih Sultan Mehmet Education and Research Hospital, Department of Neurosurgery, Istanbul, Turkey

³Marmara University School of Medicine, Department of Physiology, Istanbul, Turkey

⁴Cumhuriyet University School of Medicine, Department of Neurosurgery, Sivas, Turkey

⁵Turkish Ministry of Health, University of Health Sciences, Diskapi Education and Research Hospital, Department of Pathology, Ankara, Turkey

Corresponding author: Pinar KURU BEKTASOGLU ✉ pnr.kuru@gmail.com

ABSTRACT

AIM: To investigate the effects of an anti-ischemic agent, mildronate, on subarachnoid hemorrhage-induced vasospasm.

MATERIAL and METHODS: Rabbits were randomly divided into four groups: control, subarachnoid hemorrhage (SAH), vehicle, and mildronate (n = 8 animals per group). In the treatment group, 200 mg/kg of mildronate were intraperitoneally administered 5 min after the procedure and continued for 3 days as daily administrations of the same dose. At the end of the third day, the cerebrum, cerebellum, and brain stem were perfused, fixated, and removed for histopathological examination. Tissues were examined for arterial wall thickness, luminal area, and hippocampal neuronal degeneration.

RESULTS: Mildronate group showed significantly increased luminal area and reduced wall thickness of the basilar artery compared with the subarachnoid hemorrhage group. In addition, the hippocampal cell degeneration score was significantly lower in the mildronate group than in the SAH and vehicle groups.

CONCLUSION: These results show that mildronate exerts protective effects against SAH-induced vasospasm and secondary neural injury.

KEYWORDS: Anti-ischemic, Mildronate, Neuroprotective, Rabbit, Subarachnoid hemorrhage





INTRODUCTION





Cerebral ischemia is the most important cause of mortality and morbidity following subarachnoid hemorrhage (SAH)-related vasospasm (2,13). Despite numerous studies investigating treatments for SAH-induced vasospasm, effective prevention and therapy are still lacking.

Mildronate (2,2,2 triethylhydrazinium, Quaterine, Meldonium, MET-88) is an anti-ischemic drug first produced in Lithuania in

the early 1980s (46). The drug was firstly used as a carnitine biosynthesis inhibitor to inhibit fatty acid oxidation thus reducing the production of cytotoxic products and blocking the high oxygen use in ischemic conditions (38).

In addition to carnitine biosynthesis inhibition, mildronate inhibits carnitine acyltransferase and attenuates carnitine incorporation into the mitochondria (32). Collectively, mildronate prevents the accumulation of ischemic precursors and toxic acylcarnitine products, by inhibiting carnitine

Muhammed Taha ESER  : 0000-0002-1391-4341 Huseyin BOZKURT
Pinar KURU BEKTASOGLU  : 0000-0001-9889-9955 Mehmet SORAR
Bora GURER  : 0000-0003-1500-6184 Ozden Caglar OZTURK  : 0000-0003-3964-1895

 : 0000-0001-6432-5371 Ata Turker ARIKOK  : 0000-0003-4256-3779
 : 0000-0002-6933-7627 Hayri KERTMEN  : 0000-0002-7113-9830

biosynthesis, transport, and reabsorption, thereby directing cell metabolism to glucose consumption, which protects it from the ischemic state (6,30,35).

Mildronate reportedly inhibits vasoconstriction induced by nitric oxide synthase (NOS) inhibitors (8,38). Thus, it is thought to exhibit a vasodilator effect through nitric oxide (NO)-dependent mechanisms. An increase in NO levels is observed both in the cerebral cortex and the cerebellum 30 min after mildronate injection (9,36). Moreover, mildronate administration reduces the hydroxylation of gamma-butyrobetaine (GBB), thereby increasing GBB content. Cholinomimetic GBB esters induce a higher release of GBB at the cell level, activating endothelial NOS (eNOS) through the acetylcholine receptors of endothelial cells. Increased eNOS activity increases the NO level, thereby leading to vasodilatation (8,38).

Although mildronate is a well-known anti-ischemic vasodilator, its effects on SAH-dependent vasospasm have not been studied. To the best of our knowledge, the present study is the first to investigate the effects of mildronate on post-SAH-induced vasospasm and neuronal degeneration.

■ MATERIAL and METHODS

Experimental Groups

Animal care and all experiments were conducted according to the European Parliament and Council directive 2010/63/EU of September 22, 2010 with regard to the protection of animals for experimental use. All experimental procedures were reviewed and approved by the Turkish Republic, Ministry of Health Ankara Education and Research Hospital Animal Experiments Local Ethics Committee, with resolution number 474 at the session on 05/26/2017.

Subjects were 32 adult male New Zealand white rabbits weighting 2800–3100 g. During the experiment, all subjects were kept in a room with controlled temperature (18°C–21°C) and light-dark cycle (12/12h). Animals were fed ad libitum with standard diet. For the experiment, subjects were divided into four groups:

Group 1 (Control Group; n= 8): Group without SAH. In this group, cisterna magna puncture was performed as described below. Briefly, 1 ml/kg of physiological saline (0.9% NaCl) was administered into the cisterna magna, following evacuation of the same volume of cerebrospinal fluid (CSF).

Group 2 (SAH Group; n= 8): SAH was induced as previously described (15,17,18). No treatment was administered.

Group 3 (Vehicle Group; n= 8): SAH was induced as previously described. Briefly, 1 ml/kg of physiological saline was intraperitoneally administered 5 min after the onset of SAH. The treatment was continued for 3 days, with one daily administration of the same dose.

Group 4 (Mildronate Group; n= 8): SAH was induced as previously described, after which mildronate (NBM Pharma S.R.O., Slovenia) was intraperitoneally administered at a dose of 200 mg/kg 5 min after the onset of SAH. The treatment was continued for 3 days, with one daily administration of

the same dose. The doses of mildronate used were based on previous studies (22,28,40,42,44).

Anesthesia and Surgical Procedure

The animals were anesthetized via intramuscular administration of 70 mg/kg ketamine (Ketalar, Parke Davis Eczacıbasi, Turkey) and 5 mg/kg xylazine (Rompun, Bayer, Turkey). Throughout the procedures all animals breathed spontaneously. During the procedures, PO₂ and PCO₂ were monitored by collecting arterial blood samples from each animal's catheterized ear arteries. Animals with PO₂ higher than 70 mmHg and PCO₂ lower than 40 mmHg were included in the study. Heart rate and arterial blood pressure were measured using an ear arterial catheter. Core body temperature was rectally monitored and maintained at 37°C ± 0.5°C using a heater.

Cerebral Vasospasm Model

The cerebral vasospasm model was prepared as previously described (14). Briefly, the atlanto-occipital membrane was exposed, and 1 ml/kg of CSF was withdrawn from the cisterna magna. An equal volume of fresh, non-heparinized autologous arterial blood was injected into the cisterna magna within 2 min. Subsequently, the animals were placed in a head-down position and, after recovery, were left inside their cages for the establishment of cerebral vasospasm.

Perfusion-Fixation Procedure

All animals were sacrificed by perfusion-fixation 72 h after procedures as previously described (14). Thoracotomy was performed under anesthesia. The left ventricle was cannulated, the right atrium was widely opened and the descending thoracic aorta was clamped. After perfusion with 300 ml of physiological saline, a fixative solution was perfused (10% formaldehyde, 200 ml), after which the brains were removed and stored in formaldehyde solution at 4°C, overnight.

Histological Morphometric Analysis of the Basilar Artery

Each brainstem specimen was embedded in paraffin as previously described (14). The entire basilar artery was sectioned into five segments, each measuring 2 mm in length, and stained with hematoxylin-eosin (H&E). The morphometric measurements on all basilar artery segments were performed using the BAB- Bs200ProP Image Processing and Analysis System (Ankara, Turkey).

The area within the internal elastic lamina was considered as the luminal area (LA). The arterial LA corresponded to the average of the five sections. For each vessel, mean ± standard deviation (SD) value obtained from each artery was used as the final value. The distance between the lumen and the outer part of the muscle layer was accepted as the measure of arterial wall thickness (AWT). In impaired areas, an additional measure was taken from the distance between the internal elastic membrane and the external border of the muscle layer. The AWT for each basilar artery segment was obtained through the average of four-point measurements. Mean ± SD value obtained from each artery was used as the final value for a particular vessel. All measurements were repeated twice for each artery, in a blind fashion by two pathologists, and the final

Table I: Intra- and Inter-Class Correlation Coefficients Regarding Luminal Area and Wall Thickness Measurement

	LA		AWT	
	ICC	95% CI	ICC	95% CI
Intra-observer				
1 st observer	0.994	0.988-0.997	0.997	0.994-0.999
2 nd observer	0.974	0.949-0.987	0.998	0.996-0.999
Inter-observer				
1 st measurement	0.987	0.974-0.994	0.997	0.995-0.999
2 nd measurement	0.997	0.994-0.999	0.999	0.998-1.000

AWT: Arterial wall thickness, **CI:** Confidence interval, **ICC:** Intra-class correlation coefficient, **LA:** Luminal area.

values corresponded to the average of these measurements (10,14,17,18). The levels of inter- and intra-observer reliability are presented in Table I.

Evaluation of Hippocampal Degeneration

The paraffin embedded hippocampal samples were cut into 4 to 6 µm thick slices and stained with H&E stain. The following morphological findings of neuronal degeneration were evaluated under light microscopy: neuronal shrinkage, hyperchromasia, and nuclear pyknosis.

The presence and extent of neuronal degeneration were demonstrated by semi-quantitative scoring of the CA1, CA3, and dentate gyrus (5, 19) as follows: 1 = normal appearance, 2 = few degenerated neurons among normal neurons, 3 = large number of degenerated neurons with scattered normal neurons, and 4 = complete degeneration without residual normal neurons. All three regions of the hippocampus were assessed and the overall “degeneration score” was obtained by summing the scores of the three regions. Mean values were used for statistical analysis.

Statistical Analysis

Data analysis was performed using the IBM SPSS Statistics version 17.0 (IBM Corporation, Armonk, NY, USA). The distribution of continuous variables was investigated using the Shapiro-Wilk test. The Levene test was used to evaluate variance homogeneity. Results are presented as mean ± SD or median (25th–75th) percentiles, as applicable. For normally distributed continuous data, mean differences among groups were compared using One-Way ANOVA. For non-normally distributed continuous data and ordinal data, the Kruskal Wallis test was used. Statistically significant results from One-Way ANOVA or Kruskal Wallis tests were further analyzed using post-hoc Tukey HSD or Conover's multiple comparison tests. Intra-class correlation coefficients for basilar artery cross-sectional area and AWT were calculated to determine the level of inter- and intra-observer reliability. A level of $p < 0.05$ was considered statistically significant.

RESULTS

Basilar Artery Morphometric Analysis

The mean baseline arterial LA measurements of the control group were $268,568.8 \pm 81,492.1 \mu\text{m}^2$. The average baseline arterial LA value in the SAH and vehicle groups was $113,930.1 \pm 17,376.6 \mu\text{m}^2$ and $119,669.8 \pm 43,196.9 \mu\text{m}^2$, respectively, both significantly lower than the control group ($p < 0.001$ for both). No significant difference was found between the SAH and the vehicle groups ($p = 0.928$). The LA diameter was reduced after SAH, which is consistent with the occurrence of vasospasm. In the mildronate group, mean baseline arterial LA was $229,447.4 \pm 48,750 \mu\text{m}^2$, which was significantly higher than in the SAH group ($p < 0.001$). This result suggests that mildronate mitigates the decrease in vessel areas caused by vasospasm (Figure 1).

Mean AWT was $17.1 \pm 2.02 \mu\text{m}$ in the control group, $43.5 \pm 4.4 \mu\text{m}$ in the SAH group and $42.8 \pm 9.3 \mu\text{m}$ in the vehicle group. Both the SAH and vehicle groups had significantly higher AWT measurements as compared to the control group ($p < 0.001$ for both comparisons). No significant difference was found between the SAH and vehicle groups in terms of mean AWT ($p = 0.686$). This result suggests that vasospasm increases mean AWT.

Mean basilar artery AWT for the mildronate group was $26.8 \pm 4.3 \mu\text{m}$, which is significantly lower than that of the SAH group ($p < 0.001$) (Figure 2). This indicates that vasospasm arising after SAH, increases the basilar artery AWT, which is inhibited by mildronate treatment. Basilar artery median LA and AWT data are summarized in the Table II.

Pathological Examination of the Hippocampus

Light microscope examination of the control group revealed morphologically normal hippocampal CA1, CA3, and dentate gyrus samples (Figure 3A-C). Degeneration was observed in most hippocampal areas of both the SAH and vehicle groups (Figure 4A-C). The CA1, CA3, and dentate gyrus of the mildronate group showed a higher number of preserved neurons and a lower number of degenerated neurons (Figure 5A-C).

Table II: Mean Basilar Artery Luminal Areas and Wall Thickness Levels

	LA (μm ²)	AWT (μm)
Control	291942.7 (201508.2-334350.6) ^{a,b}	16.8 (15.8-18.9) ^{a,b,e}
SAH	115455.3 (99852.7-127609.9) ^{a,c}	44.7 (40.6-45.8) ^{a,c}
Vehicle	105051.4 (87200.4-141805.8) ^{b,d}	39.5 (37.2-52.9) ^{b,d}
Mildronate	230962.9 (181218.7-256334.8) ^{c,d}	27.8 (22.0-29.8) ^{c,d,e}
Statistics	χ ² =20.190, p<0.001 [†]	χ ² =25.969, p<0.001 [†]

Data were shown as median (25th-75th) percentiles, **AWT**: Arterial wall thickness, **LA**: Luminal area, **SAH**: Subarachnoid hemorrhage. [†] Kruskal Wallis test, **a**: Control vs SAH (p<0.001), **b**: Control vs Vehicle (p<0.001), **c**: SAH vs Mildronate (p<0.001), **d**: Vehicle vs Mildronate (p<0.001), **e**: Control vs Mildronate (p=0.006).

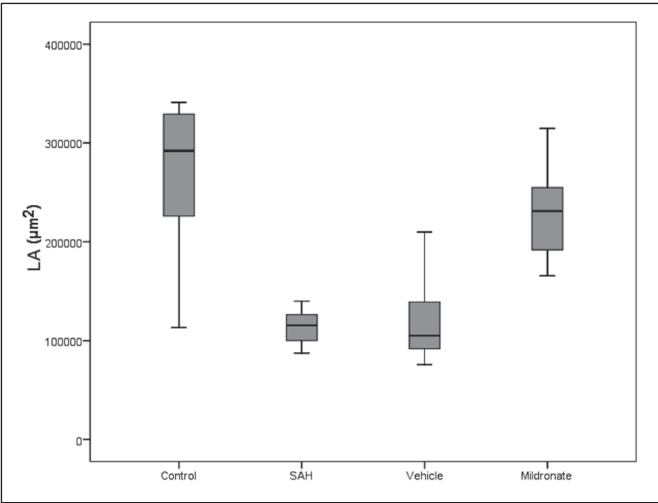


Figure 1: The horizontal lines in the middle of each box indicates the median basilar artery luminal area levels, while the top and bottom borders of the box mark the 25th and 75th percentiles, respectively. The whiskers above and below the box mark indicate the maximum and minimum levels. **LA**: Luminal area, **SAH**: subarachnoid hemorrhage.

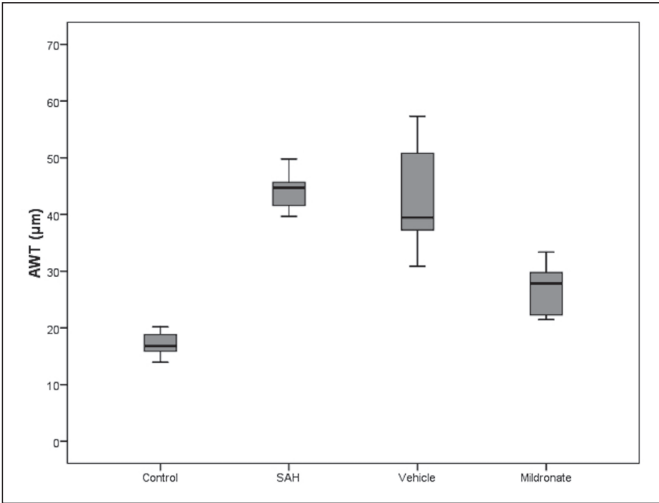


Figure 2: The horizontal lines in the middle of each box indicate the median arterial wall thickness levels, while the top and bottom borders of the box mark the 25th and 75th percentiles, respectively. The whiskers above and below the box mark indicate the maximum and minimum levels. **AWT**: arterial wall thickness, **SAH**: subarachnoid hemorrhage.

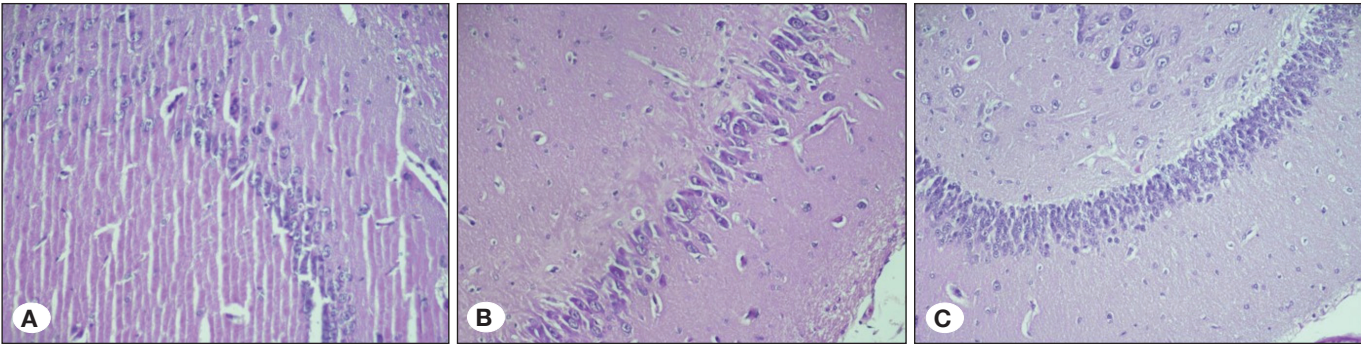


Figure 3: Photomicrographs showing the normal appearing slices from the CA1 (**A**), CA3 (**B**) and the dentate gyrus (**C**) of the hippocampus of the control group (H&E, 20X obj.).

Mean degeneration scores were 3.5 ± 0.5 for the control group, 11.1 ± 1.1 for the SAH group, and 10.8 ± 0.8 for the vehicle group. This difference was significant between the control and SAH groups and between the control and vehicle groups (both $p < 0.001$), indicating that post-SAH hippocampal CA1, CA3, and dentate gyrus neurons show further destruction and degeneration. In the mildronate group, mean degeneration score was 7.3 ± 0.5 , which differed significantly from the SAH group ($p = 0.006$), indicating that mildronate prevents post-SAH neuronal degeneration. Taken together, these results show that mildronate is a neuroprotective agent. Mean degeneration scores are summarized in the Table III.

DISCUSSION

Aneurysmal SAH represents approximately 5% of all strokes.

The young population is relatively affected, and the prognosis is generally poor (3). Overall mortality rates are 32%–67%, with permanent brain damage observed in 10%–20% patients (29), and one third of the surviving patients live with severe disability (15). A previous study examining the quality of life in patients with SAH reported that only 19% returned to the pre-disease status (16). As a result, SAH is a catastrophic condition, and only a few patients are discharged with good outcomes. Despite numerous developments in the diagnostic methods, neurosurgical procedures, anesthetic techniques, and available pre- and postoperative patient care, the results of aneurysmal SAH remain far below satisfactory levels (11).

Cerebral ischemia and delayed ischemic injury after SAH occur in almost 30% of the patients owing to vasospasm occurring 4–10 days after bleeding (4,7). An indolent clinical course

Table III: Pathological Examinations of the Hippocampus Relevant to the Study Groups

	Control	SAH	Vehicle	Mildronate	Statistics
CA 1	1 (1-1) ^{a,b,c}	4 (4-4) ^{a,d}	4 (4-4) ^{b,e}	2 (2-3) ^{c,d,e}	$\chi^2=27.810$, $p < 0.001$ [†]
CA 3	1 (1-1) ^{a,b,c}	3.5 (3-4) ^{a,d}	3.5 (3-4) ^{b,e}	3 (2-3) ^{c,d,e}	$\chi^2=22.149$, $p < 0.001$ [†]
Dentate gyrus	1 (1-1.75) ^{a,b,c}	4 (3.25-4) ^{a,d}	4 (3-4) ^{b,e}	2.5 (2-3) ^{c,d,e}	$\chi^2=24.074$, $p < 0.001$ [†]
Mean deg. score	3.5 (3-4) ^{a,b,c}	11.5 (10.25-12) ^{a,d}	11 (10-11.75) ^{b,e}	7 (7-8) ^{c,d,e}	$\chi^2=26.838$, $p < 0.001$ [†]

Data were shown as median (25th–75th) percentiles, [†] Kruskal Wallis test, **a:** Control vs SAH ($p < 0.001$), **b:** Control vs Vehicle ($p < 0.001$), **c:** Control vs Mildronate ($p < 0.05$), **d:** SAH vs Mildronate ($p < 0.01$), **e:** Vehicle vs Mildronate ($p < 0.05$). **SAH:** Subarachnoid hemorrhage.

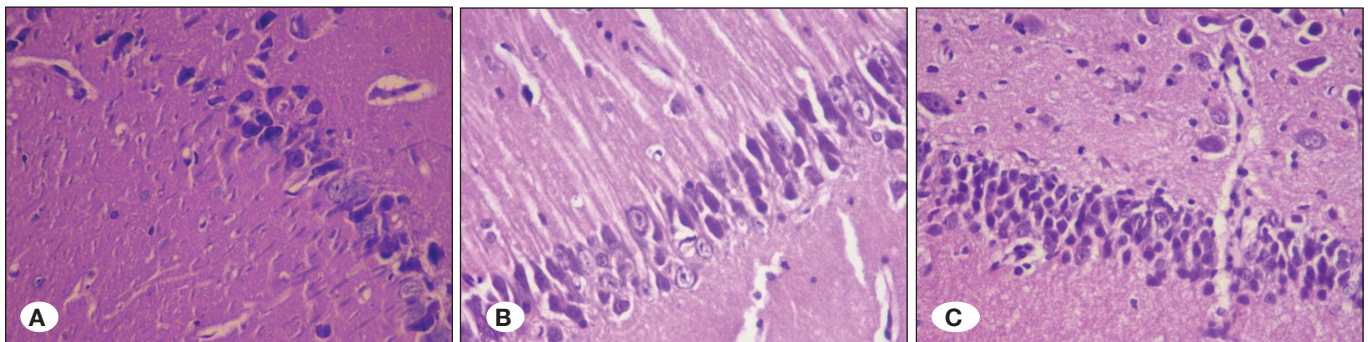


Figure 4: Photomicrographs from the SAH group showing completely degenerated neurons in the CA1 (A), CA3 (B) and the dentate gyrus (C) of the hippocampus (H&E, 20X obj.).

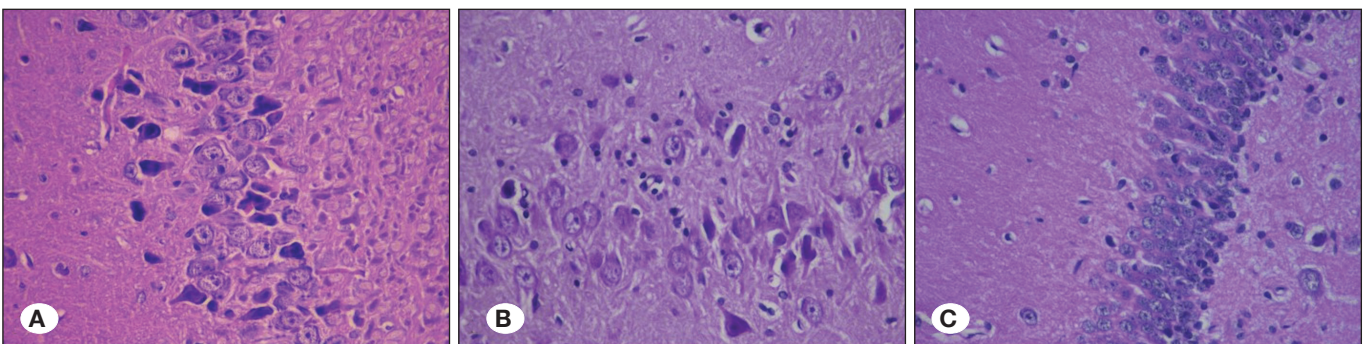


Figure 5: Photomicrographs from the mildronate group showing only mild to moderate degeneration of the neurons CA1 (A), CA3 (B) and the dentate gyrus (C) of the hippocampus (H&E, 20X obj.).

leads to focal neurological deficits and loss of consciousness. Although cerebral ischemia can be reversible, its progressive course may result in cerebral infarction, leading to serious disability and death (29). The main limitation is the lack of effective treatment. Although pharmacological agents have been experimentally tested with relative success, in clinical studies their success is limited (12).

The development of specific pharmacological treatments aims to prevent ischemia secondary to SAH. The current clinical practice is limited to increasing systolic blood pressure to induce hypertension, fluid replacement with isotonic crystalloid solutions, and preserving euvoolemia (4). The 3-H treatment previously used has now been replaced by the regimen of euvolemic hypertension (1,4). In addition, nimodipine, a calcium channel blocker, is administered to all patients. The role of oral nimodipine in preventing DCI has been extensively investigated and is the subject of many reviews (41). Although several studies suggest that nimodipine decreases the incidence of severe neurological deficit, it has no effect on the incidence and severity of angiographic vasospasm (26,27).

Several treatment methods aiming to prevent and/or eliminate cerebral vasospasm after SAH have been investigated, including the use of calcium channel blockers, statins (23), endothelial receptor antagonists (24), magnesium (45), erythropoietin (43), tirilizade (20), and glyburide (34). Despite these efforts, almost no substances were found to be clinically useful. Therefore, studies on the treatment of post-SAH vasospasm remain an important area of interest and field of research.

Mildronate is an anti-ischemic drug and a carnitine biosynthesis inhibitor designed to inhibit cytotoxic degradation products that result from fatty acid β -oxidation and lead to ischemic tissue (46). It is widely used to treat ischemic heart disease in many countries, and its effects are due to the inhibition of GBB hydroxylase and the reduction of fatty acid β -oxidation (6). Its efficacy as a new generation cardioprotective agent has been previously demonstrated (31). Mildronate reduces the level of carnitine. Carnitine enables the transport of long chain fatty acids, which are required for mitochondria, into the mitochondrial matrix for β -oxidation. In addition, it regulates the glycolytic processes of the activity of carbohydrates and pyruvate dehydrogenase by controlling the ratio of intramitochondrial acetyl-coenzyme/coenzyme (21).

Mildronate inhibits the biosynthesis of L-carnitine by increasing the amount of GBB, competing with carnitine in the kidney and reducing reabsorption. As a result, fatty acid oxidation is prevented and glucose availability as an energy substructure is ensured, thereby positively affecting the energy metabolism (21,37). In healthy subjects, mildronate administration reduces the levels of plasma carnitine without serious side effects (21). These findings indicate that mildronate works like a train on the mitochondria, adapting to the cell's fatty acid flow and activating glucose oxidation. Thus, in ischemic conditions, the cells adapt to glucose oxidation to produce energy (47).

Similarly, in the ischemic brain, there is a deterioration of the oxygen supply-demand balance. Mildronate treatment reduces brain energy requirements and increases cerebral

blood flow (47). For acute ischemic conditions, mildronate appears to be an excellent candidate to prevent the use of fatty acids by the brain and promote the use of glucose (38).

In addition to energy metabolism regulation, mildronate reduces the proteins susceptible to cellular apoptosis and the levels of inducible NOS (iNOS) and normalizes the levels of caspase-3. These apoptotic and inflammatory pathways, which are often associated with ischemic conditions, are abolished by the anti-apoptotic and anti-inflammatory effects of mildronate (28).

Mildronate exerts neuroprotective activity by restoring energy levels, inhibiting apoptosis, and preventing neuronal oxidative damage (46). Its neuroprotective efficacy has been demonstrated in several models of cerebral ischemic stroke (40). In addition, it is effective in the regulation of neurotransmitters such as glutamate (25).

Moreover, several studies have demonstrated that mildronate is a fast acting vasorelaxant (33,35). Mildronate activates secondary messenger systems via binding to membrane receptors, there by triggering DNA replication, methylation, and repair (33). Moreover, mildronate abrogates the efficacy of NOS inhibitors, leading to an increase in NO concentrations (8). Mildronate exerts vasodilator effects by raising NO-dependent pathways (38). The NO-dependent effects of mildronate on the endothelium cause vasodilatation (39).

The present study investigated the effects of mildronate on post-SAH-induced vasospasm owing to its well-known neuroprotective and vasodilator effects. Mildronate administration exerted a positive effect on post-SAH vasospasm and increased vascular LA. At the same time, a strong neuroprotective effect prevented hippocampal cell damage after SAH.

This study has some limitations. The results should be expanded by administering the drug at variable doses and different time intervals. The effects of mildronate should also be compared with those of nimodipine. In clinical settings, patients are often admitted to the hospital several hours after SAH. Therefore, the effects of mildronate on already established vasospasm should also be investigated. Further studies are required to conclude the effect of mildronate for both protection and reversion of SAH-induced vasospasm.

■ CONCLUSION

To the best of our knowledge, this is the first study reporting the protective effects of mildronate on vasospasm and its inhibitory effects on secondary neuronal damage after SAH. In addition, possible neuroprotective and vasodilator mechanisms have been discussed. Results show that mildronate administration prevents neuronal damage caused by post-SAH vasospasm. Therefore, mildronate may be used in treatment of SAH with evidence from advanced clinical studies.

■ ACKNOWLEDGEMENTS

Preparation for publication of this article is partly supported by Turkish Neurosurgical Society. The authors would like to thank Enago (www.enago.com) for the English language review.

■ REFERENCES

- Athar MK, Levine JM: Treatment options for cerebral vasospasm in aneurysmal subarachnoid hemorrhage. *Neurotherapeutics* 9: 37-43, 2012
- Barker FG, Heros RC: Clinical aspects of vasospasm. *Neurosurg Clin N Am* 1: 277-288, 1990
- Barry C, Turner RJ, Corrigan F, Vink R: New therapeutic approaches to subarachnoid hemorrhage. *Expert Opin Investig Drugs* 21: 845-859, 2012
- Connolly ES Jr, Rabinstein AA, Carhuapoma JR, Derdeyn CP, Dion J, Higashida RT, Hoh BL, Kirkness CJ, Naidech AM, Ogilvy CS, Patel AB, Thompson BG, Vespa P; American Heart Association Stroke Council; Council on Cardiovascular Radiology and Intervention; Council on Cardiovascular Nursing; Council on Cardiovascular Surgery and Anesthesia; Council on Clinical Cardiology: Guidelines for the management of aneurysmal subarachnoid hemorrhage: A guideline for healthcare professionals from the American Heart Association/American Stroke Association. *Stroke* 43: 1711-1737, 2012
- Cuthbert KD, Dyck JR: Malonyl-CoA decarboxylase is a major regulator of myocardial fatty acid oxidation. *Curr Hypertens Rep* 7: 407-411, 2005
- Dambrova M, Liepinsh E, Kalvinsh I: Mildronate: Cardioprotective action through carnitine-lowering effect. *Trends Cardiovasc Med* 12: 275-279, 2002
- Dankbaar JW, Rijdsdijk M, van der Schaaf IC, Velthuis BK, Wermer MJ, Rinkel GJ: Relationship between vasospasm, cerebral perfusion, and delayed cerebral ischemia after aneurysmal subarachnoid hemorrhage. *Neuroradiology* 51: 813-819, 2009
- Dzintare M, Baumanė L, Meirena D, Lauberte L, Kalvinsh I, Šjakste N: Involvement of nitric oxide production in the mildronate mechanism of action. *Pharmacol Rev Commun* 12: 163-170, 2002
- Enina G: Medicinal effects and indications to mildronate application in neuroangiologic practice. *Eksp Klin Farmakoter (Riga)* 19: 163-170, 1991
- Ergil J, Kertmen H, Sayin M, Gurer B, Yilmaz ER, Ozkan D, Arikok AT, Kanat MA, Sekerci Z: Vasoconstrictive effects of levobupivacaine on the basilar artery in the rabbit. *Arch Med Sci* 11: 654-659, 2015
- Grasso G, Alafaci C, Macdonald RL: Management of aneurysmal subarachnoid hemorrhage: State of the art and future perspectives. *Surg Neurol Int* 8: 11, 2017
- Grasso G, Buemi M, Giambartino F: The role of erythropoietin in aneurysmal subarachnoid haemorrhage: From bench to bedside. *Acta Neurochir* 120: 75-80, 2015
- Gurses L, Seckin H, Simsek S, Senel OO, Yigitkanli K, Ozturk E, Besalti O, Belen D, Bavbek M: Effects of raloxifene on cerebral vasospasm after experimental Subarachnoid hemorrhage in rabbits. *Surg Neurol* 72: 490-494, 2009
- Gurer B, Turkoglu E, Kertmen H, Karavelioglu E, Arikok AT, Sekerci Z: Attenuation of cerebral vasospasm and secondary injury by testosterone following experimental subarachnoid hemorrhage in rabbit. *Acta Neurochir* 156: 2111-2120, 2014
- Hop JW, Rinkel GJ, Algra A, van Gijn J: Case-fatality rates and functional outcome after subarachnoid hemorrhage: A systematic review. *Stroke* 28: 660-664, 1997
- Hop JW, Rinkel GJ, Algra A, van Gijn J: Quality of life in patients and partners after aneurysmal subarachnoid hemorrhage. *Stroke* 29: 798-804, 1998
- Kertmen H, Gurer B, Yilmaz ER, Arikok AT, Demirci A, Gokyaprak SM, Sekerci Z: The effect of thiocolchicoside on cerebral vasospasm following experimental subarachnoid hemorrhage in the rabbit. *Acta Neurochir* 154:1431-1436, 2012
- Kertmen H, Gurer B, Yilmaz ER, Arikok AT, Kanat MA, Erguder BI, Sekerci Z: The comparative effects of recombinant human erythropoietin and darbepoetin-alpha on cerebral vasospasm following experimental subarachnoid hemorrhage in the rabbit. *Acta Neurochir* 156: 951-962, 2014
- Kuhajda FP, Ronnett GV: Modulation of carnitine palmitoyl-transferase-1 for the treatment of obesity. *Curr Opin Investig Drugs* 8: 312-317, 2007
- Lanzino G, Kassell NF: Double-blind, randomized, vehicle-controlled study of high-dose tirilazad mesylate in women with aneurysmal subarachnoid hemorrhage. Part II. A cooperative study in North America. *J Neurosurg* 90: 1018-1024, 1999
- Liepinsh E, Konrade I, Skapare E, Pugovics O, Grinberga S, Kuka J, Kalvinsh I, Dambrova M: Mildronate treatment alters gamma-butyrobetaine and L-carnitine concentrations in healthy volunteers. *J Pharm Pharmacol* 63: 1195-1201, 2011
- Liepinsh E, Kuka J, Svalbe B, Vilskersts R, Skapare E, Cirule H, Pugovics O, Kalvinsh I, Dambrova M: Effects of long-term mildronate treatment on cardiac and liver functions in rats. *Basic Clin Pharmacol Toxicol* 105: 387-394, 2009
- Macdonald RL: Are statins to be STASHed in subarachnoid haemorrhage? *Lancet Neurol* 13: 639-641, 2014
- Macdonald RL, Higashida RT, Keller E, Mayer SA, Molyneux A, Raabe A, Vajkoczy P, Wanke I, Bach D, Frey A, Marr A, Roux S, Kassell N: Clazosentan, an endothelin receptor antagonist, in patients with aneurysmal subarachnoid haemorrhage undergoing surgical clipping: A randomised, double-blind, placebo-controlled phase 3 trial (CONSCIOUS-2). *Lancet Neurol* 10: 618-625, 2011
- Makrecka M, Svalbe B, Volska K, Sevostjanovs E, Liepins J, Grinberga S, Pugovics O, Liepinsh E, Dambrova M: Mildronate, the inhibitor of L-carnitine transport, induces brain mitochondrial uncoupling and protects against anoxia-reoxygenation. *Eur J Pharmacol* 723: 55-61, 2014
- Pickard JD, Murray GD, Illingworth R, Shaw MD, Teasdale GM, Foy PM, Humphrey PR, Lang DA, Nelson R, Richards P: Effect of oral nimodipine on cerebral infarction and outcome after subarachnoid haemorrhage: British aneurysm nimodipine trial. *BMJ* 298: 636-642, 1989
- Pickard JD, Murray GD, Illingworth R, Shaw MD, Teasdale GM, Foy PM, Humphrey PR, Lang DA, Nelson R, Richards P, Sinar J, Bailey S, Skene A: Oral nimodipine and cerebral ischaemia following subarachnoid haemorrhage. *Br J Clin Pract* 44: 66-67, 1990
- Pupure J, Isajevs S, Skapare E, Rumaks J, Svirskis S, Svirina D, Kalvinsh I, Klusa V: Neuroprotective properties of mildronate, a mitochondria-targeted small molecule. *Neurosci Lett* 470: 100-105, 2010

29. Rabinstein AA, Friedman JA, Nichols DA, Pichelmann MA, McClelland RL, Manno EM, Atkinson JL, Wijedicks EF: Predictors of outcome after endovascular treatment of cerebral vasospasm. *AJNR Am J Neuroradiol* 25: 1778-1782, 2004
30. Rupp H, Zarain-Herzberg A, Maisch B: The use of partial fatty acid oxidation inhibitors for metabolic therapy of angina pectoris and heart failure. *Herz* 27: 621-636, 2002
31. Sesti C, Simkhovich BZ, Kalvinsh I, Kloner RA: Mildronate, a novel fatty acid oxidation inhibitor and antianginal agent, reduces myocardial infarct size without affecting hemodynamics. *J Cardiovasc Pharmacol Ther* 47: 493-499, 2006
32. Shutenko Zh V, Simkhovich BZ, Meirena DV, Kalvinsh I, Lukevits E: Regulation of carnitine-dependent metabolism of fatty acids in the rat myocardium using 3-(2,2,2-trimethylhydrazinium) propionate. *Vopr Med Khim* 35: 59-64, 1989
33. Shutenko Zh V, Kagan TI, Sjakste NI, Kalvinsh I: Mildronate: Mechanisms of action, perspective for pathology correction. *Khim-Pharm Zh* 29:13-17, 1995
34. Simard JM, Chen M, Tarasov KV, Bhatta S, Ivanova S, Melnitchenko L, Tymbalyuk N, West GA, Gerzanich V: Newly expressed SUR1-regulated NC(Ca-ATP) channel mediates cerebral edema after ischemic stroke. *Nat Med* 12:433-440, 2006
35. Simkhovich BZ, Shutenko ZV, Meirena DV, Khagi KB, Mezapuke RJ, Molodchina TN, Kalvins IJ, Lukevics E: 3-(2,2,2-Trimethylhydrazinium) propionate (THP)--a novel gamma-butyrobetaine hydroxylase inhibitor with cardioprotective properties. *Biochem Pharmacol* 37: 195-202, 1988
36. Sjakste N, Dzene A, Mepapuie R, Ignatovich L, Lukevics E: Modifications of the genome expression by several novel drugs. *Exp Biol* 26:3,4, 1992
37. Sjakste N, Bauman L, Boucher JL, Dzintare M, Meirena D, Sjakste J, Lauberte L, Kalvinsh I: Effects of gamma-butyrobetaine and mildronate on nitric oxide production in lipopolysaccharide-treated rats. *Basic Clin Pharmacol Toxicol* 94: 46-50, 2004
38. Sjakste N, Gutcaits A, Kalvinsh I: Mildronate: An antiischemic drug for neurological indications. *CNS Drug Rev* 11: 151-168, 2005
39. Sjakste N, Kleschyov AL, Boucher JL, Bauman L, Dzintare M, Meirena D, Sjakste J, Sydow K, Munzel T, Kalvinsh I: Endothelium - and nitric oxide-dependent vasorelaxing activities of gamma-butyrobetaine esters: Possible link to the antiischemic activities of mildronate. *Eur J Pharmacol* 495: 67-73, 2004
40. Svalbe B, Zvejniece L, Vavers E, Pugovics O, Muceniece R, Liepinsh E, Dambrova M: Mildronate treatment improves functional recovery following middle cerebral artery occlusion in rats. *Behav Brain Res* 222:26-32, 2011
41. Tettenborn D, Dyck J: Prevention and treatment of delayed ischemic dysfunction in patients with aneurysmal subarachnoid hemorrhage. *Stroke* 21: IV85-IV89, 1990
42. Trumbeckaite S, Kincius M, Preidis A, Preidiene M, Veikutis V, Borutaite V, Gulbinas A: Effects of ischemia-reperfusion and pretreatment with mildronate on rat liver mitochondrial function. *Pharmacol Rep* 61: 859-869, 2009
43. Tseng MY, Hutchinson PJ, Richards HK, Czosnyka M, Pickard JD, Erber WN, Brown S, Kirkpatrick PJ: Acute systemic erythropoietin therapy to reduce delayed ischemic deficits following aneurysmal subarachnoid hemorrhage: A Phase II randomized, double-blind, placebo-controlled trial. *J Neurosurg* 111: 171-180, 2009
44. Vilskersts R, Liepinsh E, Kuka J, Cirule H, Veveris M, Kalvinsh I, Dambrova M: Myocardial infarct size-limiting and anti-arrhythmic effects of mildronate orotate in the rat heart. *Cardiovasc Drugs Ther* 23: 281-288, 2009
45. Wong GK, Chan MT, Gin T, Poon WS: Intravenous magnesium sulfate after aneurysmal subarachnoid hemorrhage: Current status. *Acta Neurochir* 110: 169-173, 2011
46. Zhu Y, Zhang G, Zhao J, Li D, Yan X, Liu J, Liu X, Zhao H, Xia J, Zhang X, Li Z, Zhang B, Guo Z, Feng L, Zhang Z, Qu F, Zhao G: Efficacy and safety of mildronate for acute ischemic stroke: A randomized, double-blind, active-controlled phase II multicenter trial. *Clin Drug Investig* 33:755-760, 2013
47. Zvejniece L, Svalbe B, Makrecka M, Liepinsh E, Kalvinsh I, Dambrova M: Mildronate exerts acute anticonvulsant and antihypnotic effects. *Behav Pharmacol* 21:548-555, 2010