

# Combined Preoperative Embolization and Surgical Treatment of a Giant Aneurysmal Bone Cyst in the Lumbar Spine: A Case Study

Idris SERTBAS, Mete KARATAY

Istanbul Yeni Yuzyil University School of Medicine, Department of Neurosurgery, Istanbul, Turkey

**Corresponding author:** Idris SERTBAS ✉ idris.sertbas@yeniyyuzuil.edu.tr

## ABSTRACT

An aneurysmal bone cyst (ABC) is a vascular locally proliferative, non-neoplastic, benign lesion observed in children and young adults. 75% of ABCs occur before the age of twenty. The cyst frequently develops in the long bones and comprises 1.4% of primary bone tumors. Spinal ABC is rare and is typically observed in the thoracic and cervical regions. In the spinal region, the posterior elements of a single vertebra are usually involved. The lamina, pedicle, facet joints are more commonly affected. The lesion may also expand toward the corpus. We present a case involving successful total excision of a lumbar spinal giant ABC by combining surgery with preoperative coil embolization. Preoperative arterial embolization contributes to decreased morbidity and mortality rates by reducing the duration of surgery and occurrence of intraoperative hemorrhage.

**KEYWORDS:** Aneurysmal bone cyst, Spinal tumor, Primary bone tumor, Hypervascularity

## INTRODUCTION

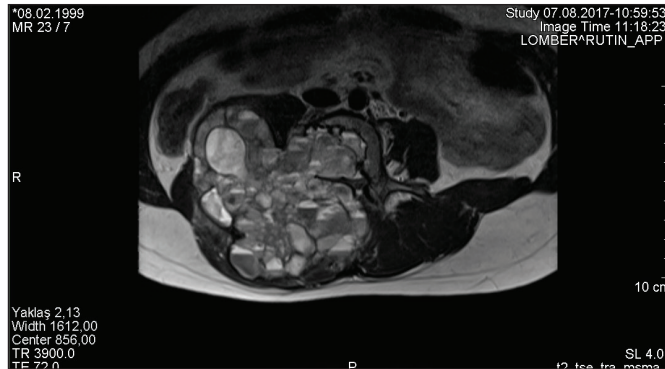
An aneurysmal bone cyst (ABC) is a benign, tumor-like, highly vascularized, locally aggressive and relatively rare osteolytic lesion with unknown etiology (16). The cysts primarily occur in the first and second decades of life and are more frequently observed in women (3,11). ABCs are the third most common benign tumors after osteoid osteomas and osteoblastomas. These cysts comprise 1.4% of primary bone tumors, and 3%-30% of cases are observed in the vertebral column, particularly in the lumbar region and posterior elements (8,15). The most common symptom is night pain, particularly on the side of the lesion. Direct graphy, computed tomography (CT), and magnetic resonance imaging (MRI) are useful for diagnosis. An enlarged osteolytic cavity can be observed on direct graphy, and a fluid-fluid level can be observed on CT and MRI. Surgical resection, radiotherapy, cryotherapy, and embolization are treatment choices for spinal lesions.

## CASE REPORT

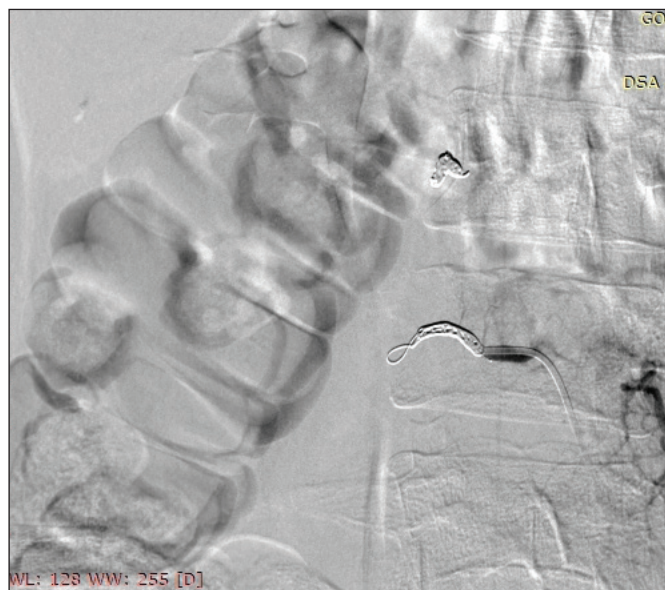An 18-year-old female presented with symptoms of low back pain and subcutaneous swelling at the fourth lumbar vertebral level for three months. Hypesthesia in the right L5 dermatome along with muscle strength of 4/5 on dorsal flexion of the right foot was noted. She had swelling that expanded the skin at the right paravertebral region at the fourth vertebral level. No urine or stool incontinence was noted, and there was no history of trauma. Lumbar CT revealed a lytic lesion in the L4 vertebral body and right pedicle. MRI revealed fluid-fluid level that was characteristic of an ABC (Figure 1). The lesion had expanded to the spinal canal and had compressed the right nerve roots. Digital subtraction angiography (DSA) performed 24 hours before surgery and revealed intense feeders of the ABC originating from the abdominal aorta and the iliac artery (Figure 2). These feeders were embolized at the L3 and L4 levels with arterial coil embolization (Figure 3). An incision was performed at the midline, extending from the lesion L2-L5 level, and extending 10 cm from this level laterally to the right. Total surgical excision was performed with a right

L3-L4 transpedicular and paravertebral approach, and fixed with a pedicle screw. The extradural part of the lesion was carefully dissected. The right L4 and L5 were observed to be adherent to the nerve roots and were carefully dissected. The lesion in the L4 vertebral body was completely excised, and corpus curettage was performed. The extradural part of the ABC, the lesion in L4 vertebral corpus, and the paravertebral component were completely excised. Pedicle screws were placed in the L3 and L5 vertebrae.

The patient had a preoperative hemoglobin level of 11g/dL and was followed for intraoperative hemoglobin, one unit of erythrocyte suspension and one unit of fresh frozen plasma were used. Intraoperative bleeding was 700 mL. Postoperatively, the patient had hemoglobin level of 8.7 g/dL, and one unit of erythrocyte suspension was used. The pain was alleviated, and no weakness developed postoperatively. Contrast-enhanced MRI revealed that the ABC had been excised (Figure 4). The pathology result was aneurysmal bone cyst.



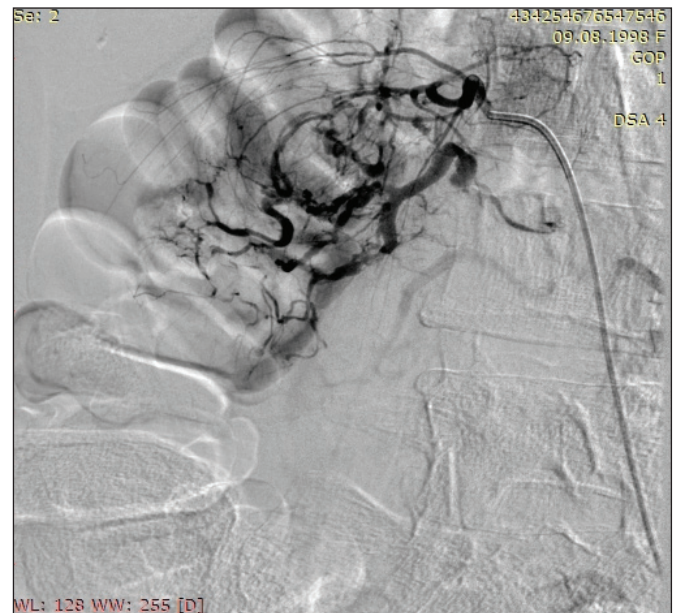**Figure 1:** Hyperintense MRI image showing fluid-fluid level at the L4 vertebra's right half on T2 axial images.



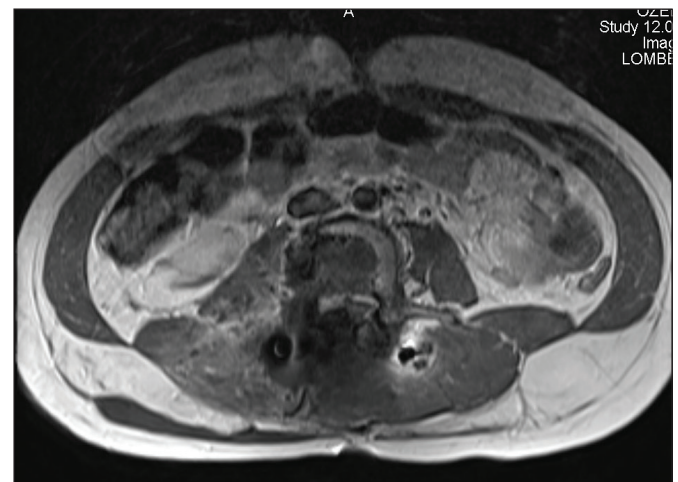
**Figure 3:** Tumor feeders from the abdominal aorta seem to be closed after selective arterial embolization.

## DISCUSSION

The lesion primarily occurs in the first and second decades of life, and is somewhat more common in women. ABCs are rare, non-neoplastic, reactive, expansive, and highly vascular lesions of the bone, and the underlying cause remains unknown (2). They are found in the long bones and pelvis in 60% of cases, and in the spine in 20% of cases (2,12,15). The posterior elements of a single vertebra are typically involved in the spinal region. The lamina, pedicle and facet joints are more commonly affected and the lesion may also expand toward the corpus. It may also spread to adjacent vertebrae and costae through the facet joints and the intervertebral disc (12). Multiple vertebral involvement has been reported in up to 40% of patients in the literature (15).



**Figure 2:** Pre-operative DSA image showing branches fed by the abdominal aorta.



**Figure 4:** Post-operative axial MRI image with contrast.

Patients with spinal ABC present most commonly with pain that increases at night and in the supine position (12). The symptoms of spinal cord and nerve root pressure are secondary. Other signs and symptoms include muscle spasms and reactive scoliosis or torticollis secondary to pain. A painless paravertebral mass may be present (6,7).

Some general findings can be used for radiological diagnosis but are not specific to ABC (3). Direct radiography, CT, and MRI are all used in the diagnosis. The appearance of the lesion may vary according to the stage of the disorder (9,10,15). The borders of the expanded bone may not be completely defined in the active early stages, and it may resemble a malignant lesion. The lytic appearance on the direct graph is remarkable, and trabeculation can be observed. In addition, a fluid-fluid level can be identified on CT. Intralesional septae formation is not specific to ABC, and the septae can be better demonstrated on contrast-enhanced MRI (17).

The histology of ABC is characterized by osteoid production and typical cavernous channels surrounded by osteoclasts such as giant cells and a spindle cell stroma (1). There are some hypotheses that the tumor is either caused by a hemorrhage inside the tumor, a vascular disease of the bone or abnormal healing of a traumatic subperiosteal hemorrhage (13).

Osteosarcoma, fibrous dysplasia, hemangioma, osteoid osteoma, fibrous cyst, solitary bone cyst, metastasis and eosinophilic granuloma should be considered in the differential diagnosis of ABC (3,15).

The treatment of spinal ABC can be challenging. Accessing lesions in this region is relatively difficult. There is a risk of excessive bleeding, and complete excision of the lesion while protecting the neural tissues is necessary (3,12,15). Current treatment options include intra-lesional curettage and bone grafting, selective embolization, radiotherapy, or a combination of these techniques (12). Additionally, percutaneous sclerotherapy using histoacryl has been reported (4). Radiotherapy is recommended only for recurrent lesions because sarcomatous degeneration and radiation myelopathy are frequently reported as later complications (2,3,7). Although single-level laminectomy is adequate for lesions where the posterior elements of only a single vertebra are involved, bone fusion and instrumentation of the lesion with curettage is required in cases where the bone destruction is wide and/or multiple segments are affected (5,12). Preoperative selective arterial embolization is currently used to minimize intraoperative bleeding (14). The procedure can decrease the blood supply of the cyst and permits the surgery to be performed more easily.

In the case, intensive vascularization of the tumor was noticed on arterial angiography 24 hours prior to surgery, and selective arterial coil embolization was performed. Total excision and curettage were surgically performed the next day after embolization.

## ■ CONCLUSION

Combined therapy involving preoperative selective arterial embolization and postoperative surgical intervention is

the ideal treatment for tumors such as giant ABCs with concentrated vascularity. Preoperative arterial embolization contributes to decreased morbidity and mortality rates by reducing the duration of surgery and occurrence of intraoperative hemorrhage.

## ■ REFERENCES

1. Al-Shamy G, Relyea K, Adesina A, Whitehead WE, Curry DJ, Luerssen TG, Jea A: Solid variant of aneurysmal bone cyst of the thoracic spine: A case report. *J Med Case Rep* 5(261):1-6,2011
2. Ameli NO, Abbassioun K, Saleh H, Eslamdoost A: Aneurysmal bone cyst of the spine. Report of 17 cases. *J Neurosurg* 63: 685-690,1985
3. De Dios AMV, Bond JR, Shives TC, McLeod RA, Unni KK: Aneurysmal bone cyst; A clinico pathologic study of 238 cases. *Cancer* 69:2921-2931, 1992
4. Dubois J, Chigot V, Grimard G, Isler M, Garel L: Sclerotherapy in aneurysmal bone cysts in children; A review of 17 cases. *Pediatri Radiol* 33(6):365-372,2003
5. Friedrich H, Seifert V, Becker H: Operative treatment of aneurysmal bone cyst of the spine; radical excision and spinal stabilization. *Advances in Neurosurgery*, cilt 14. Berlin: Springer Verlag 1986:116-132
6. Garneti N, Dunn D, El Gamal E, Williams DA, Nelson IW, Sandemon DR: Cervical spondyloptosis caused by an aneurysmal bone cyst; A case report. *Spine* 28(4):E-68-70,2003
7. Gupta VK, Gupta SK, Khosla VK, Vashisth RK, Kak VK: Aneurysmal bone cyst of the spine. *Surg Neurol* 42:428-432,1994
8. Hay MC, Paterson D, Taylor TK: Aneurysmal bone cysts of the spine. *J Bone Joint Surg Br* 60:406-411,1978
9. Jansen J, Terwey B, Rama B, Markakis E: MRI diagnosis of aneurysmal bone cyst. *Neurosurg Rev* 13:161-166,1990
10. Kransdorf MJ, Sweet DE: Aneurysmal bone cyst: Concept, controversy, clinical presentation, and imaging. *AJR* 164(3):573-580, 1995
11. Leithner A, Windhager R, Lang S, Haas O, Kainberger F, Kotz R: Aneurysmal bone cyst. A population based epidemiologic study and literature review. *Clin Orthop Relat Res* 363:176-179,1999
12. Mehdian H, Weatherley C: Combined anterior and posterior resection and spinal stabilization for aneurysmal bone cyst. *European Spine J* 4(2):123-125,1995
13. Munk PL, Helms CA, Holt RG, Johnston J, Steinbach L, Neumann C: MR imaging of aneurysmal bone cysts. *AJR Am J Roentgenol* 153(1):99-101,1989
14. Papagelopoulos PJ, Choudhury SN, Frassica FJ, Bond JR, Unni KK, Sim F: Treatment of aneurysmal bone cysts of the pelvis and sacrum. *J Bone Joint Surg Am* 83:1674-1681,2001
15. Papagelopoulos PJ, Currier BL, Shaughnessy WJ, Sim FH, Ebersold MJ, Bond JR, Unni KK: Aneurysmal bone cyst of the spine. Management and outcome. *Spine* 23:621-628,1998
16. Ruitter DJ, Van Rijssel TG, Van Der Velde EA: Aneurysmal bone cysts: A clinicopathological study of 105 cases. *Cancer* 39:2231-2239,1977
17. Turker RJ, Mardjetko S, Lubicky J: Aneurysmal bone cyst of the spine: Excision and stabilization. *J Pediatr Orthop* 18:209-213,1998