

*Original Investigation*

Common Spinal Parasites

Yong XIA¹, Yan JU², Jin Ping LIU¹, Long Yi CHEN¹¹University of Electronic Science and Technology of China, Sichuan Academy of Medical Sciences & Sichuan Provincial People's Hospital, Department of Neurosurgery, Chengdu 611731, Sichuan, P.R. China²Sichuan University, West China Hospital, Department of Neurosurgery, Chengdu, Sichuan Province, P.R. China**ABSTRACT****AIM:** To report the four most common spinal parasites for providing insight into definitive therapy.**MATERIAL and METHODS:** Twelve patients with spinal parasites were diagnosed between 2009 and 2016. A definite diagnosis was established in the form of histopathology (n=9) and response to drug therapy (n=3). The minimum follow-up was 0.9 years and ranged to a maximum of 8 years, with a median of 3 years.**RESULTS:** Twelve patients aged between 8 and 69 years were reviewed, including nine hydatidosis and three non-hydatid cases. Occupational exposure to the endemic area and unclean food were the main routes of infestation. Spinal parasites can present symptoms that correlated with the level of the lesion. There was complete paraplegia in four patients and paraparesis in six patients before surgery. Seven hydatid patients underwent posterior decompression and pedicle screw fixation with posterolateral fusion. Two non-hydatid patients experienced laminoplasty after posterior decompression. Six hydatid patients had reoccurrences and two patients with intramedullary hydatidosis died of severe complications one year after surgery.**CONCLUSION:** Spinal hydatidosis significantly differs from the three other non-hydatid parasites in diagnosis and treatment. The final prognosis of spinal hydatidosis remains poor, especially for intramedullary hydatidosis.**KEYWORDS:** Spinal parasite, Hydatid, Differential diagnosis, Treatment**ABBREVIATIONS:** MRI: Magnetic resonance image, CT: Computed tomography, CNS: Central nervous system**■ INTRODUCTION**

Parasitic diseases are distributed worldwide and are a major public health problem. Although these diseases are more prevalent in developing countries, particularly South America, Africa and South-East Asia (7), sporadic cases also occur in non-endemic areas (9,10). Spinal involvement is rare and often involves a space-occupying lesion. It is difficult for clinicians to make an accurate diagnosis before surgery. Delay in diagnosis leads to unnecessary surgery and a high rate of recurrence (5). Differential diagnosis is not only limited to spinal tumors (8), spinal tuberculosis or other pyogenic infections, but also includes differential diagnosis of different parasites, which is important because there are obvious differences in the therapeutic strategies against different parasites.

In China, hydatid, cysticercus, paragonimus and tapeworm are the most common parasites observed and mostly affect young patients. Although global efforts have been directed to radically treat this disease, the poor prognosis of spinal hydatidosis still demands that we attain a better understanding by studying medical literature. Despite some isolated cases reported in the medical literature, comparisons and summaries of different parasites are limited (8,11). In this article, we present the four most common types of spinal parasitic cases in China (7) and seek to remind clinicians that they should exercise caution in assuming a spinal tumor, spinal tuberculosis or other pyogenic infection before surgery. It is important to consider the possibility of spinal parasites, especially spinal hydatidosis.

**Corresponding author:** Yong XIA**E-mail:** Jchenhx@gmail.com/476257237@qq.com

■ MATERIAL and METHODS

Twelve patients with spinal parasites were diagnosed and treated in our hospitals from 2009 to 2016. All of the research procedures conformed to the guiding principles of the Declaration of Helsinki. All of the clinical data, investigations, surgical procedures and follow-up were investigated retrospectively. All patients underwent routine hematological investigations, spinal MRI and CT, chest and abdomen CT.

Nine patients were treated surgically through the posterior approach due to acute neurological dysfunction. The diagnosis of the nine surgical patients was confirmed by a pathological examination. The diagnosis of the other three patients was based on a positive reaction to a parasitic-specific antibody in the serum combined with clinical manifestations, typical imaging characteristics and a history of eating raw food. Seven hydatid patients, including two patients misdiagnosed with tuberculosis, had a transpedicular fixation with posterolateral fusion. Two non-hydatid patients had laminoplasty after a posterior decompression. An anti-helminthic treatment was postoperatively used in all patients. Albendazole was given

to treat hydatidosis (10 mg/kg/d for 1 year) and cysticercosis (15 mg/kg/d for 28 days). Praziquantel was given to treat tapeworm (60 mg/kg/d for 1 day) and paragonimus (25 mg/kg/d for 6 days). Ten patients were followed up by a periodic telephone interview or at discharge.

■ RESULTS

Twelve patients (5 male and 7 female) were admitted to our hospitals from 2009 and 2016. Multiorgan involvement occurred in eight patients, including three intracranial lesions (Figure 2A), seven hepatic lesions and two lung lesions (Figure 4A). The clinical symptoms were usually correlated with the level of the lesions, including chest pain, abdominal pain, lower back pain, urinary incontinence and constipation, spastic paraparesis-numbness and weakness in the legs, spinal kyphosis, and hypoesthesia below the level of the lesion. Headache and seizure occurred in patients with intracranial lesions. The sites of the lesions included the thoracic region (n=8), lumbosacral region (n=6) and cervical region (n=1). These lesions were localized to the intramedullary space (n=3),

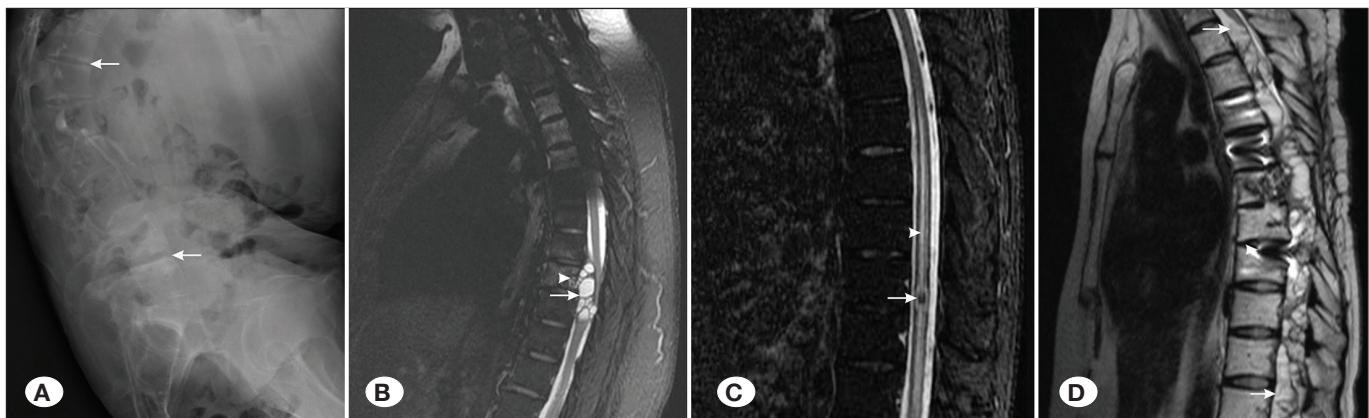


Figure 1: Spinal hydatidosis. **A)** End-plate osteochondritis and spinal deformity of the lumbar vertebrae on plain radiographs (arrows), **B)** Typical T2-weighted MR image of paravertebral-extradural hydatidosis (arrows), **C)** T2-weighted MR image of intramedullary hydatidosis (arrow) and the surrounding edema (arrowhead), **D)** T2-weighted MR image of intramedullary disseminated hydatidosis after surgery (arrows) and original fixation (arrowhead).

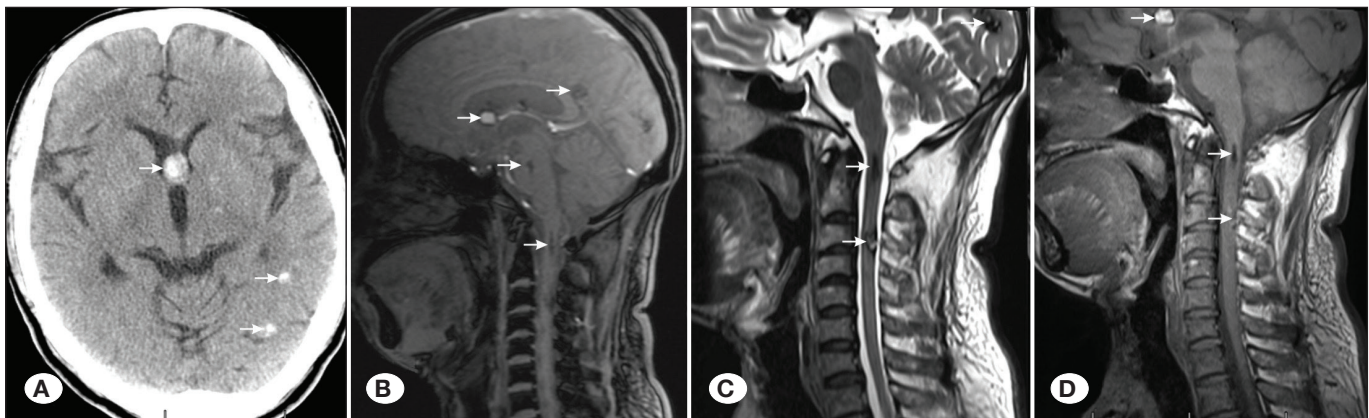


Figure 2: Intramedullary disseminated cysticercosis. **A)** CT image of intracranial lesions (arrows), **B)** T1-weighted MR image of intramedullary dissemination (arrows), **C)** T2-weighted MR image of intramedullary dissemination (arrows), **D)** No obvious enhancement on enhanced MRI (arrows).

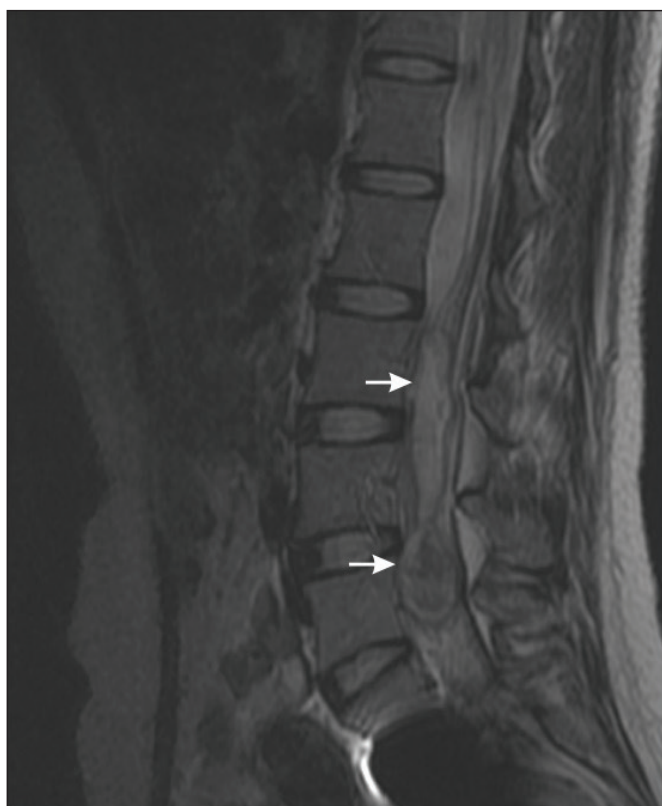

Figure 3: Spinal tapeworm. T2-weighted MR image of intradural-extramedullary lesion (arrows).

intradural space (n=1), intraspinal extradural space (n=1) and paravertebral region (n=7) (details are given in Table I). Three patients with intradural lesions had a definite history of spinal trauma or surgery.

In hydatid patients, spinal deformity, bone destruction of the vertebral body and end-plate osteochondritis were observed on plain radiographs (Figure 1A). The CT scan showed that seven hydatid patients had osteolytic destruction of their vertebral column spreading to the lamina, pedicle, and sometimes, paravertebral space. On MRI, paravertebral hydatidosis presented as a lobulated, multilocular, septated cystic mass (Figure 1B). Intramedullary disseminated hydatidosis resembled a long, “moth-eaten” intramedullary lesion with septations. The normal spinal cord was unrecognizable (Figure 1D). Spinal cysticercosis showed fusiform cord expansion with one or more ring-like lesions (Figure 2B-D). Spinal tapeworm presented as a large sausage-like lesion with two dome-shaped ends (Figure 3). Spinal paragonimus presented as a longitudinal extradural mass with multiple ring-shaped lesions (Figure 4B).

Nine patients were treated surgically through the posterior approach. Preoperative drugs were used in three patients with a hydatid history. Surgical patients were immediately given antihelminthics after surgery. No side effects related to the anti-helminthic treatment were observed. A long-term follow-up examination revealed a postoperative reoccurrence in six hydatid patients. The spinal function of patients with intramedullary hydatidosis did not improve after surgery; these patients died (one from a urinary tract infection and one from a CNS infection) within one year of surgery.

Table I: Details of the Patients

Case No.	Age(yr)	Sex	First Symptom	Location	Diagnosis	Treatment	Risk Factor	Recurrence Time	Outcome	Follow-up(yr)
1	31	F	LSP+RP	L3-S2	T	PD+RRL+M	HST	No	FOD	8
2	8	F	Cough	Brain/T3-7	P	PD+RRL+M	E+U	No	FOD	4
3	55	M	SCC+SD	Brain-C3	C	M	E+U	No	Paresis	1.5
4	47	F	BP+RP	T7-9	H	PD+PSF+M	E+U	Lost	Lost	/
5	29	F	AP,LSP	T12-L1	TB-H	PD+PSF+M	E+U	1	Paraplegia	6
6	50	M	BP+RP	L3-L5	H	PD+PSF+M	E+U	1	Paresis	4
7	50	F	AP	T11-12	TB-H	M	E+U+OH	/	Lost	/
8	43	M	Headache	Brain/T11-L5	H	M	E+HST	No	FOD	3
9	32	F	SCC	T3-S5	H	PD+PSF+M	OH+HST	1	Death	1
10	69	M	AP,BP	T9-10	H	PD+PSF+M	E+U	1	Death	1
11	33	F	BP	T11-L3	TB-H	PD+PSF	E+U	1	Paraplegia	1
12	55	M	BP	T12-L4	TB-H	PD+PSF+M	E+U+HST	2	Paresis	0.9

RP+SCC: Radicular pain and spinal cord compression, **AP:** Abdominal pain, **BP:** Back pain, **SP:** Sacrum pain, **SD:** Sphincter disturbances, **LSP:** Lumbosacral pain, **TB:** Tuberculosis, **T:** Tapeworm, **P:** Paragonimosis, **C:** Cysticercus, **H:** Hydatid, **L:** Laminectomy, **FOD:** Free of disease, **PD:** Posterior decompression, **PSF:** Pedicle screw fixation, **RRL:** Restoration of the resected lamina, **M:** Medicine, **E:** Epidemic area, **U:** Unclean food, **OH:** Occupational history, **HST:** History of spinal surgery or trauma, **OH:** Occupational history, **HST:** History of spinal surgery or trauma.

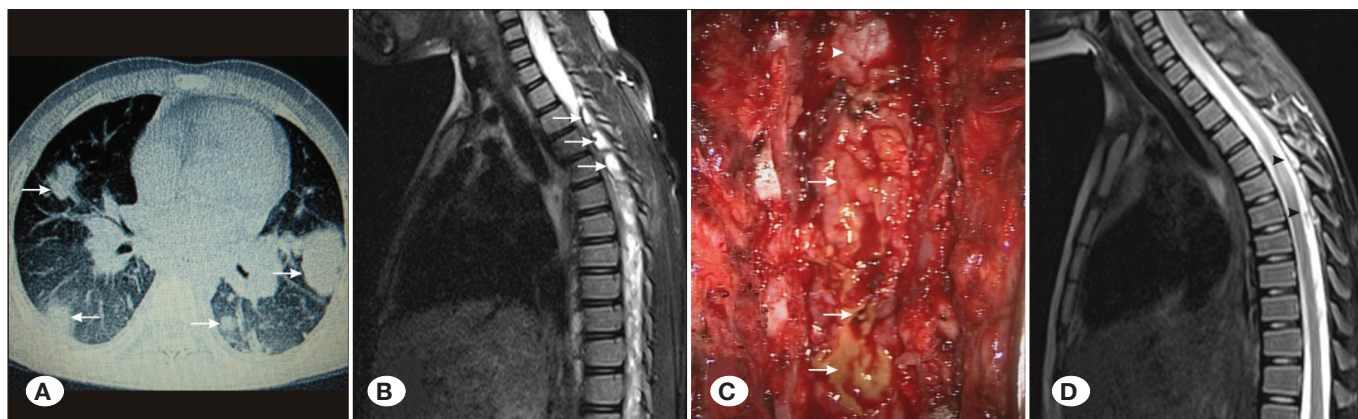


Figure 4: Spinal paragonimiasis. **A)** Lung lesions (arrows), **B)** T2-weighted MR image of a longitudinal extradural mass with multiple ring-shaped lesions (arrows), **C)** Spinal dura (arrowhead) and epidural lesion during the operation (arrows), **D)** T2-weighted MR image of the postoperative follow-up (arrows).

DISCUSSION

The number of parasitic infections has increased dramatically over the last two decades (7). Infections usually occur either directly by ingestion of parasitic eggs or indirectly from ingestion of contaminated food or water (3,7). Although the vast majority of early cases are able to be cured with prompt medical attention and treatment, many patients do not have a good prognosis owing to a delay in diagnosis. We summarized the latest data as a reference for the early diagnosis and differential therapy of spinal parasites.

Spinal parasites cause any symptoms linked to spinal cord compression and vertebral bone destruction. The most common symptoms and signs were paraparesis, radicular pain, sensory loss, sphincter disturbance, and local tenderness of the involved vertebra. These complaints were non-specific and were easily confused with spinal tuberculosis, tumor and other pyogenic diseases. For patients with intracranial lesions, epilepsy and headache were present from the first visit. The primary symptoms of patients with lung and liver involvements included coughs and abdominal pain.

The thoracic spine, especially the lower thoracic region, was the most commonly affected part of the vertebral column, followed by the lumbar spine, sacrum and cervical spine (details are given in Table I). The majority of parasitic lesions were located in the intraspinal-extradural or paraspinal areas and may have migrated from the liver or lung to the spinal canal (2). Primary intramedullary or intradural-extradural localization was exceptional, and their mechanisms remain unclear (6). Among our four patients with intradural lesions, intramedullary cysticercosis was secondary to the dissemination of intracranial infection (Figure 2A-D). Three other patients had histories of spinal trauma or surgery, which indicated that the non-integrity of the spinal dura could have provided an opportunity for intradural invasion.

Radiographic characteristics played a vital role in the diagnostic work-up of the spinal parasites. According to Braithwaite and Lees, extradural-intraspinal, vertebral and

paravertebral hydatidosis usually result in bone destruction of the vertebral body, lamina and vertebral arches (1). This destruction typically begins in the vertebral body and then infiltrates into the appendages, including the intervertebral discs, lamina and vertebral arches. Scoliosis or kyphotic deformity, end-plate osteochondritis and bone destruction of the vertebral body can appear on patients' radiographs. Such damages will also become evident on CT/MRI. The CT scan could show the degree of bone erosion and mainly present comminuted damage of the vertebral body. Cystic infiltration of the vertebral body and appendages mainly presented as a compressive fracture that, combined with the lesions, protruded into the spinal canal or paravertebral tissue on MRI (Figure 1B). The bone involvement of hydatidosis was significantly different from the bone involvement of other parasites, and needed to be distinguished from spinal tuberculosis. Hydatidosis, paragonimiasis and cysticercosis presented as ring-shaped lesions on MRI and were hypointense on T1W1 and hyperintense on T2WI (Figure 1B, C; 2B-D; 4B). By contrast, the typical hydatid rings were irregular and showed a honeycombing aggregation (Figure 1B) and the paragonimus rings were regular and showed a bead-like arrangement (Figure 4B). Intramedullary hydatidosis showed irregular "moth-eaten" changes (Figure 1D). Intramedullary cysticercosis was usually the result of intracranial dissemination (2,5) and showed a fusiform cord expansion with one or more ring lesions (Figure 2B-D).

It was important to differentiate cysticercus, paragonimus and tapeworm from hydatid, as medical treatment was effective in treating patients with these parasites, whereas surgery might be unnecessary. The main purposes of their surgery were to obtain an appropriate decompression and definitive diagnosis. Laminoplasty provided good spine stabilization for non-hydatid patients, especially pediatric patients (Figure 4D). For hydatid disease, the involvement of the vertebral bodies was as high as 82% (4). Vertebral recurrences were also high- as much as 40%, even after extensive surgery (2). Therefore, hydatid surgery not only requires an excision of the lesion and the affected vertebral body but also requires

additional effort to reduce dissemination and recurrence after surgery. Preoperative administration of antihelminthics and irrigation of the operative field with a scolical solution could significantly reduce dissemination and recurrence after surgery (10). Therefore, it is of crucial importance that an accurate diagnosis be made before surgery. Although southwest China is one of the most prevalent areas of hydatid disease, most neurosurgeons and orthopedists lack awareness of spinal hydatidosis and initially only consider the possibility of spinal tuberculosis. Only three patients received preoperative drugs, and in six patients, the disease recurred postoperatively. More importantly, it was difficult to accomplish complete removal of the involved bone combined with hydatid lesions in hydatid patients. Most surgeries actually consisted of a subtotal resection of hydatid lesions, spinal decompression and transpedicular fixation, which might have been the main cause of the high recurrence rate of hydatidosis.

Subsequent antihelminthic therapy was necessary to delay relapse and eliminate residual lesions from other organs. Paragonimus, cysticercosis and tapeworm were easily treated and the prognosis of patients with these parasites was relatively good. For hydatidosis, adjuvant antihelminthic chemotherapy was essential to control the disease locally, avoid systemic spread and prevent recurrence. In our study, although three non-hydatid cases had typical images that were able to provide some references for the clinicians, the reported number was relatively limited. Additionally, the prognosis of spinal hydatidosis is still poor and has not improved in comparison with previous reports. The goal of our study is to increase clinician's awareness to spinal parasites and encourage them to pay closer attention to preoperative diagnosis and intraoperative treatment of spinal hydatidosis.

■ CONCLUSION

Preoperative diagnosis of spinal parasites represents a challenge to contemporary clinicians. Clinicians should exercise caution in assuming spinal tuberculosis, spinal tumors or other pyogenic infections before surgery. Spinal hydatidosis necessitates a complete excision of the lesion and affected vertebral body combined with preoperative and postoperative medical therapy. The reason for surgery in

non-hydatid patients was to provide spinal decompression and confirm the pathology. The prognosis of intramedullary hydatidosis remains poor. Early recognition is essential to obtain optimum recovery.

■ DISCLOSURE

The authors have no conflict of interest concerning the materials or methods used in this study or the findings specified in this paper.

■ REFERENCES

1. Adilay U, Tugcu B, Gunes M, Gunaldi O, Gunal M, Esegolu M: Cauda equina syndrome caused by primary lumbosacral and pelvic hydatid cyst: A case report. *Minim Invasive Neurosurg* 50:292-295, 2007
2. Arif SH, Zaheer S: Intradural extramedullary primary hydatid cyst of the spine in a child: A very rare presentation. *Eur Spine J* 18 Suppl 2:179-182, 2009
3. Charles RW, Govender S, Nadio O: Echinococcal infection of the spine with neural involvement. *Spine* 13:47-49, 1988
4. Hall WA: Spinal parasites. *World Neurosurg* 83:39-40, 2015
5. Kafaji A, Al-Zain T, Lemcke J, Al-Zain F: Spinal manifestation of hydatid disease: A case series of 36 patients. *World Neurosurg* 80:620-626, 2013
6. Lath R, Ratnam BG, Ranjan A: Diagnosis and treatment of multiple hydatid cysts at the craniovertebral junction. *J Neurosurg Spine* 6:174-177, 2007
7. Li T, He S, Zhao H, Zhao G, Zhu XQ: Major trends in human parasitic diseases in China. *Trends Parasitol* 26:264-270, 2010
8. Qin Y, Cai J: MRI findings of intraspinal extradural paragonimiasis granuloma in a child. *Pediatr Radiol* 42:1250-1253, 2012
9. Schnepfer GD, Johnson WD: Recurrent spinal hydatidosis in North America. Case report and review of the literature. *Neurosurg Focus* 17:E8, 2004
10. Thaler M, Gabl M, Lechner R, Gstöttner M, Bach CM: Severe kyphoscoliosis after primary Echinococcus granulosus infection of the spine. *Eur Spine J* 19:1415-1422, 2010
11. Wang M, Ju Y, Liu X, Lv L, Wang Z, Jiang S: Hemorrhagic intraspinal paragonimiasis. *Neurology* 90:237-238, 2018