

Original Investigation

A Simple Cost-Effectiveness Analysis of Bilateral Decompression via Unilateral Approach versus Instrumented Total Laminectomy and Fusion for Lumbar Spinal Stenosis

Ali Erhan KAYALAR¹, Mehmet Resid ONEN¹, Aydin GERILMEZ², Sait NADERI¹

¹University of Health Sciences, Umraniye Teaching Hospital, Department of Neurosurgery, Istanbul, Turkey

²University of Health Sciences, Haydarpaşa Numune Teaching Hospital, Department of Neurosurgery, Istanbul, Turkey

Corresponding author: Ali Erhan KAYALAR ✉ draekayalar@gmail.com

ABSTRACT

AIM: To compare the clinical and economic results of two different surgical approaches (bilateral decompression via unilateral approach and instrumented total laminectomy and fusion) in the treatment of lumbar spinal stenosis.

MATERIAL and METHODS: The clinical, surgical, and economic aspects of 100 surgically treated patients with lumbar spinal stenosis were retrospectively reviewed.

RESULTS: Decompression was performed at 158 levels in 100 patients. The most commonly decompressed levels were L4-5 and L3-4. Significant difference was observed between pre- and postoperative visual analog scale scores in both groups ($p < 0.05$). In group 1 (instrumented total laminectomy and fusion), the mean surgery cost was 2539.2 USD (mean procedure cost, 1440.1 USD; mean implant cost, 1099.2 USD). In group 2 (bilateral decompression via unilateral approach) the mean surgery cost was 998.5 USD. The cost difference was significant ($p < 0.05$).

CONCLUSION: Both instrumented total laminectomy and fusion and bilateral decompression via unilateral approach performed with and without stabilization showed similar clinical results in patients with lumbar spinal stenosis. However, the cost of surgery was found to be 2.5-fold higher in the instrumented total laminectomy and fusion group. This study supports the concept that minimally invasive spine surgery is cost-effective.

KEYWORDS: Cost effectiveness, Economy, Lumbar spinal stenosis, Surgery

ABBREVIATIONS: **BDUA:** Bilateral decompression via unilateral approach, **CT:** Computed tomography, **MISS:** Minimally invasive spinal surgery, **MRI:** Magnetic resonance imaging, **LSS:** Lumbar spinal stenosis, **VAS:** Visual analog scale

INTRODUCTION

Lumbar spinal stenosis (LSS) may occur as a result of facet joint and ligamentum flavum hypertrophy, disc degeneration, spinal instability, or a combination of these conditions. In cases without overt instability, neurogenic claudication is the main symptom. The aim of surgical treatment is to eliminate symptoms by sufficiently decompressing the neural elements within the spinal canal. Commonly used modalities

for microsurgical treatment are laminectomy (24,32), unilateral laminotomy, bilateral laminotomy, and open door laminoplasty (5). Depending on the extent of decompression, the addition of fusion and stabilization has become more common recently as well. Furthermore, minimally invasive procedures, such as microsurgical or endoscopic decompression and bilateral decompression via unilateral approach (BDUA), have become more common (2,8,11,18). BDUA was first described by Young

et al (36). In this procedure, the facet joints and contralateral neural arch are protected, which decreases scar formation as well as the risk of iatrogenic instability. The aim of the present study was to compare the surgical results and economic costs of instrumented total laminectomy and fusion and BDUA.

■ MATERIAL and METHODS

Clinical, surgical, and economic aspects of 100 patients with LSS who underwent surgical intervention were retrospectively reviewed.

Inclusion and Exclusion Criteria

The primary indication for surgery in this study was neurogenic claudication with or without radicular pain associated with a radiological evidence of LSS. Radiological examination included lumbar magnetic resonance imaging (MRI), computed tomography (CT), dynamic lumbar radiographs, and in selected patients, scoliosis radiographs. Patients with concomitant disorders, such as inflammation, malignancy, degenerative spondylolisthesis, sagittal imbalance, and instability, were excluded from the study.

Patient Classification

Patients were classified into two groups: group 1 consisted of cases who underwent total laminectomy, transpedicular stabilization, and posterolateral fusion; group 2 consisted of patients who underwent BDUA. Leg pain of the patients was evaluated preoperatively and at 8 months postoperatively with a visual analog scale (VAS) using the VAS improvement rate [(preoperative VAS score – postoperative VAS score)/(preoperative VAS score) × 100]. In addition, the two groups were compared in terms of operation time, volume of bleeding, length of hospitalization, complications, and economic cost. The mean follow-up period was 16 ± 6 months.

Surgical Procedure

Instrumented Total Laminectomy and Fusion

All operations were performed under general anesthesia with the patient in the prone position. After fluoroscopy for level localization, a midline skin incision was made and subcutaneous dissection was performed to the lumbosacral fascia, exposing the level(s) of interest and one level above and below. The lumbosacral fascia was opened in the midline and the paravertebral muscles were subperiosteally stripped from the vertebral column bilaterally; a wide dissection was performed to visualize the transverse processes at all levels. First, transpedicular polyaxial screws were placed in each necessary pedicle under fluoroscopic guidance. Then total laminectomy was performed using Kerrison rongeurs and a high-speed drill under microscopic guidance. Following the decompression, the screw system was fixed with rods. Autogenous bone graft was used for fusion. The bone grafts were placed on and between the transverse processes (Figure 1A-D).

BDUA

All operations were performed under general anesthesia with

the patient in the prone position and all stages of the operation were performed using a surgical microscope. Entry was performed with a midline skin incision of approximately 2-3 cm, depending on the number of levels to be decompressed. The procedure was started on the symptomatic side or the side with greater stenosis on the radiographic studies in cases without radiculopathy. After subcutaneous dissection, the lumbosacral fascia was opened in the midline and the paravertebral muscles were stripped subperiosteally off the vertebral column. A Taylor retractor was placed lateral to the facet joint at the level where decompression was to be applied, and a weight of 500 g was attached. Using a high-speed drill, the upper and lower laminae were removed as far as the free edge of the hypertrophic ligamentum flavum, and the base of the spinous process was removed. Then, by tilting the operating table, the microscope angle was changed to be able to see the contralateral side. With this maneuver, an angle of approximately 60°-70° was achieved and thus good visualization was obtained. At this point, the contralateral ligamentum flavum was excised (Figure 2A-D).

Statistical Analysis

All statistical analyses were performed using SPSS for Windows 10.0 software. Descriptive statistical methods (mean, standard deviation) were used for data summarization. For quantitative data, the Wilcoxon sign test was used to compare parameters with non-normal distribution. For qualitative data, comparisons were performed using the Chi-square and McNemar tests. The results were evaluated at a confidence interval of 95% with statistical significance defined as $p < 0.05$.

■ RESULTS

Demographics

There were 50 patients in group 1 (42 females and 8 males, mean age 56.22 years), and 50 patients in group 2 (36 females and 14 males, mean age 58.44 years). There was no significant age difference between groups ($p > 0.05$).

Surgery Levels

Decompression was performed at 158 levels in 100 patients. The most commonly decompressed levels were L4-5 and L3-4. In group 1, single level decompression was performed in 27 patients and multisegmental decompression in 23 patients (mean 1.56 levels), whereas single level was performed in 24 patients and multisegmental in 26 patients in group 2 (mean 1.56 levels). In group 1, decompression was performed at a total of 78 levels (L2-3 in 6 patients, L3-4 in 21, L4-5 in 40, and L5-S1 in 11). In group 2, decompression was performed at a total of 80 levels (L2-3 in 6 patients, L3-4 in 27, L4-5 in 44, and L5-S1 in 3) (Figure 3).

Leg Pain Evaluation

A significant improvement in the degree of leg pain as a result of surgical decompression was found in all patients. The preoperative mean VAS score decreased from 7.96 ± 1.08 to 2.88 ± 0.5 in group 1, and from 7.7 ± 1.6 to 2.74 ± 0.3 in group 2. The difference between preoperative and postoperative VAS scores was statistically significant in both groups ($p = 0.000$).

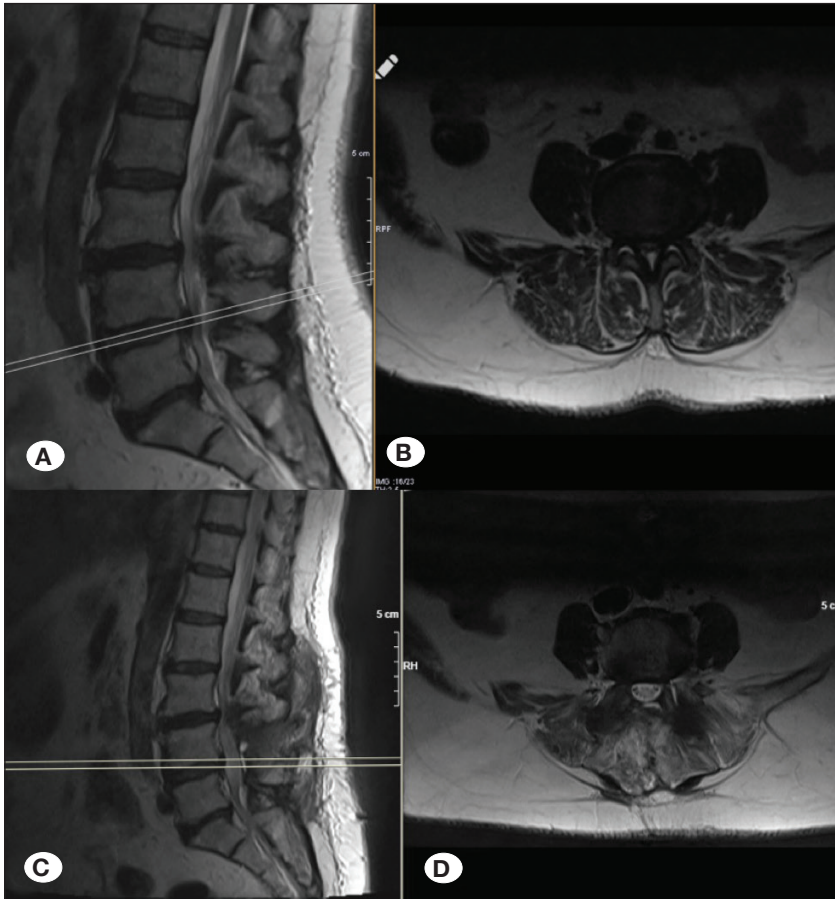


Figure 1: Preoperative (A,B) and postoperative (C,D) sagittal and axial MR images of a case with L4-5 lumbar spinal stenosis who underwent L4 total laminectomy with L4-L5 pedicle screw instrumentation.

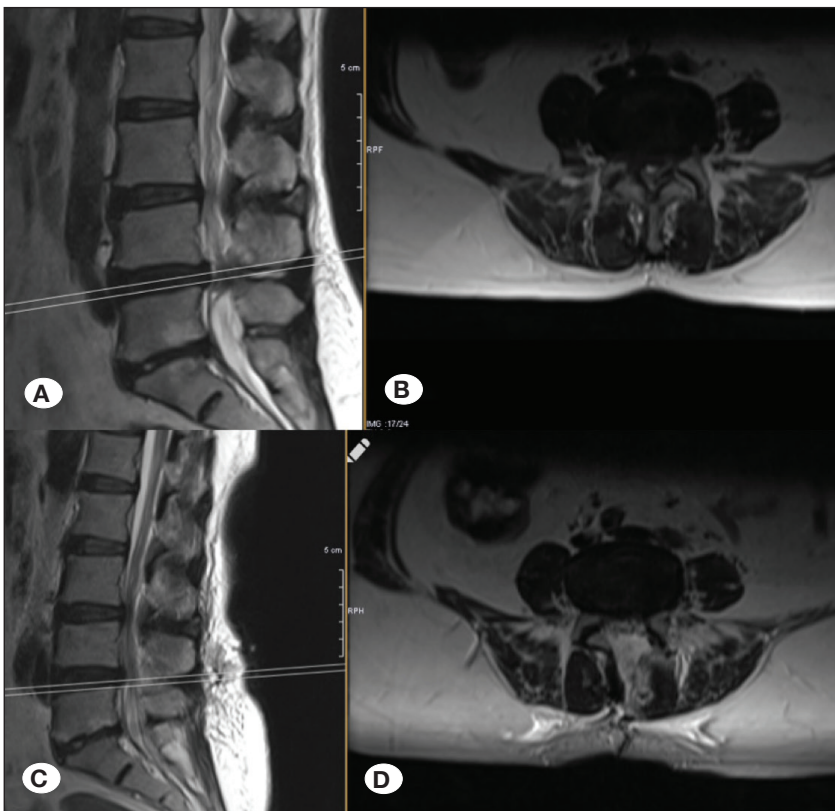


Figure 2: Preoperative (A,B) and postoperative (C,D) sagittal and axial MR images of a case with L4-5 lumbar spinal stenosis who underwent bilateral decompression via unilateral approach.

The VAS improvement rate was 63.8% in group 1 and 64.4% in group 2 (Figure 4).

Operating Time

The operating time (time from initial incision to final skin closure) was 186 ± 75 minutes in group 1 and 75.4 ± 30 minutes in group 2. The observed difference was statistically significant (p<0.05). We ignored all the periods of time lost in monitoring after intubation, arterial catheterization, attaching the catheter, positioning the patient, and positioning for preoperative fluoroscopy imaging and postoperative supine positioning, and late and early awakening.

Length of Hospitalization

Mean duration of postoperative hospitalization was 2.8 days in group 1, and 1.2 days in group 2. The observed difference between groups was statistically significant (p<0.05). In addition, we found that as the number of levels that underwent decompression increased, the length of hospitalization also increased.

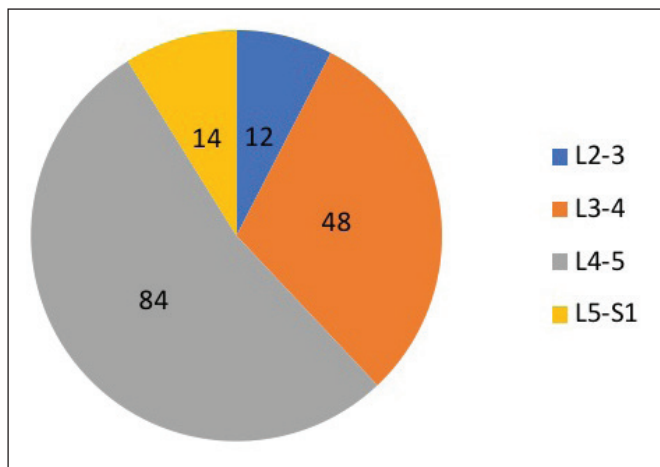


Figure 3: Number of levels operated on according to the pathological level.

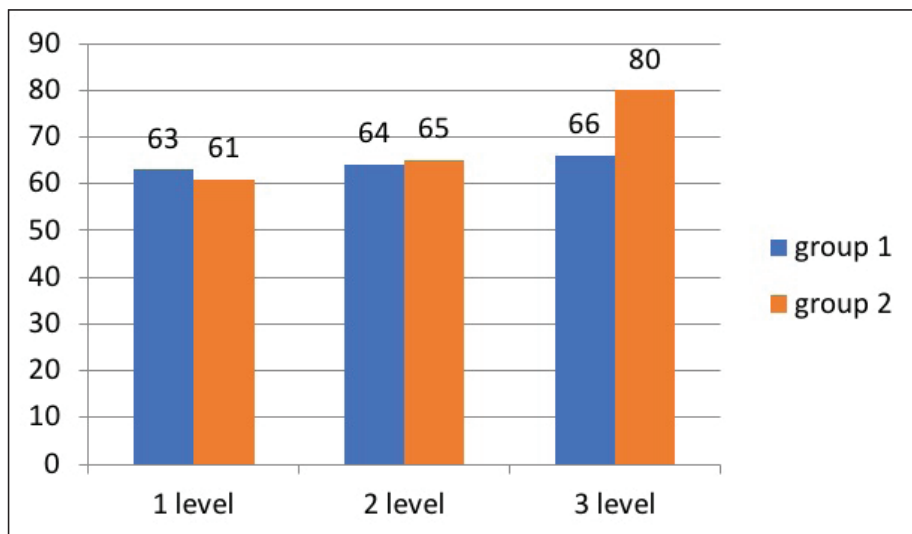


Figure 4: Preoperative – postoperative VAS changes according to the number of levels decompressed.

Blood Loss

Blood loss was 400 ± 85 mL in group 1 and 90 ± 35 mL in group 2. The observed difference was statistically significant (p<0.05).

Cost Analysis

In group 1, the mean cost of surgery was 1440.1 USD and the mean implant cost was 1099.2 USD, for a mean total cost of 2539.2 USD. In group 2, the mean cost of surgery was 998.5 USD. The difference between groups was statistically significant (p<0.05). All cost analysis data are presented in Table I.

Complications

During long-term follow-up in group 1, adjacent segment disease developed in one patient, who then underwent further decompression and extension of the fusion and instrumentation. In group 2, a dural tear occurred in one patient that was repaired with sutures and fibrin glue; no cerebrospinal fluid fistula developed during follow-up. Radicular complaints recurred during long-term follow-up in two patients who then underwent additional microdiscectomy.

DISCUSSION

This study showed the effectiveness of both laminectomy with fusion and BDUA in the surgical treatment of LSS and confirmed that BDUA is associated with lower cost, shorter postoperative hospitalization, and less blood loss than total laminectomy and fusion. The aim of surgery in LSS is improvement in neurogenic claudication and relief of pain. The standard treatment for spinal stenosis is total or hemilaminectomy. However, such a decompression may be associated with disruption of the supraspinous and interspinous ligament complexes, as well as disruption of the facet joints, leading to spinal instability (9,24,25,28,30,34). Therefore, the addition of instrumented fusion to decompression by many surgeons has become common practice (7,13). BDUA was developed

Table I: Comparison of the Results Between the Two Groups

	Number of cases	Pain relief (VAS)		Stay of hospital	Blood Loss (cc)	Operation time (min)	Cost analysis (US Dolar)
		Preoperative	Postoperative				
Group I	50 (42 F; 8 M)	7.96 ± 1.08	2.88 ± 0.5	2.8 days	400 ± 85	186 ± 75	1440.1
Group II	50 (36 F; 14 M)	7.7 ± 1.6	2.74 ± 0.3	1.2 days	90 ± 35	75.4 ± 30	2539.2
Statistically		p>0.05		p<0.05	p<0.05	p<0.05	p<0.05

to minimize instability due to iatrogenic ligament and facet joint disruption, and has become an effective alternative. By protecting a significant proportion of the facet joints and ligaments, the BDUA technique reduces the risk of instability, thus the addition of instrumented fusion to the procedure may not be needed. Previous studies have reported good short-term, mid-term, and long-term clinical results with BDUA (12,17,27,29,34). However, as the follow-up period became longer, the success rate decreased. Cavuşoğlu et al. reported a 94% patient satisfaction rate and 96% recovery rate in a study of BDUA patients with an 18–24 month follow-up period (4). In a study by Yaman et al. that compared the clinical and radiological results of classic laminectomy and BDUA at 6 and 12 months after surgery, no difference was found between the two procedures in terms of leg pain VAS scores, whereas back pain VAS scores of the BDUA patients were significantly lower (35). A randomized clinical study by Mobbs et al. that compared BDUA with open decompression in 79 patients found that BDUA was as effective as open decompression in terms of improvement in Oswestry Disability Index scores (6). Similarly, in a study by Park et al. ipsilateral and contralateral canal decompression using unilateral laminectomy were compared; the VAS improvement rate was 75.4% on the ipsilateral side and 73.7% on the contralateral side. The slight difference was not statistically significant (19). These studies and others suggest that BDUA is effective in the surgical treatment of LSS in terms of unilateral and contralateral leg pain and low back pain. In the current study, no statistically significant difference was found between group 1 and group 2 with respect to postoperative leg VAS scores, suggesting that the BDUA procedure is as successful as classic laminectomy in relieving leg pain. Back pain VAS scores of the BDUA patients were lower. We believe that this is due to less muscle stripping and retraction and preservation of the spinous processes and interspinous and supraspinous ligament complexes. The current study also showed that BDUA was associated with less blood loss, which agrees with previously published studies by Cavuşoğlu et al. (4), and Krut'ko (14). Less back pain and less blood loss are two advantages of BDUA in LSS surgery.

Other advantages associated with BDUA are shorter hospitalization time and lower cost. Although these advantages have been reported in many studies, debate remains regard-

ing whether minimally invasive spinal surgery (MISS) is more cost-effective than open surgery. This is because MISS techniques may require initial capital expenditures for imaging (C-arm, or O-arm) and the surgery itself (microscope, robotics, endoscope, and microinstruments). However, after initial expenditures, MISS techniques are associated with shorter hospitalization and faster return to work, resulting in better overall cost effectiveness in the long-term. Most cost-related studies have reported the costs of fusion techniques and confirmed the superiority of minimally invasive interbody fusion in terms of hospitalization rate, anesthesia time, and lower direct hospital costs. However, there are also several studies on the economic aspects of purely decompressive procedures (3,10,16,22,23,26,33). Udeh et al. compared laminectomy and minimally invasive decompression and reported that minimally invasive decompression was more cost-effective (43,760 USD vs. 125,985 USD) (31). Parker et al. compared conservative care, laminectomy, and interspinous spacer in the treatment of LSS and reported that laminectomy was more cost-effective than both interspinous spacer and conservative care (20-22). In other studies, the cost of decompression was compared with the cost of decompression and instrumented fusion. Kuntz et al. compared the costs and benefits of laminectomy alone to laminectomy plus lumbar fusion for patients with degenerative lumbar spondylolisthesis and LSS. As a result, they reported cost effectiveness of laminectomy alone when compared with decompression with instrumented fusion (15). A similar result was noted by Alvin et al., who reported that decompression with instrumented fusion was inferior to decompression alone in terms of cost effectiveness 1 year after surgery in patients with grade I degenerative spondylolisthesis (1). Our cost-related findings are in line with the previously reported results, however our study is limited, as a more detailed cost-effectiveness analysis could not be performed.

■ CONCLUSION

Laminectomy with fusion and BDUA for LSS have comparable clinical results after surgery, but BDUA is superior in terms of cost effectiveness (Table II). BDUA was found to be more cost-effective due to its lesser surgical cost, shorter hospital stay, and reduced need for transfusion.

Table II: Summary of the Previously Published (2012 – 2016) Literature

Comparison	Author	Year	Result
MISS vs. Open TLIF	Parker	2012	MIS-TLIF allows patients to leave the hospital sooner, achieve narcotic independence sooner, and return to work sooner than open-TLIF. In our experience, MIS- versus open-TLIF is a cost reducing technology in the surgical treatment of medically refractory low-back and leg pain from grade I lumbar spondylolisthesis.
MISS vs. Open TLIF	Parker	2014	MIS-TLIF may represent a valuable and cost-saving advancement from a societal and hospital perspective.
MISS vs. Open TLIF	Singh	2014	MIS-TLIF technique demonstrated significant reductions of operative time, LOS, anesthesia time, VAS scores, and EBL compared with the open technique. This reduction in perioperative parameters translated into lower total hospital costs over a 60-day perioperative period.
MAS tubular discectomy with conventional md, minimal access TLIF versus open TLIF, and multilevel hemilaminectomy via MAS versus open approach.	Lubelski	2014	The included cost-effectiveness studies generally supported no significant differences between open surgery and MAS lumbar approaches. Much of the evidence lacked details on methodology for modeling, related assumptions, justification of economic model chosen, and sources and types of included costs and consequences. The follow-up periods were highly variable, indirect costs were not frequently analyzed or reported, and many of the studies were conducted by a single group, thereby limiting generalizability. Prospective studies are needed to define differences and optimal treatment algorithms.
Circumferential fusions vs. posterolateral fusions	Ghogawala (Guideline update)	2014	Recent costanalyses have demonstrated the long-term benefits of circumferential fusions over posterolateral fusions (This study showed an incremental savings of \$49,306 per QALY following a circumferential fusion compared with a posterolateral fusion.)
MIS TLIF vs. OS TLIF	Vertuani	2015	MISS is a more cost-effective surgical procedure for lumbar spinal fusion in comparison with traditional OS in both the United Kingdom and Italy
CC vs. DS vs. Spacer	Parker	2015	DS was more cost effective than spacer and CC
MI-TLIF vs. open-TLIF	Phan	2015	Reduced perioperative costs, length of stay, and blood loss for minimally invasive compared with open surgical approaches for TLIF (weighted mean difference (WMD) \$2820 61%)
Laminectomy vs. MISS	Udeh	2015	MISS was more cost effective 43.760 S vs. 125.985 S
TLIF vs. PSF	Carreon	2016	At a cost per QALY threshold of \$100,000 and using SF-6D-based QALYs, the authors found that TLIF would be cost-prohibitive compared with PSF at a surgical cost of \$4830 above that of PSF. However, with EQ-5D-based QALYs, TLIF would become cost-prohibitive at an increased surgical cost of \$2960 relative to that of PSF. With the 2014 US per capita gross domestic product of \$53,042 as a more stringent cost-effectiveness threshold, TLIF would become cost-prohibitive at surgical costs \$2562 above that of PSF with SF-6D-based QALYs or at a surgical cost exceeding that of PSF by \$1570 with EQ-5D-derived QALYs.

■ REFERENCES

1. Alvin MD, Lubelski D, Abdullah KG, Whitmore RG, Benzel EC, Mroz TE: Cost-utility analysis of instrumented fusion versus decompression alone for Grade I L4-L5 spondylolisthesis at 1-year follow-up: A pilot study. *Clin Spine Surg* 29:80-86, 2016
2. Aryanpur J, Ducker T: Multilevel lumbar laminotomies: An alternative to laminectomy in the treatment of lumbar stenosis. *Neurosurgery* 26:429-432, 1990
3. Carreon LY, Glassman SD, GHogawala Z, Mummaneni PV, McGirt MJ, Asher AL: Modeled cost-effectiveness of transforaminal lumbar interbody fusion compared with posterolateral fusion for spondylolisthesis using N(2)QOD data. *J Neurosurg Spine* 24: 916-921, 2016
4. Cavusoglu H, Turkmenoglu O, Kaya RA, Tuncer C, Colak I, Sahin Y, Aydin Y: Efficacy of unilateral laminectomy for bilateral decompression in lumbar spinal stenosis. *Turk Neurosurg* 17:100-108, 2007
5. Chatani K: A novel surgical approach to the lumbar spine involving hemilateral split-off of the spinous process to preserve the multifidus muscle: Technical note. *J Neurosurg Spine* 24:694-699, 2016
6. Choi WS, Oh CH, Ji GY, Shin SC, Lee JB, Park DH, Cho TH: Spinal canal morphology and clinical outcomes of microsurgical bilateral decompression via a unilateral approach for lumbar spinal canal stenosis. *Eur Spine J* 23: 991-998, 2014
7. Deyo RA, Nachemson A, Mirza SK: Spinal fusionsurgery-the case for restraint. *N Engl J Med* 350:722-726, 2004
8. Dirksmeier P, Parsons IM, Kang J: Microendoscopic and open laminotomy and discectomy in lumbar disc disease. *Semin Spine Surg* 11:138-146, 1999
9. Fox MW, Onofrio BM, Hanssen AD: Clinical outcomes and radiological instability following decompressive lumbar laminectomy for degenerative spinal stenosis: A comparison of patients undergoing concomitant arthrodesis versus decompressional one. *J Neurosurg* 85:793-802, 1996
10. Ghogawala Z, Whitmore RG, Watters WC 3rd, Sharan A, Mummaneni PV, Dailey AT, Choudhri TF, Eck JC, Groff MW, Wang JC, Resnick DK, Dhall SS, Kaiser MG: Guideline update for the performance of fusion procedures for degenerative disease of the lumbar spine. Part 3: Assessment of economic outcome. *J Neurosurg Spine* 21:14-22, 2014
11. Herkowitz H, Kurz L: Degenerative lumbar spondylolisthesis with spinal stenosis. *J Bone Joint* 73:802-808: 1991
12. Ji YC, Kim YB, Hwang SN, Park SW, Kwon JT, Min BK: Efficacy of unilateral laminectomy for bilateral decompression in elderly lumbar spinal stenosis. *J Korean Neurosurg Soc* 37: 410-415, 2005
13. Korovessis P, Papazisis Z, Koureas G, Lambiris E: Rigid, semirigid versus dynamic instrumentation for degenerative lumbar spinal stenosis: A correlative radiological and clinical analysis of short-term results. *Spine* 29:735-742, 2004
14. Krut'ko AV: Results of decompressive stabilizing procedures via unilateral approach in lumbar spinal stenosis. *Zh Vopr Neurokhir Im N N Burdenko* 76:33-40, 2012
15. Kuntz KM, Snider RK, Weinstein JN, Pope MH, Katz JN: Cost-effectiveness of fusion with and without instrumentation for patients with degenerative spondylolisthesis and spinal stenosis. *Spine* 25:1132-1139, 2000
16. Lubelski D, Mihalovich KE, Skelly AC, Fehling MG, Harrop JS, Mummaneni OV, Wang MY, Steinmetz MP: Is minimal access spine surgery more cost-effective than conventional spine surgery? *Spine* 39 (22 Suppl 1):65-74, 2014
17. Mariconda M, Fava R, Gatto A, Longo C, Milano C: Unilateral laminectomy for bilateral decompression of lumbar spinal stenosis: A prospective comparative study with conservatively treated patients. *J Spinal Disord Tech* 15:39-46, 2002
18. Palmer S, Turner R, Palme R: Bilateral decompression of lumbar spinal stenosis involving a unilateral approach with microscope and tubular retractor system. *J Neurosurg* 97:213-217, 2002
19. Park WB, Hong JT, Lee SW, Sung JH, Yang SH, Kim IS: Clinical and radiological comparison between ipsilateral and contralateral side canal decompression using an unilateral laminotomy approach. *Korean J Spine* 13:41-46, 2016
20. Parker SL, Adogwa O, Bydon A, Cheng J, McGirt MJ: Cost-effectiveness of minimally invasive versus open transforaminal lumbar interbody fusion for degenerative spondylolisthesis associated low-back and leg pain over two years. *World Neurosurg* 78:178-184, 2012
21. Parker SL, Mendenhall SK, Shau DN, Zucherman SL, Godil SS, Cheng JS, McGirt MJ: Minimally invasive versus open transforaminal lumbar interbody fusion for degenerative spondylolisthesis: Comparative effectiveness and cost-utility analysis. *World Neurosurg* 82:230-238, 2014
22. Parker SL, Anderson LH, Nelson T, Patel VV: Cost-effectiveness of three treatment strategies for lumbar spinal stenosis: Conservative care, laminectomy, and the superior interspinous spacer. *Int J Spine Surg* 9:9-28, 2015
23. Phan K, Hogan JA, Mobbs RJ: Cost-utility of minimally invasive versus open transforaminal lumbar interbody fusion: Systemic review and economic evaluation. *Eur Spine J* 24: 2503-2513, 2015
24. Phan K, Mobbs RJ: Minimally invasive versus open laminectomy for lumbar stenosis: A systematic review and meta-analysis. *Spine* 41:91-100, 2016
25. Prestar FJ: Morphology and function of the interspinous ligaments and the supraspinal ligament of the lumbar portion of the spine. *Morphol Med* 2:53-58, 1982
26. Singh K, Nandyala SV, Marquez-Lara A, Fineberg SJ, Oglesby M, Pelton MA, Andersson GB, Isayeva D, Jegier BJ, Phillips FM: A perioperative cost analysis comparing single-level minimally invasive and open transforaminal lumbar interbody fusion. *Spine J* 14:1694-1701, 2014
27. Spetzger U, Bertalanffy H, Reinges MH, Gilsbach JM: Unilateral laminotomy for bilateral decompression of lumbar spinal stenosis. Part II: Clinical experiences. *Acta Neurochir* 139:397-403, 1997
28. Thomas NW, Rea GL, Pikul BK, Mervis LJ, Irsik R, McGregor JM: Quantitative outcome and radiographic comparisons between laminectomy and laminotomy in the treatment of acquired lumbar stenosis. *Neurosurgery* 41:567-575, 1997

29. Thome C, Zevgaridis D, Leheta O, Bazner H, Pockler-Schoniger C, Wohrle J, Schmiedek P: Outcome after less-invasive decompression of lumbar spinal stenosis: A randomized comparison of unilateral laminotomy, bilateral laminotomy, and laminectomy. *J Neurosurg Spine* 3:129-141, 2005
30. Tsai RY, Yang RS, Bray RS Jr: Microscopic laminotomies for degenerative lumbar spinal stenosis. *J Spinal Disord* 11:389-394, 1998
31. Udeh BL, Costandi S, Dalton JE, Ghosh R, Yousef H, Mekhail N: The 2-year cost-effectiveness of 3 options to treat lumbar spinal stenosis patients. *Pain Pract* 15:107-116, 2015
32. Usman M, Ali M, Khanzada K, Ishaq M, Naeem-ul-Haq, Aman R: Unilateral approach for bilateral decompression of lumbar spinal stenosis: A minimal invasive surgery. *J Coll Physicians Surg Pak* 23:852-856, 2013
33. Vertuani S, Nilsson J, Borgman B, Buseghin G, Leonard C, Assietti R, Quraishi NA: A cost-effectiveness analysis of minimally invasive versus open surgery techniques for lumbar spinal fusion in Italy and the United Kingdom. *Value Health* 18: 810-816, 2015
34. Weiner BK, Walker M, Brower RS, McCulloch JA: Micro decompression for lumbar spinal canal stenosis. *Spine* 24: 2268-2272, 1999
35. Yaman O, Ozdemir N, Dagli AT, Acar E, Dalbayrak S, Temiz C: A comparison of bilateral decompression via unilateral approach and classic laminectomy in patients with lumbar spinal stenosis: A retrospective clinical study. *Turk Neurosurg* 25: 239-245, 2015
36. Young S, Veerapen R, O'Laoire SA: Relief of lumbar canal stenosis using multilevel subarticular fenestrations as an alternative to wide laminectomy: Preliminary report. *Neurosurgery* 23:628-633, 1988