

Original Investigation

Effects of Microvascular Decompression Plus Longitudinal Nerve Sectioning on Recurrent Trigeminal Neuralgia and Investigations of Postoperative Recurrence Causes

Luo CONG, Cheng ZHIHUA, Guo ZHILIN, Ou Yang HUONIU

Shanghai Jiao Tong University, School of Medicine, Shanghai Ninth People's Hospital, Department of Neurosurgery, Shanghai, China

ABSTRACT

AIM: To investigate the causes of recurrent trigeminal neuralgia (RTN) and to evaluate the efficacy of microvascular decompression (MVD) plus longitudinal nerve sectioning (LNS) or LNS only for RTN patients who have undergone multiple procedures.

MATERIAL and METHODS: 21 patients underwent MVD plus LNS or LNS only at our institute from June 2008 to December 2014. The patients were retrospectively studied and analyzed. The following data were collected: age, sex, treatment before surgery, pain severity and distribution, findings during surgery, immediate postoperative BNI (Barrow Neurological Institute score system), final follow-up BNI, complications and associated comorbidities.

RESULTS: Vascular compression, arachnoid adhesion and Teflon granulomas were the primary causes of recurrent TN. After MVD plus LNS or LNS only treatments, almost all patients (19/21, 90.5%) reported pain relief after 36.1 months. Of these patients, 15 patients (71.4%) reported being pain-free (BNI score I) and 4 patients (19.1%) reported pain relief (BNI II-III). Two patients reported a pain level of BNI IV. However, almost all patients were left with some degree of numbness.

CONCLUSION: This study certified that vascular compression, arachnoid adhesion and Teflon granulomas were the reasons for recurrent trigeminal neuralgia. MVD plus LNS or LNS only were both feasible therapeutic options, with good probabilities of success, especially after multiple neurodestructive procedures.

KEYWORDS: Microvascular decompression, Longitudinal nerve sectioning, Recurrent trigeminal neuralgia, Vascular compression, Arachnoid adhesion, Teflon granuloma

INTRODUCTION

Idiopathic trigeminal neuralgia (TN) is a facial pain syndrome. The incidence of idiopathic TN is reported as 1 to 2/10000 (21). It is usually qualified by sharp, paroxysmal, unilateral and electric shock-like pain in branches of the trigeminal nerve, accompanied with innocuous triggers (25). However, the exact pathophysiology of TN is not well studied yet. As reported, the leading etiology hypothesis focuses on vascular compression at the root entry zone (REZ) of the trigeminal nerve (17,23,28). The effectiveness of microvascular decompression (MVD) for idiopathic TN supports this argument (3,24,35).

Studies have shown that the success rate of MVD tends to reduce over time. Approximately 22-42% of patients suffer from recurrent TN 5 years after MVD treatment, and careful decisions with respect to additional treatment must be made (5,24). Whether to use surgical or non-surgical methods to treat patients with recurrent TN has long been a controversial issue, and potential treatments include MVD, percutaneous glycerol rhizotomy, percutaneous radiofrequency rhizotomy, stereotactic radiosurgery, and percutaneous balloon compression. The purpose of this study was to discuss the outcomes of MVD plus LNS or LNS only for patients with recurrent TN.



Corresponding author: Zhilin GUO
E-mail: 13262626183@163.com

We also explored the possible causes of the disorder based on the observations during surgery.

■ MATERIAL and METHODS

This study was approved by the institutional review board of Shanghai Ninth People's Hospital.

Inclusion and Exclusion Criteria

A total of 376 patients with idiopathic TN accepted to undergo surgery at the department of Neurosurgery of our hospital from June 2008 to December 2014. Among them, 21 patients suffered from recurrent TN, even after several destructive surgical treatments, and ultimately accepted a treatment protocol of MVD plus LNS or LNS alone. The primary indications were typical, drug-resistant TN (the International Headache Society criteria), or drug-responsive TN but with severe drug-related adverse effects, without absolute contraindications to general anesthesia (12). The exclusion criteria were as follows: 1) patients who had failed initial surgeries; 2) patients who had a pain-free period after the initial surgical treatment; 3) patients with absolute contraindications to general anesthesia; 4) patients who did not choose MVD plus LNS treatment for recurrent TN; 5) patients whose data were not complete; and 6) patients who had any other surgery in the posterior fossa, such as tumor removal, vascular malformations and congenital malformations.

Data Collection

The medical records of all patients were reviewed. The data collected, included age, sex, treatment before surgery, pain severity and distribution, findings during surgery, immediate postoperative BNI, final follow-up BNI, associated comorbidities (e.g., cardiovascular diseases, arterial hypertension, and diabetes), and complications. The severity of pre- and post-operative pain was scored using the Barrow Neurological institute (BNI) Pain Intensity Scale Score. Statistics were analyzed with the mean, minimum and maximum range for continuous data. The enumeration data were expressed as percentages.

Surgical Procedures

MVD plus LNS was performed through a suboccipital retrosigmoid approach. Briefly, the patients were placed in the supine position, with the affected side up, the ear parallel to the floor, and the chin flexed (22). A standard 5 cm to 7 cm linear retroauricular incision was made. Then, if necessary, the existing cranioplasty material was completely removed. We removed the additional bone to visualize the edges of the sigmoid sinus and the transverse sinus. The craniotomy required was less than 3×2 cm. The dura was incised to form a flap, and the upper external posterior cranial fossa was fully exposed until the trigeminal nerve roots were clearly observed. The arachnoid membrane surrounding the trigeminal nerves was opened to expose REZ.

During the surgery, new Teflon felt pieces were used to separate the third nerve from the offending vessels. Then, the nerve fibers were divided longitudinally into several respective bundles, from the REZ to the petrous bone, by using a straight

blunt-tip bayonet probe. If necessary, the fibers were combed without evidence of compression. After surgery, the surgical incision was closed very carefully. During the surgery, the medical microscope video recorder system was used to record the intracranial details. All patients included in this study were operated on by one neurosurgeon, Zhi-Lin Guo.

Follow-up and the Post-Operative Outcome Assessments

All patients were telephoned and outpatient follow-ups were performed. The follow-up period ended on October 30, 2016. The Barrow Neurological Institute (BNI) scoring system was used to evaluate the degree of pain relief. According to Figure 4, the TN was divided into five grades, depending on the severity of pain and the response to medicine (27). Independent observers, who were not involved in patient management or surgeries, managed follow-ups through outpatient services or telephone and also recorded complications and recurrences. General inquiry, facial nerve tests and hearing tests were performed during the follow-ups.

■ RESULTS

A total of 376 patients were analyzed in this study, of whom 150 were men and 226 were women. The mean age at MVD was 58.2 ± 10.3 years old (range, 26.4-78.7 years old). The length of follow-up was from 21 to 98 months (mean, 59.2 ± 26.3 months). There were 18 patients with diabetes mellitus, 27 with cardiovascular disease and 96 with arterial hypertension. The demographic characteristics of the patients in our study are shown in Table I. Among them, 21 patients suffered from recurrent TN after multiple destructive surgical treatments, performed at other medical institutions, including microvascular decompression (MVD), percutaneous glycerol rhizotomy (PGR), stereotactic radiosurgery (SRS), botulinum neurotoxin (BoNT) and percutaneous balloon compression (PBC) (Table II). Ultimately 12 patients accepted MVD plus

Table I: Demographics and Characteristics of Patients

Characteristics	Value
Number of patients who underwent MVD	376
Male/female ratio	150/226
Male sex, n (%)	150 (39.9)
Age at surgery, years	
Median	58.2 ± 10.3
Range	26.4-78.7
Follow-up range (months)	21-98
Mean follow-up	59.2 ± 26.3
Comorbidities	
Diabetes mellitus	18
Cardiovascular disease	27
Arterial hypertension	96

LNS, and 9 patients accepted LNS alone, at the Department of Neurosurgery of Shanghai Ninth People's Hospital. Of these, 6 patients experienced facial numbness prior to the procedure.

All 21 patients experienced unilateral and electric shock-like pain, 8 on the left side and 13 on the other side. They had experienced recurrent pain for 3-18 months (mean 8 ± 4.3 months) and depended on drugs for pain relief to varying degrees (Table II). The mean age of the patients at the time of surgery was 59.6 ± 11.0 years old (range 39-78 years old). The follow-up period after the latest surgery ranged from 22 to 68 months (mean 38.3 ± 15.2 months). During the follow-up period, relief from symptoms was observed in all cases. The demographic characteristics of the patients are shown in Table II.

Preoperative Imaging and Operative Findings

The pre-operative MRTA of 18 patients (18/21, 85.7%) showed positive results, consistent with the observations during operations. During the surgery the following were discovered: arterial compression in 7 patients (33.3%); venous compression in 2 patients (4.8%); arterial combined with venous compression in 2 patients (9.5%); Teflon granulomas in 1 patient (4.8%); and nothing except arachnoid adhesion in 9 cases (42.9%) (Table III). Arachnoid adhesion was found in 20 out of the 21 patients (95.2%) and was dissected during surgery.

Teflon granulomas have been considered to be responsible for recurrent TN. During the operations, a Teflon granuloma was found in the cerebellopontine angle and was in touch with the trigeminal nerve in 1 of the 21 patients. As shown in Figure 1, the mass was a low-intensity signal in the T2-weighted MRI

Table II: Demographics and Characteristics of Patients Undergoing MVD Plus LNS or LNS Only

Patient No.	sex	age	Duration of symptoms before the procedure	Pain distribution before the procedure	Follow-up duration after the procedure, months	Other treatments before the procedure
1	F	49	18	R V2	32	MVD, BoNT
2	F	66	5	R V3	23	MVD, SRS
3	F	62	7	R V2	68	MVD, PBC
4	F	39	6	L V2	60	MVD, PGR
5	F	63	4	L V2V3	26	MVD, PBC
6	M	50	17	R V1	48	MVD, SRS
7	F	64	3	R V2	24	MVD, SRS, PBC, BoNT
8	F	69	7	L V2	37	MVD, BoNT
9	M	63	12	R V2	33	MVD, PBC
10	F	41	3	L V2	25	MVD, SRS
11	M	55	7	R V2	28	MVD, SRS
12	F	70	5	RV3	27	MVD, SRS
13	M	60	7	RV2	28	MVD, BoNT
14	M	69	6	RV2	27	MVD, SRS, BoNT
15	F	41	11	LV1	35	MVD, BoNT, SRS
16	M	78	14	RV3	58	MVD, PBC
17	F	70	10	LV2	57	MVD, SRS
18	F	49	4	LV2	66	MVD, SRS
19	M	59	6	RV3	22	MVD, SRS
20	F	69	7	RV2	33	MVD, PGR
21	M	66	9	LV2	47	MVD, PBC

F: Female, **M:** Male, **R:** Right, **L:** Left, **V1:** The first branch of trigeminal nerve, **V2:** The second branch of the trigeminal nerve, **V3:** The third branch of the trigeminal nerve, **MVD plus LNS:** Microvascular decompression in combination with longitudinal nerve sectioning, **MVD:** Microvascular decompression, **PGR:** Percutaneous glycerol rhizotomy, **PBC:** Percutaneous balloon compression, **SRS:** Stereotactic radiosurgery, **BoNT:** Botulinum neurotoxin.

Table III: Magnetic Resonance Tomographic Angiography and Operative Findings in 21 Patients

Patients No.	MRTA before the procedure	the procedure	Findings during the surgery	the procedure			Comorbidities
				Pre-op BNI	Immediate post-op BNI	Final follow-up BNI	
1	P	LNS	AA only	IV	I	II	AH
2	P	LNS	AA only	IV	I	I	NO
3	P	MVD+LNS	AICA+PV+AA	V	I	IV	AH
4	P	LNS	AA only	IV	I	I	AH
5	P	LNS	AA only	V	I	I	NO
6	N	MVD+LNS	PV+AA	V	II	IV	NO
7	p	MVD+LNS	AICA+AA	V	I	I	NO
8	P	MVD+LNS	AICA+AA	IV	I	I	NO
9	p	LNS	AA only	IV	I	I	NO
10	P	MVD+LNS	AICA+AA	V	I	II	NO
11	P	LNS	AA only	V	I	I	AH
12	P	MVD+LNS	SCA+AA	V	I	I	NO
13	N	MVD+LNS	PV+AA	V	I	II	NO
14	P	MVD+LNS	AICA	IV	I	I	AH
15	P	LNS	AA only	V	I	I	AH,CD
16	p	MVD+LNS	AICA+AA	IV	I	I	NO
17	P	MVD+LNS	SCA+AA	IV	I	II	AH
18	P	MVD+LNS	AICA+PV+AA	V	I	I	NO
19	N	LNS	AA only	IV	I	I	AH
20	P	MVD+LNS	Teflon granuloma+AA	V	II	III	NO
21	P	LNS	AA only	V	I	I	NO

MVD plus LNS: Microvascular decompression in combination with longitudinal nerve sectioning, **MVD:** Microvascular decompression, **P:** Positive, **N:** Negative, **SCA,** **AICA,** **AA:** Arachnoid adhesion, **PV:** Petrosal vein, **AH:** Arterial hypertension, **CD:** cardiovascular diseases.

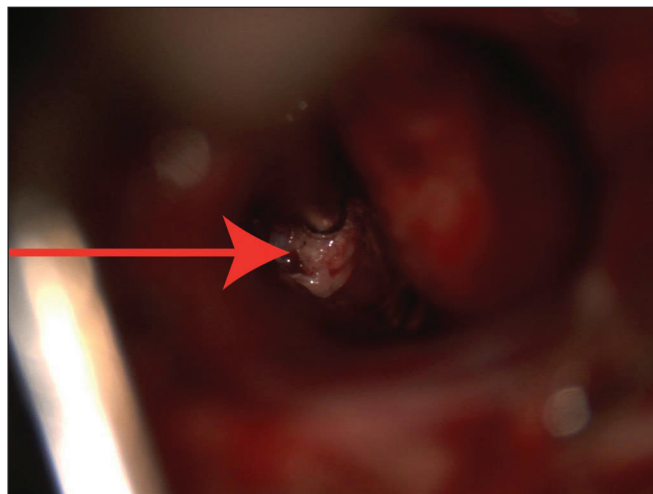
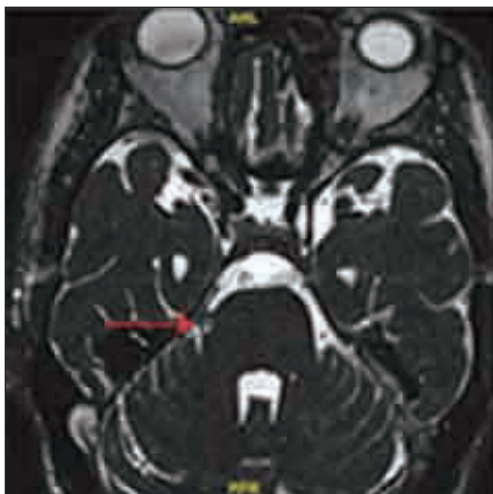


Figure 1: Brain MRI and an intraoperative photograph showing that a Teflon granuloma (arrowhead) compressed the right trigeminal nerve.

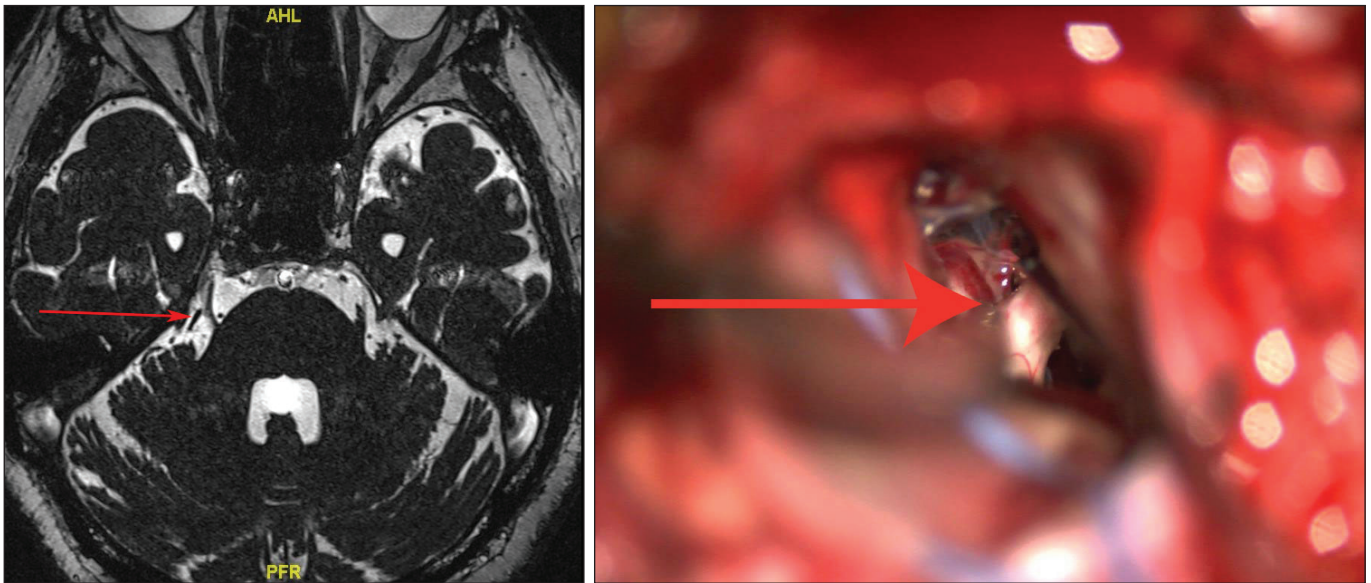


Figure 2: Brain MRI and an intraoperative photograph showing a new defending venous (arrowhead) compression on the right trigeminal nerve.

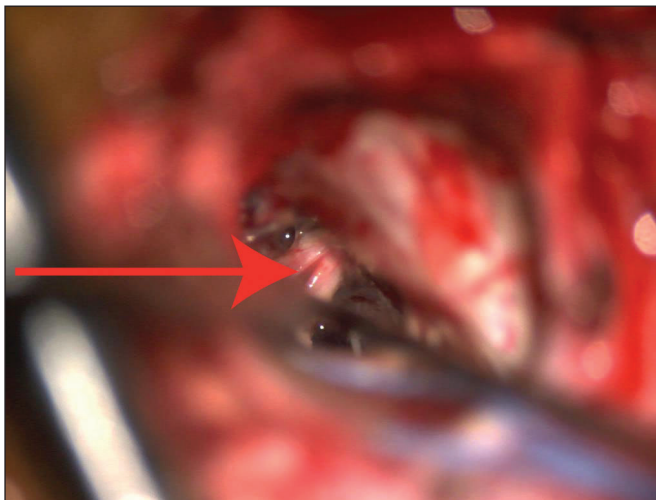


Figure 3: Brain MRI and an intraoperative photograph showing that the right trigeminal nerve fibers were gently combed.

under MRTA. During the surgical procedures, the mass was removed and the nerve fibers were combed gently, as seen in Figure 3.

Follow-up and Outcome Assessments

The MVD plus LNS or LNS only treatments offered a high degree of pain relief for patients suffering from recurrent TN pain. All 21 patients reported immediate pain relief after the surgeries. Among them, 19 cases (90.5%) had a BNI score of I, and 2 cases (9.5%) had a BNI score of II (Table III). At the end of the follow-up period, 15 patients (71.4%) had BNI I, 3 cases (14.3%) had BNI II and 1 case (4.8%) experienced BNI III. The final 2 patients (9.5%) had BNI scores of IV and controlled their pain with medication.

Complications of MVD plus LNS or LNS Only Operations

Complications of the operation included cerebrospinal fluid leakage in 1 patient (4.76%) and bacterial meningitis in 1 patient (4.76%); however, the bacterial meningitis and cerebrospinal fluid leakage were resolved after appropriate treatment. Facial numbness occurred in 21 patients (100%) immediately after surgery and 18 patients (85.7%) still experienced facial numbness at the end of the follow-up period. No patients died, and no sensory deficits or other cranial nerve deficits such as hearing loss were noted (Table IV).

DISCUSSION

MVD is accepted as one of the effective treatments for idiopathic TN (10). Although the long-term pain relief rate of MVD is 71%-84%, not all patients experience recovery after the procedure (5,10,14,24,29,30,34). In fact, some patients experience recurrent TN pain at a recurrence rate of 1- 5% every year (3,4,6,32).

The options for the effective treatment of recurrent TN patients are controversial. Only a few studies have examined the outcome of MVD plus LNS or LNS only. Percutaneous balloon compression, gamma knife surgery, and repeated MVD have previously been reported to treat patients with recurrent TN, but the results were not very satisfactory (2,11,16,31). In our study, almost all patients (19/21, 90.5%) reported pain relief 36.1 months after the procedure, 15 patients (71.4%) reported being pain free (BNI score I), and 4 patients (19.0%) reported pain relief (BNI II-III).

Two possible explanations for the effectiveness of this surgical method were analyzed. One explanation is that the vascular contact was dissected at the REZ of the third cranial nerve (28,31). The other explanation is that the continuity of the axon was destroyed by combing the nerve, not only resulting in a

grade I	No pain, no medication
grade II	Occasional pain, not requiring medication
grade III	Some pain, adequately controlled with medication
grade IV	Some pain, not adequately controlled with medication
grade V	Severe pain/no pain relief

Figure 4: Barrow Neurological Institute (BNI) pain intensity scale score.

Table IV: Complications of MVD Plus LNS or LNS Only

Complication	Cases (%)
mortality	0
CSF leakage	1 (4.76)
Facial numbness	18 (85.7)
Cranial nerve deficit	0
Bacterial meningitis	1 (4.76)
Sensory deficits	0

reduction of the electrical excitability that was being produced by abnormal afferent trigeminal fibers, but causing partial injury to sensory nerves (18-20,36). During our procedure, we found that the operative route was full of arachnoid thickening and adhesions. The arachnoid membrane bound the trigeminal nerve and could not be released by the sharpness of separation alone; we therefore added longitudinal nerve sectioning. Pain disappeared in nine patients after treatment by LNS only, and the effect was significant. Therefore, we thought the technique of MVD plus LNS could be more effective for patients who had previously received several traumatic surgeries. However, trauma to the trigeminal root does not appear to be the mechanism for facial numbness. Facial numbness could be caused by other lesioning techniques, such as BoNT, SRS, PBC or PGR. However, the MVD plus LNS or LNS only techniques can be used by any surgical center where MVD can be performed, even in remote hospitals. Above all, this procedure can be performed in patients without vascular compression.

The causes of recurrent TN were commonly considered to be vascular compression and arachnoid adhesion, followed by Teflon granulomas.

In this study vascular compression involving the following components was observed: vessel loops were observed in 11 cases (50.0%), the superior cerebellar artery was observed in 2 cases (9.5%), the anterior inferior cerebellar artery was observed in 5 cases (23.8%), the petrosal vein was observed in 2 cases (9.5%), and the anterior inferior cerebellar artery combined with the petrosal vein was observed 2 cases (9.5%). According to the records of previous operations for multiple patients, venous compression of the third cranial nerve was located and removed, and patients reported pain relief after the operations. During the procedures in our hospital, Teflon

was found between the third cranial nerve and the new venous compression of the trigeminal nerve. We hypothesize that the new compression is responsible for the return of TN. Vascular compression is mainly caused by progressive blood vessel changes, which is associated with the normal aging process, such as arteriosclerosis. Arachnoid adhesions and thickening, which decrease the cerebellopontine angle area, increase the probability of blood vessels contacting the trigeminal nerve.

A Teflon granuloma, as shown in Figure 2, was found in 1 patient (4.8%), ventral to the trigeminal nerve. As is known, Teflon granulomas occur in 1.1-7.3% of all MVD cases performed in accordance with Jannetta's procedure (7,8,26). They cause pain in 13-50% of recurrent neuralgia patients (1,8,9). The most common giant cell inflammatory responses associated with Teflon applications have been described in orthopedics, maxillofacial surgery, and otolaryngology (13,15,33).

Surgery can induce arachnoid thickening or unusual adhesions, which complicates the anatomical relationship between the cranial nerve and adjacent vascular structures. In our study, arachnoid adhesion was found in almost all patients (20/21, 95.2%). Arachnoid adhesion and thickening reduce the cerebellopontine angle area, increasing the probability of blood vessels contacting the trigeminal nerve. This could help to make a connection between the trigeminal nerve and offending vessels. The pulse through the offending vessels was transmitted to the nerve more easily, and the flow of cerebrospinal fluid or changes in patient position made the pad shift. However, we doubted that the thickening arachnoid bound the trigeminal nerve.

The primary complication of MVD plus LNS or LNS only treatment was facial numbness in this study. The patients had previously received MVD treatment, and after the recurrence of post-operative pain they were also treated with MVD, BoNT, SRS, PBC or PGR. However, pain continued to recur, and they sought pain relief at our institution. With the addition of longitudinal nerve sectioning, we could accurately observe the position of the corresponding nerve bundle during the surgery and then comb the trigeminal nerve. This technique can effectively relieve pain, but it is also one of the causes of post-operative facial numbness. Other operational techniques can also result in pain relief, but these surgical procedures can also cause facial numbness, to some extent. Ko et al. reported that patients treated with internal neurolysis experienced numbness, but the numbness did not obviously affect their quality of life (20). Gao et al. also reported that MVD and LNS resulted in almost complete pain relief and

with few complications (13). In our study, although 6 patients experienced facial numbness prior to the procedure, new facial numbness existed in all patients immediately after the operation and 18 patients (85.7%) still suffered from facial numbness at the end of the follow-up period. This result is believed to be associated with the removal of the Teflon or the combing of the nerve fibers (Table IV).

This study has several limitations. First, all patients were studied retrospectively. This study did not compare the effectiveness, the recurrence rate or the complication rate of different surgical methods, all of which require further study. Second, the sample size was small, and was not enough to conduct a precise analysis. Third, the follow-up period was relatively short. Therefore, larger studies are needed to be conducted over longer periods than 10 years to find a more effective treatment for recurrent TN after multiple procedures.

CONCLUSIONS

The study certifies that vascular compression, arachnoid adhesion and Teflon granulomas were the causes of recurrent trigeminal neuralgia. MVD plus LNS and LNS only are both feasible therapeutic options with good probabilities of success, especially after multiple neurodestructive procedures.

REFERENCES

- Amador N, Pollock BE: Repeat posterior fossa exploration for patients with persistent or recurrent idiopathic trigeminal neuralgia. *Journal of Neurosurgery* 108(5):916-920, 2008
- Bakker NA, Van Dijk JM, Immenga S, Wagemakers M, Metzemaekers JD: Repeat microvascular decompression for recurrent idiopathic trigeminal neuralgia. *J Neurosurg* 121:936-939, 2014
- Barker FG 2nd, Jannetta PJ, Bissonette DJ, Larkins MV, Jho HD: The long-term outcome of microvascular decompression for trigeminal neuralgia. *N Engl J Med* 334:1077-1083, 1996
- Bederson JB, Wilson CB: Evaluation of microvascular decompression and partial sensory rhizotomy in 252 cases of trigeminal neuralgia. *J Neurosurg* 71:359-367, 1989
- Broggi G, Ferroli P, Franzini A, Servello D, Dones I: Microvascular decompression for trigeminal neuralgia: Comments on a series of 250 cases, including 10 patients with multiple sclerosis. *J Neurol Neurosurg Psychiatry* 68(1):59-64, 2000
- Burchiel KJ, Clarke H, Haglund M, Loeser JD: Long-term efficacy of microvascular decompression in trigeminal neuralgia. *J Neurosurg* 69:35-38, 1988
- Capelle HH, Brandis A, Tschann CA, Krauss JK: Treatment of recurrent trigeminal neuralgia. *J Headache Pain* 11(4):339-344, 2010
- Chen J, Lee S, Lui T, Yeh Y, Chen T, Tzaan W: Teflon granuloma after microvascular decompression for trigeminal neuralgia. *Surg Neurol* 53(3):281-287, 2000
- Cho DY, Chang CG, Wang YC, Wang FH, Shen CC, Yang DY: Repeat operations in failed microvascular decompression for trigeminal neuralgia. *Neurosurgery* 35(4):665-669, 1994
- Cruccu G, Gronseth G, Alksne J, Argoff C, Brainin M, Burchiel K, Nurmikko T, Zakrzewska JM; American Academy of Neurology Society; European Federation of Neurological Society: AAN-EFNS guidelines on trigeminal neuralgia management. *Eur J Neurol* 15:1013-1028, 2008
- Du Y, Yang D, Dong X, Du Q, Wang H, Yu W: Percutaneous balloon compression (PBC) of trigeminal ganglion for recurrent trigeminal neuralgia after microvascular decompression (MVD). *Ir J Med Sci* 184:745-751, 2015
- Dubey A, Sung WS, Shaya M, Patwardhan R, Willi B, Smith D, Nanda A: Complications of posterior cranial fossa surgery: An institutional experience of 500 patients. *Surg Neurol* 72(4):369-375, 2009
- Gao X, Qi W, Li M, Zhang J, Cao Y, Ma Z: To study the clinical valuation of different operation methods in treatment primary trigeminal neuralgia by retrosigmoidal approach. *Lin Chung Er Bi Yan Hou Tou Jing Wai Ke Za Zhi* 21(14):643-645, 2007
- Gu W, Zhao W: Microvascular decompression for recurrent trigeminal neuralgia. *J Clin Neurosci* 21(9):1549-1553, 2014
- Harrigan C, Branstetter BF, Snyderman CH, Maroon J: Teflon granuloma in the nasopharynx: A potentially false-positive PET/CT finding. *AJNR Am J Neuroradiol* 26(2):417-420, 2005
- Huang CF, Chiou SY, Wu MF, Tu HT, Liu WS: Gamma Knife surgery for recurrent or residual trigeminal neuralgia after a failed initial procedure. *J Neurosurg* 113:172-177, 2010
- Jannetta PJ: Arterial compression of the trigeminal nerve at the pons in patients with trigeminal neuralgia. *J Neurosurg* 26:159-162, 1967
- Jie H, Xuanchen Z, Deheng L, Kun G, Fengyang X, Xiang C, Xiaoting W, Guangxin Z, Yiqing L: The long-term outcome of nerve combing for trigeminal neuralgia. *Acta Neurochir* 155:1703-1708, 2013
- Kline DG, Hudson AR: Acute injuries of peripheral nerve. In: *JR Y (ed), Neurological Surgery*, 1996
- Ko AL, Ozpinar A, Lee A, Raslan AM, McCartney S, Burchiel KJ: Long-term efficacy and safety of LNS for trigeminal neuralgia without neurovascular compression. *J Neurosurg* 122:1048-1057, 2015
- Manzoni GC, Torelli P: Epidemiology of typical and atypical craniofacial neuralgias. *Neurol Sci* 26 Suppl 2:s65-s67, 2005
- McLaughlin MR, Jannetta PJ, Clyde BL, Subach BR, Comey CH, Resnick DK: Microvascular decompression of cranial nerves: Lessons learned after 4400 operations. *J Neurosurg* 90:1-8, 1999
- Nurmikko TJ, Eldridge PR: Trigeminal neuralgia-pathophysiology, diagnosis and current treatment. *Br J Anaesth* 87:117-132, 2001
- Oesman C, Mooij JJ: Long-term follow-up of microvascular decompression for trigeminal neuralgia. *Skull Base* 21:313-322, 2011
- Olesen J: Headache Classification Committee of the International Headache Society. The International Classification of Headache Disorders, 3rd edition (beta version). *Cephalalgia* 33(9):629-808, 2013
- Premasagar IC, Moss T, Coakham HB: Teflon-induced granuloma follow treatment of trigeminal neuralgia by microvascular decompression. Report of two cases. *J Neurosurg* 87(3):454-457, 1997

27. Rogers CL, Shetter AG, Fiedler JA, Smith KA, Han PP, Speiser BL: Gamma knife radiosurgery for trigeminal neuralgia: The initial experience of The Barrow Neurological Institute. *Int J Radiat Oncol Biol Phys* 47:1013-1019, 2000
28. Sabalys G, Juodzbals G, Wang HL: Aetiology and pathogenesis of trigeminal neuralgia: A comprehensive review. *J Oral Maxillofac Res* 3(4):e2, 2013
29. Sandell T, Eide PK: Effect of microvascular decompression in trigeminal neuralgia patients with or without constant pain. *Neurosurgery* 63:93-99, 2008
30. Sarsam Z, Garcia-Fiñana M, Nurmikko TJ, Varma TR, Eldridge P: The long-term outcome of microvascular decompression for trigeminal neuralgia. *Br J Neurosurg* 24:18-25, 2010
31. Ugwuanyi UC, Kitchen ND: The operative findings in redo microvascular decompression for recurrent trigeminal neuralgia. *British Journal of Neurosurgery* 24(1):26-30, 2010
32. Walchenbach R, Voormolen JH, Hermans J: Microvascular decompression for trigeminal neuralgia: A critical reappraisal. *Clin Neurol Neurosurg* 96:290-295, 1994
33. Yeretsian RA, Blodgett TM, Branstetter BF, Robertsc MM, Meltzer CC: Teflon-induced granuloma: A false-positive finding with PET resolved with combined PET and CT. *AJNR Am J Neuroradiol* 24(6):1164-1166, 2003
34. Zhang H, Lei D, You C, Mao BY, Wu B, Fang Y: The long-term outcome predictors of pure microvascular decompression for primary trigeminal neuralgia. *World Neurosurg* 79:756-762, 2013
35. Zhong J, Li ST, Zhu J, Guan HX, Zhou QM, Jiao W, Ying TT, Yang XS, Zhan WC, Hua XM: A clinical analysis on microvascular decompression surgery in a series of 3000 cases. *J Clin Neurosci* 114:846-851, 2012
36. Zhou X, Liu Y, Yue Z, Luan D, Zhang H, Han J: Comparison of nerve combing and percutaneous radiofrequency thermocoagulation in the treatment for idiopathic trigeminal neuralgia. *Braz J Otorhinolaryngol* 82:574-579, 2016