



DOI: 10.5137/1019-5149.JTN.23058-18.1

Received: 02.03.2018 / Accepted: 09.04.2018

Published Online: 20.04.2018

Turk Neurosurg, 2018

Original Investigation

Comparison of Dorsal Intercostal Artery Perforator Propeller Flaps and Bilateral Rotation Flaps in Reconstruction of Myelomeningocele Defects

Goktekin TENEKECI¹, Yavuz BASTERZI², Sakir UNAL¹, Alper SARI¹, Yavuz DEMIR¹, Celal BAGDATOGLU³, Bahar TASDELEN⁴

¹Mersin University Hospital, Department of Plastic, Reconstructive & Aesthetic Surgery, Mersin, Turkey

²Bahcesehir University, Department of Plastic, Reconstructive & Aesthetic Surgery, Istanbul, Turkey

³Mersin University Hospital, Department of Neurosurgery, Mersin, Turkey

⁴Mersin University Hospital, Department of Biostatistics and Medical Information, Mersin, Turkey

This study has been presented at the 39th National Congress of Turkish Plastic, Reconstructive and Aesthetic Surgery Society, 11-14 October 2017, Antalya, Turkey.

ABSTRACT

AIM: Bilateral rotation flaps are considered the workhorse flaps in reconstruction of myelomeningocele defects. Since the introduction of perforator flaps in the field of reconstructive surgery, perforator flaps have been used increasingly in the reconstruction of various soft tissue defects all over the body because of their appreciated advantages. The aim of this study was to compare the complications and surgical outcomes between bilateral rotation flaps and dorsal intercostal artery perforator (DICAP) flaps in the soft tissue reconstruction of myelomeningocele defects.

MATERIAL and METHODS: Between January 2005 and February 2017, we studied 47 patients who underwent reconstruction of myelomeningocele defects. Patient demographics, operative data, and postoperative data were reviewed retrospectively and are included in the study.

RESULTS: We found no statistically significant differences in patient demographics and surgical complications between these two groups; this may be due to small sample size. With regard to complications—partial flap necrosis, cerebrospinal fluid (CSF) leakage, necessity for reoperation, and wound infection—DICAP propeller flaps were clinically superior to rotation flaps. Partial flap necrosis was associated with CSF leakage and wound infection, and CSF leakage was associated with wound dehiscence.

CONCLUSION: Although surgical outcomes obtained with DICAP propeller flaps were clinically superior to those obtained with rotation flaps, there was no statistically significant difference between the two patient groups. A well-designed comparative study with adequate sample size is needed. Nonetheless, we suggest using DICAP propeller flaps for reconstruction of large myelomeningocele defects.

KEYWORDS: Dorsal intercostal artery perforator flap, Myelomeningocele, Rotation flap, Surgery



Corresponding author: Goktekin TENEKECI

E-mail: dr_tenekeci@hotmail.com

■ INTRODUCTION

Neural tube defects are congenital disorders that affect 1 to 2 of 1000 newborns in the United States (1). Myelomeningoceles may cause paraplegia. Myelomeningoceles must be treated early with a combined operation of neurosurgery and plastic surgery to prevent cerebrospinal fluid (CSF) leakage and enable defect reconstruction (2). Muscle flaps, random-pattern fasciocutaneous flaps (such as rotation flaps), V-Y advancement flaps, and Z-plasties have been used for reconstruction of myelomeningocele defects. Bilateral rotation flaps are considered the workhorse flap for reconstructing myelomeningocele defects. However, since Koshima and Soeda (9) introduced perforator flaps in the field of reconstructive surgery, perforator flaps have been used increasingly in the reconstruction of various soft tissue defects all over the body because of the appreciated advantages such as freedom of flap design, reliability, necessity for a smaller area to be dissected, and improved rates of donor site morbidity. Among the perforator flaps, dorsal intercostal artery perforator (DICAP) propeller flaps appear to be the favorite option because they can be used to reconstruct myelomeningocele defects in every location and provide soft tissue with thickness similar to that of the surrounding tissue.

To the best of our knowledge, no other researchers have compared perforator flaps and random-pattern flaps in the reconstruction of myelomeningocele defects until now. The aim of this study was to compare the complications and surgical outcomes between bilateral rotation flaps and DICAP flaps in the soft tissue reconstruction of myelomeningocele defects.

■ MATERIAL and METHODS

We retrospectively reviewed the reconstruction of 55 myelomeningocele defects with bilateral rotation flaps (Figure 1A-D) and DICAP propeller flaps (Figure 2A-D) between January 2005 and February 2017. We reviewed the patient demographics and operative and postoperative data of 47 of the 55 patients for this study. Of the 47 defects, 28 were reconstructed with rotation flaps (Figure 1 A-D), and the remaining 19 were reconstructed with DICAP propeller flaps (Figure 2 A-D). Defects were no smaller than 5×5 cm in size.

We reviewed the following data: patients' age at operation, preoperative hemoglobin count, postoperative hemoglobin count, difference between preoperative and postoperative hemoglobin counts, postoperative hospitalization period (hospitalization period following operation), and follow-up period, and surgical complications such as wound dehiscence, partial flap necrosis, donor site dehiscence, wound dehiscence at flap recipient site, need for reoperation, CSF leakage, and wound infection.

Relationships between partial flap necrosis and CSF leakage, between partial flap necrosis and wound infection, between CSF leakage and wound dehiscence, and between wound dehiscence and wound infection were assessed statistically, regardless of the reconstructive option used.

Statistical Analysis

The data were processed and analyzed with the Stata/MP 11 statistical package. Normality assumptions of hospitalization, preoperative, and postoperative hemoglobin levels were checked with the Shapiro-Wilk test. These variables were summarized as mean and standard deviation and the change between preoperative and postoperative hemoglobin values was analyzed with the paired t test. The patients who received rotation flaps and those who received DICAP propeller flaps were compared with the independent t test. The relationship between categorical variables was tested with Fisher's exact test, and data were summarized as count (percentage). The level of statistical significance was less than 0.05.

■ RESULTS

The demographic data are outlined in Table I. The preoperative and postoperative hemoglobin counts and the difference between the two (decrease in hemoglobin level during operation) hospitalization period and follow-up period of the patients who received rotation flaps were not significantly different from those of the patients who received DICAP propeller flaps (Table I).

No total flap necrosis occurred in either group. Partial flap necrosis was noted in 6 (21.43%) of the 28 patients who received rotation flaps, and partial (superficial) flap necrosis was noted in 1 (5.26%) of the 19 patients who received DICAP propeller flaps. The rates of partial flap necrosis in the two groups were not significantly different ($p=0.215$; Table II). Of the 6 patients who received rotation flaps and suffered partial necrosis, 4 underwent reconstruction by flap advancement because the necrotic area was very small. In the other 2 patients, split-thickness skin grafts were used because their defects were larger. In the patient with superficial partial necrosis of the DICAP propeller flap, the necrosis was on the distal part of the flap, despite normal bleeding during the follow-up period. This patient had severe hypotension starting from the first hours of the postoperative period and therefore required dopamine administration. However, the severe hypotension could not be relieved, which resulted in hypoperfusion of flap and organ systems, which in turn caused multiple organ failure syndrome and death on postoperative day 14.

Wound dehiscence at the flap recipient site was noted in 4 (14.29%) of the 28 patients who received rotation flaps. Two cases were associated with CSF leakage, one was associated with infection, and no precipitating factor was found for the fourth. On the other hand, wound dehiscence was noted in 3 (15.79%) of the 19 patients who received DICAP propeller flaps. In DICAP propeller flap group, wound dehiscence was accompanied with wound infection in one case while the remaining two was associated with CSF leakage. The rates of wound dehiscence in the two groups were not significantly different ($p=1.000$; Table II). All the wound dehiscences in both groups were reconstructed by primary closure except two, which healed by secondary intention.

CSF leakage was noted in 7 patients (25%) who received rotation flaps. Of these patients, 2 had wound dehiscence

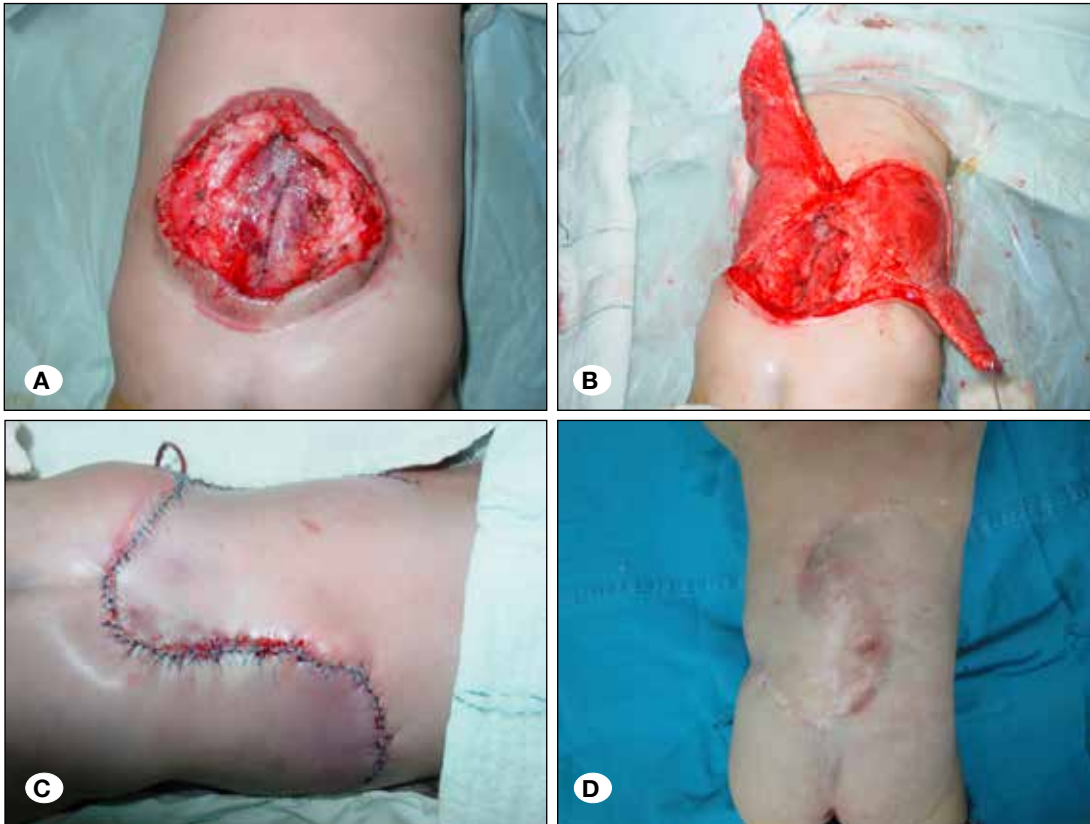


Figure 1:
A) A myelomeningocele defect located over thoracolumbar region measuring 6 x 8 cm is seen.
B) Bilateral rotation flap harvested for soft tissue reconstruction of the defect.
C) Appearance in the early postoperative period.
D) Appearance 1 year after surgery.

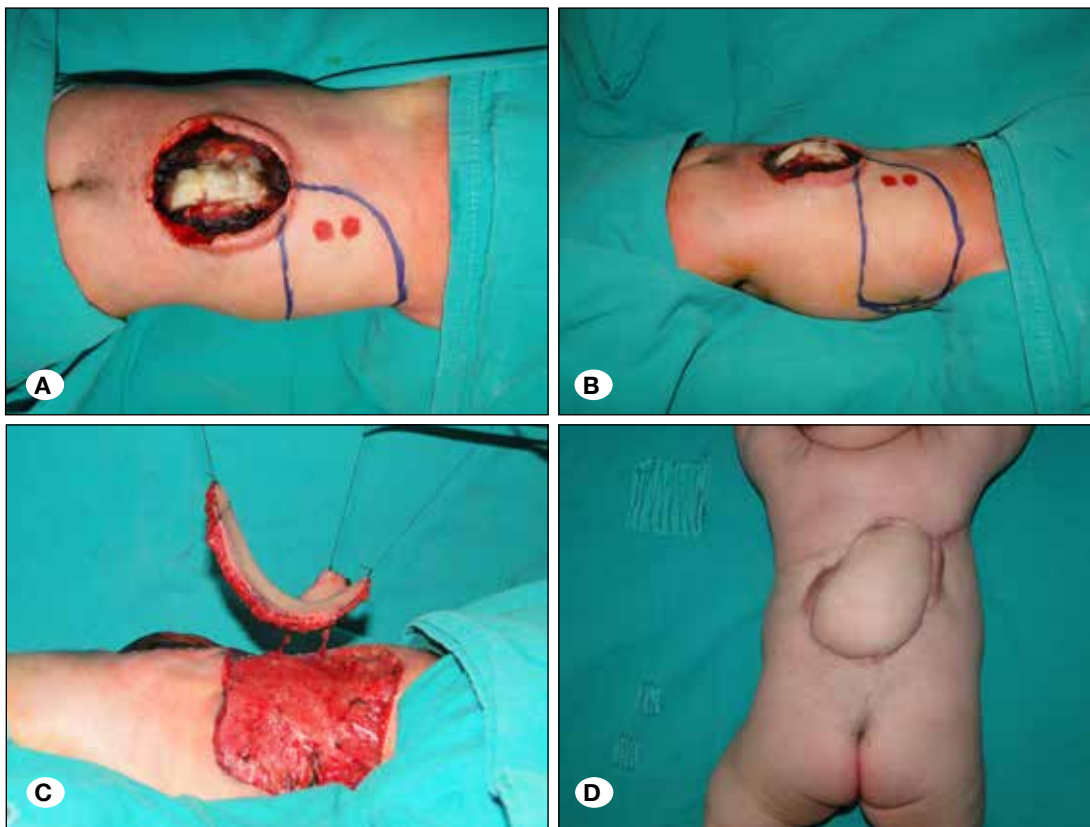


Figure 2:
A) A myelomeningocele defect located over thoracolumbar region measuring 6x7 cm is seen. Reconstruction with dorsal intercostal artery perforator (DICAP) propeller flap is planned.
B) DICAP propeller flap planning, seen from the lateral aspect.
C) Two perforators are dissected off, and the flap is harvested.
D) Appearance at 4 months postoperatively.

Table I: Data Related to Patient Demographics

	Rotation Flap Group (n=28) (Mean)	DICAP Propeller Flap Group (n=19) (Mean)	p
Time of Operation (day)	15.035	3	-
Preoperative Hemoglobin Count (gr/dL)	16.275	15.921	-
Postoperative Hemoglobin Count (gr/dL)	13.289	12.763	-
The difference between preoperative & postoperative hemoglobin count (gr/dL)	2.986	3.158	0.7722
Hospitalization Period (day)	15.750	19.631	0.1104
Follow-up period (day)	212.642	159.736	0.5800

Table II: Comparison of Surgical Complications and Outcome

	Rotation Flap Group (n=28)		Dorsal Intercostal Artery Perforator Propeller Flap Group (n=19)		p
	n	%	n	%	
Total Flap Necrosis	-	-	-	-	-
Partial Flap Necrosis	6	21.43	1	5.26	0.215
Wound Dehiscence	4	14.29	3	15.79	1.000
Cerebrospinal Fluid Leakage	7	25	2	10.53	0.278
Re-operation	10	35.71	4	21.05	0.343
Wound Infection	5	17.86	1	5.26	0.378
Donor Site Dehiscence	1	3.57	2	10.53	0.557

without flap necrosis, whereas 1 had neither flap necrosis nor wound dehiscence. The remaining 4 patients with CSF leakage had partial flap necrosis. On the other hand, CSF leakage was noted in 2 patients (10.53%) who received DICAP propeller flaps. CSF leakage in these two patients was associated with wound dehiscence. The rates of CSF leakage in the two groups were not significantly different ($p=0.278$; Table II).

Donor sites of all rotation flaps and DICAP propeller flaps were reconstructed by primary closure. However, donor site dehiscence was noted in 2 (10.53%) of the 19 DICAP propeller flaps as a result of excessive tension, and primary closure was required later. Among the 28 rotation flaps, donor site dehiscence was noted in 1 (3.57%) and was reconstructed with a split-thickness skin graft. The rates of donor site dehiscence rates in the two groups were not significantly different ($p=0.557$; Table II).

Among the 28 patients who received rotation flaps, complications that necessitated reoperation in the rotation flap group occurred in 10 (35.71%): 6 cases of partial necrosis, 3 of wound dehiscence (of which 2 were secondary to CSF leakage and the other to wound infection), and 1 of donor site dehiscence. Among the 19 patients who received DICAP propeller flaps, in contrast, reoperation was necessary in only 4 (21.05%): 2 cases of wound dehiscence (of which 1 was

secondary to CSF leakage and the other to wound infection) and 2 cases of donor site dehiscence. The reoperation rates in the two groups were not significantly different ($p=0.343$; Table II).

Wound infection was noted in 5 (17.86%) of the 28 patients who received rotation flaps. Of the five wound infections, three were accompanied by partial flap necrosis, one was accompanied by wound dehiscence, and the last one was accompanied by neither partial necrosis nor wound dehiscence. In contrast, of the 19 patients who received DICAP propeller flaps, only 1 (5.26%) had wound infection, which was accompanied by wound dehiscence. The wound infection rates in the two groups were not significantly different ($p=0.378$; Table II).

The relationships between partial flap necrosis and CSF leakage, between partial flap necrosis and wound infection, between CSF leakage and wound dehiscence, and between wound dehiscence and wound infection were assessed statistically regardless of the reconstructive option used. Four out of seven patients with partial flap necrosis, 4 (57.14%) also had CSF leakage; the remaining 3 patients (42.86%) had no CSF leakage. The relationship between partial flap necrosis and CSF leakage was therefore significant ($p=0.018$). Of the 7 patients with partial flap necrosis, 3 (42.86%) also had wound infection (42.86%). Wound infection rate of the 40 patients

without partial flap necrosis was 7.5% (3/40). Partial, only 3 (7.5%) had wound infection. The relationship between partial flap necrosis and wound infection was therefore significant ($p=0.035$). Of the 9 patients with CSF leakage, 4 (44.44%) also had wound dehiscence, whereas of the 38 patients without CSF leakage, only 3 (7.89%) had wound dehiscence. The relationship between CSF leakage and wound dehiscence was therefore significant ($p=0.018$). Of the 6 patients with wound infection, 2 (33.33%) also had wound dehiscence; of the 41 patients without wound infection, 5 (12.20%) had wound dehiscence. Wound infection was therefore not significantly associated with wound dehiscence ($p=0.214$).

■ DISCUSSION

Plastic Surgery and Neurosurgery teams perform a combined operation for reconstruction of the neural tube defect and soft tissue early in the postpartum period (2). Since the introduction of perforator flaps by Koshima and Soeda in 1989, their use in reconstruction of various defects throughout the body, including myelomeningocele defects, has become widespread (2,3,17).

Random-pattern flaps such as rotation-transposition fasciocutaneous flaps (16), bilobed flaps (10), and bilateral V-Y advancement flaps (8) have been the mainstays in the treatment of myelomeningocele defects. However, random-pattern flaps are bound to the flap donor site by their pedicle, which limit their mobility and result in tension over the suture lines. Unlike perforator flaps, random-pattern flaps necessitate extensive dissection, and usually two flaps are needed for reconstruction of myelomeningocele defects. Use of musculocutaneous flaps such as latissimus dorsi flaps (6) have been reported; however, the back muscles are important for ambulation and must be spared (10) because many patients with myelomeningocele are future candidates for being wheelchair users (2).

The goals of ideal reconstruction of myelomeningocele defects include flaps with a reliable blood supply and with minimal tethering of the pedicle, which will minimize the tension of the flap during defect reconstruction and will cover the defect so that the suture lines will not overlap in the midline where the dura is repaired (2). Those goals are fulfilled by local perforator flaps. Soft tissue reconstruction of myelomeningocele defects with local perforator flaps has been reported in several articles. These flaps include DICAP propeller flaps (2,17) and superior gluteal artery perforator flaps (3).

The rates of partial flap necrosis, CSF leakage, reoperation, and wound infection were not different from each other statistically between the two groups of patients because of the small sample size. However, although statistical significance was not reached, DICAP propeller flaps were clinically superior to rotation flaps in those aspects (Table II). Wound dehiscence rates were not different from each other either statistically or clinically (Table II). In contrast, rates of dehiscence at the donor site was higher with DICAP propeller flaps despite statistical significance not being reached (Table II).

Well-vascularized tissue must be transferred over the myelomeningocele defect where the dura is repaired. Therefore,

two-layer closure is the principal goal in reconstruction of myelomeningocele defects. However, when soft tissue reconstruction fails as a result of partial flap necrosis, non-viable tissue on top of the dura repair line cannot prevent CSF leakage, and rates of CSF leakage may be higher in such cases. Our study reveals that partial flap necrosis is frequently accompanied by CSF leakage ($p=0.018$) and that CSF leakage is frequently accompanied by wound dehiscence ($p=0.018$). Continuous CSF leakage results in wound dehiscence, which may necessitate re-repair of the dura suture line and primary suturing of skin edges. Other reasons for wound dehiscence at the flap recipient site may be caused by wound infection or closure of the wound under excessive tension. Partial flap necrosis is frequently accompanied by wound infection ($p=0.035$).

Some of the wound complications seem to have an effect on the formation of some other complications. Therefore, each complication may be interrelated with some other wound complications, and this may prolong the hospitalization period, result in the need for reoperation, increase the mortality or morbidity rate, and increase the health care expenses of affected patients. Postoperative hospitalization periods were not significantly different between the two groups ($p=0.1104$). The hospitalization period for newborns with myelomeningocele is affected not only by the reconstructive technique used but also by the general condition of the newborn and other systemic disorders.

Although the difference between preoperative and postoperative hemoglobin levels is not an exact indicator of the amount of blood loss in the two groups, it is indicative of the amount of blood loss during the operation. The decreases in hemoglobin count in the two groups were not significantly different ($p=0.7722$). Therefore, neither type of flap is superior to the other one in terms of perioperative blood loss.

Perforating vessels are quite small in this newborn population. Handheld Doppler probes are used for localization of the perforators. Flap harvesting must be performed under magnification (operating microscope or loupe magnification larger than 4x), microsurgical instruments must be used during pedicle dissection, and the surgeon must be experienced in perforator flap dissection in the newborn population. Otherwise, unfavorable results may be obtained. Schmidt et al. reported that perforator flaps supplied by the superior gluteal and dorsal intercostal arteries may be unreliable because of the small size of their perforating vessels (15). In our study, the rate of partial flap necrosis rates was lower in patients who received the DICAP propeller flap than in those who received the rotation flap, although the small sample size precluded statistical significance.

Minabe and Harii reported that DICAPs anastomose with perforators of transverse cervical arteries, with horizontal or parascapular branches of the scapular circumflex artery, or with the perforators of the lumbar arteries and the musculocutaneous perforators of the latissimus dorsi (13). Therefore, the upper DICAPs follow a transverse axial course, and lower DICAPs follow a more vertical axial (transverse oblique) course than do the upper perforators (13). On the

basis of this finding, we planned DICAP propeller flaps in a transverse or transverse oblique direction to follow the axial course of perforating vessels. However, the distal edge of rotation flaps does not follow the axial vascular course. This may be one of the reasons why rates of partial flap necrosis are higher with rotation flaps than with DICAP propeller flaps.

A limited further advancement is possible with rotation flaps in case of partial flap necrosis (11). This is applicable in reconstruction of a small necrotic area. However, flap re-advancement may not be adequate for reconstruction of a larger necrotic area. The same is true for DICAP propeller flaps. During the initial operation to harvest DICAP propeller flaps, we perform intramuscular pedicle dissection to prevent kinking of the perforator, to be able to supply the flap with multiple perforators without twisting of the perforators, and to move the flap freely toward the defect (17). Therefore, a major re-advancement of the DICAP propeller flap may not be possible for reconstruction if partial flap necrosis occur.

Feng et al. (4) reported a method of recycling perforator flaps using the same perforator of the previously transferred perforator flap for transferring some part of the skin and soft tissue from the previously transferred perforator flap and mobilizing this recycled perforator flap with an advancement movement or propeller rotation movement. However, because the DICAP perforators are located eccentrically, not centrally, a propeller movement cannot be made on a recycled DICAP flap. Furthermore, because the pedicle length is short in this newborn population, advancement of the recycled DICAP flap will not be efficient for reconstruction of the partial flap loss. Instead, repeated elevation of the DICAP propeller flap and advancement may be helpful for minor partial necrosis.

We believe that re-advancement of rotation flaps and DICAP propeller flaps after partial necrosis can help reconstruct minor defects. However, rotation flaps from both sides of the myelomeningocele defect are used for reconstruction, whereas DICAP propeller flaps are used from one side of the defect. Therefore, dorsal intercostal artery perforators from the opposite side of the defect remain untouched, and another DICAP propeller flap can still be used for reconstruction of the defect in case of major necrosis of the previous DICAP propeller flap.

Chronic pain over the closure site and tethered cord may be a late complication of myelomeningocele closure. Signs and symptoms include back and leg pain, incontinence, change in bladder tone, spasticity of lower extremities, change in motor or sensory level of lower extremities and rapid progression of scoliosis (12). Tethered cord can be caused by traction of the spinal cord and can be worsened by external scarring (5). Scarring or adhesive arachnoiditis in a neural placode that results in adherence to the dura and overlying skin may cause symptomatic tethered cord in patients with myelomeningocele (14).

Duffy et al. (3) reported that the use of superior gluteal artery perforator flaps for reconstruction of myelomeningocele defects may be effective in decreasing the chronic pain at the closure site, and also in diminishing the incidence

of tethered cord as a result of vascularity and durability of flap (3). Because perforator propeller flaps have more robust blood supply, they are more reliable and have more predictable outcomes with than do random-pattern flaps. It is hypothesized that scarring or adhesive arachnoiditis may be less serious in patients in whom myelomeningocele defects are reconstructed with perforator propeller flaps. Recently, Whittemore et al. have reported that long-term follow-up of myelomeningocele defects reconstructed utilizing, superior gluteal artery perforator flaps is not associated with chronic pain (18). 10-30% of children with myelomeningocele defects exhibit symptoms related to tethered cord (7). However, no patient whose myelomeningocele defect was reconstructed with a superior gluteal artery perforator flap exhibited clinical manifestations related to tethered cord (18).

A larger sample and a comparative study with random-pattern flaps is necessary to prove the superiority of perforator flaps in terms of chronic pain and tethered cord in myelomeningocele reconstruction. The results of this study, however, are an indication for reconstructive surgeons that perforator-based flaps may be preferable in the reconstruction of myelomeningocele defects.

■ CONCLUSION

Rates of partial flap necrosis, CSF leakage, re-operation, and wound infection were lower with DICAP propeller flaps. The difference between two groups was clinically significant in those aspects; however, statistical significance was not reached because of the small sample size. Some wound complications can lead to other complications. This is the reason why the safest method with the smoother outcome must be preferred for reconstruction of myelomeningocele defects. The postoperative healing period seems to be smoother with DICAP propeller flaps than with rotation flaps. We, thus, recommend DICAP propeller flaps for reconstruction of large myelomeningocele defects.

■ REFERENCES

1. Au KS, Northrup H, Kirkpatrick TJ, Volcik KA, Fletcher JM, Townsend IT, Blanton SH, Tyerman GH, Villareal G, King TM: Promoter genotype of the platelet derived growth factor receptor-alpha gene shows population stratification but not association with spina bifida meningomyelocele. *Am J Med Genet A* 139: 194-198, 2005
2. Basterzi Y, Tenekeci G: Dorsal intercostal artery perforator propeller flaps: A reliable option in reconstruction of large meningomyelocele defects. *Ann Plast Surg* 76(4):434-437, 2016
3. Duffy FJ, Weprin BE, Swift DM: A new approach to closure of large lumbosacral myelomeningoceles: The superior gluteal artery perforator flap. *Plast Reconstr Surg* 114(7):1864-1868, 2004
4. Feng KM, Hsieh CH, Jeng SF: Free-style puzzle flap: The concept of recycling a perforator flap. *Plast Reconstr Surg* 131(2): 258-263, 2013
5. Fujita Y, Yamamoto H: An experimental study on spinal cord traction effect. *Spine* 14(7):698-705, 1989

6. Hosseinpour M, Forghani S: Primary closure of large thoracolumbar myelomeningocele with bilateral latissimus dorsi flaps. *J Neurosurg Pediatr* 3: 331–333, 2009
7. Hudgins RJ, Gilreath CR: Tethered spinal cord following repair of myelomeningocele. *Neurosurg Focus* 16(2): E7, 2004
8. Komuro Y, Yanai A, Koga Y, Seno H, Inoue M: Bilateral modified V-Y advancement flaps for closing meningomyelocele defects. *Ann Plast Surg* 57(2):195–198, 2006
9. Koshima I, Soeda S: Inferior epigastric artery skin flap without rectus abdominis muscle. *Br J Plast Surg* 42:645, 1989
10. Lapid O, Rosenberg L, Cohen A: Meningomyelocele reconstruction with bilobed flaps. *Br J Plast Surg* 54:570–572, 2001
11. Lin PY, Kuo YR, Tsai YT: A reusable perforator-preserving gluteal artery-based rotation fasciocutaneous flap for pressure sore reconstruction. *Microsurgery* 32(3):189-195, 2012
12. McLone DG, Herman JM, Gabriela AP, Dias L: Tethered cord as a cause of scoliosis in children with myelomeningocele. *Pediatr Neurosurg* 16(1):8-13, 1990
13. Minabe T, Harii K: Dorsal intercostal artery perforator flap: Anatomical study and clinical applications. *Plast Reconstr Surg* 120 (3):681-689, 2007
14. Sarwark JF, Weber DT, Gabrieli AP, McLone DG, Dias L: Tethered cord syndrome in low motor level children with myelomeningocele. *Pediatr Neurosurg* 25:295-301, 1996
15. Schmidt VJ, Horch RE, Dragu A, Beier JP, Eyupoglu IY, Hirsch A, Kneser U: Myocutaneous propeller flap based on the superior gluteal artery (SGA) for closure of large lumbosacral meningomyelocele defects: A case report. *J Plast Reconstr Aesthet Surg* 65:521-524, 2012
16. Selçuk CT, Civelek B, Bozkurt M, Kapi E, Kuvat SV: Reconstruction of large meningomyelocele defects with rotation-transposition fasciocutaneous flaps. *Ann Plast Surg* 69(2):197–202, 2012
17. Tenekeci G, Basterzi Y: Reliability of extended dorsal intercostal artery perforator propeller flaps for reconstruction of large myelomeningocele defects. *J Plast Reconstr Aesthet Surg* 70(1):60-66, 2017
18. Whittemore BA, Swift DM, Weprin BE, Duffy FJ Jr: Long-term follow-up of superior gluteal artery perforator flap closure of large myelomeningoceles. *J Neurosurg Pediatr* 19(3): 333-338, 2017