

Case Report

Central Nervous System Strongyloides Stercoralis. A Case Report

Nezih OKTAR¹, Haluk M. OZER¹, Eren DEMIRTAS²¹Medifema Hospital, Department of Neurosurgery, Izmir, Turkey²Mikro Pathology Laboratory, Neuropathology, Izmir, Turkey**ABSTRACT**

Strongyloidiasis is an infestation caused by the intestinal nematode *Strongyloides stercoralis*. It is potentially fatal in immunocompromised hosts due to its capacity to cause an overwhelming hyperinfestation however infested healthy individuals are usually asymptomatic. Hyperinfestation is extremely rare in the Central Nervous System (CNS) and usually limited to the gastrointestinal tract or lungs. CNS involvement in strongyloidiasis has only been seen in patients with hyperinfestation syndrome and may be fatal when misdiagnosed. In this report, we describe an unusual case of a 13-year-old girl presented with epileptic fits, multiple brain lesions and diagnosed as *Strongyloides stercoralis* infestation. Suitable frontal lesion biopsied and diagnosed as *Strongyloides* infestation and vasculitis. MRI features were totally regressed after the treatment with oral Albendazole for 3 months.

KEYWORDS: *Strongyloides stercoralis*, CNS, Brain, Epilepsy, Albendazole

■ INTRODUCTION

Strongyloidiasis is an infestation caused by the intestinal nematode *Strongyloides stercoralis*. Infested healthy individuals are usually asymptomatic, however, it is potentially fatal in immunocompromised hosts due to its capacity to cause an overwhelming hyperinfestation (15,16,18,21,28). Strongyloidiasis could be missed during routine screening because of low and intermittent larval output in stool and variable manifestations of the symptoms. Severe, complicated *Strongyloides* infestation can lead to bacterial sepsis and meningitis (1,17). Involvement of the central nervous system with acquired immune deficiency syndrome (2,13) or without a correlation of an immunosuppression may also occur (10). Masquerading as cerebral vasculitis (25), granulomatous ependymitis, even as an acute subarachnoid-ventricular hemorrhage (6) mostly diagnosed at post-mortem (13,23).

In this report, we describe an unusual case of a 13-year-old girl presented with epileptic fits and multiple brain lesions and diagnosed as *Strongyloides stercoralis* infestation.

■ CASE REPORT

A 13-year-old girl presented with epileptic fits and multiple brain lesions on MRI.

She had no background history of any disease and epilepsy before. Neurological examination was normal.

On MRI hyperintense multiple contrast-enhancing tumoral lesions with a huge perilesional edema along with right frontal lobe and above corpus callosum were detected (Figure 1, 2A-C). Laboratory and biochemical screening concerning CRP, ESR, Toxoplasmosis tests were all normal. No definite diagnosis was considered pre-operatively based on a radiological report which revealed a multifocal diffuse anaplastic glioma.

An operation was planned to remove one of the suitable subcortical lesion just adjacent to a coronary suture on the right frontal lobe by using an intraoperative US guiding (Figure 3). Intraoperative findings were some subcortical pinkish-gray abnormal lesion without giving a demarcated border from the normal white matter that may also be considered as



Corresponding author: Nezih OKTAR

E-mail: nezih.oktar@gmail.com

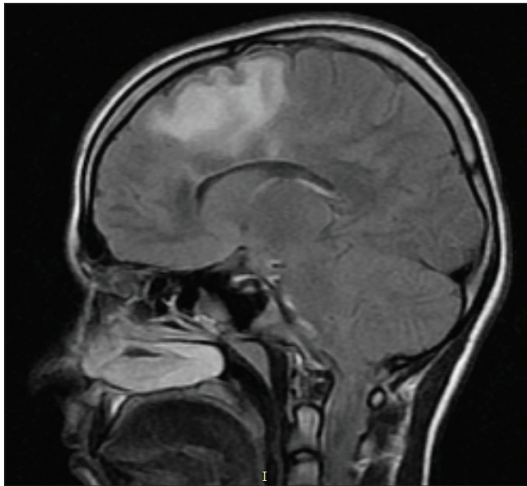


Figure 1: Thirteen-year-old female patient with seizure presentation. On MRI FLAIR sequence shows a huge hyperintense perilesional edema along with right frontal lobe above corpus callosum.

low-grade glioma. Histopathology revealed a granulomatous inflammatory lesion with vasculitis (Figure 4) and a probably a dead silhouette of a parasite (Figure 5). *Strongyloides stercoralis* was the final diagnosis after parasitological consultation and ELISA test.

She was put on Albendazole treatment- 400 mg orally two times a day for 3 months. Monthly MRI controls revealed that all the enhancing tumoral lesions were disappeared. She has got antiepileptic drug of Levetiracetam (Keppra®) (2 times 1000mg/day) for 6 months as well.

The follow-up period was three years and control brain MRI was normal and no antiepileptic treatment at all after a year (Figure 6A-C).

■ DISCUSSION

Strongyloides stercoralis can lead an intestinal infestation in humans and called as Strongyloidiasis. *Strongyloides fulleborni* is one of the other subspecies, though pathogenic in primates, cause only minor infestations in humans (26). Strongyloidiasis

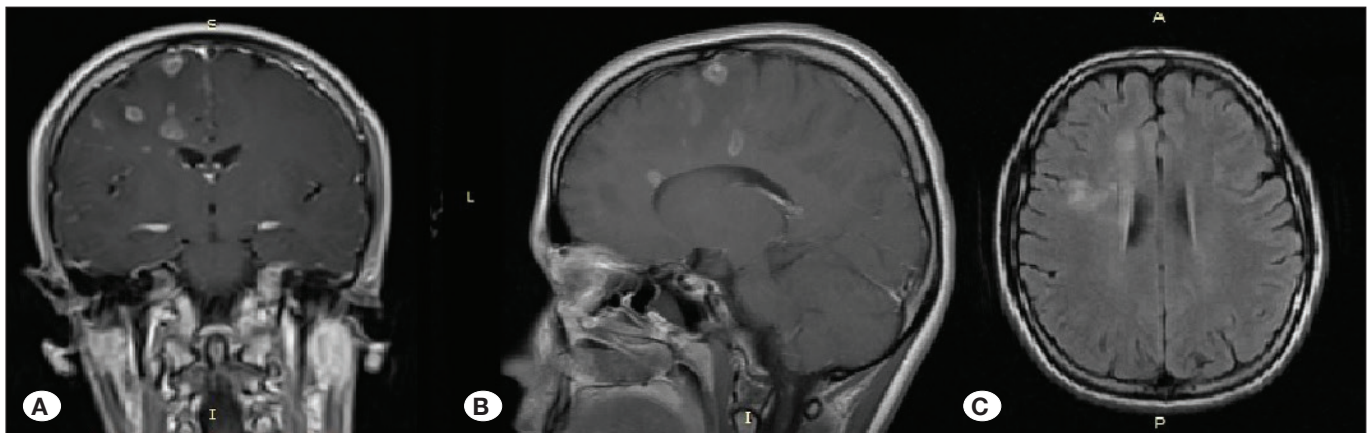


Figure 2: Multiple disseminated intrinsic frontal lesions with contrast enhancement on coronal (A), sagittal (B) and axial (C) MRI scans.

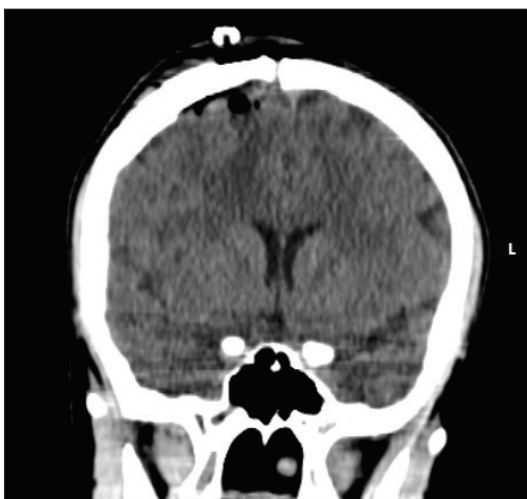


Figure 3: Suitable frontal lesion biopsied. Early post-operative CT-scan.

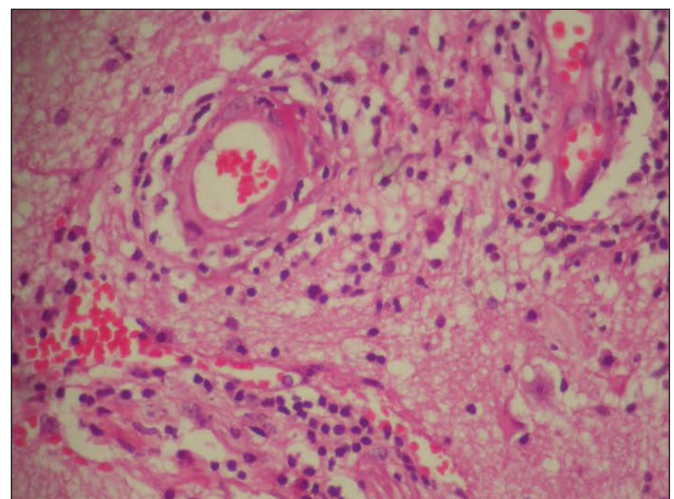


Figure 4: Histopathology revealed a granulomatous inflammatory lesion with vasculitis.

has been restricted to tropical and subtropical regions, but the infestation is increasingly becoming common in other parts of the world, such as Europe, and in the United States (13). On the other hand, a risk of forming hyperinfestation in humans, not only in developing but also in developed world having rising incidence with the appearance of HIV infection and more frequent use of immuno-suppressant medications (3,12,21).

There are three developmental stages of *Strongyloides stercoralis*: infective filariform, rhabditiform, and adult form. After entering a human host, the parasite follows the venous circulation, migrates through the lung alveoli, and eventually tunneling into the small intestine, where it can settle for up to 50 years (24). From this site, worms can be released into the stool or can develop into the filariform state and reinfest the host. Infestation also facilitates co-infestation with other pathologic agents, sometimes resulting in overwhelming bacteremia with dissemination to the CNS and other organs (21). Disseminated *Strongyloides stercoralis* infestation is more likely to occur in the immuno-compromised host (7). Hyperinfestation syndrome, in other words, massive worm

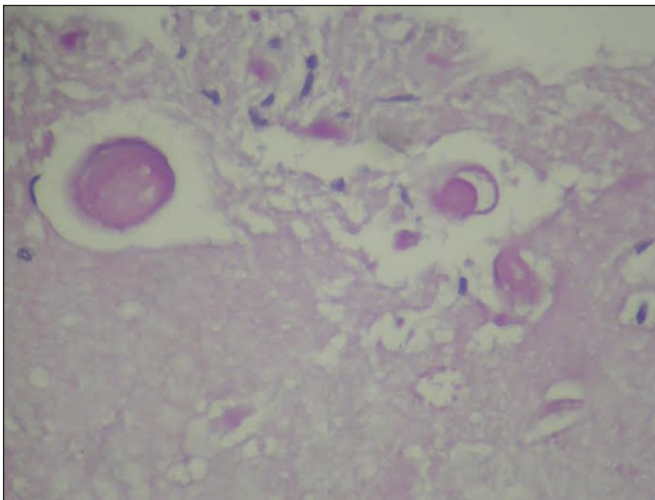


Figure 5: Nematode pieces on histopathological specimen showing probably a dead silhouette of the parasite.

burden, may occur when the usual parasitic life cycle is accelerated (9). Hyperinfestation is extremely rare in the CNS and is usually limited to the gastrointestinal tract or lungs.

Infestation may persist for many years without producing any symptoms in the host. The acute disease generally is limited to the gastrointestinal tract and lungs. On the other hand, the disseminated disease can produce infestation in other organ systems, including the CNS (8,13). Alteration in mental status and meningismus are the most common manifestations of CNS involvement, but penetration of vessel walls can produce a mycotic aneurysm and intracranial hemorrhage, even vasculitis (25). Nearly 30% of brain abscess cases caused by *Escherichia Coli* may produce focal neurological symptoms if bacterial hyper-infection develops (22).

During the primary infestation, serum eosinophilia is common but declines with the dissemination of infestation. Diagnosis can be confirmed by identification of *Strongyloides* rhabditiform larvae in stool, serum, peritoneal fluid or CSF. Until approximately 1 month after initial infestation larvae do not appear in the stool (26). Antibody detection testing should be performed if strongyloidiasis is suspected but not detected by direct identification tests (19, 20). Unfortunately, the antibody detection tests may cross-react with other helminthic and filarial infestations or cannot distinguish between past or present infection, or can also be negative in patients with disseminated infection. Enzyme immunoassay has the highest sensitivity up to 90% of the available antibody tests (19). Real-time PCR for *Strongyloides stercoralis* is available (14).

Neuroimaging is often nonspecific, sometimes atrophy may be prominent in patients with chronic infection (9). Mycotic aneurysms, abscess formation may occur along any vascular distribution usually sparing the extracranial vascular system (11). In our case, multiple contrast-enhancing lesions mimicked a malignant multifocal glioma.

Treatment of choice is using Ivermectin, but thiabendazole, albendazole, and mebendazole are also effective (4). We treated our patient with albendazole. A high mortality rate of nearly 80% can occur in disseminated disease, so early diagnosis and prompt treatment are crucial (5,21).

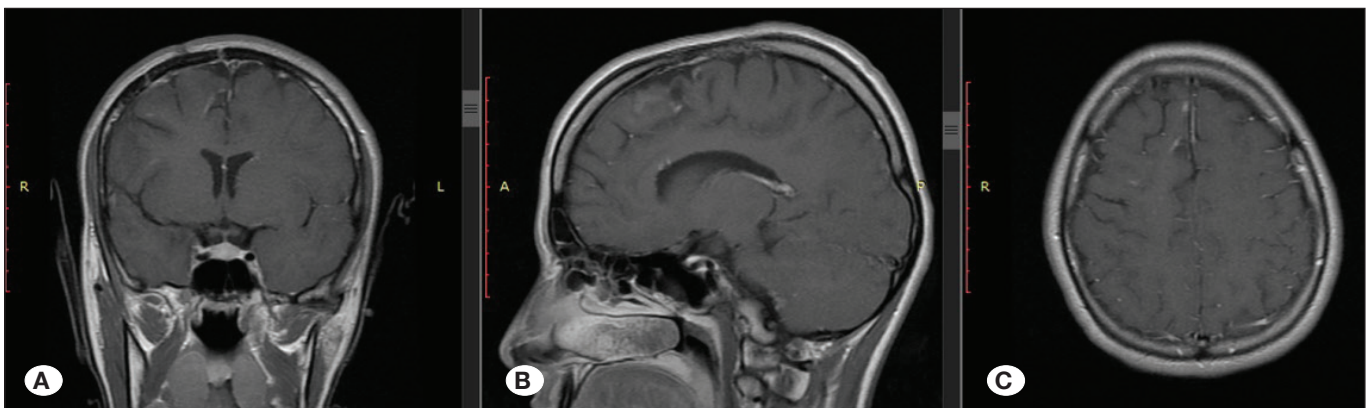


Figure 6: MRI features were totally regressed after treatment with oral albendazole for 3 months. Coronal (A), sagittal (B) and axial (C) MRI scans after a year in follow-up.

■ REFERENCES

- Dokmeci O, Forshay B, Scholand SJ: Worms on the brain: Fatal meningoencephalitis from disseminated strongyloides infection. *Conn Med* 77(1):31-33, 2013
- Dutcher JP, Marcus SL, Tanowitz HB, Wittner M, Fuks JZ, Wiernik PH: Disseminated strongyloidiasis with central nervous system involvement diagnosed antemortem in a patient with acquired immunodeficiency syndrome and Burkitt's lymphoma. *Cancer* 66(11):2417-2420, 1990
- Feely NM, Waghorn DJ, Dexter T, Gallen I, Chiodini P: Strongyloides stercoralis hyperinfection: Difficulties in diagnosis and treatment. *Anaesthesia* 65(3):298-301, 2010
- Gann PH, Neva FA, Gam AA: A randomized trial of single-and two-dose ivermectin versus thiabendazole for treatment of strongyloidiasis. *J Infect Dis* 169:1076-1079, 1994
- Genta RM: Global prevalence of strongyloidiasis: Critical review with epidemiologic insights into the prevention of disseminated disease. *Rev Infect Dis* 11:755-767, 1989
- Giannoulis E, Arvanitakis C, Zaphiropoulos A, Nakos V, Karkavelas G, Haralambidis S: Disseminated strongyloidiasis with uncommon manifestations in Greece. *J Trop Med Hyg* 89(4):171-178, 1986
- Gompels MM, Todd J, Peters BS, et al: Disseminated strongyloidiasis in AIDS: Uncommon but important. *AIDS* 5:329-332, 1991
- Igra-Siegman Y, Kapila R, Sen P, et al: Syndrome of hyperinfection with Strongyloides stercoralis. *Rev Infect Dis* 3:397-407, 1981
- Kothary NN, Muskie JM, Mathur SC: Strongyloides stercoralis hyperinfection. *Radiographics* 19:1077-1081, 1999
- Lahn MM, Staub-Schmidt T, Himy R, Villard O, Molet B, Kremer M, Christmann DJ: Strongyloides stercoralis infection in a non-immunosuppressed tourist with involvement of the central nervous system. *Trop Geogr Med* 46(6):368-370, 1994
- Masdeu JC, Tantulavanich S, Gorelick PP, et al: Brain abscess caused by Strongyloides stercoralis. *Arch Neurol* 39:62-63, 1982
- McLarnon M, Ma P: Brain stem glioma complicated by Strongyloides stercoralis. *Ann Clin Lab Sci* 11:546-549, 1981
- Morgello S, Soifer FM, Lin CS, Wolfe DE: Central nervous system Strongyloides stercoralis in acquired immunodeficiency syndrome: A report of two cases and review of the literature. *Acta Neuropathol* 86(3):285-288, 1993
- Nadir E, Grossman T, Ciobotaro P, Attali M, Barkan D, Bardenstein R, Zimhony O: Real-time PCR for Strongyloides stercoralis-associated meningitis. *Diagnostic Microbiology and Infectious Disease* 84(3):197-199, 2016
- Norsarwany M, Abdelrahman Z, Rahmah N, Ariffin N, Norsyahida A, Madihah B, Zeehaida M: Symptomatic chronic strongyloidiasis in children following treatment for solid organ malignancies: Case reports and literature review. *Trop Biomed* 29(3):479-488, 2012
- Orlent H, Crawley C, Cwynarski K, Dina R, Apperley J: Strongyloidiasis pre and post autologous peripheral blood stem cell transplantation. *Bone Marrow Transplant* 32(1):115-117, 2003
- Owor R, Wamukota WM: A fatal case of strongyloidiasis with Strongyloides larvae in the meninges. *Trans R Soc Trop Med Hyg* 70(5-6):497-499, 1976
- Reyes F, Singh N, Anjuman-Khurram N, Lee J, Chow L: Strongyloides Hyperinfection Syndrome causing fatal meningitis and septicemia by Citrobacter koseri. *ID Cases* 10:102-104, 2017
- Siddiqui AA, Berk SL: Diagnosis of Strongyloides stercoralis infection. *Clin Infect Dis* 33:1040-1047, 2001
- Silva LP, Barcelos IS, Passos-Lima AB, et al: Western blotting using Strongyloides ratti antigen for the detection of IgG antibodies as confirmatory test in human strongyloidiasis. *Mem Inst Oswaldo Cruz* 98:687-691, 2003
- Simpson WG, Gerhardstein DC, Thompson JR: Disseminated Strongyloides stercoralis infection. *South Med J* 86(7):821-825, 1993
- Smallman LA, Young JA, Shortland-Webb WR, et al: Strongyloides stercoralis hyperinfestation syndrome with Escherichia coli meningitis: Report of two cases. *J Clin Pathol* 39:366-370, 1986
- Takayanagui OM, Lofrano MM, Araújo MB, Chimelli L: Detection of Strongyloides stercoralis in the cerebrospinal fluid of a patient with acquired immunodeficiency syndrome. *Neurology* 45(1):193-194, 1995
- Thompson JR, Berger R: Fatal adult respiratory distress syndrome following successful treatment of pulmonary strongyloidiasis. *Chest* 99:772-774, 1991
- Wachter RM, Burke AM, MacGregor RR: Strongyloides stercoralis hyperinfection masquerading as cerebral vasculitis. *Arch Neurol* 41(11):1213-1216, 1984
- Walker MD, Zunt JR: Neuroparasitic Infections: Nematodes. *Semin Neurol* 25(3):252-261, 2005
- Woll F, Gotuzzo E, Montes M: Strongyloides stercoralis infection complicating the central nervous system. *Handb Clin Neurol* 114:229-234, 2013
- Yee B, Chi NW, Hansen LA, Lee RR, U HS, Savides TJ, Vinetz JM: Strongyloides stercoralis hyperinfection syndrome presenting as severe, recurrent gastrointestinal bleeding, leading to a diagnosis of cushing disease. *Am J Trop Med Hyg* 93(4):822-827, 2015