

*Technical Note*

# Inverted (Buried) Reef Knot in Microsurgery - A Technical Note

Nupur Pruthi, Dhaval Gohil, Sampath Somanna

National Institute of Mental Health and Neurosciences (NIMHANS), Department of Neurosurgery, Bangalore, Karnataka, India

To watch the surgical videoclip, please visit <http://turkishneurosurgery.org.tr/images/22646-video.mp4>.**ABSTRACT**

In side to side anastomosis and end to end (one way up) microvascular anastomosis, the back wall of the vessel is sutured first with inverted/buried knots. A common mistake made by surgeons during this step is the formation of a granny knot. In inverted suturing, cut ends of granny knot points inside the vessel lumen and interfere with the suture line. This additional Intraluminal thread may promote foreign body reaction and may act as a nidus for thrombus formation. Hence, this subtle mistake in knot formation may cause immediate and/or delayed anastomosis failure. The purpose of the study was to describe principles of inverted/buried reef knot formation. We describe in detail the methodology to form an inverted reef knot in microsurgery using paracords and a glove model.

**KEYWORDS:** Inverted knot, Buried knot, Reef knot, Microvascular anastomosis, Knot

**■ INTRODUCTION**

Microvascular anastomosis is a technically demanding procedure. It is evident from literature (including first author's previous study) that the delayed patency rate of an anastomosis is lower than its immediate patency rate (8, 9). Delayed anastomotic failure is also well documented in reconstructive surgery literature (5,6).

A frequently overlooked technical mistake in microsurgery is formation of a granny knot (2). It is a consequence of subtle changes in thread directions while making a knot. The cut ends of a granny knot do not lie perpendicular to the suture line and interfere with the adjacent sutures (Figure 1). In end to end (one way up technique) and side to side anastomosis, back wall of the vessels are approximated first with inverted knots (1). Here, a knot is formed beneath the back wall (buried/inverted). A cut end of an inverted 'granny' knot points inside the vessel lumen and fails to get buried (Figure 2A, B). It is well documented in literature that an intra-luminal thread promotes foreign body reaction and thrombus formation (3,7,10). Another disadvantage of a granny knot is that it is unstable and tends to slip under tension (4).

An inverted Reef knot is a possible solution to these problems. The cut ends of the reef knot lie perpendicular to suture line and do not project into the vessel lumen. Moreover, reef knot is more stable than a granny knot (4,9).

**■ TECHNIQUE**

A model was created using two different colored paracords. Both the cords were fixed (tied) at one end. The blue paracord was assumed to be the short end and the maroon paracord was assumed to be the long end (similar to the short and long ends of the suture used in microsurgery). The combinations of blue and maroon cord movements which resulted in formation of an inverted reef knot were noted (Video).

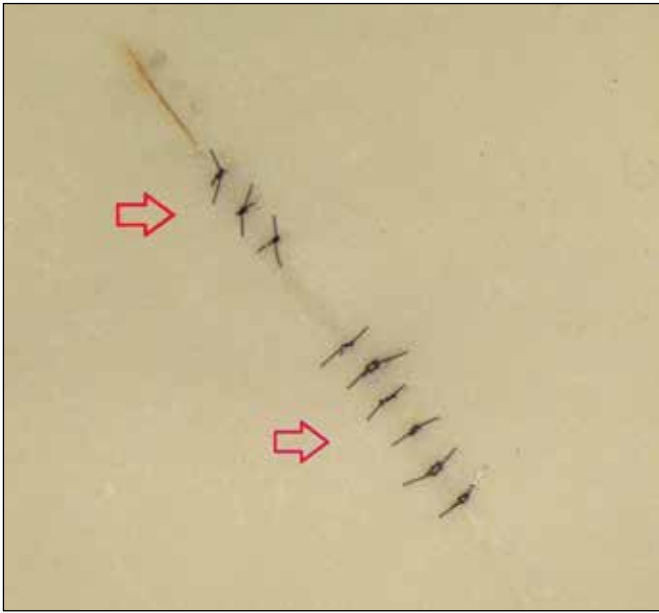
Same combination of movements were replicated in a standard glove model using 9-0 nylon thread under microscope using (10X and 16X) magnification.

Note: Figures and explanations are given with reference to a right handed surgeon. For a left handed surgeon, it is advised to view the figures with the help of a mirror.

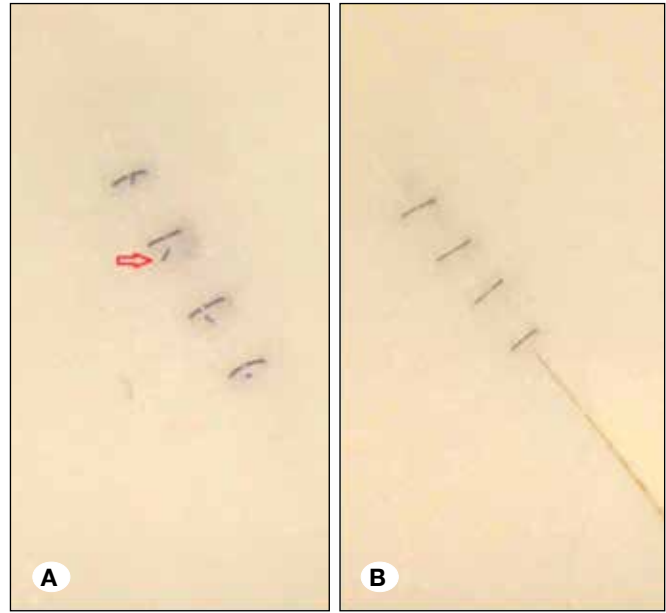


Corresponding author: Nupur PRUTHI

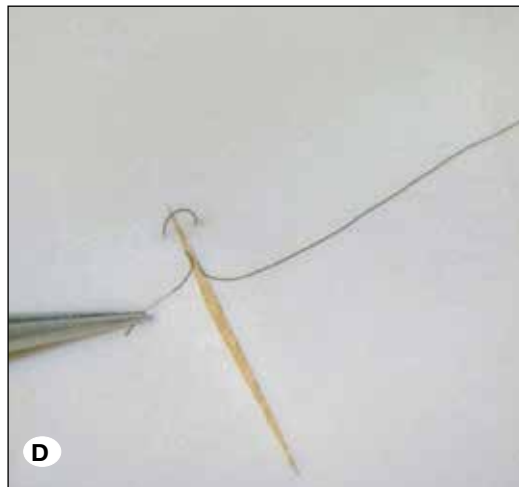

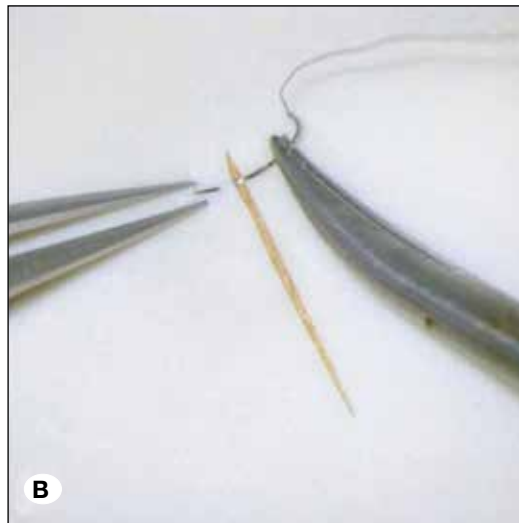
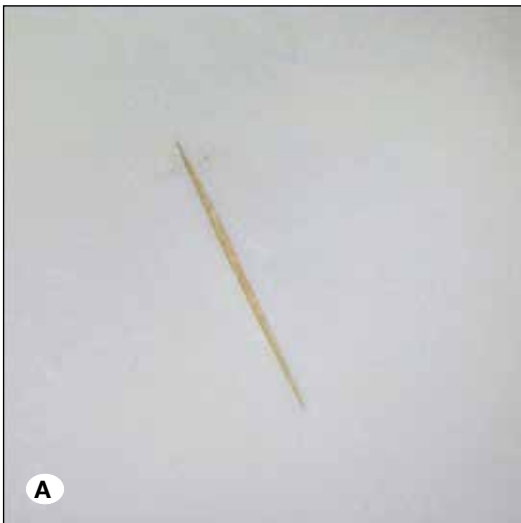
E-mail: pruthi\_nupur@yahoo.co.in



**Figure 1:** Regular knots in glove model (magnification- 25X) Granny knots (top arrow) and reef knots (bottom arrow).



**Figure 2A, B:** Inverted knots in glove model (magnification- 25X): **A)** granny knots (arrow denotes pointing cut end of knot), **B)** reef knots.



**Figure 3A-D:** (magnification- 16X) Inverted suturing in glove model for right handed surgeon (Taking bites): **A)** glove surface is considered as back wall of blood vessel, **B)** outside-in bite, **C)** inside-out bite, **D)** short end and long end of thread.

It is sincerely advised that the surgeon/trainee sits with a pair of different colored paracords and/or a glove model (under microscope) to understand the steps.

#### Taking Bites:

For the first bite, the needle is passed from outside to inside on the left side vessel end. The thread is pulled leaving a small short end. The second bite is then taken in an inside to outside manner on the right side vessel end (Figure 3A-D).

#### First Throw:

**Step 1:** For an inverted knot, long end of the thread lies towards the right side and the short end towards the left side of the surgeon (Figure 4A). The long end is held with the left hand instrument at a length approximately three times the length of the short end (Figure 4B)

**Step 2:** Loop formation for the first throw - With the long end of the thread being held in the left hand instrument, hold another instrument in the right hand and place it at the far side of the long end of the thread, pointing towards the short


end (Figure 4C). Make a single loop around this right hand instrument with the left hand such that the remaining part of the long end points towards the surgeon (Figure 4D).

**Step 3:** Catch and cross: Having formed the loop around the right hand instrument, catch the tip of the short end of the thread (Figure 4E). Cross the long and short ends (Figure 4F). This completes the first throw.

**Step 4:** After completion of the first throw, the long end of the thread is handed over from the left side instrument to the right side instrument (Figure 5A, B).

#### Second Throw:

**Step 5:** Loop formation for the second throw: The long end of the thread being held with the right side instrument, place the left side instrument at the far side of the long end of the thread, pointing towards the short end (Figure 6A). Make a single loop around this left hand instrument such that remaining part of the long end of the thread points towards the surgeon (Figure 6B).



**Figure 4A-F:** (magnification- 10X) First throw of inverted reef knot formation (Note- in 'A' short end of thread is fixed to glove with the help of a tape. It is just to indicate that it lies on left side of the surgeon).


**Step 6: Catch and cross-** Having formed the loop around the left hand instrument, catch the tip of the short end of the thread (Figure 6C). Cross the long and the short end (Figure 6D). Cut the short and the long ends. This completes the formation of an inverted reef knot (Figure 6E).

The pins holding the glove in place are removed. Glove surface is then turned upside down. Under high magnification (25X),


direction of the cut ends is observed (perpendicular to suture line) (Figure 6F).

■ **CONCLUSION**

We have developed a standard method to make inverted/buried reef knot. To the best of our knowledge this is the first work that explains in detail the methodology to make an inverted reef knot in microsurgery.



**Figure 5: A)** Long end of thread is held in left hand instrument after completion of first throw (Note short end of thread is fixed to glove with the help of a tape. It is just to indicate that it lies on right side of the surgeon), **B)** Thread handed over to right hand instrument (magnification- 10X).



**Figure 6A-F:** Second throw of inverted reef knot formation (magnification- 10X). **Note:** in 'E'- suture loop after formation of inverted reef knot; Note that there is no cut end pointing on glove surface (here glove surface considered as back wall of blood vessel). In 'F'- glove turned upside down to study the knot (magnification 25X); Note that the direction of cut ends is perpendicular to suture line .

## ■ REFERENCES

1. Acland RD, Sabapathy SR: One Way up Anastomosis. Acland's Practice Manual for Microvascular Surgery. 3rd ed. Indian Society for Surgery of the Hand, 2008:81-83
2. Avoine X, Lussier B, Brailovsk Vi, Inaekyan K, and Beauchamp G: Evaluation of the effect of 4 types of knots on the mechanical properties of 4 types of suture material used in small animal practice. *Can J Vet Res* 80(2):162-170, 2016
3. Fried MP, Caminear DS, Sloman-Moll ER: The efficacy of absorbable suture for microvascular anastomosis. *Arch Otolaryngol Head Neck Surg* 116(9):1051-1054, 1990
4. Johnson A, Stulting R: Knot-Tying principles and techniques. In: Marian SM (ed). *Ophthalmic Microsurgical Suturing Techniques*. New York: Springer-Verlag, 2007:21-28
5. Lidman D, Daniel RK: Evaluation of clinical microvascular anastomoses-reasons for failure. *Annals of Plastic Surgery* 6(3):215-223, 1981
6. Nahabedian MY, Momen B, Manson PN: Factors associated with anastomotic failure after microvascular reconstruction of the breast. *Plastic and Reconstructive Surgery* 114(1):74-82, 2004
7. Ozer F, Nisanci M, Tas C, Rajadas J, Alhan D, Bozkurt Y, Gunal A, Demirtas S, Isik S: Sutureless microvascular anastomosis with the aid of heparin loaded poloxamer 407. *Journal of Plastic, Reconstructive and Aesthetic Surgery* 70(2):267-273, 2017
8. Pruthi N, Sarma P, Pandey P: Training in micro-vascular anastomosis using rat femoral vessels: Comparison of immediate and delayed patency rates. *Turkish Neurosurgery* 28(1):56-61, 2018
9. Radad K, El-Shazly M: Clinical and pathological assessment of different suture techniques for microvascular anastomosis in rat femoral artery. *Journal of Veterinary Science* 8(3):269-273, 2007
10. Thiede A, Lütjohann K, Beck C, Blunck F: Absorbable and nonabsorbable sutures in microsurgery: Standardized comparable studies in rats. *Journal of Microsurgery* 1(3):216-222, 1979