

Change of Sagittal Spinopelvic Parameters after Selective and Non-Selective Fusion in Lenke Type 1 Adolescent Idiopathic Scoliosis Patients

Deniz KARGIN, Ozgur Ismail TURK, Akif ALBAYRAK, Ilhan Avni BAYHAN, Mehmet Akif KAYGUSUZ

University of Health Sciences, Baltalimani Bone Diseases Education and Research Hospital, Department of Orthopedics, Istanbul, Turkey

ABSTRACT

AIM: Lenke Type 1, the main thoracic curve type, is the most common spinal curve pattern in adolescent idiopathic scoliosis (AIS). The aim of this study was to compare the postoperative changes of both sagittal spinal and spinopelvic parameters in patients with Lenke Type 1 AIS who underwent selective and non-selective fusion surgery.

MATERIAL and METHODS: We conducted a retrospective study among 53 Lenke Type 1 AIS patients who underwent corrective surgery at our centre between 2006 and 2012. Patients were classified as group 1 if they underwent selective surgery and as group 2 if they underwent non-selective surgery. Surgical results of preoperative and postoperative sagittal and spinopelvic measurements, pelvic tilt (PT), pelvic incidence (PI), sacral slope (SS), lumbar lordosis (LL) and thoracic kyphosis (TK) values were analysed using the SURGIMAP® Software (Nemaris Inc. USA) measurement system.

RESULTS: In both groups, a comparison of pre- and postoperative sagittal spinal parameters did not show a statistically significant difference. In both groups, pre- and postoperative measurements of LL and TK did not show a statistically significant difference.

CONCLUSION: After selective and non-selective surgery, sagittal spinal and spinopelvic parameters are not affected in the middle term. We think that the long-term studies to be done in this regard will increasingly require the necessity of keeping the pelvis in mind while evaluating the sagittal plan in AIS surgery.

KEYWORDS: Adolescent idiopathic scoliosis, Lenke Type 1, Sagittal spinal and spinopelvic parameters

INTRODUCTION

Lenke Type I, the main thoracic curve type, is the most common spinal curve pattern in adolescent idiopathic scoliosis (AIS) (10). According to Lenke, selective fusion is the preferred treatment in Type 1 scoliosis. However, non-selective fusion can also be required in some patients (7). Surgical procedures correct the deformity, in both the coronal and sagittal planes. Since scoliosis is a 3-dimensional deformity, in not only the coronal but also the spinal plane, deformity correction is important.

In sagittal plane evaluations, thoracic kyphosis (TK), lumbar lordosis (LL), sagittal vertical axis (SVA), and sagittal

spinopelvic parameters, such as pelvic tilt (PT), pelvic incidence (PI) and sacral slope (SS) can be used (1). Studies in the literature about PT, PI and SS are gaining popularity especially with both spine and hip surgeons. We conducted this study to evaluate whether these parameters are affected depending on fusion types in Lenke Type 1 scoliosis.

The aim of this study was to compare the changes in sagittal spinal and spinopelvic parameters in patients with Lenke Type 1 AIS who underwent selective and non-selective fusion surgery compared with the changes observed in the preoperative period.



Corresponding author: Deniz KARGIN

E-mail: kargn75@yahoo.com

■ MATERIAL and METHODS

Institutional Review Board approval was obtained before initiation of this study. We conducted a retrospective archive scan of all AIS patients who had undergone scoliosis surgery from 2006–2012 in our hospital. As a result of the review, the records of 204 patients with Lenke Type 1 AIS were identified. Patients who had complete files, both preoperative and postoperative scoliosis x-rays and those who had adequate follow-up for at least 24 months were identified from logs. In addition, patients who had not undergone spinal surgery before and only patients who had posterior screw instrumentation were included in the study. After examining postoperative x-rays and operative notes of 53 patients according to these criteria, two groups were assigned as patients who underwent selective surgery (group 1, n=21) and those who underwent non-selective surgery (group 2, n=32).

Preoperative and postoperative sagittal spinal and spinopelvic parameters were measured using the SURGIMAP® (Nemaris Inc. USA) (<https://www.surgimap.com/>) measurement system. Measurements of PT, PI, SS, TK and LL were assessed on the lateral orthoroentgenogram. The TK value was determined by measuring the Cobb angle between T5 and T12. The LL value was determined by measuring the Cobb angle between L1 and S1. The PI, PT and SS were measured as the angle between the vertical line of the sacral plate and the line connecting the midpoint of the sacral plate to the midpoint of the bilateral femoral head centre, the angle between the plumb line and the line connecting the midpoint of the sacral plate with the midpoint of the bilateral femoral head centre and the angle between the sacral plate and the horizontal line, respectively (Figure 1). Preoperative and postoperative spinopelvic measurements of all patients are listed in Table I.

For the statistical analysis of obtained values, a Kolmogorov-Smirnov test was performed to test for normality. A paired sample t-test was used for the pre-postoperative evaluation and an independent sample t-test was used for intergroup evaluation. $p < 0.05$ was considered significant.

■ RESULTS

In group 1, 17 (80%) patients were female and 4 (20%) were male and in group 2, 23 (71%) patients were female and 9 (29%) were male. The mean age of the patients was 15.50 ± 2.8 years in group 1 and 15.23 ± 2.8 years in group 2. The mean follow-up period was 85 months in group 1, and 72 months in group 2 (Table II).

The mean values of PT, PI, SS, LL and TK preoperatively were $11^\circ \pm 9^\circ$, $53.62^\circ \pm 16^\circ$, $42.6^\circ \pm 8^\circ$, $60^\circ \pm 16^\circ$, $22.2^\circ \pm 9^\circ$ in group 1 and $9.9^\circ \pm 12^\circ$, $47.7^\circ \pm 16^\circ$, $38^\circ \pm 9^\circ$, $55.6^\circ \pm 11^\circ$ and $22.3^\circ \pm 13^\circ$ in group 2, respectively. Postoperative mean values in group 1 were $10.6^\circ \pm 8^\circ$, $45.8^\circ \pm 18^\circ$, $37.5^\circ \pm 11^\circ$, $54.8^\circ \pm 11^\circ$, $20.5^\circ \pm 10^\circ$ and $11.9^\circ \pm 8^\circ$, $48.3^\circ \pm 12^\circ$, $36.3^\circ \pm 8^\circ$, $53.2^\circ \pm 8^\circ$ and $17.8^\circ \pm 6^\circ$ in group 2, respectively (Table III).

When the whole patient group was evaluated together, preoperative mean values were $10.3^\circ \pm 11^\circ$, $50^\circ \pm 16^\circ$, $39.8^\circ \pm 9^\circ$,

$57.5^\circ \pm 13^\circ$ and $22.3^\circ \pm 12^\circ$, while the postoperative values were $11.4^\circ \pm 9^\circ$, $47.3^\circ \pm 15^\circ$, $36.8^\circ \pm 9^\circ$, $54^\circ \pm 9^\circ$ and $20.8^\circ \pm 8^\circ$.

In both groups, comparison of pre- and postoperative sagittal spinal parameters did not show any statistically significant difference (PT, PI and SS, respectively). Although LL showed a decrease in the postoperative follow-up period in both groups, it was not statistically significant (group 1; $p=0.1$ and group 2; $p=0.2$). Also, TK was slightly lower than normal values in the non-selective group (17.8°), but the statistical change was not significant ($p=0.6$). The mean TK in the selective group remained at approximately the same level in the preoperative (22.2°) and postoperative measurements (20.5°) ($p=0.3$). In terms of LL and TK, there was no statistically significant difference between the groups in both preoperative and postoperative evaluations (Figure 2A-D; 3A-D).

When all Lenke Type 1 patients were compared preoperative-postoperative, there was no statistically significant difference regarding both PT and PI measurements, but the mean SS showed a decrease with a low statistical significance ($p=0.04$). In contrast, the means of TK and LL did not change significantly.

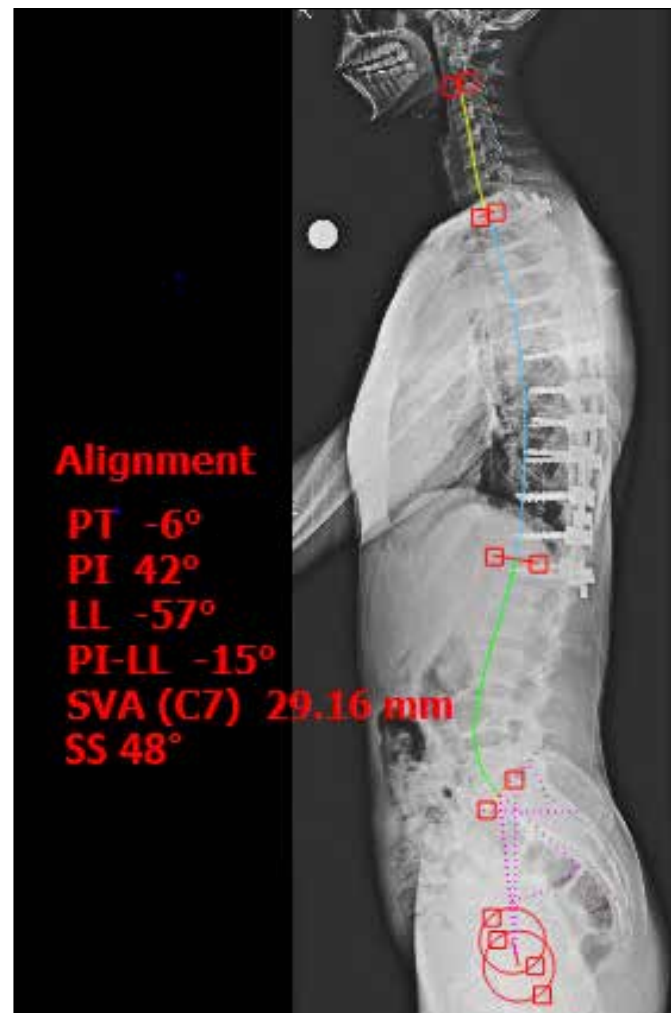


Figure 1: Sagittal spinopelvic parameters measurements.

■ DISCUSSION

One of the main aims of surgical treatment of AIS is to provide coronal and sagittal balance. Therefore, it is not only important to ensure coronal but also sagittal balance. Sagittal balance can be evaluated with local (cervical lordosis, TK, LL) and global (SVA) parameters. In the current literature, spinopelvic

parameters are also gaining popularity for the sagittal balance evaluation (1).

Duval-Beaupere et al. (4) described the association between spinopelvic parameters as $PI = PT + SS$ and called $Pi < 44$ low, 44-62 medium and > 62 high. This relationship between PI and other parameters according to measurements we

Table I: All Patients' Demographic and Measurements Data

	Preoperative			Postoperative		
	PT	PI	SS	PT*	PI*	SS*
S 1	17	52	36	11	51	41
S 2	-2	30	32	0	31	31
S 3	8	35	27	10	38	28
S 4	26	81	55	23	69	46
S 5	18	58	40	16	66	50
S 6	24	85	61	15	51	36
S 7	9	52	43	20	59	39
S 8	24	68	44	10	30	20
S 9	15	59	44	21	53	33
S 10	1	47	46	4	45	40
S 11	-2	30	32	-1	33	34
S 12	1	35	34	0	12	12
S 13	26	81	55	4	34	30
S 14	15	59	44	12	69	49
S 15	11	65	54	17	1	39
S 16	12	53	40	17	53	35
S 17	13	55	42	21	48	27
S 18	17	65	47	14	68	54
S 19	-6	36	42	-10	35	45
S 20	4	40	36	4	45	42
S 21	0	40	41	15	72	57
NS 1	26	60	34	22	64	43
NS 2	18	65	48	-7	35	42
NS 3	-1	34	36	26	62	36
NS 4	10	42	33	7	41	34
NS 5	16	56	39	6	47	40
NS 6	-2	46	48	6	39	32
NS 7	1	25	24	3	31	28
NS 8	21	66	45	17	62	45
NS 9	1	35	34	15	49	34
NS 10	-2	22	24	16	31	15
NS 11	29	71	42	16	45	28
NS 12	3	36	33	4	38	34
NS 13	16	63	47	24	72	48
NS 14	7	33	26	8	40	32
NS 15	0	28	28	-2	30	32
NS 16	20	56	35	24	59	34
NS 17	-37	6	44	1	31	30
NS 18	11	54	43	21	57	36
NS 19	5	39	34	13	47	34
NS 20	18	69	51	12	61	50
NS 21	25	79	55	17	63	46
NS 22	25	71	46	27	62	35
NS 23	17	62	45	5	53	49
NS 24	4	37	33	8	36	28
NS 25	8	50	42	12	53	41
NS 26	13	64	51	18	53	35
NS 27	7	38	32	6	42	36
NS 28	10	34	24	11	40	29
NS 29	16	50	34	15	47	32
NS 30	5	41	36	10	44	35
NS 31	26	48	23	2	39	37
NS 32	1	49	48	19	73	54

Table II: Groups' Demographic Data

	n	Females	Males	Mean age	Total Follow up
Group 1	21	17	4	22.63 years	85 months
Group 2	32	23	9	21.25 years	72 months

Table III: Preoperative and Postoperative Mean Sagittal Spinopelvic Parameters

Group 1	PT	PI	SS	LL	TK
Preoperative	11°±9	53.62°±16	42.6°±8	60°±16	22.2°±9
Postoperative	10.6°±8	45.8°±18	37.5°±11	54.8°±11	20.5°±10
Group 2					
Preoperative	9.9°±12	47.7°±16	38°±9	55.6°±11	22.3°±13
Postoperative	11.9°±8	48.3°±12	36.3°±8	53.2°±8	17.8°±6
TOTAL					
Preoperative	10.3°±11	50°±16°	39.8°±9	57.5°±13	22.3°±12
Postoperative	11.4°±9	47.3°±15	36.8°±9	54°±9	20.8°±8

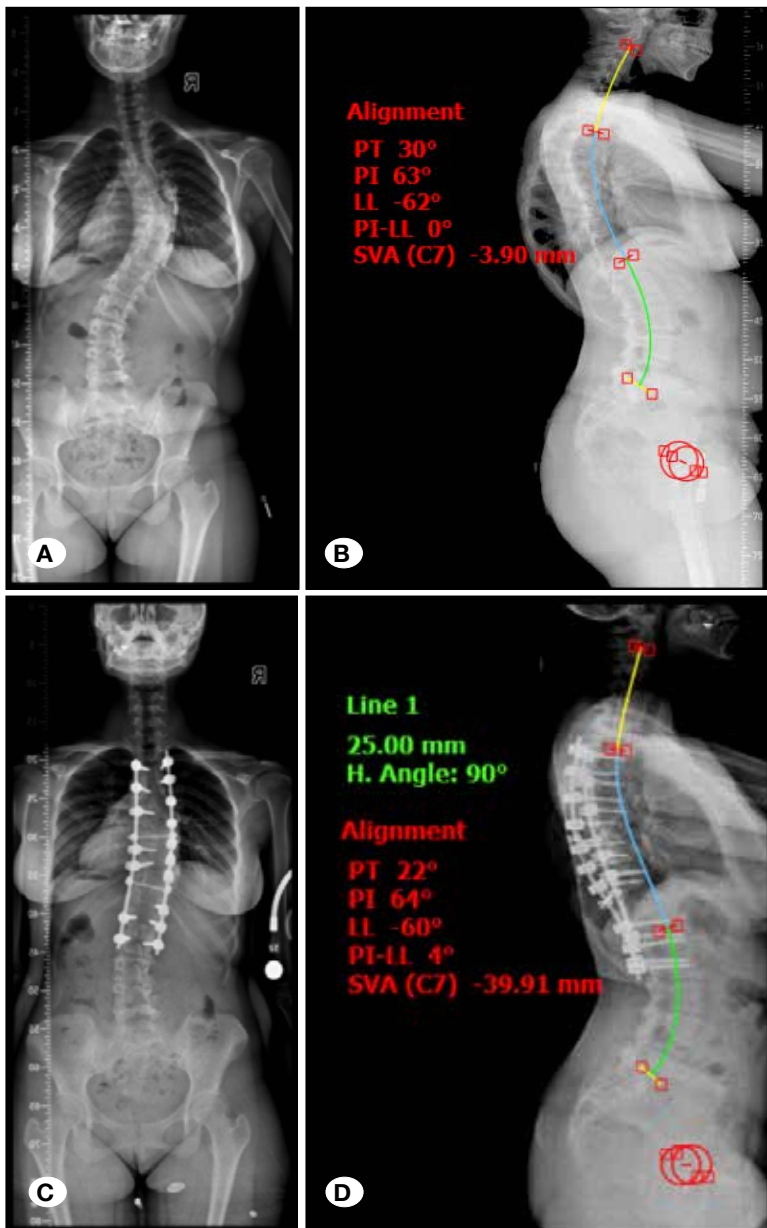


Figure 2: Non-selective Group preoperative **A,B)** postoperative, **C,D)** sagittal spinopelvic parameters.

made was seen in both groups of patients. Also, the PI values of both groups were in the middle group according to the evaluations made by Duval-Beaupere et al. (group 1=53.6°, group 2=47.7°).

Upasani et al. (14), who compared sagittal parameters with the normal population in AIS patients, reported that TK was mainly affected in AIS patients and TK was lower in thoracic curvatures. They stated that in AIS, PI was higher than normal in adolescents close to adulthood. In contrast, Legaye et al. (8) showed that PI was not different in these patients compared with that in the normal population. When the averages of both groups of our patients were evaluated, the PI average was

found to be 50° and remained within the same limits as the range for the normal population.

Investigations of sagittal spinopelvic parameters among Lenke types are gaining interest (5,6,13,15). In the study by Farshad et al. (5), AIS patients showed a mild posterior imbalance, especially in the Lenke Type 1; however, sagittal spinopelvic parameters were similar in all Lenke types. In our patient group, the overall mean of TK was normokyphotic (22.2°) and the mean of SVA was in normal range. However, Roussouly et al. (13) investigated 132 AIS patients and found that SS and LL were decreasing postoperatively, PT was increasing mildly but significantly, and PI was not changing. According to their

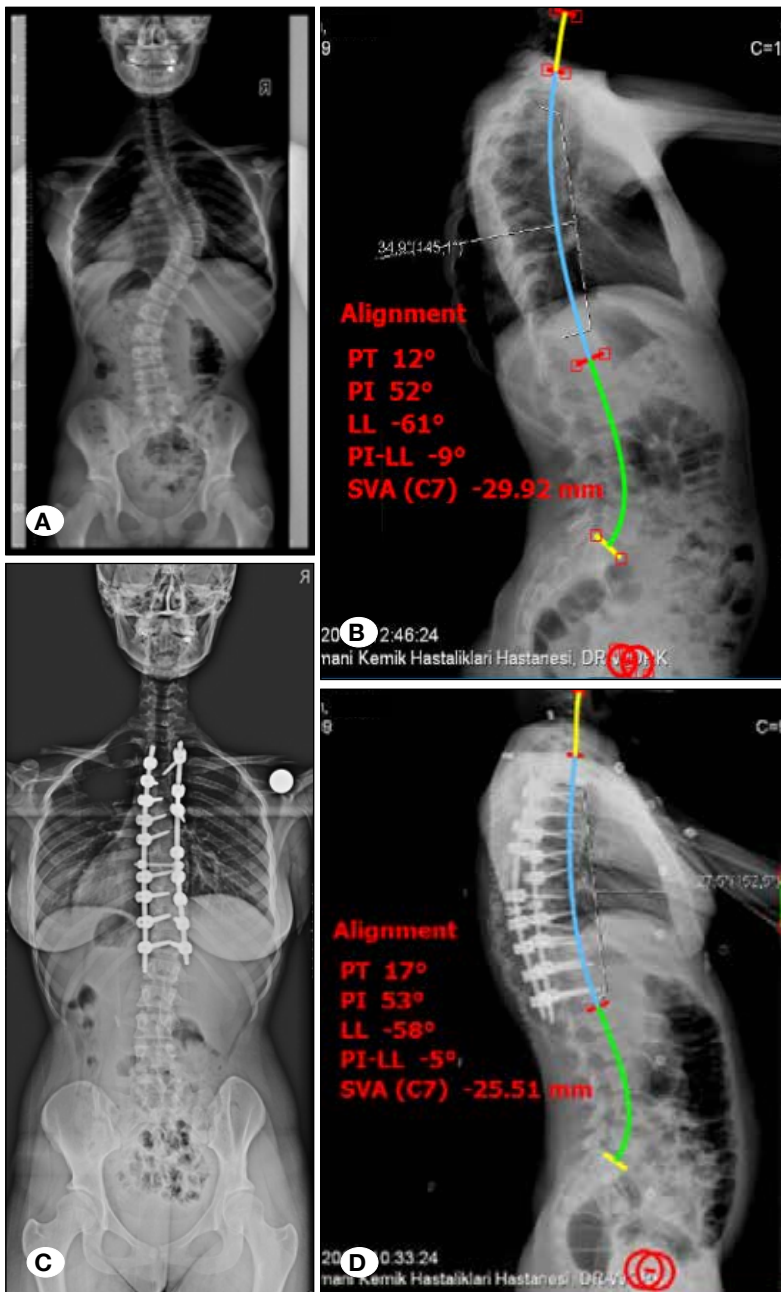


Figure 3: Selective Group preoperative **A,B)** postoperative **C,D)** sagittal spinopelvic parameters.

results, TK was found to be unchanged. In the same study, changes in the sagittal plane between Lenke's types were minimal. In a total of 53 Lenke Type 1 patients who constituted our patient group, PT and PI did not change significantly at the postoperative evaluation, but a slight decrease in SS was observed ($p=0.04$).

Selective fusion surgery remains popular since Lenke stated that compensatory curvatures at the AIS should not be included in the fusion site (9). However, this rule cannot be followed in some cases. Non-selective fusion sites can be added in patients whose curvature cannot be corrected in the coronal plane. Changes in sagittal parameters during the postoperative period can be expected in patients with both selective and non-selective fusion. Ries et al. (12) compared the group of 50 Lenke Type 1 and Type 2 patients with 32 healthy individuals and found that both the TK and LL were decreased after selective fusion in each group, whereas SVA and PT were not affected. As a result, they showed that, although the sagittal profile was altered; sagittal spinopelvic parameters did not change. However, in our study, the absence of significant changes in both TK and LL in patients with selective fusion may suggest that selective surgery will not necessarily affect the sagittal plane (Figure 2A-D; 3A-D).

In the studies by Celestre et al. (3) although the values of the sagittal parameter of non-selective fusion patients were not changed during the mid-term follow up, patients with selective fusion had increased thoracic and/or thoracolumbar kyphotic values. Even though spinopelvic parameters are not mentioned in the same study, it is said that the effects of these changes (kyphosis increase) on sagittal balance are not known in the long-term and they should be considered when choosing a fusion level. Despite the absence of postoperative changes in the selective group, in our study we observed a decrease in TK rather than an increase in the non-selective group. However, this decrease was not statistically significant but may be explained by the fact that no extra effort may have been required to achieve TK in our general patient group, which was normokyphotic.

In their study on disc degeneration in AIS, Bernstein et al. (2) explained thoughts about sagittal parameters indirectly, as follows: 'Increased thoracic kyphosis after selective fusion can be tolerated in the short term with pelvic retroversion and increased pelvic tilt changes, but long-term effects of these effects are unknown'. During our mid-term follow up, we do not mean that sagittal spinal or spinopelvic parameters were not affected after selective or non-selective fusion surgery.

A pedicle screw system was used in all our patients. In this respect, Liu and Hai (11) investigated the effects of hybrid and non-hybrid screw systems in the sagittal plane, but did not find any differences between the two systems.

■ CONCLUSION

Sagittal spinopelvic parameters in AIS show different changes in various studies after surgery. There are also studies that give different results from our studies as well as others that report similar findings. Therefore, the reasons for these different

results warrant more detailed investigations, especially if this difference is because scoliosis is a 3-dimensional deformity.

A multi-dimensional deformity needs to be assessed using many different variables. For this reason, comparing the parameters on a single plane and ignoring the effects of other factors may have critical consequences. This point can be considered as one of the limitations of our study, while other limitations are the same patient being operated on by more than one surgeon, a relatively narrow (homogeneous) group of patients and the inability to eliminate measurement errors.

In conclusion, after selective and non-selective surgery, sagittal spinal and spinopelvic parameters are not affected in the mid-term. We think that future long-term studies that will be conducted in this regard will increasingly require the necessity of keeping the pelvis in mind while evaluating the sagittal plane in AIS surgery.

■ REFERENCES

- Atici Y, Balioglu MB, Albayrak A, Kargin D, Atici A, Akman YE: The sagittal plane analysis of spine. *Journal of Turkish Spinal Surgery* 25:149-154, 2014
- Bernstein PB, Hentschel S, Platzek I, Hühne S, Etrich U, Hartmann A, Seifert J: Thoracal flat back is a risk factor for lumbar disc degeneration after scoliosis surgery. *Spine J* 14:925-932, 2013
- Celestre PC, Carreon LY, Lenke LG, Sucato DJ, Glassman SD: Sagittal alignment two years after selective and nonselective thoracic fusion for Lenke 1C adolescent idiopathic scoliosis. *Spine Deform* 3(6):560-565, 2015
- Duval-Beaupere G, Schmidt C, Cosson P: A Barycentremetric study of the sagittal shape of spine and pelvis: The conditions required for an economic standing position. *Ann Biomed Eng* 20(4):451-462, 1992
- Farshad M, Catanzaro S, Schmid SL: The spinopelvic geometry in different Lenke curve types of adolescent idiopathic scoliosis. *Spine Deform* 4(6):425-431, 2016
- La Maida GA, Zottarelli L, Mineo GV, Misaggi B: Sagittal balance in adolescent idiopathic scoliosis: Radiographic study of spino-pelvic compensation after surgery. *Eur Spine J* 22 Suppl 6:859-867, 2013
- Larson AN, Fletcher ND, Daniel C, Richards BS: Lumbar curve is stable after selective thoracic fusion for adolescent idiopathic scoliosis: A 20 year follow-up. *Spine* 37:833-839, 2012
- Legaye J, Duval-Beaupere G, Hecquet J, Marty C: Pelvic incidence: A fundamental pelvic parameter for three-dimensional regulation of spinal sagittal curves. *Eur Spine J* 7(2):99-103, 1998
- Lenke LG, Betz RR, Haer TR, Lapp MA, Merola AA, Harms J, Shufflebarger HL: Multisurgeon assessment of surgical decision-making in adolescent idiopathic scoliosis: Curve classification, operative approach, and fusion levels. *Spine* 26(21): 2347-2353, 2001
- Lenke LG, Betz RR, Harms J, Bridwell KH, Clements DH, Lowe TG, Blanke K: Adolescent idiopathic scoliosis: A new classification to determine extent of spinal arthrodesis. *J Bone Joint Surg* 83:1169-1181, 2001

11. Liu T, Hai Y: Sagittal plane analysis of selective posterior thoracic spinal fusion in adolescent idiopathic scoliosis. A comparison study of all pedicle screw and hybrid instrumentation. *J Spinal Disord Tech* 27(5):277-282, 2014
12. Ries Z, Harpole B, Graves C, Gnanapragasam G, Larson N, Weintstein S, Mendoza-Lattes SA: Selective thoracic fusion of Lenke I and II curves affects sagittal profiles but not sagittal or spinopelvic alignment. *Spine* 40(12):926-934, 2015
13. Roussouly P, Labelle H, Rouissi J, Bodin A: Pre- and post-operative sagittal balance in idiopathic scoliosis: A comparison over the ages of two cohorts of 132 adolescents and 52 adults. *Eur Spine J* 22 Suppl 2:203-215, 2013
14. Upasani VV, Tis J, Bastrom T, Pawelek J, Marks M, Lonner B, Crawford A, Newton PO: Analysis of sagittal alignment in thoracic and thoracolumbar curves in adolescent idiopathic scoliosis. How do these two curve types differ? *Spine (Phila Pa 1976)* 32(12):1355-1359, 2007
15. Yong Q, Zhen L, Zezhang Z, Bangping Q, Feng Z, Tao W, Jun J, Xu S, Xusheng Q, Weiwei M, Weijun W: Comparison of sagittal spinopelvic alignment in Chinese adolescents with and without idiopathic thoracic scoliosis. *Spine* 37(12):714-720, 2012