

Case Report

Pneumothorax After a Ventriculoperitoneal Shunt Placement: Case Report and Review of the Literature

Tsong-Ming SU¹, Tsung-Han LEE¹, Shih-Wei HSU²¹Kaohsiung Chang Gung Memorial Hospital and Chang Gung University College of Medicine, Department of Neurosurgery, Kaohsiung, Taiwan²Kaohsiung Chang Gung Memorial Hospital and Chang Gung University College of Medicine, Department of Radiology, Kaohsiung, Taiwan**ABSTRACT**

An 82-year-old woman underwent a ventriculoperitoneal (VP) shunt placement to treat hydrocephalus secondary to a right thalamic intracerebral hemorrhage. Pneumothorax and subcutaneous emphysema was noted 2 hours later. No respiratory distress was noted. A chest computed tomography scan revealed that the shunt tube had penetrated the diaphragm and entered the pleural space. The shunt tube penetrated the lung parenchyma and exited the pleural space via the third intercostal space. She underwent chest drainage and VP shunt re-position. The VP shunt functioned properly and no infection was noted. Bending the shunt passer slightly and keeping the passer tip pointed upward and palpable during its advancement may prevent this complication. It may be acceptable to leave the shunt tube in place after chest drainage for pneumothorax.

KEYWORDS: Hydrocephalus, Pneumothorax, Ventriculoperitoneal shunt

ABBREVIATIONS: CT: Computed tomography; VP: Ventriculoperitoneal

■ INTRODUCTION

Pneumothorax after a ventriculo- or subdural-peritoneal shunt placement is a rare and dangerous complication. To our knowledge, only 4 cases have been reported in the English literature (1-4). Awareness of this potential complication may help to prevent its occurrence or manage it in time before it becomes fatal. Herein, we report a case of tension pneumothorax after a ventriculoperitoneal (VP) shunt placement and discuss the strategies to prevent and manage this complication.

■ CASE REPORT

An 82-year-old woman with a history of hypertension was admitted to the gastrointestinal ward due to acute pancreatitis. Sudden onset of consciousness disturbance and left hemiparesis occurred 3 days later. A brain computed tomography (CT) scan disclosed a right thalamic intracerebral

hematoma with rupture into the ventricle. Acute hydrocephalus was also noted. She underwent placement of an external ventricular drain emergently. After surgery, her consciousness improved gradually.

She was scheduled for a VP shunt placement 10 days after the occurrence of right thalamic intracerebral hemorrhage. The shunt passer was advanced from the abdominal subcutaneous fat tissue to the supraclavicular portion. The tip of the passer could not be palpated underneath the patient's breast. Shunt placement went as planned, and no change in vital signs was noted during the operation. Subcutaneous emphysema was found in her neck and right chest wall two hours after the surgery. The patient did not show respiratory distress, and her vital signs were stable. A chest x-ray revealed diffuse subcutaneous emphysema, and right pneumothorax, which was not immediately recognized by the resident. A chest CT scan revealed that the shunt tube had penetrated the diaphragm and entered the pleural space, causing



Corresponding author: Tsung-Ming SU

E-mail: tsungming4516@gmail.com

pneumothorax and subcutaneous emphysema (Figure 1A). Then, the shunt tube penetrated the lung parenchyma and exited the pleural space via the third intercostal space (Figure 1B). A chest drainage tube was inserted via the fifth intercostal space in the midaxillary line. The shunt tube was re-positioned to the thoracic subcutaneous fat tissue and into the abdominal cavity after chest drainage. The chest drainage tube was removed uneventfully 5 days later. The VP shunt functioned properly and no infection was noted. The patient progressed favorably and was transferred to a nursing home 2 weeks later.

DISCUSSION

To our knowledge, only 4 cases of pneumothorax after ventriculo- or subdural-peritoneal shunt placement have been reported in the English literature (Table I). All reported patients were female. As in the case of Schul et al. (3), the chest CT in our patient showed that the shunt tube had penetrated the diaphragm and lung parenchyma, and then exited the pleural space via the intercostal space. However, the shunt tube was externalized in the case of Schul et al. (3). We re-positioned the tube to the thoracic subcutaneous fat tissue because we thought the tube located in the injured lung parenchyma might affect the healing of pneumothorax.

To avoid pneumothorax after a shunt procedure, the tip of shunt passer should be kept palpable during its advancement, although this can be difficult to achieve underneath a patient's breast or in obese patients (1,3). Bending the passer slightly

and keeping the passer tip pointed upward during its advancement may facilitate the palpability of the passer tip and decrease the risk of pleural penetration.

No consensus exists regarding the treatment strategies of pneumothorax after a VP shunt procedure. The strategies should consider 2 critical factors: the need for chest drainage and the risk of shunt infection after chest drainage. The need for chest drainage depends on the amount of pneumothorax and the symptoms caused by the pneumothorax. Chest drainage should be performed immediately in the case of tension pneumothorax. The chest drainage tube should be inserted more laterally than usual to decrease the risk of shunt infection. Close surveillance is necessary if the pneumothorax is minimal and treated conservatively.

Removal of the shunt tube can avoid the risk of shunt infection after chest drainage. However, shunt revision would be necessary later (3). In 3 previously reported cases, the shunt tube was not removed after chest drainage, and no infection was noted (Table I). In our case, we decided to re-position the shunt tube to the thoracic subcutaneous tissue because we thought the tube located in the injured lung parenchyma might affect the healing of pneumothorax. Still, no shunt infection after shunt re-position was noted. Therefore, it may be acceptable to leave the shunt in place even after chest drainage. We know our decision to re-position the shunt is controversial. In a previous reported case with similar CT findings (3), the shunt was externalized. More studies are necessary to clarify this issue.

Table I: Review of the Literature on Pneumothorax After Ventriculo- or Subdural-Peritoneal Shunt Placement

Literatures	Age Sex	Operation	Presentation	When found	Specific CT findings	Management	
						Chest drainage (timing)	Shunt management
Portnoy et al.	66 Yr F	VP shunt	Subcutaneous emphysema	Several hours after the operation	ND	+ (immediately)	Left in situ
Schul et al.	74 Yr F	VP shunt	Respiratory insufficiency	2 hours after the operation	Shunt tube penetrates the diaphragm and lung parenchyma	+ (immediately)	Externalization
Solmaz et al.	4 Mo F	SP shunt	Oxygen desaturation, hypotension, bradycardia	During the operation	None	+ (immediately)	Left in situ
Kono et al.	73 Yr F	VP shunt	None	Just after the operation	Shunt tube passes underneath the 3 rd to 5 th rib	+ (one week later)	Left in situ
Current case	82 Yr F	VP shunt	Subcutaneous emphysema	2 hours after the operation	Shunt tube penetrates the diaphragm and lung parenchyma	+ (1 hour later)	Revision

Yr: year; Mo: month; F: female; VP: ventriculoperitoneal; SP: subdural-peritoneal; CT: computed tomography; ND: not done.

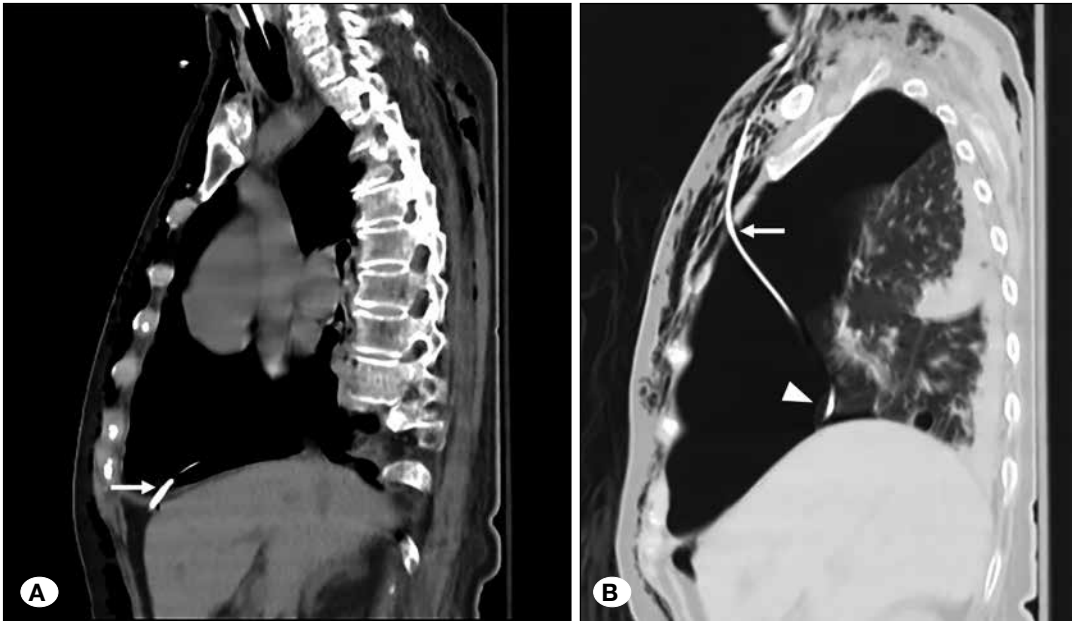


Figure 1: **A)** A chest CT scan revealed that the shunt tube penetrated the diaphragm (arrow) and entered the pleural space. **B)** The shunt tube penetrated the lung parenchyma (arrowhead) and exited the pleural space via the third intercostal space (arrow).

■ CONCLUSION

Pneumothorax after a VP shunt procedure is a rare complication. Neurosurgeons should be careful to avoid this complication, especially in female or obese patients. Bending the shunt passer slightly and keeping the passer tip pointed upward and palpable during its advancement may prevent this complication. It may be acceptable to leave the shunt tube in place after chest drainage for pneumothorax.

■ REFERENCES

1. Kono K, Tomura N, Okada H, Terada T: Iatrogenic pneumothorax after ventriculoperitoneal shunt: An unusual complication and a review of the literature. *Turk Neurosurg* 24:123-126, 2014
2. Portnoy HD, Croissant PD: Two unusual complications of a ventriculoperitoneal shunt. *J Neurosurg* 39:775-776, 1973
3. Schul DB, Wolf S, Lumenta CB: Iatrogenic tension pneumothorax resulting in pneumocephalus after insertion of a ventriculoperitoneal shunt: An unusual complication. *Acta Neurochir (Wien)* 152:143-144, 2010
4. Solmaz I, Tehli O, Kaya S, Erdogan E, Izci Y: Bilateral pneumothorax during subdural-peritoneal shunting. *Turk Neurosurg* 21:421-422, 2011