



Original Investigation

Infections under Skin Flap After Cranioplasty and a Simple Effective Treatment

Jun-Hui CHEN^{1*}, Wenwen ZHANG^{2*}, Zhong-Hua SHI^{1*}, Lei CHEN¹, Xu HU¹, Jian-Qing HE¹, Yu-Hai WANG¹¹Anhui Medical University, Clinical Medical School, 904st Hospital of PLA (Wuxi Taihu Hospital), Department of Neurosurgery, Wuxi, China²Taizhou NO.4 People's Hospital, Departments of Neurosurgery, Taizhou, China

*Co-first authors.

Corresponding author: Yu-Hai WANG ✉ wangyuhai1516@163.com

ABSTRACT

AIM: To report treatment experiences with titanium mesh cranioplasty infection at a single institution over the last 5 years.**MATERIAL and METHODS:** We retrospectively reviewed 11 consecutive patients who were diagnosed with infection under the skin flap after titanium mesh cranioplasty and received our new treatment between Feb 2008 and Feb 2013. We performed a 2- to 6-year follow-up to evaluate prognosis and security.**RESULTS:** All 11 patients were cured and discharged, and all saved their infected bone flap (titanium mesh) completely. There was no recurrence of infection after follow-up for 2-6 years.**CONCLUSION:** Sensitive antibiotics combined with enclosed continuous irrigation and drainage is a safe, easy, economical and effective treatment for infection after titanium mesh cranioplasty that can save the infected bone flap.**KEYWORDS:** Titanium mesh cranioplasty, Surgical site infection, Antibiotics, Enclosed continuous irrigation

INTRODUCTION

Decompressive craniectomy or the removal of bone flap is an effective and standard treatment to reduce intracranial pressure (ICP) from acute brain swelling or cerebral edema resulting from severe traumatic brain injury, intracranial hemorrhage, or cerebral infarction (8,13,17,19). After decompressive craniectomy, cranioplasty is also generally required, not only to protect against further trauma or cosmesis but also to improve the patient's neurological function. Cranioplasty is increasingly being performed (5). However, this operation is still associated with a higher complication rate, such as infection, than many other neurosurgical operations (8,15). Kim et al. found that the rate of graft infection after cranioplasty (GIC) was 7.05 % in 85 patients who were analyzed retrospectively (9). Soumya et

al. found that the overall complication rate after cranioplasty was 26.4% (46/174), and the plate removal rate was 10.3 % (18/174) (12). The most common complication was infection, which accounted for 69% of plate removals.

Infectious complications following titanium mesh cranioplasty can significantly increase morbidity, increase health care costs and hospital stay, and make treatment difficult, even though the operation is required to remove the infected bone flap. If the bone flap is removed, the cost and length of hospitalization must increase.

Is there another treatment that can replace removal of the infected bone flap to cure infection? In this series, we report our treatment experiences with titanium mesh cranioplasty infection at a single institution over the last 5 years.

Jun-Hui CHEN : 0000-0002-9410-9722
Wenwen ZHANG : 0000-0002-3384-3181
Zhong-Hua SHI : 0000-0003-3298-1520

Lei CHEN : 0000-0001-7038-9128
Xu HU : 0000-0001-6480-4997
Jian-Qing HE : 0000-0003-2791-1261

Yu-Hai WANG : 0000-0002-6442-8677

■ MATERIAL and METHODS

Ethics Statement

This study was approved by the Ethics Committee of the 101st Hospital of PLA of Anhui Medical University (Approval Number: AMU-EXLL200801), and signed informed consent was obtained.

Patient Population

Between Feb 2008 and Feb 2013, a single center retrospective chart review of 513 patients aged 18 years to 69 years who underwent titanium mesh cranioplasty procedures at the Department of Neurosurgery, 101 PLA Hospital, Jiangsu, China found that 28 (5.46 %) patients had an infection after the operation. In these 28 patients with infection, seventeen patients received conventional anti-infection treatment, and 9 patients were cured and did not have the bone flap (titanium mesh) removed. Another 8 patients failed, and the infected bone flap was removed after conventional anti-infection treatment was not effective. However, this procedure is a heavy economic burden to patients, society and the government. Another 11/28 patients received our new treatment, and all of them were cured successfully, with no reinfection after discharged. The clinical features are shown in Table I. All 11 patients, four of whom were female and seven of whom were male, required cranioplasty for severe trauma brain injury (sTBI). The cranioplasty area was 5x7 cm for two patients, 8x10 cm for four patients, and 10x12 cm for five patients. The mean duration from cranioplasty to infection was 17 days (range: 5 to 60 days). All patients received a titanium mesh as the cranioplasty material.

The clinical features were fluid under the skin flap, fever, poor feeding, local incision redness and swelling, and a secretion culture or smear with a positive result (the same pathogen from at least two consecutive secretion samples to avoid contamination). All 11 patients had a positive secretion culture from the skin flap before anti-infection treatment.

Treatment of Infection After Titanium Mesh Cranioplasty

When we found local infection after titanium mesh cranioplasty or the incision secretion culture was positive, we first adopted systemic anti-infection treatment, strengthened immune support therapy and controlled risk factors. An enhanced CT examination and lumbar puncture were performed, which would help us evaluate the infection. It can also help us exclude intracranial infection. If patients had intracranial infection, then we could not use the new treatment. If there was no effect of conventional anti-infection treatment for one week, then our new way method was used.

Specific Steps of New Treatment

1. Lumbar puncture was performed to confirm intracranial infection. If conventional anti-infection treatment was not effective after one week, we adapted this enclosed continuous irrigation and drainage for all patients if the family agreed and authorized it.
2. After conventional preoperative preparation, we made a 1-cm horizontal incision through the skin beside the

original incision at the forehead. We freed the flap and titanium mesh adequately through the subgaleal by artery forceps, and then placed the drainage tube with side holes on top of the infection area, and used it for continuous irrigation. We installed another drainage tube the same way into the lowest point of infection area and used it for drainage. Then, first we ran saline through irrigation tube and observed whether the drainage tube was blocked. It was successful if the drainage tube was unblocked, and then we connected the drainage tubing to the end of a closed drainage bag (Figure 1A, B).

3. When an infection under the skin flap after cranioplasty was found, we first used intravenous vancomycin (0.9 NaCl 100 ml + vancomycin 0.5 g iv, tid). Then, and most importantly, we enclosed continuous irrigation and drainage with vancomycin or cefoperazone sodium and sulbactam sodium. The specific method involved; 1) using the concentration and dose of antibiotics shown in Table II, 2) changing the antibiotics based on the drainage liquid or CSF culture results, if necessary, and 3) removing the titanium mesh materials using the traditional treatment method if this treatment was not effective for patients after one week.
4. The irrigation liquid was uniformly instilled at 1000~1500 ml/day. The drainage tube was clipped before irrigation. It was reopened if infection cavities were full of antibiotics for two hours. The above operation was repeated 2~3 times every day. The whole process must be carried out under aseptic conditions.
5. The criteria for considering the infection cured were a normal temperature for 3 days and no meningeal irritation, routine blood examination showing a normal WBC and procalcitonin (PCT), routine drainage liquid examination showing WBC <10/mL, with normal protein and glucose, and a negative drainage liquid culture at least 3 times. The irrigation tube can be removed first if patients satisfied these conditions, and then the drainage tube can be removed 24 hours later.

■ RESULTS

Outcome and Follow-up

All 11 cases were cured and discharged with a favorable outcome, and no patients experienced treatment-related complications at the time of hospitalization. All patients received 2-5 years of follow-up without infection recurrence, none of them suffered CSF oozes from the incision, and all the wounds healed well.

Cost and Hospital Stay

All 11 cases received 3 weeks of systemic intravenous antibiotics and one week of closed, continuous swash and drainage by tube insertion. The mean hospital stay was 24.5 days, which less than other patients who had the mesh materials removed (24.5 vs 34.5, $p=0.003$). The mean hospital cost of the 11 cases who received our treatment was 66000 Renminbi (RMB), but the mean hospital cost of standard

treatment was approximately 125000 RMB (the data from our department from 15 patients who received standard treatment between 2011 and 2014, shown in Table III).

DISCUSSION

Cranioplasty was designed to restore cosmesis, physically protect the underlying brain, and prevent complications

from long-term skull defects (12,18). There are many kinds of cranioplasty materials from which to choose. In our department, all cranioplasty materials were titanium. Titanium is relatively cheap, bioacceptable, and radiolucent, but it may not be a good option in cases of bad skin viability (12).

Cranioplasty after decompressive craniectomy carries a high rate of complications. Brommeland et al. reported that

Table I: Patients Characteristic of Infections After Titanium Mesh Cranioplasty

NO	Sex	Age (years)	Cause	Time to cranioplasty (day)	Time (day)	organism
1	Male	23	post-traumatic	125	9	Staph.e
2	Male	36	post-traumatic	98	3	Staph.a
3	Male	34	post-traumatic	67	7	Staph.e
4	Male	46	post-traumatic	54	6	Staph.a
5	Male	54	SAH post-traumatic	69	11	Staph.e
6	Female	58	SAH	156	5	Ab
7	Male	35	post-traumatic	99	7	Enterob
8	Female	47	post-traumatic	115	10	Staph.a
9	Male	27	post-traumatic	67	7	Staph.e
10	Male	57	SAH	86	10	Staph.a
11	Female	43	SAH	67	8	Staph.a

Cause: reason to cranioplasty; **Time to cranioplasty:** the time from decompressive craniectomy to cranioplasty. **Time:** the time of cranioplasty operation to infection; **Revision:** shunt materials revise (pressure revise and partial revise). **Staph.e:** Staphylococcus epidermidis; **Staph.a:** Staphylococcus aureus; **Enterob:** Enterobacter cloacae. **Ab:** Acinetobacter baumannii.

Table II: The Concentration and Dose of Antibiotics

Group	N	Antibiotics	Concentration	Dose/day
G ⁻	5	Vancomycin	500 ml Nacl+0.5 g	1000 ml
		CSSS	250 ml Nacl+0.5 g	500 ml
G ⁺	6	Vancomycin	500 ml Nacl+0.5 g	1500 ml

CSSS: Cefoperazone Sodium and Sulbactam Sodium.

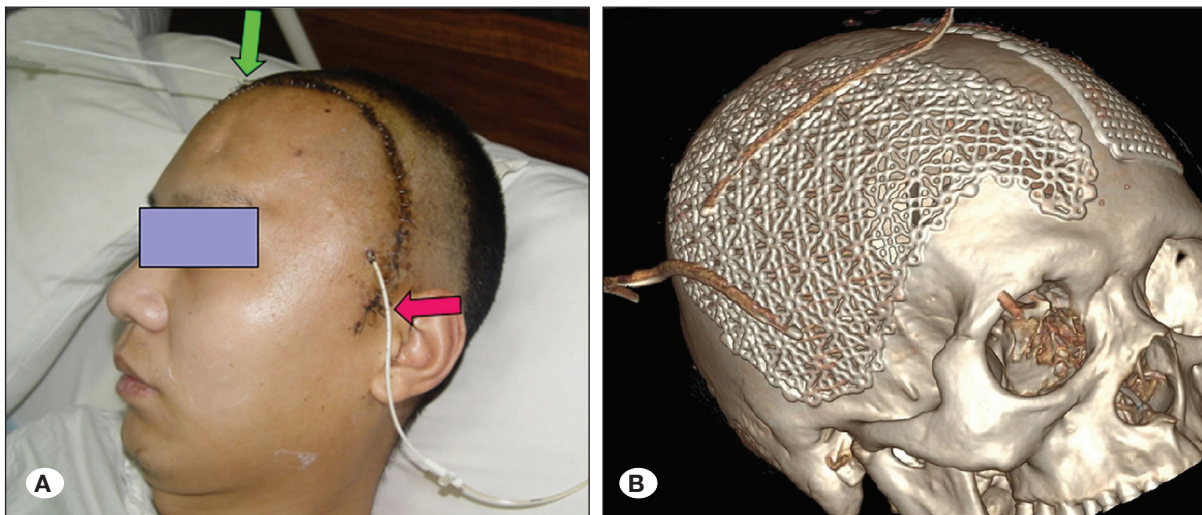


Figure 1: Sensitive antibiotic combine with enclosed continuous irrigation and drainage to treatment for infection under the skin flap after cranioplasty. **A)** Green arrow point to the irrigation tube, and pink arrow point to the drainage tube. **B)** CT three dimensional reconstruction images.

Table III: The Effect of Two Groups

Group	Hospital Stay (mean ± SD) (day)	Hospital Cost (mean ± SD) (ten thousand ¥)	Cure rate (%)
New treatment	6.6 ± 2.1	24.5 ± 5.2	100 (11/11)
Standard treatment	12.5 ± 5.6	34.5 ± 8.1	86.7 (13/15)
<i>P</i>	0.003	0.002	0.492

Independent samples test was used for continuous variable. A chi-squared test, rank sum test or Fisher exact was used for categorical variable.

surgical site infection and bone flap resorption were the two most common complications (2), and many other studies reported a wide variation in complication rates after titanium cranioplasty, but most rates were greater than 25 % (1,12,16). Mukherjee et al. also reported that the most common complication was infection at a rate of 8.6 % (12). The plate removal rate was 10.3 %, and infection accounted for 69 % of these cases. Therefore, minimizing complications and curing infections after cranioplasty are very important goals.

The Risks Factors for Infections After Cranioplasty

Infections after cranioplasty are a very important complication, and the rate ranges from 7 %-22 % in the literature (3,6,7,11,14). In this study, we retrospectively analyzed 11 cases of infections under the skin flap after cranioplasty procedures. There are many reasons for infections under skin flap after cranioplasty. Riordan et al. found wound dehiscence and breakdown was a common concern in cranioplasty patients (14), and local wound infections may lead to skin colonization that, when left untreated, could increase the risk of recurrent infection. There is also a fear of indolent infection of the underlying bone flap that may not be treated with a simple washout, as it is a very difficult situation (3,7,14).

Morton et al. reported the largest study on predictors of infection after cranioplasty and found that the overall infection rate after cranioplasty was 6.6 % (50 cases), and that infections occurred on median postoperative day 31. The authors also considered that cranioplasty procedures should be performed at least 14 days after initial craniectomy to minimize infection risk (11). Rosseto et al. reported that the risk factors of infection include motor deficits, Glasgow Outcome Scale score <4, lower hemoglobin levels, recent systemic infections, interval between DC and CP of 29-84 days, decompressive craniectomy and craniectomy performed during the same hospitalization after analyzing 45 patients who underwent cranioplasty after unilateral decompressive craniectomy from April 2011 through January 2012 (15). In our study, 5 patients had wound dehiscence and breakdown and 3 patients had recent systemic infections.

Treatment Plan

As local inflammation was wrapped, just using systemic antibiotics alone and incompletely removing the titanium mesh had an unacceptably high failure rate. Most studies have confirmed that the best treatment is to remove the titanium mesh (10,14). However, this treatment is too expensive, lavish

and risky as described above. In this study, we tried a new and simple therapy to treat cranioplasty infection that was shown to be effective through long-term follow-up. All 11 cases were cured and discharged with a favorable outcome. There was no recurrence of infection after follow-up for 2-5 years. The new treatment plan was better than standard therapy with reduced hospital cost, shorter hospital stays and safer treatment ($p < 0.05$).

Pathogenesis and Choice of Antibiotics

The rate of positive bacteria culture was very low. In our study, just 5 patients (45.5 %) had microorganisms in CSF samples, which was not enough to examine the sensitivity of the drugs for treating cranioplasty infection. Therefore, it was very important to study the distribution of cranioplasty infectious bacteria. Recently, a review of the literature indicated that the main pathogen was *Pseudomonas aeruginosa* (4). In our study, no *Pseudomonas aeruginosa* was found. Instead, just one Enterob was found, as well as other organisms, including 5 *Staphylococcus aureus* and 4 *Staphylococcus epidermidis* and one *Acinetobacter baumannii*. All our isolates were part of normal skin flora except *Enterobacter cloacae*, and the main mechanism of cranioplasty infection was contamination of bacteria of the skin flora.

The choice of antibiotics may be a very difficult problem as different doctors made different choices. Most doctors selected antibiotics according to the sensitivity of the drugs, but not every cranioplasty infection patient had a satisfactory result from the bacteria susceptibility test. All 5 patients accepted intravenous vancomycin alone and enclosed continuous irrigation and drainage. Treatment duration was 2 weeks, based on the objective condition of the patient. All 11 patients had a good outcome, with no neurological dysfunction and no reinfections.

■ CONCLUSION

Our study shows that valve injection antibiotics combined with systemic medication may be a simple, safe and effective way to treat cranioplasty surgical site infection. It can significantly reduce hospitalization and hospital stay. Our study was limited by a small sample size and lack of randomization, but it had a distinct advantage compared to traditional treatment in our department. However, a larger multicenter, randomized, controlled trial study is required to evaluate the effectiveness of this treatment to cure cranioplasty infection.

■ REFERENCES

1. Aydin S, Kucukyuruk B, Abuzayed B, Sanus GZ: Cranioplasty: Review of materials and techniques. *J Neurosci Rural Pract* 2:162–167, 2011
2. Brommeland T, Rydning PN, Pripp AH, Helseth E: Cranioplasty complications and risk factors associated with bone flap resorption. *Scandinavian Journal of Trauma, Resuscitation and Emergency Medicine* 23:75, 2015
3. Bruce JN, Bruce SS: Preservation of bone flaps in patients with postcraniotomy infections. *J Neurosurg* 98:1203–1207, 2003
4. Cheng YK, Weng HH, Yang JT, Lee MH, Wang TC, Chang CN: Factors affecting graft infection after cranioplasty. *Journal of Clinical Neuroscience* 15:1115–1119, 2008
5. Chibbaro S, Fricia M, Vallee F, Beccaria K, Poczoz P, Mateo J, Romano A, Ippolito S, Ippolito M, Guichard JP, Gobron C, George B, Vicaut E: The impact of early cranioplasty on cerebral blood flow and metabolism and its correlation with neurological and cognitive outcome: prospective multi-center study on 34 patients. *Indian J Neurosurg* 1:17–22, 2012
6. Coulter IC, Pesic-Smith JD, Cato-Addison WB, Khan SA, Thompson D, Jenkins AJ, Strachan RD, Mukerji N: Routine but risky: A multi-centre analysis of the outcomes of cranioplasty in the Northeast of England. *Acta Neurochir (Wien)* 156:1361–1368, 2014
7. Cronquist AB, Jakob K, Lai L, Della Latta P, Larson EL: Relationship between skin microbial counts and surgical site infection after neurosurgery. *Clin Infect Dis* 33:1302–1308, 2011
8. Honeybul S, Ho KM: Decompressive craniectomy for severe traumatic brain injury: The relationship between surgical complications and the prediction of an unfavourable outcome. *Injury* 45:1332–1339, 2014
9. Kim H, Sung SO, Kim SJ, Kim SR, Park IS, Jo KW: Analysis of the factors affecting graft infection after cranioplasty. *Acta Neurochir* 155:2171–2176, 2013
10. Matsuno A, Tanaka H, Iwamuro H, Takanashi S, Miyawaki S, Nakashima M, Nakaguchi H, Nagashima T: Analyses of the factors influencing bone graft infection after delayed cranioplasty. *Acta Neurochir (Wien)* 148:535–540, 2006
11. Morton RP, Abecassis IJ, Hanson JF, Barber J, Nerva JD, Emerson SN, Ene CI, Chowdhary MM, Levitt MR, Ko AL, Dellit TH, Chesnut RM: Predictors of infection after 754 cranioplastys and the value of intraoperative cultures for cryopreserved bone flaps. *J Neurosurg* 15:1–5, 2016
12. Mukherjee S, Thakur B, Haq I, Hettige S, Martin AJ: Complications of titanium cranioplasty—a retrospective analysis of 174 patients. *Acta Neurochir* 156:989–998, 2014
13. Otani N, Takasato Y, Masaoka H, Hayakawa T, Yoshino Y, Yatsushige H, Miyawaki H, Sumiyoshi K, Chikashi A, Takeuchi S, Suzuki G: Surgical outcome following decompressive craniectomy for poor-grade aneurysmal subarachnoid hemorrhage in patients with associated massive intracerebral or Sylvian hematomas. *Cerebrovasc Dis* 26:612–617, 2008
14. Riordan MA, Simpson VM, Hall WA: Analysis of factors contributing to infections following cranioplasty: A single-institution retrospective chart review. *World Neurosurgery* 87:207–213, 2016
15. Rosseto RS, Giannetti AV, de Souza Filho LD, Faleiro RM: Risk factors for graft infection after cranioplasty in patients with large hemispheric bony defects. *World Neurosurgery* 84:431–437, 2015
16. Sobani ZA, Shamim MS, Zafar SN, Qadeer M, Bilal N, Murtaza SG, Enam SA, Bari ME: Cranioplasty after decompressive craniectomy: An institutional audit and analysis of factors related to complications. *Surg Neurol Int* 2:123, 2011
17. Thomale UW, Graetz D, Vajkoczy P, Sarrafzadeh AS: Severe traumatic brain injury in children—a single center experience regarding therapy and long-term outcome. *Childs Nervous System* 11:1563–1573, 2010
18. Wiggins A, Austerberry R, Morrison D, Ho KM, Honeybul S: Cranioplasty with custom-made titanium plates—14 years' experience. *Neurosurgery* 72:248–256, 2013
19. Zhao Z, Yu J, Liao S, Xiong L, Liang Z, Ling L, Wang F, Hou Q, Zhou W, Pei Z, Zeng J: Delayed decompressive craniectomy improves the long-term outcomes in hypertensive rats with space-occupying cerebral infarction. *Neurocrit Care* 7:263–269, 2007