

*Review*

# Variation and Anomalies of the Posterior Cerebral Artery: Review and Pilot Study

Karen CILLIERS, Benedict John PAGE

Stellenbosch University, Department of Anatomy and Histology, Cape Town, South Africa

This study was presented at the International Conference on Medical and Health Science, Cape Town, South Africa, December 6, 2016.

**ABSTRACT**

Variations and anomalies of the posterior cerebral artery (PCA) have several clinical implications, including assisting in understanding the clinical signs of a stroke. Anomalies have been described previously; however, few reports mention the origins, absence, duplication and triplication of the cortical branches. Furthermore, the PCA branching pattern has not been adequately described. The aim of this study was to describe the anatomy and anomalies of the PCA. Results of a pilot study were additionally included.

The quantity, origin, diameter and length of the PCA cortical branches were described in this review, as well as the branching pattern and the anomalies. Accordingly, the pilot study reported on these aspects. In the pilot study it was evident that the description of the branching pattern is not the "normal" pattern, since it was only observed in one case. This pattern was re-evaluated and three groups were described; monofurcation, bifurcation and trifurcation. Furthermore, one case of a fenestration was observed.

Aneurysms tend to form at branching points, thus knowledge of the branching pattern can aid in detection of ruptured and unruptured aneurysms in this region. This review outlined several gaps in the literature, and a pilot study was included to fill some of these gaps. Future research should especially focus on the branching pattern of the PCA. Possible sex, age and population differences may also exist.

**KEYWORDS:** Anomaly, Branching pattern, Cortical branch, Fenestration, Posterior cerebral artery

**ABBREVIATIONS:** AITA: Anterior inferior temporal artery, CA: Calcarine artery, CTA: Common temporal artery, MITA: Middle inferior temporal artery, PCA: Posterior cerebral artery, PITA: Posterior inferior temporal artery, PoA: Parieto-occipital artery, SA: Splenial artery.

**■ INTRODUCTION**

In comparison to the anterior and middle cerebral arteries, very few reports have been published on the anatomy of the posterior cerebral artery (PCA). Variations and anomalies of the PCA can have clinical implications, and can be especially helpful in understanding the clinical signs of a stroke (20,41). Few studies report on the presence (absence, duplication and triplication), size and origin of the cortical branches. Furthermore, the branching pattern of the PCA has also not been adequately described. Anomalies of the PCA have been

described previously; however, rare and distinctive anomalies are still being reported. The aim of this study was to describe the anatomy and anomalies of the PCA. The results of a pilot study were additionally added.

**■ LITERATURE REVIEW**

The PCA is the terminal branch of the basilar artery (32,40). There are four segments (Figure 1); the P1 or pre-communicating segment, the P2 or ambient segment, the P3 or quadrigeminal segment, and the P4 or calcarine segment

**Corresponding author:** Karen CILLIERS**E-mail:** 16173112@sun.ac.za

(7,34,37,40). There are six PCA cortical branches; the anterior, middle and posterior inferior temporal arteries, the splenial artery, the calcarine artery (CA), and the parieto-occipital artery (PoA). A common trunk between the temporal arteries can also be present, referred to as the common temporal artery (CTA). These segments and cortical branches are illustrated in Figure 1.

### Segments

The P1 segment starts at the end of the basilar artery and ends at the origin of the PcoA. The P2 segment extends from the PcoA and can be divided into P2A and P2P segments (anterior and posterior parts) (40). The transition point has been described as the posterior margin (30,54,56) or lateral aspect (43) of the cerebral peduncle, as well as the lateral mesencephalic sulcus (43). The P3 segment continues at the perimesencephalic cistern, although it has also been described to start at the anterior inferior temporal artery (AITA); however, this point varies. The P4 segment runs from the calcarine fissure (43).

### Cortical Arteries

#### Temporal Arteries

The temporal arteries can originate from the main trunk of the PCA (typically P2 segment), or from the common temporal artery (34-36,40,56). The CTA also typically arises from the P2 segment (35), and can be referred to as the temporo-occipital artery, lateral occipital artery, or the lateral division of the PCA. This “temporo-occipital artery” should not be confused with the temporo-occipital artery from the middle cerebral artery (17,35,40,56). The origins of the temporal arteries are tabulated in Table I as observed by Zeal and Rhoton (56) and Haegelen et al. (22).

According to the literature (35,56), the middle inferior temporal artery (MITA) is the least consistent PCA cortical branch, while selected authors (34) do not mention this branch. Duplication of the anterior and middle inferior temporal arteries have not been reported previously; however, the posterior inferior temporal artery (PITA) was duplicated in 2.8% (one case)(35), 6.0% (three cases) (56) and 7.5% (three cases) (34). Margolis

et al. (34) additionally observed three or more PITA's in five cases (12.5%).

### Splenial Artery

The splenial artery arises from the PoA or the main PCA stem (Table II) and supplies the splenium of the corpus callosum. It can also be referred to as the posterior pericallosal artery, and anastomoses can occur between this artery and the anterior cerebral pericallosal artery (17,49,56). This artery has been observed in a range of 35.0% to a 100% of cases (34,56). Duplication has also been reported; Türe et al. (49) observed 10 cases (25.0%) of a duplicated splenial artery.

### Terminal Trunks

The terminal trunk of the PCA consists of the PoA and calcarine artery, and this terminal division usually occurs at the P3 segment (Table II) (35,40). The artery with the largest diameter is considered the terminal branch, and Zeal and Rhoton (56) reported the terminal branch as the PoA in 56.0%, and as the calcarine artery in 44.0%.

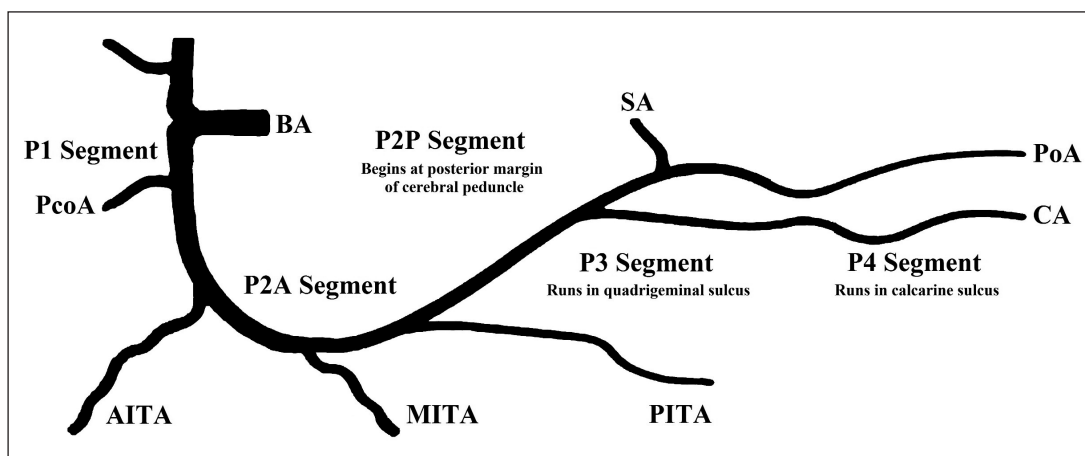
The PoA and CA supply the posterior third of the medial surface of the brain, as well as parts of the parietal and occipital lobes (40). Duplication of the PoA have been reported in a range of 1.7% to 5.0% (34,35), and duplication of the calcarine artery have been documented in a range of 10.0% to 60.0% (34,35,56).

### Diameter and Lengths

Unfortunately, limited reports exist on the diameter and length of the PCA cortical branches. However, Pai et al. (41) and Kawashima et al. (30) measured these parameters. This is tabulated in Table III.

### Branching Pattern

The PCA main trunk was previously considered to end at the origin of the common temporal artery; however, it is currently described to end at the origin of the calcarine artery and PoA. This branching (terminal division) can occur at different levels; usually at the P3 segment, however it can also divide at the P2 or P4 segments. This main trunk has also been referred to as the medial occipital artery (33). Milisavljević et al. (37)



**Figure 1:** The different segments and cortical branches of the posterior cerebral artery. (AITA) Anterior inferior temporal artery; (BA) Basilar artery; (CA) Calcarine artery; (MITA) Middle inferior temporal artery; (PITA) Posterior inferior temporal artery; (PcoA) Posterior communicating artery; (PoA) Parieto-occipital artery; and (SA) Splenial artery.

**Table I:** Origins of the Temporal and Common Temporal Arteries

Authors	CTA		AITA		MITA		PITA	
	Zeal & Rhoton (1978)	Haegelen et al. (2012)	Zeal & Rhoton (1978)	Haegelen et al. (2012)	Zeal & Rhoton (1978)	Haegelen et al. (2012)	Zeal & Rhoton (1978)	Haegelen et al. (2012)
<b>Total</b>	50	40	50	40	50	40	50	40
<b>Presence</b>	16.0%	20.0%	84.0%	80.0%	38.0%	20.0%	96.0%	80.0%
<b>P2 segment</b>	-	-	-	-	-	-	-	-
<b>P2A</b>	37.5%	50.0%	76.2%	93.8%	42.1%	50.0%	4.2%	18.8%
<b>Junction</b>	-	12.5%	-	3.1%	-	12.5%	-	12.5%
<b>P2P</b>	62.5%	37.5%	23.8%	3.1%	57.9%	37.5%	89.6%	68.8%
<b>P3 segment</b>	-	-	-	-	-	-	6.3%	-

**AITA:** Anterior inferior temporal artery, **CTA:** Common temporal artery; **MITA:** Middle inferior temporal artery; **PITA:** Posterior inferior temporal artery.

**Table II:** Origins of the Splenial, Parieto-Occipital and Calcarine Arteries

Authors	SA		PoA		CA		CA		
	Zeal & Rhoton (1978)	Ture et al. (1996)	Párraga et al. (2011)	Margolis et al. (1971)	Zeal & Rhoton (1978)	Párraga et al. (2011)	Margolis et al. (1971)	Zeal & Rhoton (1978)	Párraga et al. (2011)
<b>Total</b>	50	40	70	40	50	70	40	50	70
<b>Present</b>	100%	100%	90.0%	-	96.0%	100%	-	100%	91.4%
<b>P2 segment</b>	-	2.0%	-	38.0%	-	-	16.0%	-	-
<b>P2A</b>	-	-	-	-	10.0%	-	-	-	-
<b>P2P</b>	4.0%	-	-	-	40.0%	1.4%	-	42.0%	-
<b>P3 segments</b>	4.0%	32.0%	30.2%	22.0%	-	71.4%	23.0%	48.0%	64.3%
<b>P4 segments</b>	-	-	3.2%	40.0%	-	27.1%	39.0%	-	27.1%
<b>PoA</b>	62.0%	52.0%	50.8%	-	-	-	16.0%	10.0%	8.6%
<b>CA</b>	12.0%	7.0%	-	-	-	-	-	-	-
<b>PITA</b>	6.0%	-	-	-	-	-	-	-	-
<b>CTA</b>	-	7.0%	-	-	-	-	-	-	-
<b>MPChA/ LPChA</b>	12.0%	-	15.9%	-	-	-	-	-	-

**CA:** Calcarine artery; **CTA:** Common temporal artery; **PITA:** Posterior inferior temporal artery; **PoA:** Parieto-occipital artery; **SA:** Splenial artery.

**Table III:** The Average Diameter (mm) and Length (mm) of the Posterior Cerebral Artery Segments

	Diameter		Length	
	Kawashima et al. (2005)		Pai et al. (2007)	
			R	L
<b>P2 segment</b>	-	-	19.9 mm (12-28 mm)	18.44 mm (10-28 mm)
<b>P2A segment</b>	2.1 mm ± 0.4 mm	-	-	-
<b>P2P segment</b>	1.7 mm ± 0.3 mm	-	-	-
<b>P3 segment</b>	1.7 mm ± 0.2 mm	-	22.4 mm (13-38 mm)	20.9 mm (13-38 mm)

described three branching patterns of the distal PCA; terminal division at the P3 or P4 segment, either with (Type 2) or without (Type 1) the presence of the CTA, or division at the P2 segment (Type 3). Type 1, Type 2 and Type 3 were observed in 42.9%, 41.4%, and 15.7% of cases, respectively (37).

### Variation and Anomalies

Variations of the PCA include cortical branches being absent, duplicated or triplicated, and these cortical branches arising from abnormal origins. There have been selected cases where the PCA cortical branches originated from the internal carotid artery; including the PoA (8,11,40), calcarine artery (40), and PITA (3,40). Moreover, the true anomalies of the PCA include duplicated and triplicated PCA's, and fenestration can also be observed in the P1, P2, P3 and P4 segments. The prevalence of these anomalies is summarised in Table IV.

### Duplicated and Triplicated Posterior Cerebral Arteries

The PCA is usually an extension of the basilar artery. With duplication, an additional branch can originate from the PcoA, the P1 or P2 segment. Duplication is most commonly observed in the P1 segment (10,28). When the additional branch arises from the P2 segment, this can present similar to early branching of the PCA (3). Most PCA duplications are reported as case studies (5,18); however, PCA duplication

have been observed in a range of 0.2% to 2.3% (Table IV) (1, 6,10,14,19,23,28,31,33,36,53). Posterior cerebral duplication and triplication are illustrated in Figure 2A, B.

Triplication of the PCA is extremely rare and limited studies have reported this anomaly. Kapoor et al. (28) found PCA triplication in eight cases (0.8%). The branches arose from the P1 segment, and supplied the temporal and occipital lobes. Furthermore, the middle branch was usually small.

### Fenestration

Fenestration is defined as a vessel that splits into two channels and then re-joins. It can also be referred to as partial or incomplete duplication (4,9,15,42,48). Posterior cerebral fenestrations are rarely observed; however, they are usually observed in the P1 segment. These fenestrations can also be observed in the P2 segment or distal PCA, although this is extremely rare (2,10,13,21,39,42). While most cases of PCA fenestration are reported as case reports (21,24,44,46,55), the prevalence has been reported to be between 0.01% and 1.4% (Table IV) (2,10,12,19,23,29,37,47,51,52).

### PILOT STUDY

Ethical clearance (S14/05/100) was obtained from the Health Research Ethics Committee (HREC). The PCA's of 20

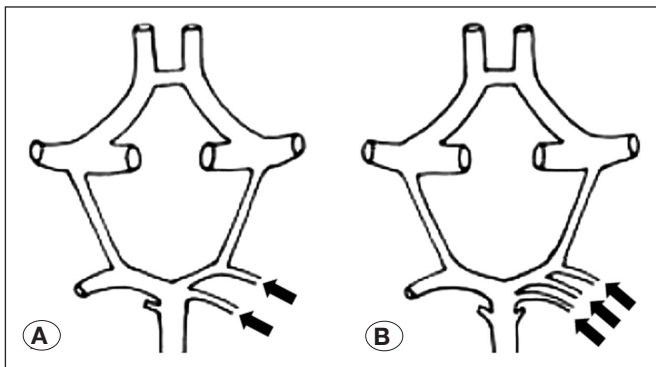
**Table IV:** The Prevalence of the Posterior Cerebral Artery Anomalies

	Total	Fenestration		Duplication		Triplication	
		Cases	%	Cases	%	Cases	%
Windle (1888)	200	-	-	3	1.5%	-	-
Fisher (1965)	414	-	-	1	0.2%	-	-
Milenković (1981)	60	-	-	1	1.7%	-	-
Bartosiak et al. (1983)	50	-	-	1	2.0%	-	-
Bisaria (1984)	252	-	-	1	0.4%	-	-
Milisavljević et al. (1988)	70	1	1.4%	-	-	-	-
Caruso et al. (1991)	100	1	1.0%	1	1.0%	-	-
Karazincir et al. (2004)	176	1	0.6	-	-	-	-
Ladziński & Maliszewski (2005)	100	-	-	1	1.0%	-	-
Kapoor et al. (2008)	1000	-	-	23	2.3%	8	0.8%
van Rooij et al. (2009)	208	2	1.0%	-	-	-	-
Bayrak et al. (2011)	395	2	0.5%	-	-	-	-
Sun et al. (2012)	4652	1	0.02%	-	-	-	-
Hamidi et al. (2013)	500	7	1.4%	1	0.2%	-	-
Cooke et al. (2014)	10 927	167	0.01%	-	-	-	-
Kovač et al. (2014)	455	-	-	1	0.2%	-	-
Gunnal et al. (2015)	340	3	0.9%	5	1.5%	-	-
Vlajković et al. (2015)	468	4	0.9%	-	-	-	-

hemispheres were perfused with saline, followed by colored silicone (MM922 Silicone, ACC Silicone Concepts). Any absent, duplicated and triplicated cortical branches were noted, and the origins and branching patterns were described. The diameter and length of the PCA cortical branches were measured using a digital micrometre, and string and a ruler. The posterior margin of the cerebral peduncle was used as the transition point between the P2A and P2P segments. The presence, duplication, triplication, diameter, length and origins of the PCA cortical branches are tabulated in Table V.

#### Absence, Duplication and Triplication

Most commonly absent was the splenial artery in 16 cases



**Figure 2:** Anomalies of the posterior cerebral artery (28). **A)** Duplication; and **B)** Triplication.

(80.0%), and the calcarine artery was duplicated in five cases (25.0%). The AITA was the only triplicated cortical branch (one case) (Table V).

#### Diameter and Lengths

The cortical branch with the largest diameter was the common temporal artery (2.0 mm); however, this artery was only present in 30.0%. The splenial artery had the smallest diameter (0.8 mm), as well as the greatest average length (63.2 mm).

#### Origin

The anterior, middle, posterior and common temporal arteries usually originated from the P2A segment, while the splenial artery mostly originated from the parieto-occipital artery. The PoA and calcarine artery usually originated from the P3 segment. The common temporal artery was observed in only six hemispheres; in three cases it gave origin to the MITA and PITA, and in three cases it gave origin to all three temporal arteries.

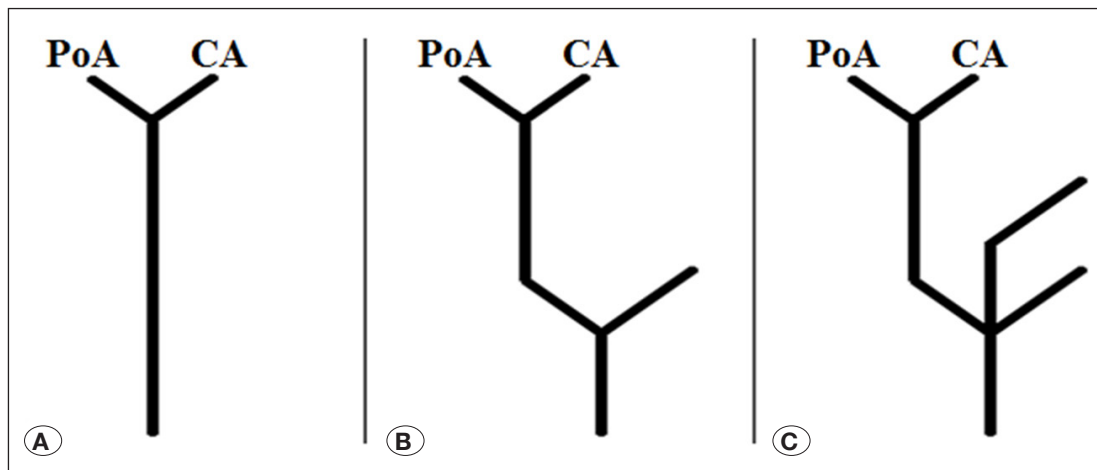
#### Branching Pattern

Since the literature has not sufficiently described the branching pattern of the PCA, this was done in the pilot study. The main branching point of the PCA is described as a division between the PoA and calcarine artery; however, this was only observed in one case. This branching type was defined as “monofurcation”. In the remaining 19 cases there was an additional branching before the division of the PoA and calcarine artery. This could result in two equal sized trunks (bifurcation) or three equal sized trunks (trifurcation).

**Table V:** The Average Diameter (mm), Average Length (mm), Presence, Duplication, Triplication and Origins of the Posterior Cerebral Cortical Branches Observed in the Pilot Study

	CTA	AITA	MITA	PITA	CA	PoA	SA
Presence	30.0%	75.0%	95.0%	95.0%	100%	100%	20.0%
Duplication	-	10.0%	-	10.0%	25.0%	10.0%	-
Triplication	-	5.0%	-	-	-	-	-
Diameter	2.0	1.0	1.3	1.6	1.2	1.5	0.8
Length	25.7	19.5	27.0	30.8	52.0	55.4	63.2
P2A	100%	77.8%	47.4%	52.4%	16.0%	13.6%	-
P2P	-	-	-	4.8%	24.0%	18.2%	25.0%
P3	-	-	-	4.8%	44.0%	54.6%	-
P4	-	-	-	-	8.0%	9.1%	-
CTA	-	11.1%	31.6%	28.6%	-	-	-
MITA	-	-	-	4.8%	-	-	-
PITA	-	11.1%	21.1%	-	4.0%	-	25.0%
CA	-	-	-	4.8%	-	4.6%	-
PoA	-	-	-	-	4.0%	-	50.0%

**AITA:** Anterior inferior temporal artery; **CA:** Calcarine artery; **CTA:** Common temporal artery; **MITA:** Middle inferior temporal artery; **PITA:** Posterior inferior temporal artery; **PoA:** Parieto-occipital artery; **SA:** Splenial artery.



**Figure 3:** The different branching types of the posterior cerebral artery.

**A)** Monofurcation;  
**B)** Bifurcation; and  
**C)** Trifurcation.



**Figure 4:** Fenestration of the P2A segment.

Monofurcation, bifurcation and trifurcation are illustrated in Figure 3A-C.

In the 16 bifurcation cases, the branching could occur at the origin of the CTA (six cases), PITA (eight cases) and MITA (two cases). Trifurcation was observed in the remaining three hemispheres. The first case was due to fenestration of the P2A segment (Figure 4). In the second case the PoA and calcarine artery divided early and the MITA arose at the bifurcation. In the third case a trifurcation was formed due to the anterior and posterior inferior temporal arteries arising at the same origin.

#### Anomalies

There were no duplication or triplication of the posterior cerebral artery; however, a large fenestration was observed in the left P2A segment in one case. This is illustrated in Figure 4. Only 20 hemispheres were assessed, consequently, a larger study will most likely result in a more realistic frequency of these anomalies.

#### CONCLUSION

In summary, a literature review was done on the anatomy of the PCA, specifically on the cortical branches, branching pattern, and anomalies of the PCA. After the gaps were outlined, a pilot study was done to further add data to these aspects.

In the literature review, it was established that the cortical branches can indicate variation in quantity, origin and size. However, few studies have been completed on these aspects. Furthermore, the branching pattern has not been satisfactorily described in the literature; in contrast, the PCA anomalies have been adequately described.

The pilot study therefore reported on the quantity, origin, diameter and length of these PCA cortical branches. In the pilot study it was evident that the branching pattern description is not the “normal” branching pattern since it was only observed in one case. Therefore, this branching pattern was re-evaluated and three groups were described; monofurcation, bifurcation and trifurcation. The anomalies of the PCA are scarce; however, one case of a fenestration was observed.

Knowledge of the anatomy of the PCA is important in any vascular surgery related to the PCA (25,26,50). Aneurysms are prone to form at branching points in cerebral vessels, thus knowledge on the branching pattern can aid in detection of ruptured and un-ruptured aneurysms (16,25,27,38,45). Future research should focus on the branching pattern of the PCA since limited information is available. A study with a larger samples size will most likely find more anomalies, since these anomalies are extremely rare. Possible sex, age and population differences may also exist.

#### ACKNOWLEDGEMENT

The authors wish to thank the Harry Crossley Foundation, and Mr. RP Williams for technical assistance.

## ■ REFERENCES

- Bartosiak P, Borowski S, Golab B: Variation of the origin, the course and branching of posterior cerebral arteries in man. *Folia Morphol (Warsz)* 42(3): 165-173, 1983
- Bayrak AH, Senturk S, Akay HO, Ozmen CA, Bukte Y, Nazaroglu H: The frequency of intracranial arterial fenestrations: A study with 64-detector CT-angiography. *Eur J Radiol* 77(3): 392-396, 2011
- Bergquist E: An anomalous posterior cerebral artery. *Neuroradiology* 8(4): 213-215, 1975
- Bharatha A, Aviv RI, White J, Fox AJ, Symons SP: Intracranial arterial fenestrations: Frequency on CT angiography and association with other vascular lesions. *Surg Radiol Anat* 30(5): 397-401, 2008
- Binning MJ, Couldwell WT: Fenestration of the oculomotor nerve by a duplicated posterior cerebral artery and aneurysm. Case report. *J Neurosurg* 111(1): 84-86, 2009
- Bisaria KK: Anomalies of the posterior communicating artery and their potential clinical significance. *J Neurosurg* 60(3): 572-576, 1984
- Bradac GB: *Cerebral Angiography-Normal Anatomy and Vascular Pathology*. London: Springer, 2011
- Buxton PJ, Cook PL: Anomalous origin of the parieto-occipital artery: Case note. *Neuroradiology* 35(3): 212, 1993
- Canham PB, Finlay HM: Morphometry of medial gaps of human brain artery branches. *Stroke* 35(5): 1153-1157, 2004
- Caruso G, Vincentelli F, Rabehanta P, Giudicelli G, Grisoli F: Anomalies of the P1 segment of the posterior cerebral artery: Early bifurcation or duplication, fenestration, common trunk with the superior cerebellar artery. *Acta Neurochir (Wien)* 109: 66-71, 1991
- Choi CY, Lee CH: A parieto-occipital artery arising from ICA directly and resultant incomplete PCA. *Surg Radiol Anat* 33(7): 641-643, 2011
- Cooke DL, Stout CE, Kim WT, Kansagra AP, Yu JP, Gu A, Jewell NP, Hetts SW, Higashida RT, Dowd CF, Halbach VV: Cerebral arterial fenestrations. *Interv Neuroradiol* 20(3): 261-274, 2014
- Dimmick SJ, Faulder KC: Normal variants of the cerebral circulation at multidetector CT angiography. *Radiographics* 29(4): 1027-1043, 2009
- Fisher CM: The circle of willis: Anatomical variations. *Ann Vasc Dis* 2: 99-105, 1965
- Gailloud P, Albayram S, Fasel JH, Beauchamp NJ, Murphy KJ: Angiographic and embryologic considerations in five cases of middle cerebral artery fenestration. *AJNR Am J Neuroradiol* 23(4): 585-587, 2002
- Gibo H, Carver CC, Rhoton AL, Lenkey C, Mitchell RJ: Microsurgical anatomy of the middle cerebral artery. *J Neurosurg* 54: 151-169, 1981
- Gloger S, Gloger A, Vogt H, Kretschmann HJ: Computer-assisted 3D reconstruction of the terminal branches of the cerebral arteries. III. Posterior cerebral artery and circle of Willis. *Neuroradiology* 36(4): 251-257, 1994
- Gordon-Shaw C: Two cases of reduplication of the arteria cerebri posterior. *J Anat Physiol* 44(3): 244-248, 1910
- Gunnal SA, Farooqui MS, Wabale RN: Study of posterior cerebral artery in human cadaveric brain. *Anat Res Int* 2015: 681903, 2015
- Gunnal SA, Wabale RN, Farooqui MS: Variations of anterior cerebral artery in human cadavers. *Neurol Asia* 18(3):249-259, 2013
- Hacein-Bey L, Muszynski CA, Varelas PN: Saccular aneurysm associated with posterior cerebral artery fenestration manifesting as a subarachnoid hemorrhage in a child. *AJNR Am J Neuroradiol* 23(8): 1291-1294, 2002
- Haegelen C, Berton E, Darnault P, Morandi X: A revised classification of the temporal branches of the posterior cerebral artery. *Surg Radiol Anat* 34(5): 385-391, 2012
- Hamidi C, Bukte Y, Hattapoglu S, Ekici F, Tekbas G, Onder H, Gumus H, Bilici A: Display with 64-detector MDCT angiography of cerebral vascular variations. *Surg Radiol Anat* 35(8): 729-736, 2013
- Iwashita T, Tanaka Y, Hongo K, Koyama Ji J, Koyama T, Nitta J: Aneurysm originating from the fenestration of the posterior cerebral artery: Case report. *Neurosurgery* 50(4):881-884, 2002
- Kahilogullari G, Ugur HC, Comert A, Tekdemir I, Kanpolat Y: The branching pattern of the middle cerebral artery: Is the intermediate trunk real or not? An anatomical study correlating with simple angiography laboratory investigation. *J Neurosurg* 116(5):1024-1034, 2012
- Kakou M, Destrieux C, Velut S: Microanatomy of the pericallosal arterial complex. *J Neurosurg* 93: 667-675, 2000
- Kaplan HA: The lateral perforating branches of the anterior and middle cerebral arteries. *J Neurosurg* 23(3): 305-310, 1965
- Kapoor K, Singh B, Dewan LI: Variations in the configuration of the circle of Willis. *Anat Sci Int* 83(2): 96-106, 2008
- Karazincir S, Ada E, Sarsilmaz A, Yalcin O, Vidinli B, Sahin E: Frequency of vascular variations and anomalies accompanying intracranial aneurysms. *Diagn Interv Radiol* 10(2):103-109, 2004
- Kawashima M, Rhoton AL, Tanriover N, Ulm AJ, Yasuda A, Fujii K: Microsurgical anatomy of cerebral revascularization. Part II: Posterior circulation. *J Neurosurg* 102(1):132-147, 2005
- Kovač JD, Stanković A, Stanković D, Kovač B, Šaranović D: Intracranial arterial variations: A comprehensive evaluation using CT angiography. *Med Sci Monit* 20: 420, 2014
- Krayenbuhl H, Yasargil MG, Huber P: *Cerebral angiography*. Thieme Medical Publishers, 1982
- Ladziński P, Maliszewski M: Variability of the division of the cortical branches of the posterior cerebral artery. *Anat Rec A Discov Mol Cell Evol Biol* 282(1):74-82, 2005
- Margolis MT, Newton TH, Hoyt WF: Cortical branches of the posterior cerebral artery. *Anatomic-radiologic correlation. Neuroradiology* 2(3):127-135, 1971
- Marinkovic SV, Milisavljevic MM, Lolic-Draganic V, Kovacevic MS: Distribution of the occipital branches of the posterior cerebral artery. Correlation with occipital lobe infarcts. *Stroke* 18: 728-732, 1987

36. Milenković Z: Anastomosis between internal carotid artery and anterior cerebral artery with other anomalies of the circle of Willis in a fetal brain. *J Neurosurg* 55(5): 701-703, 1981
37. Milisavljević M, Marinković S, Marinković Z, Malobabić S: Anatomic basis for surgical approach to the distal segment of the posterior cerebral artery. *Surg Radiol Anat* 10(4): 259-266, 1988
38. Ogeng'o JA, Njongo W, Hemed E, Obimbo MM, Gimongo J: Branching pattern of middle cerebral artery in an African population. *Clin Anat* 24(6): 692-698, 2011
39. Okahara M, Kiyosue H, Mori H, Tanoue S, Sainou M, Nagatomi H: Anatomic variations of the cerebral arteries and their embryology: A pictorial review. *Eur J Radiol* 12(10): 2548-2561, 2002
40. Osborn AG, Jacobs JM: *Diagnostic Cerebral Angiography*. 2<sup>nd</sup> ed. Lippincott Williams & Wilkins, 1999
41. Pai BS, Varma RG, Kulkarni RN, Nirmala S, Manjunath LC, Rakshith S: Microsurgical anatomy of the posterior circulation. *Neurol India* 55(1): 31-41, 2007
42. Parmar H, Sitoh YY, Hui F: Normal variants of the intracranial circulation demonstrated by MR angiography at 3T. *Eur J Radiol* 56(2): 220-228, 2005
43. Párraga RG, Ribas GC, Andrade SE, de Oliveira E: Microsurgical anatomy of the posterior cerebral artery in three-dimensional images. *World Neurosurg* 75(2): 233-257, 2011
44. Pasaoglu L, Hatipoglu HG, Vural M, Ziraman I, Ozcan HN, Koparal S: Persistent primitive hypoglossal artery and fenestration of posterior cerebral artery: CT and MR angiography. *Neurocirugia (Astur)* 20(6): 563-566, 2009
45. Perlmutter D, Rhoton AL: Microsurgical anatomy of the distal anterior cerebral artery. *J Neurosurg* 49: 204-228, 1978
46. Pleş HO, Loukas MA, Iacob NI, Andall NR, Miclăuş GD, Tubbs RS, Matusz PE: Duplication of the distal end of the left vertebral artery with fenestration of the right posterior cerebral artery. *Rom J Morphol Embryol* 56(2): 575-577, 2015
47. Sun ZK, Li M, Li MH, Li YD, Sun WP, Zhu YQ: Fenestrations accompanied by intracranial aneurysms assessed with magnetic resonance angiography. *Neurol India* 60(1): 45, 2012
48. Teal JS, Rumbaugh CL, Bergeron RT, Segall HD: Angiographic demonstration of fenestrations of the intradural intracranial arteries. *Radiology* 106(1): 123-126, 1973
49. Ture U, Yasargil MG, Krisht AF: The arteries of the corpus callosum: A microsurgical anatomic study. *Neurosurgery* 39(6): 1075-1084, 1996
50. Umansky F, Juarez SM, Dujovny M, Ausman JI, Diaz FG, Gomes F, Mirchandani HG, Ray WJ: Microsurgical anatomy of the proximal segments of the middle cerebral artery. *J Neurosurg* 61: 458-467, 1984
51. Van Rooij S, van Rooij WJ, Sluzewski M, Sprengers ME: Fenestrations of intracranial arteries detected with 3D rotational angiography. *AJNR Am J Neuroradiol* 30(7): 1347-1350, 2009
52. Vlajković S, Vasović L, Trandafilović M, Jovanović I, Ugrenović S, Đorđević G: Fenestrations of the human posterior cerebral artery. *Childs Nerv Syst* 31(3): 381-387, 2015
53. Windle BC: The arteries forming the circle of Willis. *J Anat Physiol* 22(2): 289-293, 1888
54. Yamamoto I, Kageyama N: Microsurgical anatomy of the pineal region. *J Neurosurg* 53(2): 205-221, 1980
55. Zanini MA, Pereira VM, Jory M, Caldas JG: Giant fusiform aneurysm arising from fenestrated posterior cerebral artery and basilar tip variation: Case report. *Neurosurgery* 64(3): E564-565, 2009
56. Zeal AA, Rhoton AL: Microsurgical anatomy of the posterior cerebral artery. *J Neurosurg* 48: 534-559, 1978