



DOI: 10.5137/1019-5149.JTN.20951-17.2

Received: 07.06.2017 / Accepted: 29.07.2017

Published Online: 15.09.2017

Case Report

Successful Application of the Ventriculo-Gallbladder Shunt: A Salvage Procedure

Bülent GUCLU¹, Tufan HICDONMEZ¹, Utku ADILAY¹, Yunus Emre ALTUNTAS²

¹University of Health Sciences, Kartal Dr Lutfi Kirdar Research and Training Hospital, Neurosurgery Clinic, Istanbul, Turkey

²University of Health Sciences, Kartal Dr Lutfi Kirdar Research and Training Hospital, General Surgery Clinic, Istanbul, Turkey

ABSTRACT

Ventriculo-gallbladder shunt is very rarely used in the treatment of hydrocephalus. A 44-year-old male with ventriculoatrial shunt dysfunction was evaluated. His ventriculoatrial shunt was not working. His medical history revealed that his hydrocephalus was treated five times by ventriculoperitoneal shunt, and four times by ventriculoatrial shunt. Another trial for ventriculoperitoneal or ventriculoatrial shunting was not considered feasible. A ventriculo-gallbladder shunt was placed to the patient as a potential salvage procedure. Remarkably, the patient benefited from the ventriculo-gallbladder shunt and was discharged from the hospital. We think that ventriculo-gallbladder shunting is a safe and effective treatment for hydrocephalus as the last resort in complicated cases of shunt dysfunction.

KEYWORDS: Hydrocephalus, Shunt dysfunction, Ventriculo-gallbladder shunt

INTRODUCTION

A ventriculoperitoneal shunt is the most common method used in the treatment of hydrocephalus (8). When a patient presents with abdominal problems, the ventriculoatrial shunt or ventriculopleural shunt can be considered as a treatment option. Lately, ventriculo-gallbladder shunt has been justified in situations where other options were not possible (4). Herein, we present a case of a patient who did not benefit from multiple ventriculoperitoneal and ventriculoatrial shunt operations, but significantly responded to the ventriculo-gallbladder shunt.

CASE REPORT

A 44-year-old male patient presented with ventriculoatrial shunt infection. His 5-year medical history revealed four ventriculoperitoneal and three ventriculoatrial shunt operations, none of which improved his condition. Although the third ventriculoatrial shunt was functional, it was infected. We replaced the ventriculoatrial shunt with the ventriculo-

peritoneal shunt; however, it did not work because of poor absorption capacity in the peritoneal cavity. We assessed the pleural space for placing the ventriculopleural shunt, but the pleura was highly calcified. Therefore, we replaced the ventriculoperitoneal shunt with the ventriculoatrial shunt, which worked for 6 months until the patient presented with shunt dysfunction symptoms at the emergency department of our hospital. We removed the ventriculoatrial shunt to alleviate his symptoms and placed an external ventricular drainage system. The feasibility of another trial of ventriculoperitoneal or ventriculoatrial shunting was dismal. Therefore, as a salvage procedure, a ventriculo-gallbladder shunt was placed in the patient (Figure 1). Remarkably, the patient benefitted from the ventriculo-gallbladder shunt and was discharged from the hospital.

DISCUSSION

Currently, several medical professionals consider the ventriculoperitoneal shunt as the standard treatment of hydrocephalus (8). However, in the case of non-availability



Corresponding author: Utku ADILAY

E-mail: utkuadilay@hotmail.com

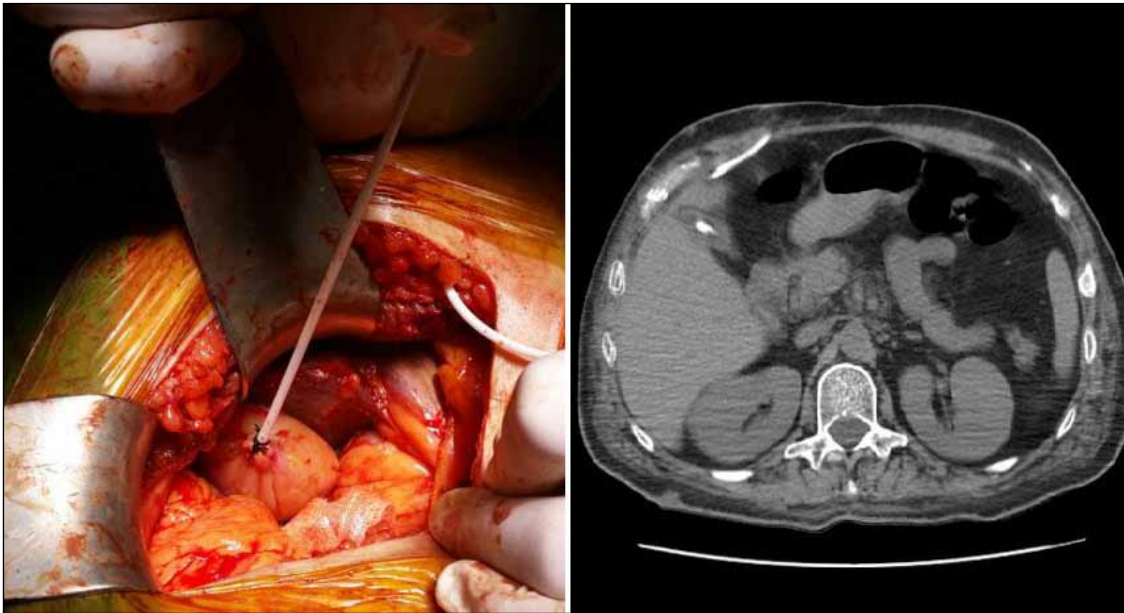


Figure 1: The distal end of the ventriculo-gallbladder shunt was placed inside the gallbladder (Left). Abdominal computed tomography shows the distal end of the ventriculo-gallbladder shunt in the gallbladder (Right).

of the peritoneal space, the ventriculopleural shunt is the most common alternative (5). At times, the ventriculoatrial shunt is also used in the absence of the peritoneal space (7). Nonetheless, in our case, the ventriculo-gallbladder shunt, initially reported by Smith et al.(9), was used as an alternative shunt.

The main function of the gallbladder is to store bile, which is needed for the digestion of food. The liver produces the bile, which then flows through the hepatic ducts into the gallbladder. At any one time, 30–60 mL of bile is stored in the gallbladder. The gallbladder concentrates the bile by absorbing water and inorganic electrolytes; the absorption range is approximately 16% of the total volume of the gallbladder per hour. Whether the cerebrospinal fluid from the gallbladder is drained completely into the duodenum through the common duct or some of it is absorbed by the vesicular epithelium is unclear. The suitability of the gallbladder to absorb the cerebrospinal fluid is because it can resorb fluid and electrolytes, is relatively sterile and the lytic action of the bile can potentially break down proteins in the cerebrospinal fluid, impairing absorption and forming reactive fibrous tissue (9).

The defective absorption of the cerebrospinal fluid through peritoneal and pleural cavities and any contraindication to the ventriculoatrial shunt usage increase the possibility of using the ventriculo-gallbladder shunt. As reported in our case, a majority of patients treated with the ventriculo-gallbladder shunt had an average of 3.9 ventricular shunts of a different type before using the ventriculo-gallbladder shunt (6).

Notably, ultrasonography of the gallbladder and bile ducts and the use of prophylactic antibiotics are necessary for the preparation of the ventriculo-gallbladder shunt. The contraindications to use the ventriculo-gallbladder shunt are cholecystitis, bile duct diseases and intra-abdominal infections. This surgical procedure is easy and well tolerated;

however, similar to those in other shunt systems, complications are likely during the post-operative follow-up period. West et al. placed the ventriculo-gallbladder shunt in 25 patients, of whom early (before 2 months) or late infection occurred in 6 patients and gallbladder atony developed in 2 patients (10). Bernstein and Hsueh reported the case of a paediatric patient who died after the application of the ventriculo-gallbladder shunt because of complications such as acquired communicating hydrocephalus, bilious ventriculitis secondary to a ventriculocholecystic shunt and pulmonary oedema (2). Conversely, Barami et al. demonstrated bile reflux in the lumbar-gallbladder shunt placed in a patient, who responded positively to shunt revision (1).

Fountas et al. reported the development of a distal obstruction in a previously inserted ventriculo-gallbladder shunt because of a large, radiolucent bile calculus (3).

■ CONCLUSION

In cases where the peritoneal cavity cannot serve as the insertion site of a ventricular shunt, other body cavities can be used to divert the cerebrospinal fluid. Because the gallbladder is one such alternative, the ventriculo-gallbladder shunt can be utilised successfully.

■ REFERENCES

1. Barami K, Sood S, Ham S, Canady A: Chemical meningitis from bile reflux in a lumbar-gallbladder shunt. *Pediatr Neurosurg* 29:328-330, 1998
2. Bernstein RA, Hsueh W: Ventriculocholecystic shunt. A mortality report. *Surg Neurol* 23:31-37, 1985
3. Fountas KN, Kassam MA, Grigorian AA: A rare, delayed complication of a ventriculogallbladder shunt. Case report and review of the literature. *Neurosurg Focus* 22:1-3, 2007

4. Hamamcioglu MK, Hicdonmez T, Kilincer C, Simsek O, Basaran UN, Cobanoglu S: Ventriculo-gallbladder shunting as an alternative treatment for complicated shunt dysfunction: Case report. *Turk Norosir Derg* 15:169-172, 2005 (In Turkish)
5. Haret DM, Onisei AM, Martin TW: Acute-recurrent subcutaneous emphysema after ventriculopleural shunt placement. *J ClinAnesth* 21:352-354, 2009
6. Hasslacher-Arellano JF, Arellano-Aguilar G, Funes-Rodríguez JF, López-Forcén S, Torres-Zapiain F, Domínguez-Carrillo LG: Ventriculo-gallbladder shunt: An alternative for the treatment of hydrocephalus. *Cir Cir* 84:225-229, 2016
7. Keucher TR, Mealey J Jr: Long-term results after ventriculoatrial and ventriculoperitoneal shunting for infantile hydrocephalus. *J Neurosurg* 50:179-186, 1979
8. Ngo QN, Ranger A, Singh RN, Kornecki A, Seabrook JA, Fraser DD: External ventricular drains in pediatric patients. *Pediatr Crit Care Med* 10:346-351, 2009
9. Smith GW, Moretz WH, Pritchard WL: Ventriculo-biliary shunt; a new treatment for hydrocephalus. *Surg Forum* 9:701-705, 1958
10. West KW, Turner MK, Vane DW, Boaz J, Kalsbeck J, Grosfeld JL: Ventricular gallbladder shunts: An alternative procedure in hydrocephalus. *J Pediatr Surg* 22:609-612, 1987