



DOI: 10.5137/1019-5149.JTN.20649-17.1

Received: 23.04.2017 / Accepted: 16.07.2017

Published Online: 21.09.2017

Original Investigation

# Safety and Efficacy of Ventriculostomy Procedures under Dual Antiplatelet Therapy in Patients Treated with Stent Assisted Coiling in Subarachnoid Hemorrhage

Soner CIVI<sup>1</sup>, Cagatay ANDIC<sup>2</sup>, Ozgur KARDES<sup>1</sup>, Halil Ibrahim SUNER<sup>1</sup>, Emre DURDAG<sup>1</sup>, Ozlem OZMETE<sup>3</sup>, Kadir TUFAN<sup>1</sup>

<sup>1</sup>Başkent University, School of Medicine, Department of Neurosurgery, Adana, Turkey

<sup>2</sup>Başkent University, School of Medicine, Department of Radiology, Adana, Turkey

<sup>3</sup>Baskent University, School of Medicine, Department of Anesthesiology and Reanimation, Adana, Turkey

## ABSTRACT

**AIM:** Stent assisted coiling (SAC) is an alternative in the treatment of ruptured aneurysms. Stenting requires the use of dual antiplatelet agents. Hydrocephalus is a complication of subarachnoid hemorrhage (SAH) and may require ventriculostomy. Antiplatelet treatment carries a risk of hemorrhage in ventriculostomy. The anti-aggregant effect starts at least four hours after the initial doses of treatment. However, in many studies, ventriculostomy was performed before antiplatelet treatment and hemorrhagic complications were related to the procedure. The aim of this study was to determine the risk of ventriculostomy related hemorrhage in patients with impaired thrombocyte function and to contribute to the literature.

**MATERIAL and METHODS:** Between 2011 and 2016, 53 patients treated with SAC due to SAH in our clinic were retrospectively evaluated. Hemorrhagic complication risks due to antiplatelet therapy related to ventriculostomy were also evaluated.

**RESULTS:** All of the ventricular catheter procedures were performed at least 1 day after the dual therapy (in average 4.3 days after SAC). In 5 patients 1 ventriculostomy was performed, in 2 patients 2, and in 1 patient 6 ventriculostomies were performed. Although radiological hemorrhage was present on the catheter tract in 4 patients, no temporary or permanent neurological deficit was observed.

**CONCLUSION:** Impaired thrombocyte functions pose a risk in ventriculostomy. Also, evaluating the risk of hemorrhage before the antiplatelet treatment reaches its full effect may lead to false results. Studies with small patient groups with anti-aggregant therapy and impaired thrombocyte functions also contribute to the literature. Larger studies regarding this subject are needed.

**KEYWORDS:** Hemorrhagic complication, Stent-assisted coiling, Ventriculostomy

## INTRODUCTION

About two-thirds of all patients with subarachnoid hemorrhage (SAH) following an aneurysm experience serious neurological complications or even death (20). In addition to conventional treatment using surgical clipping, endovascular coiling is an alternative treatment strategy (17,18). Intracranial stent-assisted coiling is useful particularly

for wide-neck aneurysms (15). Although the stent-assisted technique has been commonly used in the treatment of non-hemorrhagic aneurysms, recently it is also being employed for the treatment of ruptured aneurysms. Stenting requires institution of treatment with dual antiplatelet agents (acetylsalicylic acid and clopidogrel) to avoid thromboembolic complications (1,16).

qr code

Corresponding author: Soner CIVI

E-mail: sonercivi@yahoo.com

The risk of developing acute hydrocephalus following SAH is 20%, and it is usually treated with a ventriculostomy (11,13,21). The risk of ventriculostomy-related hemorrhage is low in patients without impairment of platelet function. Patients receiving dual antiplatelet therapy for prevention of stent thrombosis are at high risk of hemorrhage. However, these results were obtained from studies in which patients with unimpaired platelet function were evaluated (14,16,23).

We aimed to contribute to the literature while evaluating the risk of ventriculostomy-related hemorrhage in patients who underwent stent-assisted coiling (SAC) with concurrent impairment in platelet function.

## ■ MATERIAL and METHODS

### Patient Population and Procedural Technique

Our study was performed after a proposal was approved by the Institutional Review Board at the Baskent University, School of Medicine. We retrospectively evaluated data obtained from 53 patients treated using the SAC method for a ruptured aneurysm between June 2011 and April 2016. Informed consent was obtained from all patients included in the study, or from their relatives with regard to approval for administration of medications, and permission to perform interventional and surgical procedures. The study included 30 women (mean age 50.2 years), and 23 men (mean age 51.08 years).

Six asymptomatic patients who demonstrated ventriculomegaly did not undergo a surgical procedure, and were not included in our study. Only eight patients who underwent 15 ventriculostomies due to hydrocephalus following the SAC procedure for SAH were enrolled in the study.

Angiographic evaluation determined the size of aneurysms and their morphology. A wide-neck aneurysm was defined as one having a dome-to-neck ratio  $<2:1$  and/or a neck length  $>4$  mm. In patients treated with SAC, 600 mg of clopidogrel and 100 mg of aspirin were administered as a loading dose via a nasogastric tube just prior to treatment, with a daily maintenance dose of 75 mg of clopidogrel and 100 mg aspirin. All patients were heparinized to maintain an activated clotting time of 250-300 seconds during the endovascular procedure. Heparinization was discontinued after the procedure, and patients were switched to low-molecular weight heparin. Platelet inhibition levels were confirmed using the rapid platelet function assay, viz. VerifyNow P2Y12 (Accumetrics, San Diego, California) the day after the procedure and on day 5. Low-molecular weight heparin administration was discontinued if therapeutic levels were noted to have been achieved (inhibition value  $>30\%$ ).

A standard ventriculostomy catheter (outer diameter 2.8 mm, PS Medical ventricular catheter, Medtronic) was advanced 5-6 cm from Kocher's point. A Ghajar guide (Neurodynamics, Inc.) was used in all patients.

### Determination of Ventriculostomy-Related Hemorrhage

Computed tomography (CT) scans obtained in all patients were reviewed by a radiologist and a neurosurgeon. We

evaluated 63 CT scans. Patients demonstrating hemorrhage in locations other than along the ventricular catheter tract were excluded from the study. Cerebral hemorrhage occurring along the catheter tract was considered to be related to the ventriculostomy (Figure 1A, B). A review of the patient's medical records determined the clinical significance of the hemorrhage. Hemorrhage was classified as symptomatic if deterioration in neurological examination could not be attributed to pathological processes such as vasospasm, meningitis, or stroke, and was considered asymptomatic if the patient showed no changes on clinical examination. However, in some cases, ventriculostomy-related hemorrhage was diagnosed concurrently with severe vasospasm or meningitis.

## ■ RESULTS

We retrospectively evaluated records obtained from 53 patients in whom SAC was used to treat ruptured aneurysms between June 2011 and April 2016. A ventriculostomy was performed in eight patients while they were concomitantly administered dual antiplatelet treatment. Patients were between 36-75 years of age (mean 51.8 years). Of these patients ( $n=8$ ), five showed aneurysms in the anterior circulation [two internal carotid artery (ICA) and three anterior communicating artery (ant-com)], two had aneurysms in the posterior circulation (two basilar dome), and one patient had two aneurysms of the anterior and posterior communicating arteries (ant-com and post-com). The Hunt-Hess score was 3 in six patients, and 4 in two. Prior to ventriculostomy, the Fisher score on CT scan was noted to be 4 in all patients. Initial post-ventriculostomy CT scan was performed within the first 24 hours (Figure 2A, B). Ventricular drains were changed only if occluded or if infection was detected. However, no ventricular catheter was used for longer than a week. Patients who underwent long-term drainage for a week had their catheters changed due to blockage. All ventricular catheter procedures were performed at least a day after the institution of dual therapy (mean of 4.3 days after SAC). "Prothrombin time" or "activated clotting time" was determined in all patients prior to performing ventriculostomy procedures. All values were within normal limits. Patients with known bleeding diathesis were excluded from the study. One ventriculostomy was performed in five patients, 2 ventriculostomies in two patients, and 6 ventriculostomies were performed in one patient. Although radiologically there was evidence of hemorrhage along the catheter tract in four patients, no temporary or permanent neurological deficit was observed. No deaths were related to complications associated with the ventriculostomy. Demographic data of the patients included in the study are presented in Table I.

## ■ DISCUSSION

Intracranial stents are used in the treatment of wide-neck aneurysms where conventional methods are insufficient. The use of a stent requires anti-aggregant treatment. Previously, use of anti-aggregant treatment was avoided due to the risk of possible hemorrhagic complications; however, this led to the risk of thromboembolic events (5,7-9).

Table 1: Demographic Data of the 8 Patients Included in the Study

Case no.	Age (yrs)/ Sex	Aneurysm	Hunt and Hess Grade	Fisher Score	EVD Placement	Radiological hemorrhage on the catheter tract	Final mRS	Duration of ventricular drainage (days)	Results of hydrocephalus after drainage
1	75/M	ACoA	III	IV	Post-procedure	no	6	4	No clinical deterioration due to hydrocephalus.
2	39/M	ACoA	III	IV	Post-procedure	yes	2	13	No clinical deterioration due to hydrocephalus. Shunt was performed after the acute phase.
3	59/F	BA	III	IV	Post-procedure	yes	3	17	No clinical deterioration due to hydrocephalus.
4	46/F	ICA	IV	IV	Post-procedure	no	6	2	No clinical deterioration due to hydrocephalus.
5	70/M	ACoA, rt PCoA	IV	IV	Post-procedure	no	6	3	No clinical deterioration due to hydrocephalus.
6	50/M	ACoA	III	IV	Post-procedure	yes	6	2	No clinical deterioration due to hydrocephalus.
7	36/M	ICA	III	IV	Post-procedure	yes	2	15	No clinical deterioration due to hydrocephalus. Shunt was performed after the acute phase.
8	40/M	BA	III	IV	Post-procedure	no	6	14	No clinical deterioration due to hydrocephalus.
<b>Mean</b>	<b>51.8</b>								

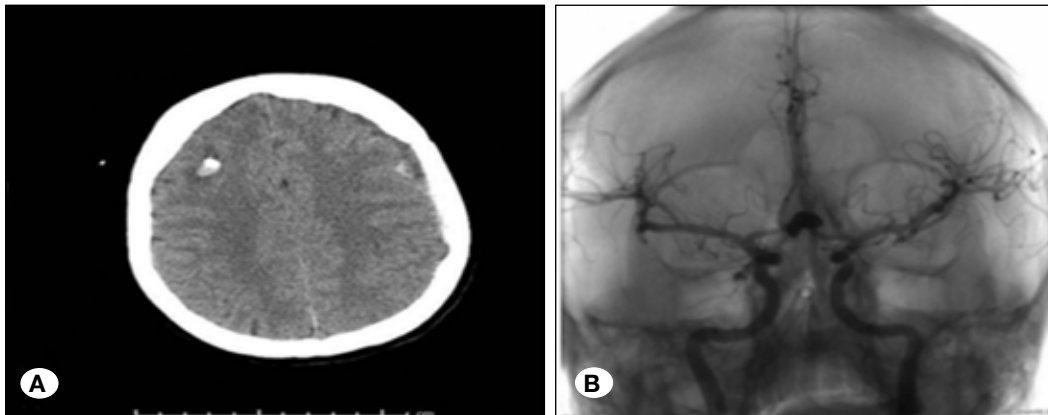
**ACoA:** Anterior communicating artery; **PCoA:** Posterior communicating artery; **BA:** Basilar artery; **ICA:** Internal carotid artery; **mRS:** Modified Rankin Scale; **EVD:** External ventricular drainage; **ys:** Years; **rt:** Right; **M:** male; **F:** female.

Reportedly, the rate of thromboembolic complications is 7-15% (4,9). Although antiplatelet agents have been used in recent times for the prevention of these complications (2,3,5), their use has been associated with a higher risk of hemorrhagic complications. Data regarding complications in patients using dual antiplatelet therapy are primarily obtained from coronary artery related procedures; gastrointestinal and retroperitoneal hemorrhages have been commonly reported (8-10,12,24).

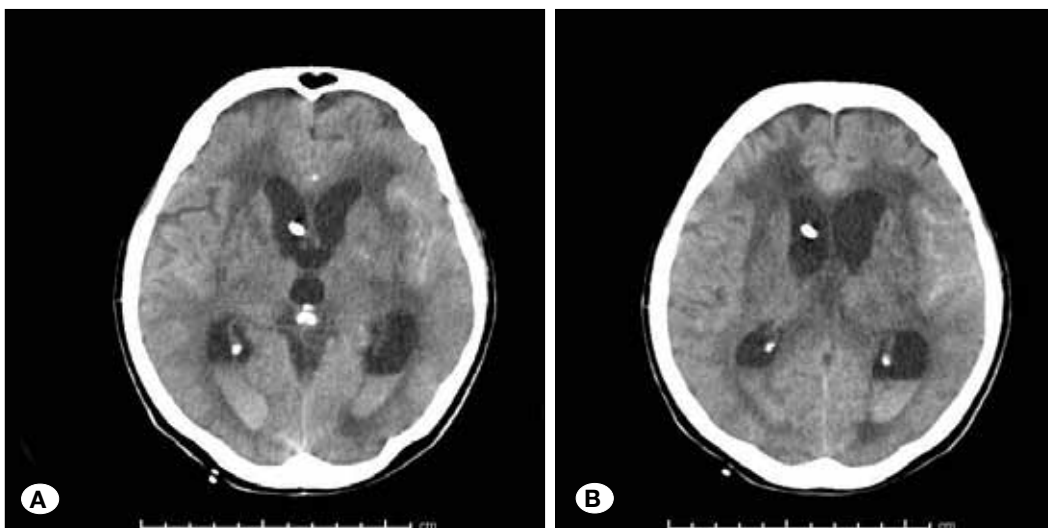
Previous studies have shown that clopidogrel use is dose dependant and a single dose of 600 mg causes major antiplatelet activity within 2 hours of use. Aspirin is rapidly absorbed from the stomach and upper gastrointestinal system with peak plasma concentrations attained within 30-40 minutes of intake resulting in inhibition of platelet function within an hour (19,25). However, in studies performed to determine the risk of hemorrhage in patients with a ventriculostomy with concurrent administration of dual therapy, it has been observed that in some patients, the ventriculostomy had been performed prior to administration of the dual therapy, while in some others, it was performed after dual therapy had been instituted (6). If patients are not administered dual therapy prior to SAC treatment and at the time of the ventriculostomy procedure, hemorrhagic changes observed along the catheter

tract in such cases would not be attributable to platelet function impairment.

Numerous studies describe ventriculostomy-related hemorrhagic complications associated with endovascular treatment of intracranial aneurysms. Although relatively safe, ventriculostomy is not a risk-free procedure. A meta-analysis involving 1790 patients who underwent ventriculostomy reported the risk of hemorrhagic complications as 5.7%. However, the rate of clinically significant hemorrhage was 0.61%. Dual therapy was considered to be the most important risk factor associated with a ventriculostomy, and it is known to be catheter related. Kim et al., in a study performed on patients with SAH, reported that all hemorrhagic complications were secondary to ventriculostomies (7). Bodily et al., in a literature review, found that among 90 patients, 10 (11%) showed ventriculostomy-related hemorrhages. However, because the precise number of ventriculostomies performed on patients included in the study could not be determined, the reported rate was estimated to be approximately 3-10%. In this study, dual therapy had generally been administered following the ventriculostomy (4). Tumialan et al., in their case series which included seven patients, reported hemorrhagic complications in six (85%) patients. In this study, similar to the previously



**Figure 1: A)** CT scan (axial slice) shows right frontal subcortical ventriculostomy-related hemorrhage. **B)** Brain angiography after the stent coil was placed.



**Figure 2A,B:** CT scan (axial image) shows hydrocephalus and intraventricular catheter.

described one, the ventriculostomy had been performed before dual therapy had been instituted in 5/7 patients, and hemorrhagic complications were observed in four patients.

In this study, a ventriculostomy was performed in two patients with concurrent administration of dual therapy, and both patients developed hemorrhagic complications (23). Kung et al. evaluated 50 ventriculostomy procedures in 40 patients and found evidence of radiological (asymptomatic) hemorrhages in 16 (32%) patients and symptomatic hemorrhages in four (8%). In this study, the procedure had been performed while they concomitantly received dual therapy in 3/4 symptomatic patients, while dual therapy had been administered prior to the ventriculostomy or revision procedure was performed in 3/16 asymptomatic patients (14). Taylor et al., in their study performed on 17 patients, reported an instance of one symptomatic and one asymptomatic procedure-related intracranial hemorrhage. In both cases, ventriculostomies had been performed prior to the endovascular procedure (22).

Bruder et al. performed ventriculostomies on seven patients after anticoagulant treatment had been administered and ventriculostomy-related hemorrhage was observed in three (43%) cases. In the same study, 110 patients had ventriculostomies performed prior to initiation of anticoagulant treatment, and hemorrhage was observed in 25 (25%) patients (6).

Lodi et al., in their study performed on 15 patients, performed ventriculostomy on 13 patients 6 hours prior to administration of a loading dose of anticoagulant to prevent any complications, and no complications were observed. This study demonstrated that performing external ventricular drainage at least 6 hours before the loading dose is administered can prevent complications (15).

We retrospectively evaluated eight patients receiving dual therapy who were treated using the SAC method and 15 ventriculostomies due to hydrocephalus were evaluated. Ventriculostomies performed prior to SAC were excluded from the study. The inclusion criterion was that the ventriculostomy should have been performed at least 6 hours after administration of dual therapy. The primary objective of application of this criterion was to determine the effect of dual therapy on hemorrhagic complications. Hemorrhage was observed using radiological evaluation in four (50%) patients receiving dual therapy, but all patients were asymptomatic, or it could be stated that the clinical deterioration was not ventriculostomy related. As shown in literature, the rate of hemorrhagic complications in patients not receiving dual therapy is 0-25% as opposed to 43-80% in those receiving anti-aggregant therapy. However, patients with or without intake of dual therapy were included in these studies, and the rates stated above are all obtained after detailed literature review. These studies also included patients who showed hemorrhagic complications even in the absence of concurrent dual therapy, indicating that these complications were related to late-onset adverse effects of dual therapy.

In the present study, the effect of anti-aggregant therapy was determined using evaluation of platelet function as an indicator

in all patients who underwent a ventriculostomy. Patients who required acute interventions due to hydrocephalus were excluded from the study, and the risk of hemorrhage was evaluated using objective criteria. This fact distinguishes our study from previous ones. The rate of hemorrhage obtained in our study in patients without use of dual therapy is higher than rates determined previously. This can be accepted as evidence of the fact that concurrent dual therapy increases the risk of hemorrhage. Not all patients in our study presented with hydrocephalus; however, the presence of intraventricular hemorrhage was associated with a risk of hydrocephalus. Additionally, the need for ventriculostomy arose after the initiation of dual therapy.

Intraventricular hemorrhage is associated with a risk of hydrocephalus, and if a ventriculostomy is performed prior to platelet function impairment (institution of antiplatelet therapy), the risk of complications is expected to be lower.

This study has limitations due to its retrospective nature, the relatively small patient population that was studied, and lack of comparison with a control group. Nevertheless, our study did demonstrate a definite risk of ventriculostomy-related hemorrhagic complications associated with platelet function inhibition.

## ■ CONCLUSION

Our study showed that patients treated with SAC in the presence of impaired platelet function might be at higher risk of hemorrhagic complications following a ventriculostomy. Studies demonstrating ventriculostomy-related risks of hemorrhagic complications owing to platelet dysfunction are very limited and clinical cases contributing to literature comprise small studies. Patients included in these studies had undergone a ventriculostomy before SAC was performed due to acute hydrocephalus. Thus, platelet inhibition had not yet occurred. Due to the limited number of patients included in previous studies, as well as in ours, we propose that larger study samples would be required to obtain definitive evidence.

## ■ REFERENCES

1. Akbari SH, Reynolds MR, Kadkhodayan Y, Cross DT 3rd, Moran CJ: Hemorrhagic complications after prasugrel (Effient) therapy for vascular neurointerventional procedures. *J Neurointerv Surg* 5:337-343, 2013
2. Alfke K, Straube T, Dorner L, Mehdorn H, Jansen O: Treatment of intracranial broad-neck aneurysms with a new self-expanding stent and coil embolization. *AJNR Am J Neuroradiol* 25:584-591, 2004
3. Benitez RP, Silva MT, Klem J, Veznedaroglu E, Rosenwasser RH: Endovascular occlusion of wide-necked aneurysms with a new intracranial microstent (Neuroform) and detachable coils. *Neurosurgery* 54:1359-1368, 2004
4. Bodily KD, Cloft HJ, Lanzino G, Fiorella DJ, White PM, Kallmes DF: Stent-assisted coiling in acutely ruptured intracranial aneurysms: A qualitative, systematic review of the literature. *AJNR Am J Neuroradiol* 32: 1232-1236, 2011

5. Brisman JL, Song JK, Niimi Y, Berenstein A: Treatment options for wide-necked intracranial aneurysms using a self-expandable hydrophilic coil and a self-expandable stent combination. *AJNR Am J Neuroradiol* 26:1237–1240, 2005
6. Bruder M, Schuss P, Konczalla J, El-Fiki A, Lescher S, Vatter H, Seifert V, Güresir E: Ventriculostomy-related hemorrhage after treatment of acutely ruptured aneurysms: The influence of anticoagulation and antiplatelet treatment. *World Neurosurg* 84: 1653–1659, 2015
7. Chung J, Lim YC, Suh SH, Shim YS, Kim YB, Joo JY, Kim BS, Shin YS: Stent-assisted coil embolization of ruptured wide-necked aneurysms in the acute period: incidence of and risk factors for periprocedural complications. *J Neurosurg* 121:4–11, 2014
8. Fiorella D, Albuquerque FC, Deshmukh VR, McDougall CG: Usefulness of the Neuroform stent for the treatment of cerebral aneurysms: Results at initial (3–6-mo) follow-up. *Neurosurgery* 56: 1191–1192, 2005
9. Fiorella D, Albuquerque FC, Han P, McDougall CG: Preliminary experience using the Neuroform stent for the treatment of cerebral aneurysms. *Neurosurgery* 54: 6–17, 2004
10. Grewe PH, Deneke T, Machraoui A, Barmeyer J, Müller KM: Acute and chronic tissue response to coronary stent implantation: Pathologic findings in human specimen. *J Am Coll Cardiol* 35:157–163, 2000
11. Hasan D, Vermeulen M, Wijdicks EF, Hijdra A, van Gijn J: Management problems in acute hydrocephalus after subarachnoid hemorrhage. *Stroke* 20: 747–753, 1989
12. Jabbour P, Koebbe C, Veznedaroglu E, Benitez RP, Rosenwasser R: Stent-assisted coil placement for unruptured cerebral aneurysms. *Neurosurg Focus* 17:E10, 2004
13. Kassell NF, Torner JC, Haley EC Jr, Jane JA, Adams HP, Kongable GL: The international cooperative study on the timing of aneurysm surgery. Part 1: Overall management results. *J Neurosurg* 73:18–36, 1990
14. Kung DK, Policeni BA, Capuano AW, Rossen JD, Jabbour PM, Torner JC, Howard MA, Hasan D: Risk of ventriculostomy-related hemorrhage in patients with acutely ruptured aneurysms treated using stent-assisted coiling. *J Neurosurg* 114: 1021–1027, 2011
15. Lodi YM, Latorre JG, El-Zammar Z, Swarnkar A, Deshaies E, Fessler RD: Stent assisted coiling of the ruptured wide necked intracranial aneurysm. *J Neurointerv Surg* 4: 281–286, 2012
16. Mahaney KB, Chalouhi N, Viljoen S, Smietana J, Kung DK, Jabbour P, Bulsara KR, Howard M, Hasan DM: Risk of hemorrhagic complication associated with ventriculoperitoneal shunt placement in aneurysmal subarachnoid hemorrhage patients on dual antiplatelet therapy. *J Neurosurg* 119:937–942, 2013
17. Molyneux A, Kerr R, Stratton I, Sandercock P, Clarke M, Shrimpton J, Holman R; International Subarachnoid Aneurysm Trial (ISAT) Collaborative Group: International Subarachnoid Aneurysm Trial (ISAT) of neurosurgical clipping versus endovascular coiling in 2143 patients with ruptured intracranial aneurysms: A randomised trial. *Lancet* 360: 1267–1274, 2002
18. Molyneux AJ, Kerr RS, Yu LM, Clarke M, Sneade M, Yarnold JA, Sandercock P; International Subarachnoid Aneurysm Trial (ISAT) Collaborative Group: International subarachnoid aneurysm trial (ISAT) of neurosurgical clipping versus endovascular coiling in 2143 patients with ruptured intracranial aneurysms: A randomised comparison of effects on survival, dependency, seizures, rebleeding, subgroups, and aneurysm occlusion. *Lancet* 366: 809–817, 2005
19. Patrono C, Baigent C, Hirsh J, Roth G: American College of Chest Physicians. Antiplatelet drugs: American College of Chest Physicians Evidence-Based Clinical Practice Guidelines (8th Edition). *Chest* 133: 199–233, 2008
20. Stapf C, Mohr JP: Aneurysms and subarachnoid hemorrhage-epidemiology. In: Le Roux PD, Winn HR, Newell DW (eds), *Management of Cerebral Aneurysms*. Philadelphia: Saunders, 2004: 183–188
21. Suarez-Rivera O: Acute hydrocephalus after subarachnoid hemorrhage. *Surg Neurol* 49: 563–565, 1998
22. Taylor RA, Callison RC, Martin CO, Hayakawa M, Chaloupka JC: Acutely ruptured intracranial saccular aneurysms treated with stent assisted coiling: Complications and outcomes in 42 consecutive patients. *J Neurointerv Surg* 2:23–30, 2010
23. Tumulán LM, Zhang YJ, Cawley CM, Dion JE, Tong FC, Barrow DL: Intracranial hemorrhage associated with stent-assisted coil embolization of cerebral aneurysms: A cautionary report. *J Neurosurg* 108: 1122–1129, 2008
24. Van Belle E, Tio FO, Couffinhal T, Maillard L, Passeri J, Isner JM: Stent endothelialization. Time course, impact of local catheter delivery, feasibility of recombinant protein administration, and response to cytokine expedition. *Circulation* 95:438–448, 1997
25. Von Beckerath N, Taubert D, Pogatsa-Murray G, Schömig E, Kastrati A, Schömig A: Absorption, metabolization, and antiplatelet effects of 300-, 600-, and 900-mg loading doses of clopidogrel: Results of the ISAR-CHOICE (Intracoronary Stenting and Antithrombotic Regimen: Choose Between 3 High Oral Doses for Immediate Clopidogrel Effect) Trial. *Circulation* 112: 2946–2950, 2005